



1

ADRIANA MEIRELLES
PAULO AGUILLERA

ABDOMINAL
ULTRASOUND IN
CATS AND DOGS:
AN ILLUSTRATED
REFERENCE VALUE
GUIDE

ABDOMINAL ULTRASOUND IN CATS AND DOGS: AN ILLUSTRATED REFERENCE VALUE GUIDE

Adriana Meirelles

Paulo Aguilera

About the authors



Adriana Meirelles , MVS, graduated from the School of Veterinary Medicine at the Federal University of Rio Grande do Sul (UFRGS), Brazil, in 2008. She completed her residency program in Diagnostic Imaging at Universidade Estadual Paulista (UNESP) at Jaboticabal in 2010, and received her Master's degree in Veterinary Surgery from the same institution in 2012 with a dissertation on Diagnostic Imaging. Today, she is a veterinary sonographer in Canoas, RS, Brazil. She also teaches online courses on veterinary ultrasound, and provides mentorship to veterinary sonographers in Brazil through an online program called Ultrasound Club, which is currently under expansion to become international (<https://veterinaryultrasoundclub.com>).

Visit Adriana's website: <https://vetadrianameirelles.com.br>

Like Adriana on Facebook: <facebook.com/vetadrianameirelles>

Follow Adriana on Instagram: <instagram.com/vetadrianameirelles>

Veterinary Ultrasound Club's profile on Instagram:
<instagram.com/veterinaryultrasoundclub>



Paulo Aguilera has graduated from Veterinary Medicine at UNIFEOB (2006), in Brazil. He completed a specialization program in Diagnostic Imaging at IBVET-Campinas. He has been a lecturer and teacher in veterinary ultrasound courses since 2014. Today, he is a veterinary sonographer in Ribeirão Preto, Brazil, teaches online courses, and provides mentorship to veterinary sonographers through the Ultrasound Club (<https://ultrassonografiacub.com.br/>).

Follow Paulo no Instagram: [instagram.com/paulo_aguilera/](https://www.instagram.com/paulo_aguilera/)

Table of contents

<u>URINARY BLADDER</u>
<u>KIDNEYS</u>
<u>RENAL PELVIS</u>
<u>URETER</u>
<u>URETHRA</u>
<u>SPLEEN</u>
<u>ADRENAL GLANDS</u>
<u>PANCREAS</u>
<u>MAJOR DUODENAL PAPILLA</u>
<u>LIVER</u>
<u>GALLBLADDER</u>
<u>AORTA, PORTAL VEIN E CAUDAL VENA CAVA</u>
<u>UTERUS</u>
<u>OVARIES</u>
<u>PROSTATE</u>
<u>TESTICLES</u>

PREFACE

During our years practicing veterinary ultrasound, we perceived the need to check reference values while writing our reports. In many instances, these values are used all the time and are widely known. In other situations, however, details regarding these values may be quite overwhelming, and the chances of making mistakes increase if we do not revisit these numbers.

From our experience as mentors for hundreds of veterinary sonographers in our Ultrasound Club, it became clear that these professionals need an easy, yet safe, way of checking reference values in their daily routine. Because of that, an old project was reborn, and we created our first publication to help our colleagues. All values presented here were carefully checked in scientific publications and compiled in this illustrated reference guide of abdominal ultrasound in cats and dogs.

We hope this guide is useful to you!

Sincerely,

Adriana Meirelles and Paulo Aguilera

URINARY BLADDER

The table below contains reference values for urinary bladder thickness in cats and dogs.

NORMAL URINARY BLADDER WALL THICKNESS IN CATS AND DOGS	
SPECIES	WALL THICKNESS
FELINE	0.13 to 0.17 cm
CANINE*	0.23 cm (minimal distension) 0.16 cm (mild distension) 0.14 cm (moderate distension)
* The values shown are averages. Minimal, mild and moderate distensions correspond to 0.5 ml/kg, 2 ml/kg, and 4 ml/kg, respectively.	

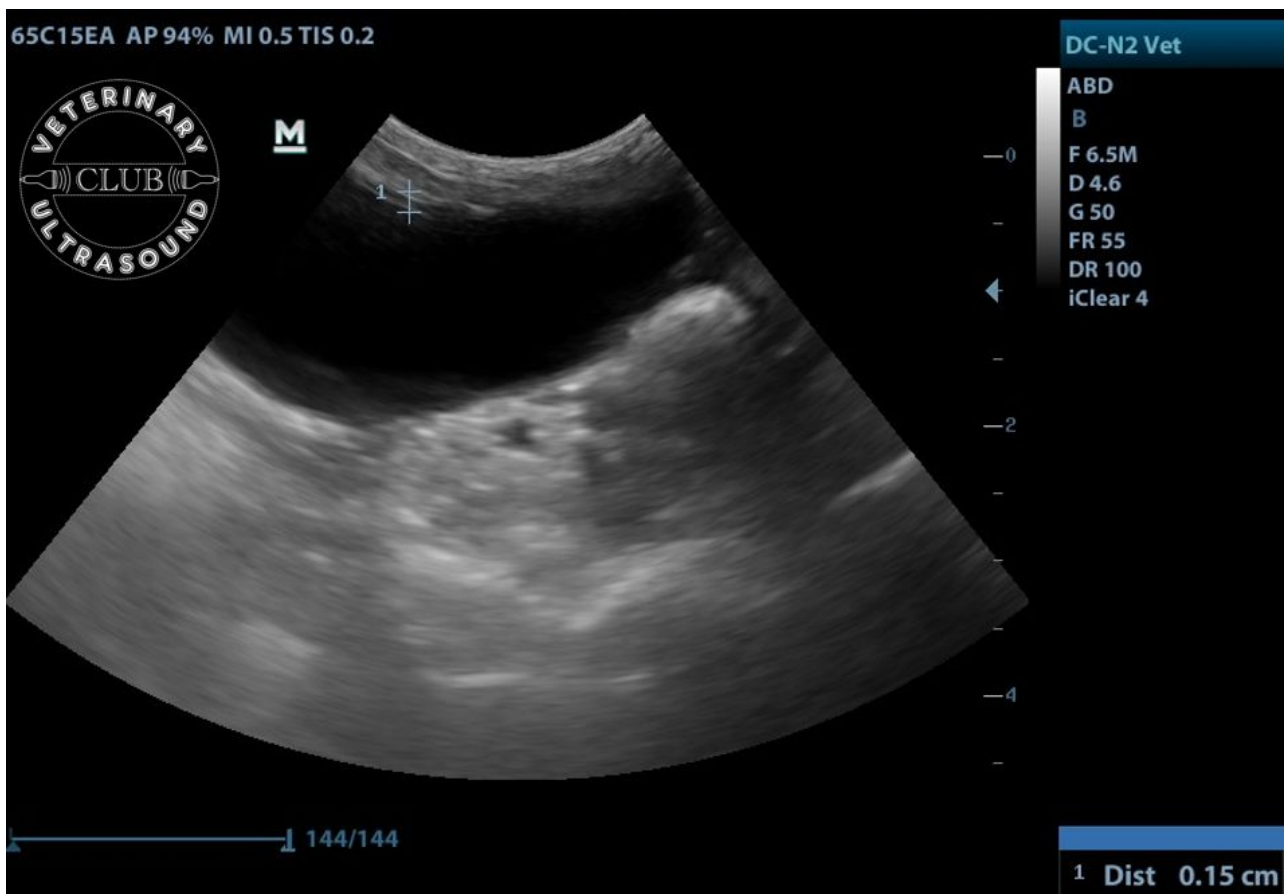


Figure 1. Ultrasound image of a urinary bladder in a dog. The calipers were placed on the internal and external surfaces of the ventral wall of the bladder. The distance between calipers (Distance 1; 0.15 cm) corresponds to the thickness of the urinary bladder wall.

KIDNEYS

The table below contains the normal size range of feline kidneys, and normal values of kidney to aorta ratio, with the aorta diameter measured caudal to the left renal artery.

NORMAL KIDNEY DIMENSIONS IN CATS AND DOGS

SPECIES	SIZE
FELINE	3.8 a 4.4 cm
CANINE	Kidney/aorta ratio between 5.5 and 9.1

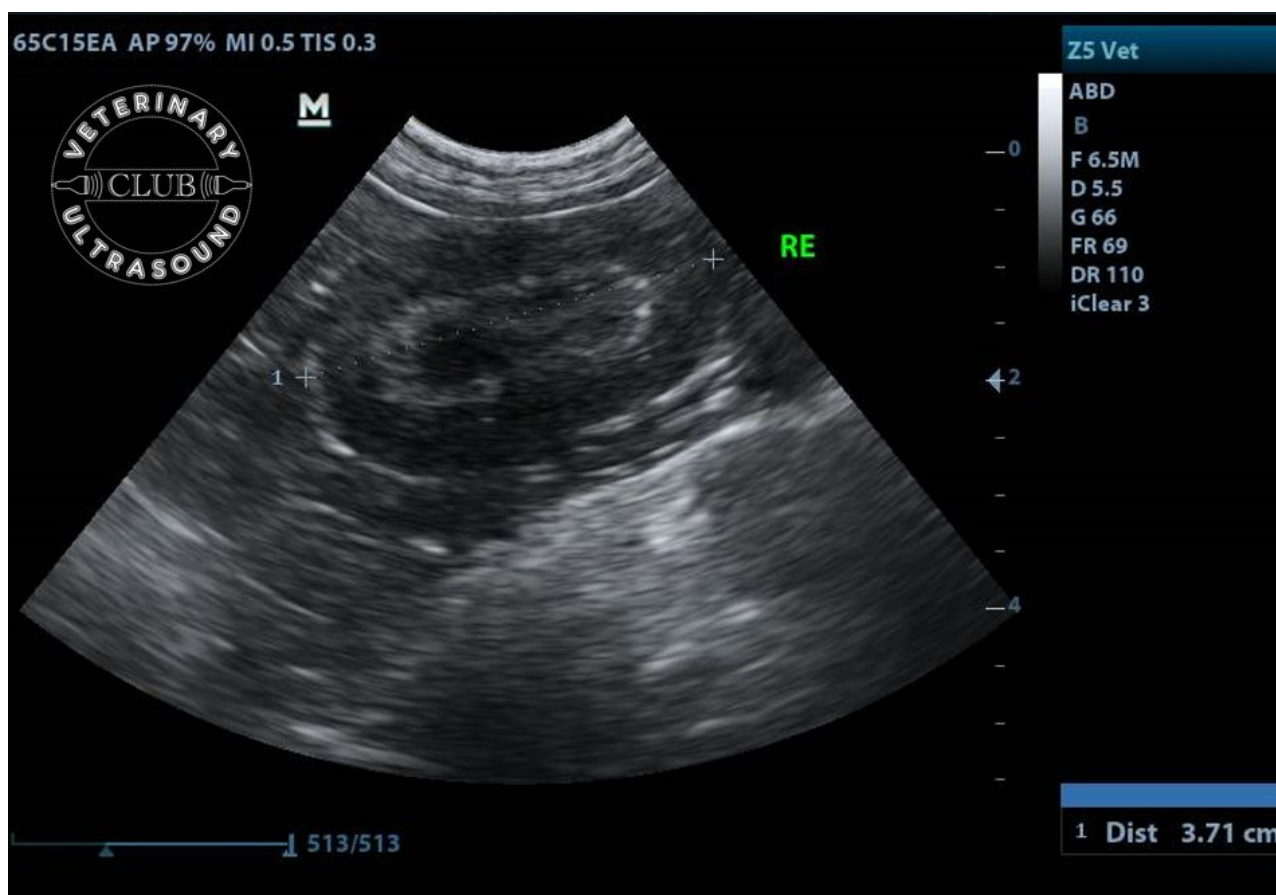


Figure 2. Ultrasound image of a kidney in a cat. The distance between calipers (Distance 1 in the image; 3.71 cm) defines the renal length.

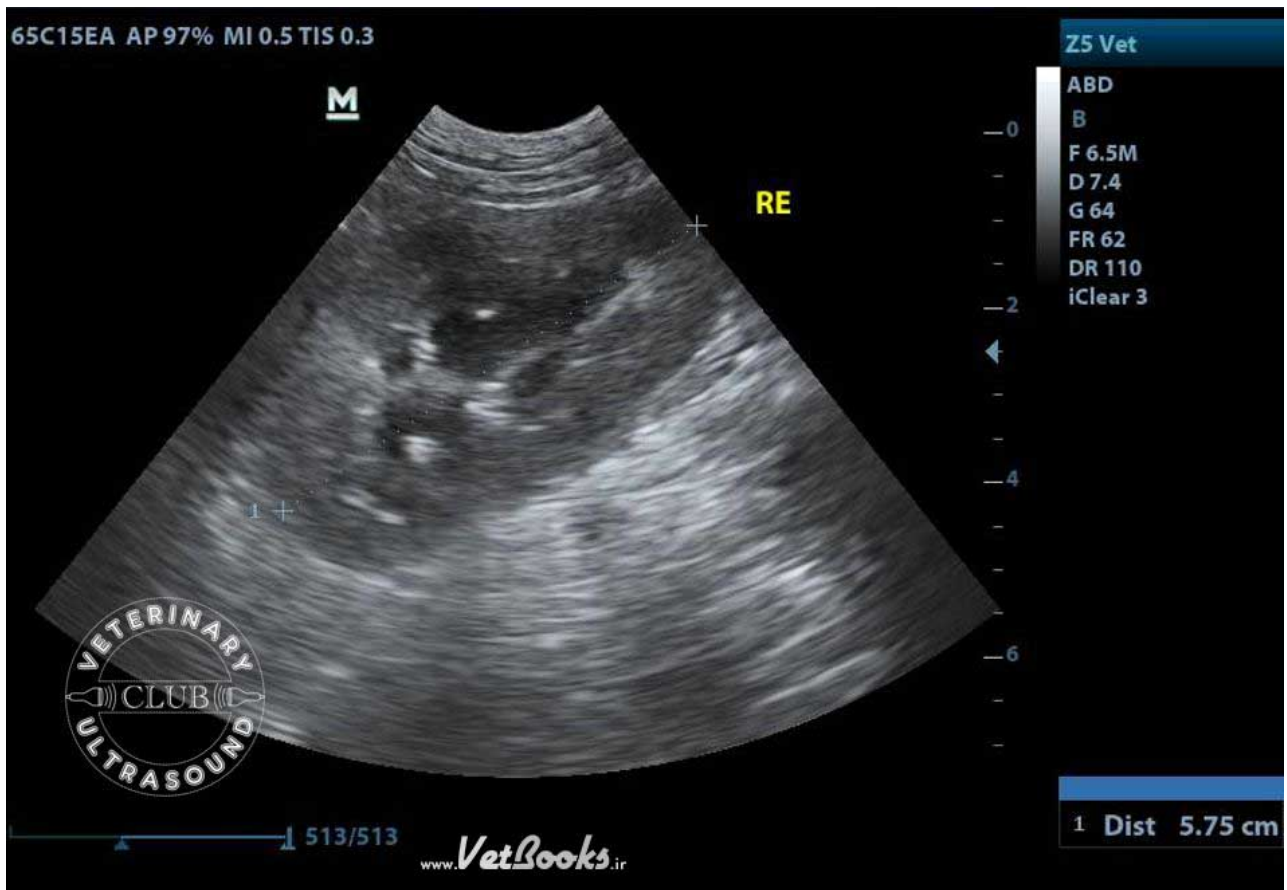

Figure 3. Ultrasound image of a kidney in a dog. The calipers were positioned on the cranial and caudal poles to determine the length of the kidney (in this case, 5.75 cm).

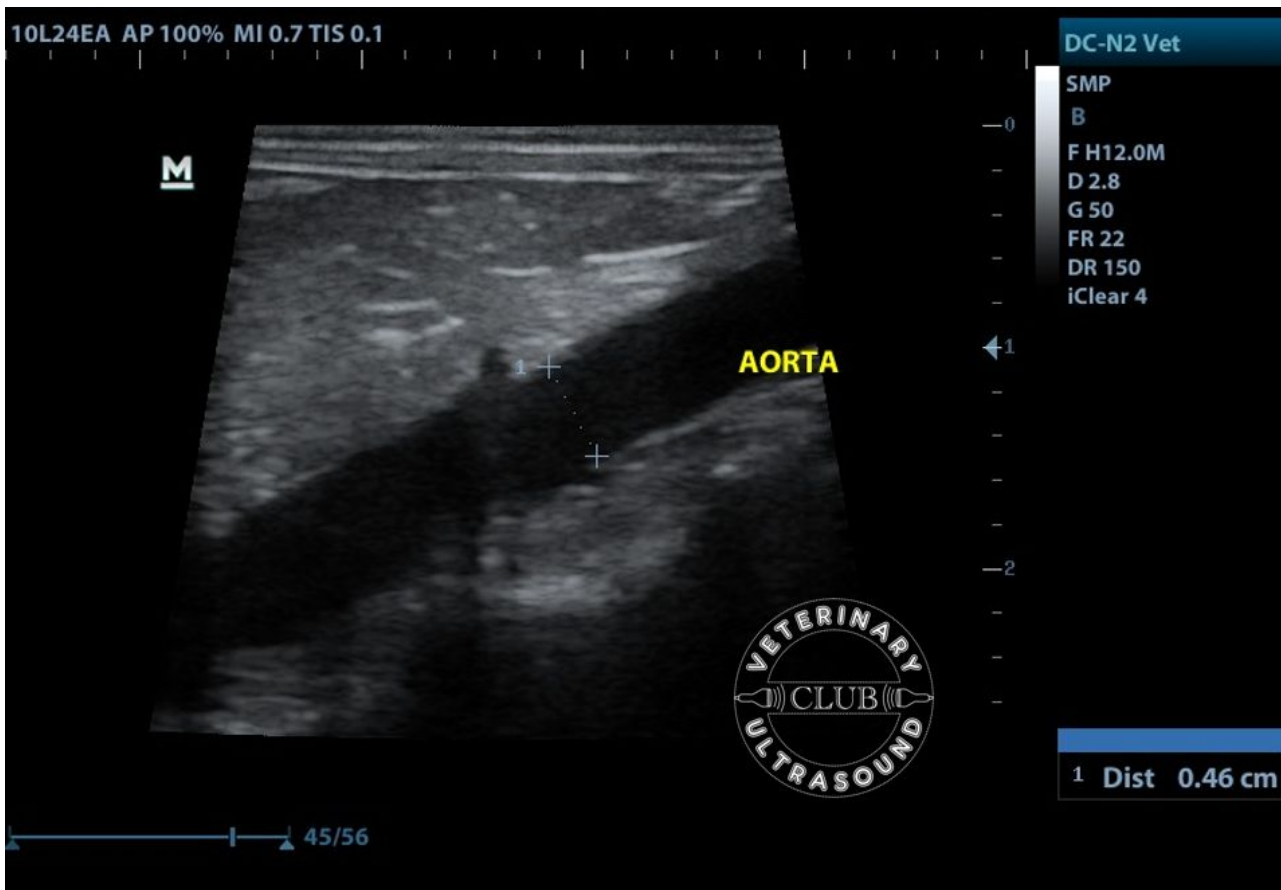


Figure 4. Ultrasound image of the abdominal aorta in a dog. The diameter of the aorta was measured caudal to the left renal artery. The calipers were positioned in the lumen, excluding the vessel walls. The distance between calipers (Distance 1; 0.46 cm) corresponds to the diameter of the aorta.

Additional information on the kidneys in dogs

- The length of the kidneys in dogs is variable due to variable sizes and weights existent in this species. Because of that, the ratio between the kidney length and the diameter of the aorta in longitudinal plane can be used, as follows:

Kidney/aorta ratio greater than 9.1 = increased kidneys

Kidney/aorta ratio less than 5.5 = reduced kidneys
--

- A published study has determined kidney length according to weight in dogs. The table below shows the average sizes and ranges of kidney length in 100 dogs (200 kidneys):

NORMAL RENAL LENGTH IN DOGS		
Weight (kg)	Average (cm)	Range (cm)

0-4	3.2	3.2 – 3.3
5-9	4.4	3.2 – 5.2
10-14	5.6	4.8 – 6.4
15-19	6.0	5.0 – 6.7
20-24	6.5	5.2 – 8.0
25-29	6.9	5.7 – 7.8
30-34	7.2	6.1 – 8.7
35-39	7.6	6.6 – 9.3
40-44	7.6	6.3 – 8.4
45-49	8.5	7.6 – 9.1
50-59	9.1	7.5 – 10.6
60-69	9.0	8.3 – 9.8
90-99	9.4	8.6 – 10.1

Additional information on the kidneys in cats

- The kidneys should be symmetrical.
- Some studies show that the average kidney length in cats ranges from 3 to 4.3, but may reach up to 5.3 cm.
- A study on normal kidney dimensions in cats found an average \pm standard deviation of 3.99 ± 0.4 cm for the right kidney, and 3.83 ± 0.42 cm for the left kidney. Another study found similar values: 3.8 ± 0.4 cm for the right kidney, and 3.7 ± 0.3 cm for the left kidney.
- **Normal kidney lengths** for the following **specific cat breeds** are: 4.09 ± 0.33 cm for Sphynx, 3.77 ± 0.43 cm for British Shorthair, and 3.87 ± 0.41 cm for Ragdoll.
- Females have smaller kidneys compared to males.
- Neutered males have larger kidneys compared to intact males.
- Some studies reported thickness values for cortex and medulla. One study found a thickness of 0.82 ± 0.14 cm for the cortex, and 0.59 ± 0.06 cm for the medulla. Another study reported a smaller value for normal cortical thickness (0.47 ± 0.08 cm), and slightly different medullary thicknesses between the left and right kidneys (0.55 ± 0.07 cm for the medulla of the left kidney, and 0.5 ± 0.07 cm for the medulla of the right kidney). There are also normal values for specific breeds, which will not be covered here. In general terms, the left kidney has a thicker medulla and, consequently, a smaller corticomedullary ratio compared to the right kidney.

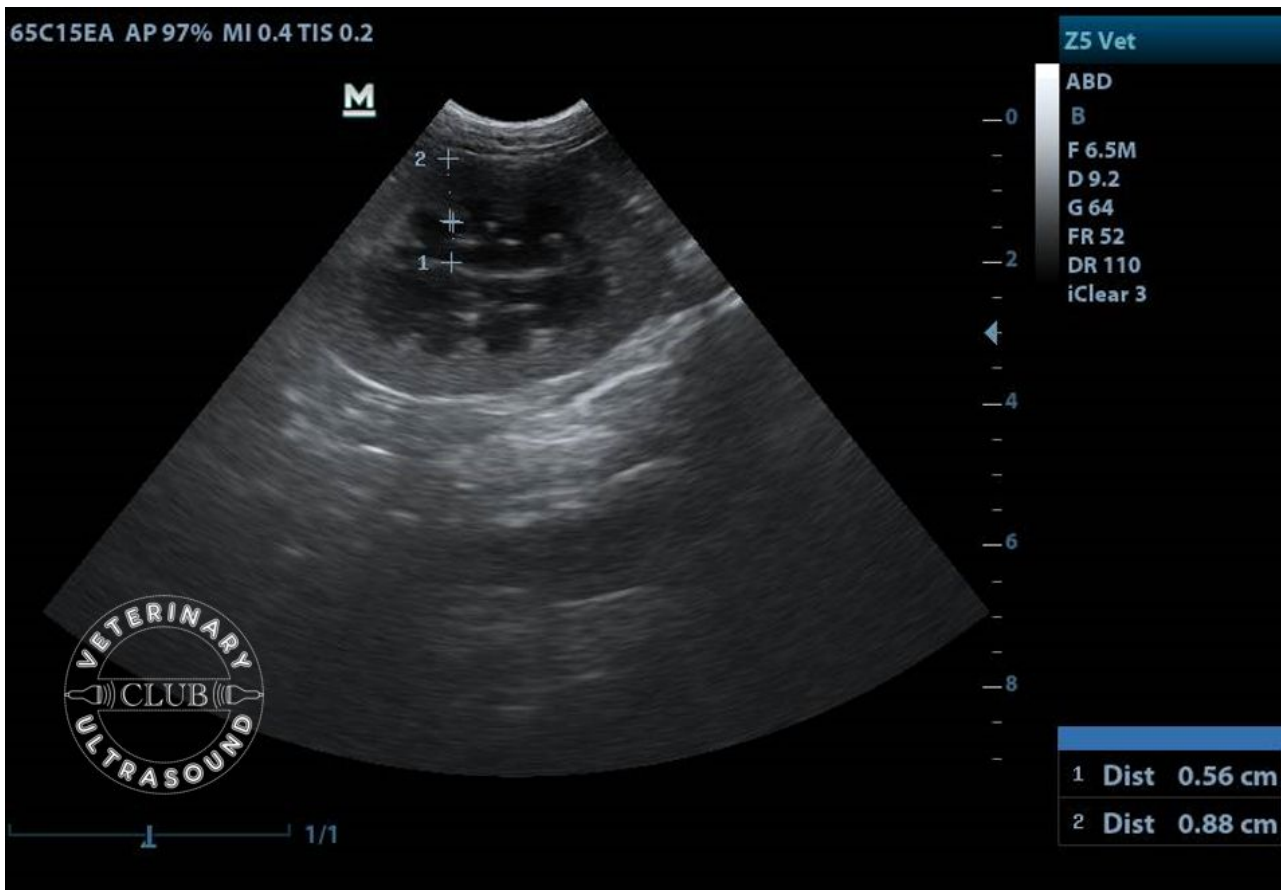


Figure 5. Ultrasound image of a feline kidney. Distance 1 represents the thickness of the medullary region (0.56 cm), and Distance 2 represents the thickness of the cortical region (0.88 cm).

RENAL PELVIS

The table below contains normal dimensions for the renal pelvis in cats and dogs.

NORMAL RENAL PELVIS DIMENSIONS	
SPECIES	LUMEN
FELINE	Up to 0.3 cm
CANINE	Up to 0.3 cm

Additional information on the renal pelvis in cats and dogs

- A study on renal pelvis dilatation showed that values above 1.3 cm were predictive of obstruction in 100% of the cases. Values lower than 1.3 are not predictive of obstruction, but cannot be used to exclude the hypothesis of obstruction at an initial stage.

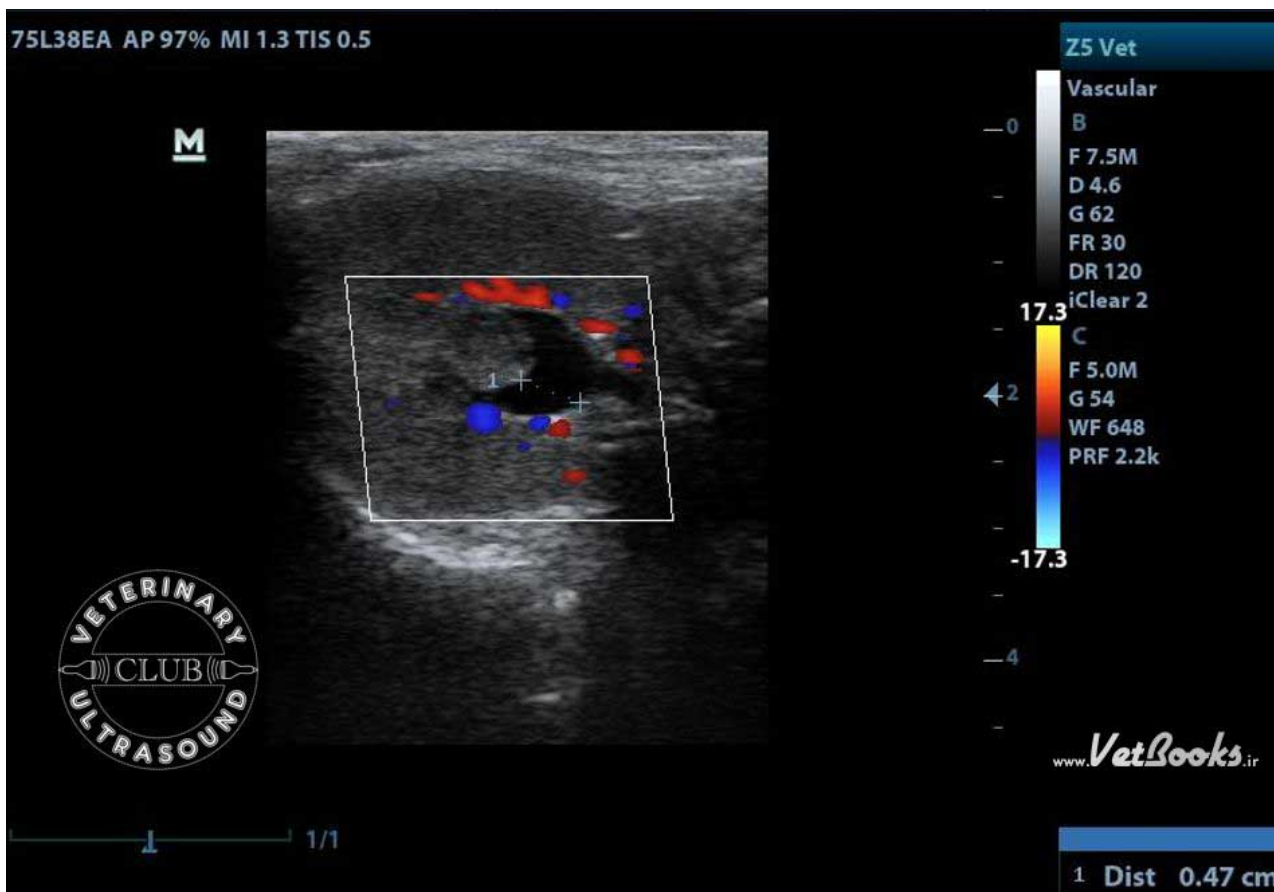


Figure 6. Ultrasound image of a dilated renal pelvis. The measurement should be taken on transverse plane, with calipers positioned from the renal crest to the renal sinus.

URETER

The ureter is normally not visible unless dilated. Reference values follow below:

NORMAL URETER DIAMETER IN CATS AND DOGS	
SPECIES	URETERAL DIAMETER
FELINE	External diameter 0.1 cm Luminal diameter 0.04 cm
CANINE*	0.13-0.27 cm
* These values are based on computed tomography (CT). The ureteral diameter observed on post-contrast CT scans measured up to 0.34 cm.	

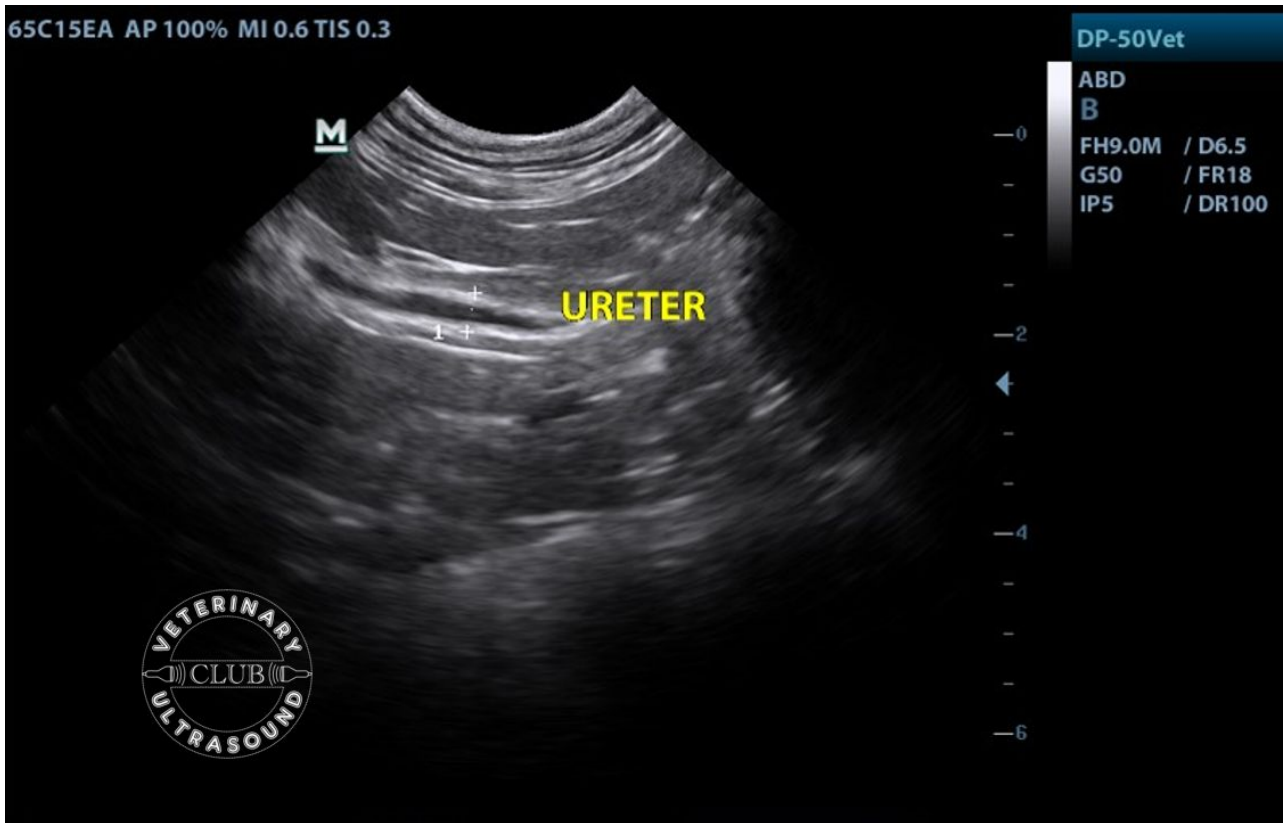


Figure 7. Ultrasound image of a dilated ureter in a cat. The caliper was placed on the walls of the ureter, which was hyperechoic and thickened in this patient, measuring 0.4 cm in diameter.

URETHRA

Under normal circumstances, the lumen of the urethra is not visible unless the urinary bladder is distended. In that case, urethral obstruction should be investigated.

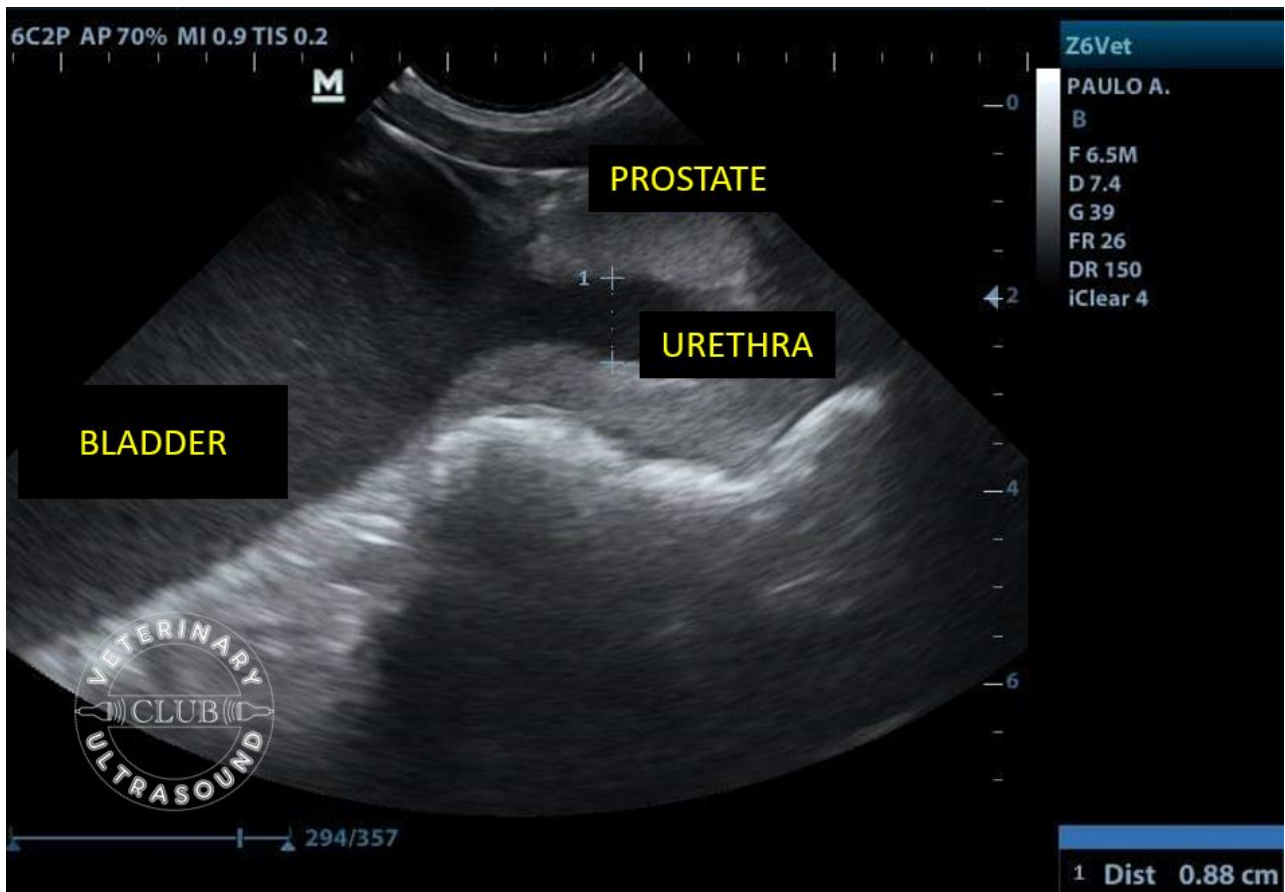


Figure 8. Ultrasound image of a dilated prostatic urethra in a dog. The distance between the calipers (Distance 1; 0.88 cm) represents the diameter of the prostatic urethra.

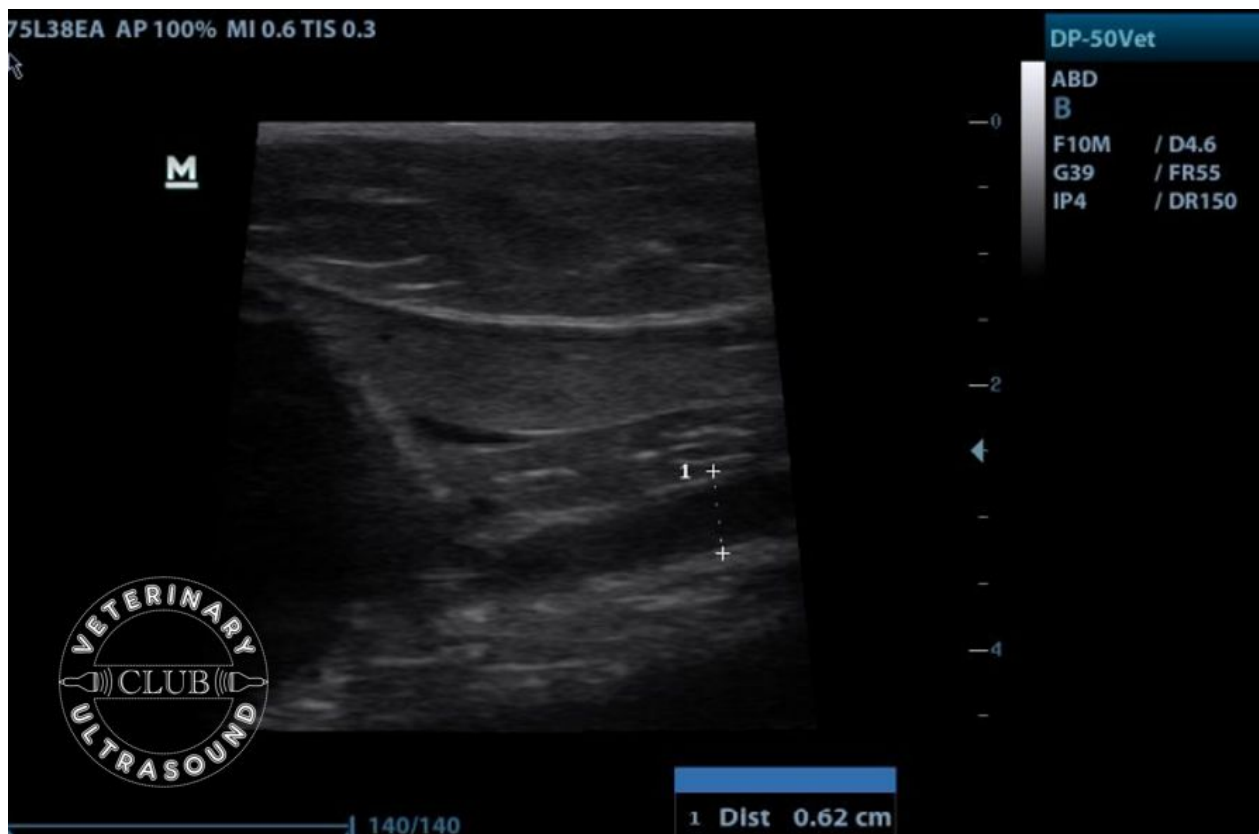

Figure 9. Ultrasound image of a dilated urethra in a cat with urethral obstruction. The distance between

calipers (Distance 1) is 0.62 cm.

SPLEEN

The table below contains information on the normal dimensions of the spleen in cats and dogs.

NORMAL DIMENSIONS OF THE SPLEEN IN CATS AND DOGS	
SPECIES	DIMENSIONS
FELINE	Thickness of the proximal portion: 0.71 cm (0.51-0.91 cm) - A thickness greater than 0.91 cm indicates splenomegaly and suggests cytology should be performed - A folded spleen indicates splenomegaly Width: 2.67 cm
CANINE	Evaluation if subjective. Check extension and borders

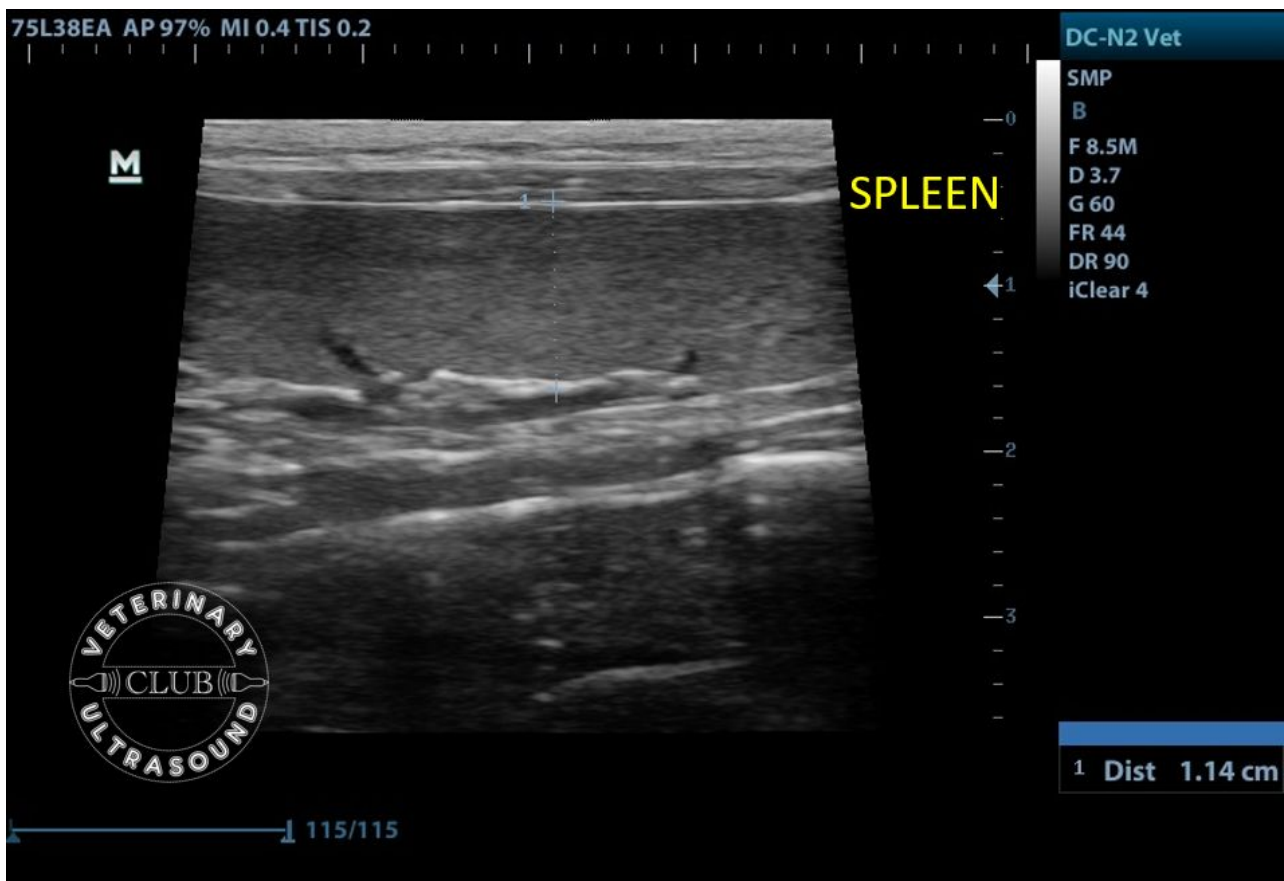


Figure 10. Ultrasound image of an increased spleen in a cat. The measurement should be performed in the proximal third. The radicle of the lienal vein ("splenic vein") may be used as a reference point on the mesenteric surface.

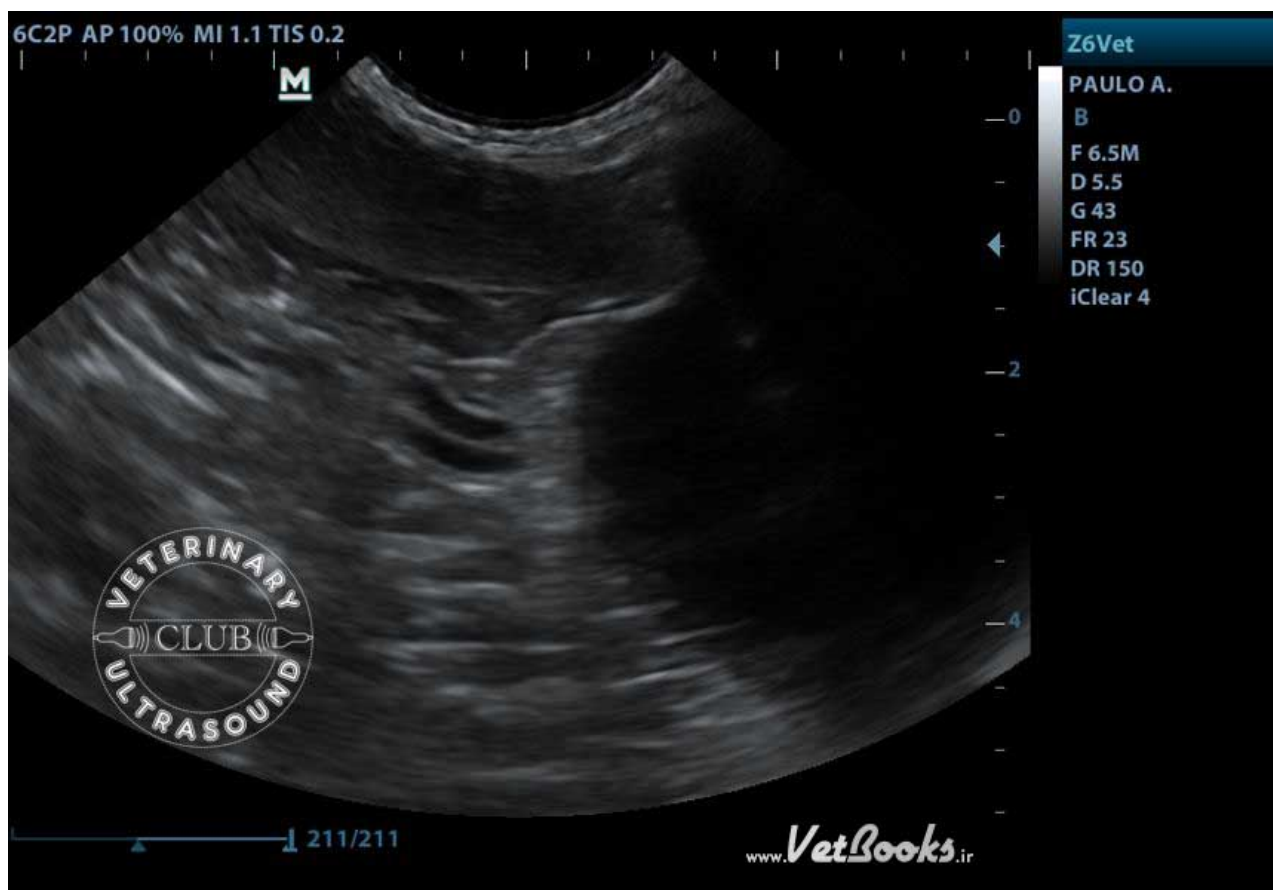


Figure 11. Ultrasound image of an increased spleen in a dog. In this case, the organ was evaluated subjectively by observing the contact and displacement of the urinary bladder.

ADRENAL GLANDS

The table below contains reference values for dimensions of the adrenal glands in cats in dogs.

NORMAL DIMENSIONS OF THE ADRENAL GLANDS IN CATS AND DOGS	
SPECIES	DIMENSIONS
FELINE	Length: 0.89 – 1.25 cm
	Cranial pole thickness: 0.30 – 0.48 cm
	Caudal pole thickness: 0.30 – 0.45 cm
CANINE	Length: 1 a 5 cm
	Dogs up to 10 kg: up to 0.54 cm*
	Dogs from 11 to 30 kg: up to 0.68 cm*
	Dogs above 30 kg: up to 0.8 cm*
* Maximal height (cutoff value) of the caudal pole in sagittal plane. Length is too variable and not significantly important for evaluation of adrenal gland alterations in dogs.	

Additional information about the adrenal glands in dogs

- A detailed study has defined normal adrenal gland thickness according to weight and age of dogs. The table below shows average thickness in centimeters found at the caudal pole, with values grouped according to weight and age.

NORMAL THICKNESS OF THE CAUDAL POLE OF THE ADRENAL GLANDS OF DOGS						
WEIGHT (kg)	AGE (years)					
	<4		4-8		>8	
	RAG	LAG	RAG	LAG	RAG	LAG
<6	0.38	0.36	0.43	0.42	0.42	0.43
6-12	0.47	0.43	0.44	0.41	0.44	0.44
12-20	0.46	0.46	0.47	0.46	0.55	0.54
20-30	0.49	0.48	0.52	0.49	0.52	0.54
30	0.50	0.47	0.52	0.49	0.56	0.61
TODOS	0.46	0.44	0.47	0.45	0.49	0.51

RAG, right adrenal gland; LAG, left adrenal gland. The values shown are averages in centimeters.

- In the study mentioned above, the authors determined that the caudal pole of the adrenal gland should not be greater than 0.62 cm in dogs under 12 kg, and not greater than 0.72 cm in dogs with weight greater than or equal to 12 kg.

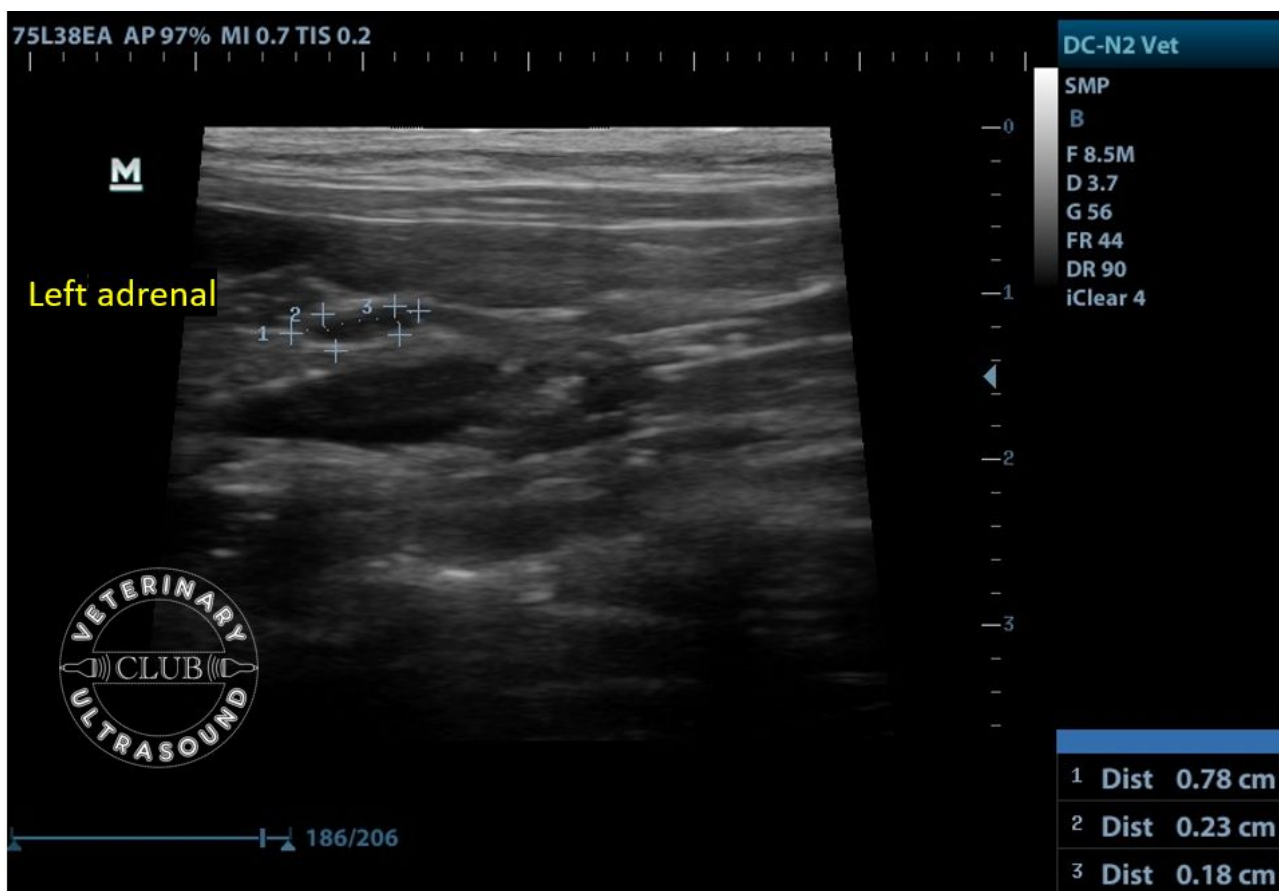


Figure 12. Ultrasound image of the left adrenal gland in a cat. The length (Distance 1; 0.78 cm) and height of the cranial (Distance 2; 0.23 cm) and caudal (Distance 3; 0.18 cm) poles were determined.

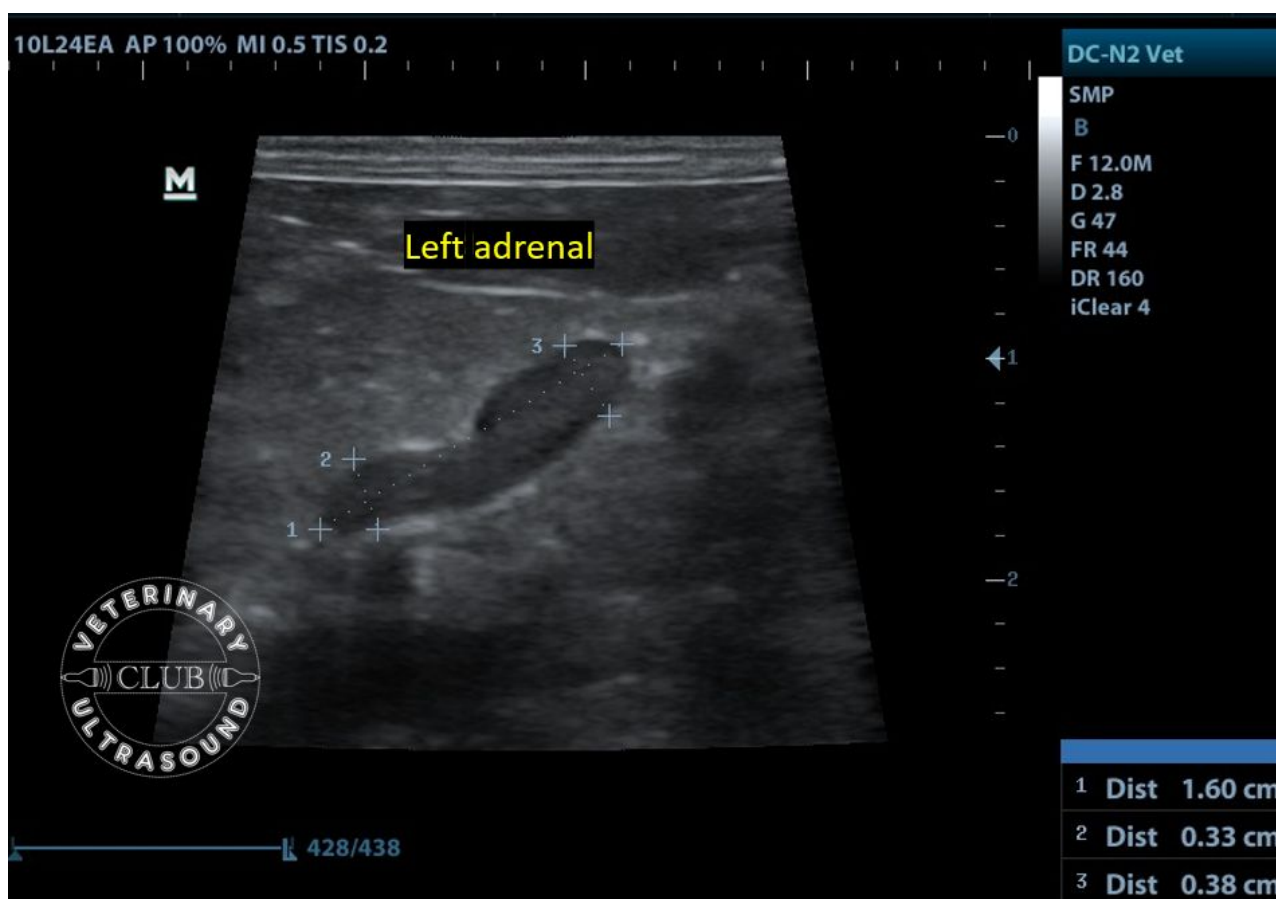


Figure 13. Ultrasound image of the left adrenal gland in a dog. Length (Distance 1; 1.60 cm) and height of the cranial (Distance 2; 0.33 cm) and caudal (Distance 3; 0.38 cm) poles were measured.

PANCREAS

AVERAGE THICKNESS OF PORTIONS OF THE PANCREAS, AND DIAMETER OF THE PANCREATIC DUCT IN CATS AND DOGS.				
SPECIES	LEFT LOBE	BODY	RIGHT LOBE	PANCREATIC DUCT
FELINE	0.54 cm (0.34 – 0.9)	0.66 cm (0.47 – 0.95)	0.45 cm (0.28 – 0.59)	0.1 cm (0.05 – 0.13)*
CANINE	0.65 cm (0.36 – 1.4)	0.63 cm (0.35 – 1.12)	0.81 cm (0.39 – 1.6)	Left lobe: 0.06 cm (0.04 – 0.1) Right lobe: 0.07 cm (0.01 a 0.12)
* Some studies consider the normal diameter of the pancreatic duct to can reach up to 0.25 cm in cats.				

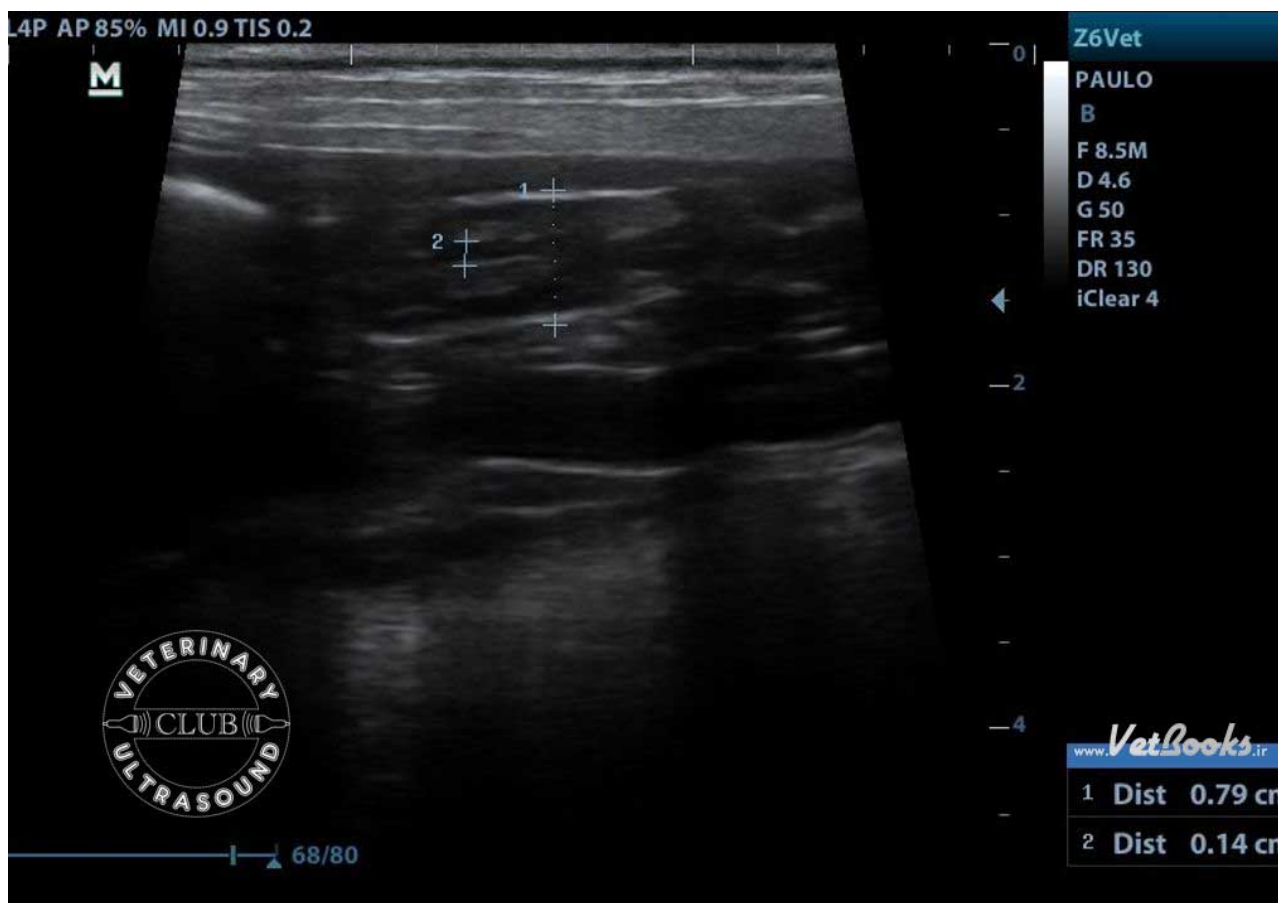


Figure 14. Ultrasound image of a feline pancreas. Distance 1 represents the thickness of the pancreas (0.79 cm), and Distance 2 (0.14 cm) indicates the pancreatic duct diameter.

Additional information on the pancreas

- The pancreatic duct is not always discernable in dogs; when visible, it is best seen on the right lobe. Pancreas thickness and duct diameter increases significantly with body weight.

MAJOR DUODENAL PAPILLA

NORMAL DIMENSIONS OF THE DUODENAL PAPILLA IN CATS AND DOGS	
SPECIES	DIMENSIONS
FELINE	Width: 0.29 to 0.55 cm Height: up to 0.4 cm
CANINE	Length: 1.52 ± 0.35 cm Width: 0.63 ± 0.16 cm Height: 0.43 ± 0.1 cm

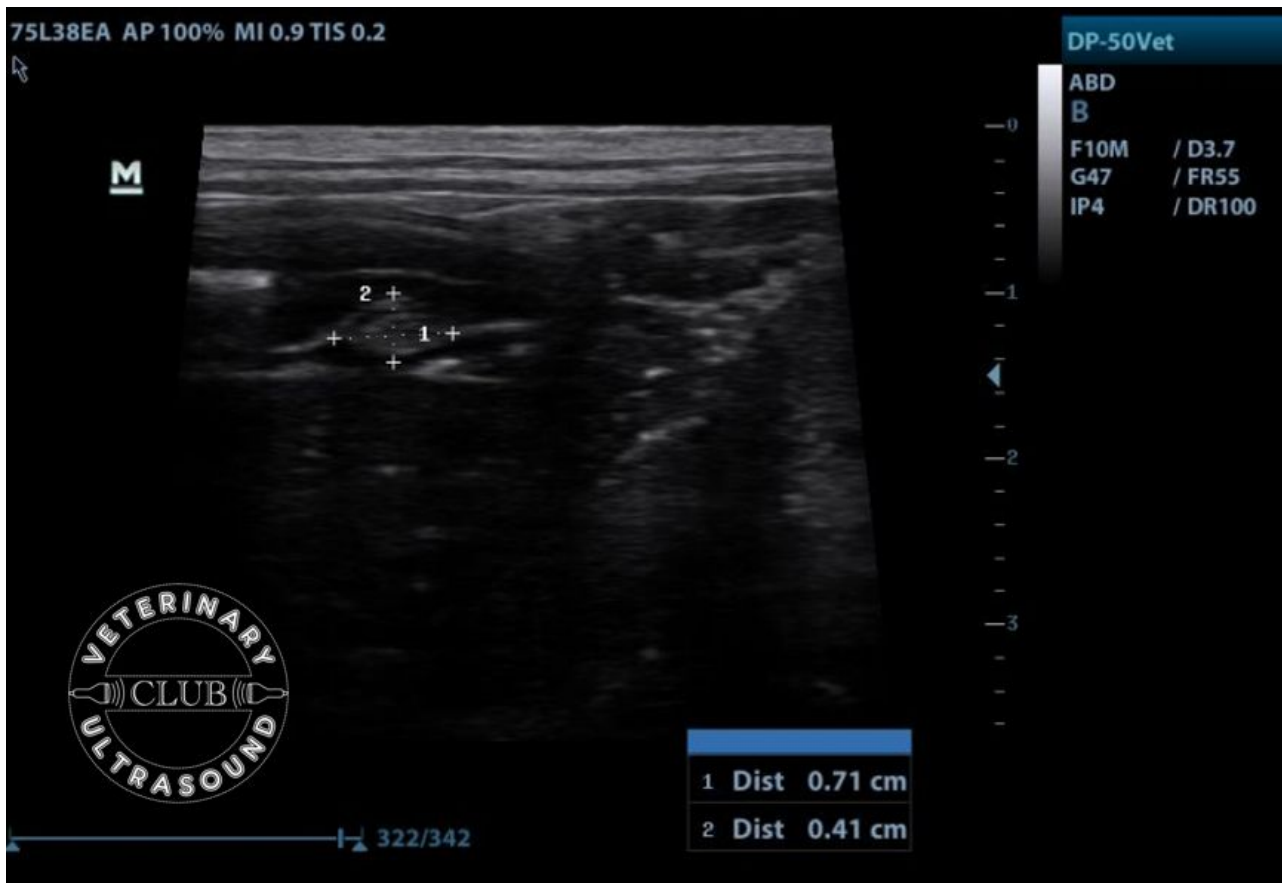


Figure 15. Ultrasound image of the duodenal papilla in a dog. Distance 2 (0.41 cm) corresponds to the height of the major duodenal papilla.

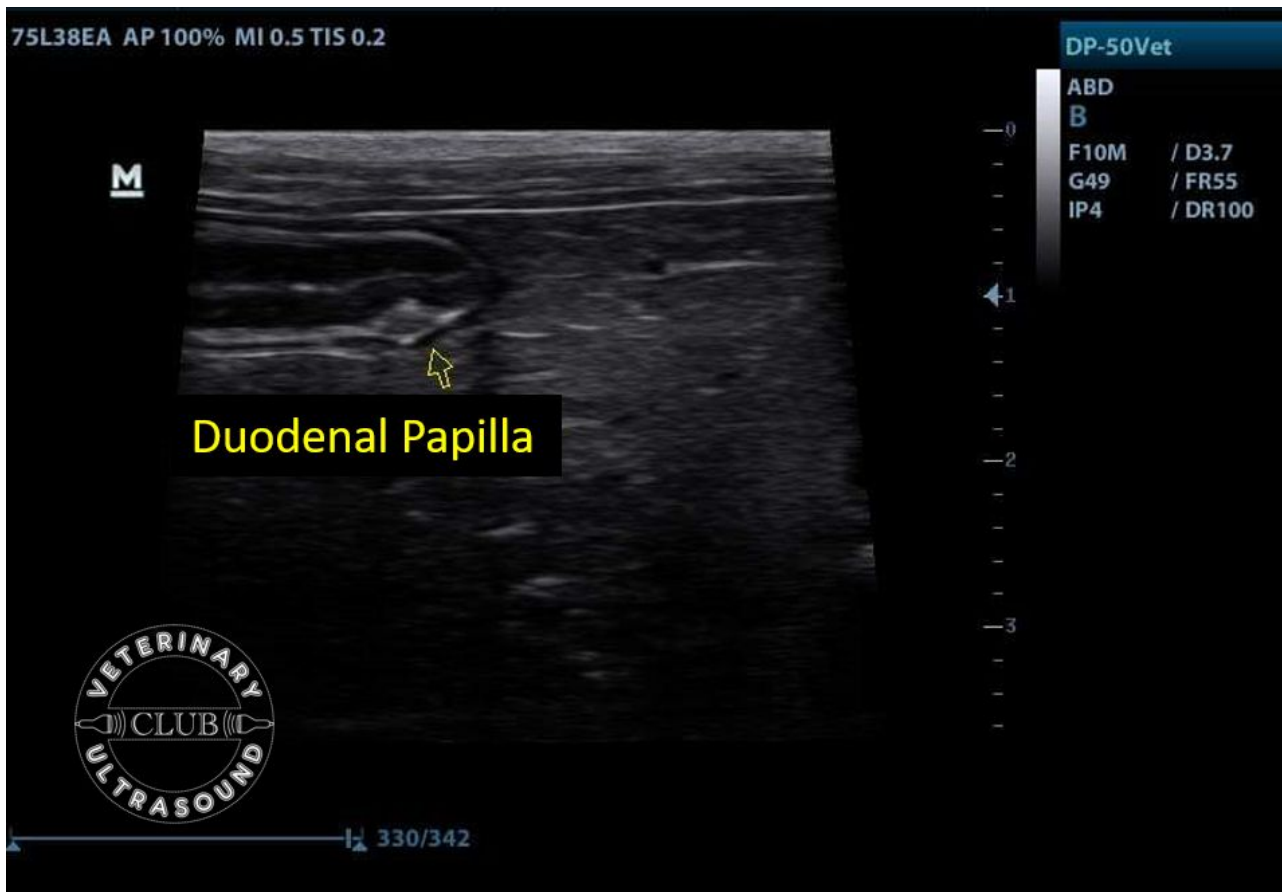


Figure 16. Ultrasound image of the duodenal papilla at the proximal portion of the descending duodenum.

LIVER

NORMAL DIMENSIONS OF THE LIVER IN CATS AND DOGS	
SPECIES	DIMENSION
FELINE	Subjective evaluation – caudal margins extend slightly beyond the ribs, with sharp margins.
CANINE	Subjective evaluation – most of the liver lies under the rib cage.

GALLBLADDER

NORMAL VALUES OF PARAMETERS OF THE GALLBLADDER IN CATS AND DOGS			
SPECIES	WALL	VOLUME*	COMMON BILE DUCT (<i>Ductus choledochus</i>)
FELINE	smooth and	2.42 mL	Less than or equal to 0.4 cm in

	hyperechoic; less than 0.1 cm in thickness		diameter
CANINE	0.1 to 0.2 cm	Less or equal to 1 mL/kg	Less than 0.3 cm in diameter (usually not visible)
* The volume is calculated using the ellipsoid formula (0.52 x length x height x width)			

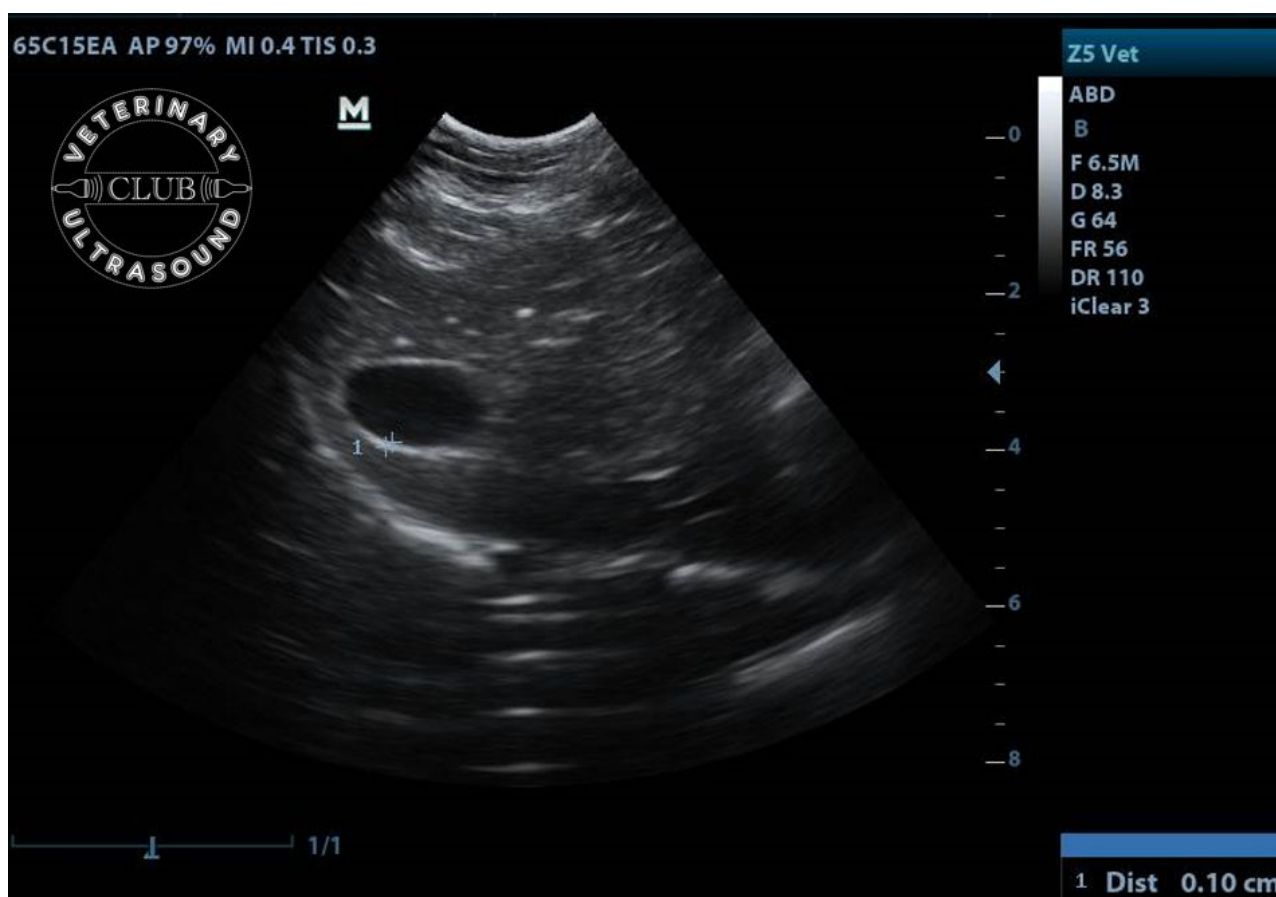


Figure 17. Ultrasound image of the liver and gallbladder in a dog. The calipers were placed on the external and internal surfaces of the gallbladder wall to measure wall thickness.

Additional information on the gallbladder

- Gallbladder dilation is not a good indicator of obstruction in cats, since there is absence of dilation in 50% of cats with biliary obstruction.
- Gallbladder volume in fasting cats varies from 0.84 to 4.5 ml (average = 2.42 ml). Two hours after food ingestion, the volume decreases from 2.4 to 0.9 ml.
- Under normal circumstances, intrahepatic ducts are not ultrasonographically visible.

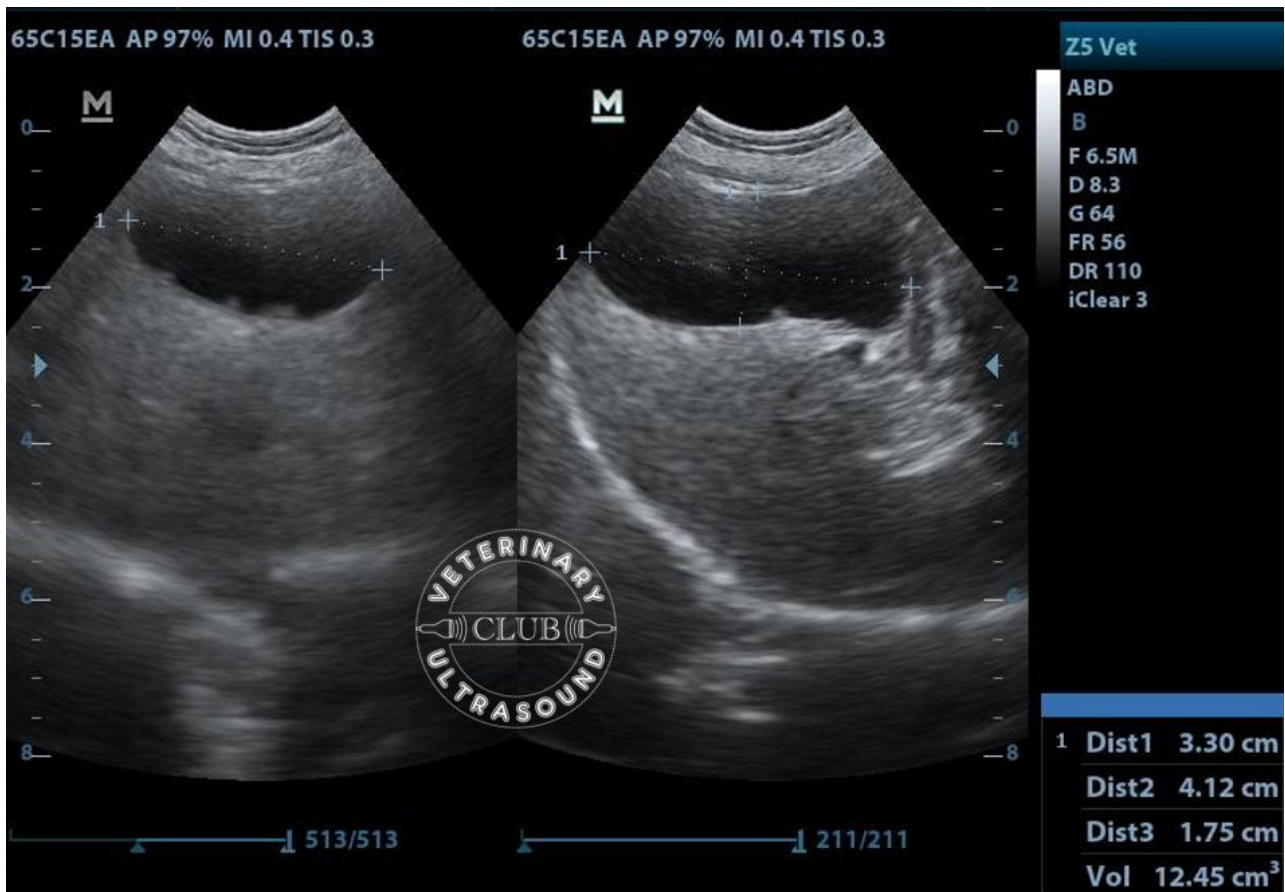


Figure 18. Ultrasound image of the gallbladder in a dog. To calculate gallbladder volume using the ellipsoid formula, measurements of width (transversal plane), height, and length (longitudinal plane) were made.

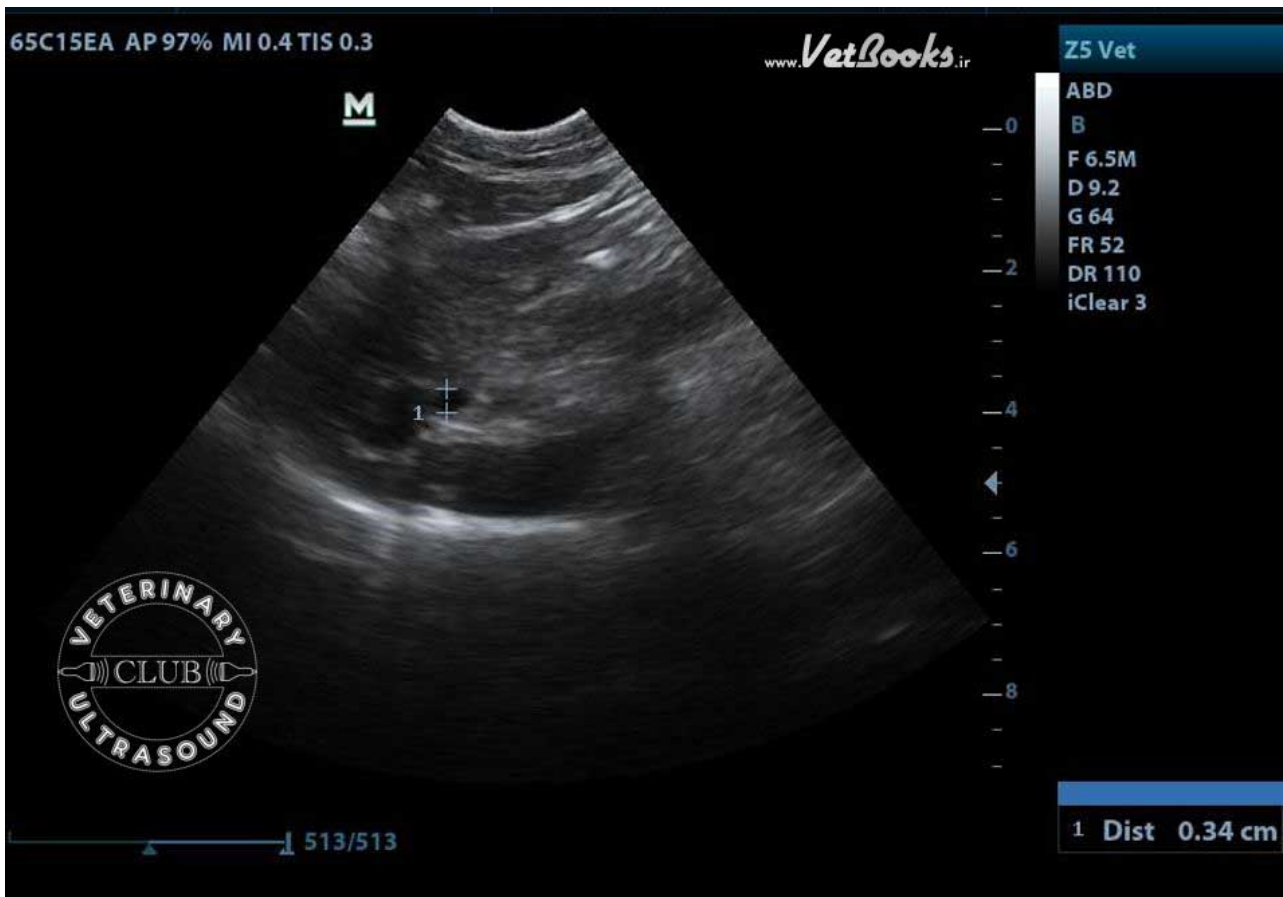


Figure 19. Ultrasound image of the common bile duct (ductus choledochus) in a cat. In this patient, the common bile duct was easily seen and had a tortuous path. The anatomical position of this structure is dorsal do the duodenum and ventral to the portal vein.

AORTA, PORTAL VEIN E CAUDAL VENA CAVA

The table below shows normal diameters of the abdominal aorta, portal vein, and caudal vena cava as defined in two studies. In one of these works, dogs were grouped according to body weight.

NORMAL DIAMETERS OF THE ABDOMINAL AORTA, PORTAL VEIN, AND CAUDAL VENA CAVA IN DOGS AND CATS						
SPECIES	BW (kg)	ABDOMINAL AORTA	PORTAL VEIN	CAUDAL VENA CAVA	PV/Ao RATIO	PV/CVC RATIO
FELINE		0.45 cm	0.44 cm (0.34-0.55)	0.46 cm	0.93 (0.78-1.25)	0.95 (0.77-1.25)
CANINE		0.55 cm	0.49 cm (0.33-1.05)	0.52 cm	0.89 (0.71-	0.90 (0.71-1.33)

					1.02)	
	< 10	0.61 ± 0.11 cm	0.65 ± 0.11 cm	0.65 ± 0.12 cm	1.07 ± 0.09	1.01 ± 0.08
CANINE	10.1-20	0.9 ± 0.07 cm	0.9 ± 0.08 cm	0.98 ± 0.12 cm	1.01 ± 0.08	0.93 ± 0.18
	> 20.1	0.95 ± 0.07 cm	0.97 ± 0.12 cm	1.04 ± 0.08 cm	1.02 ± 0.09	0.93 ± 0.11
BW, body weight; PV, portal vein; Ao, aorta; CVC, caudal vena cava						

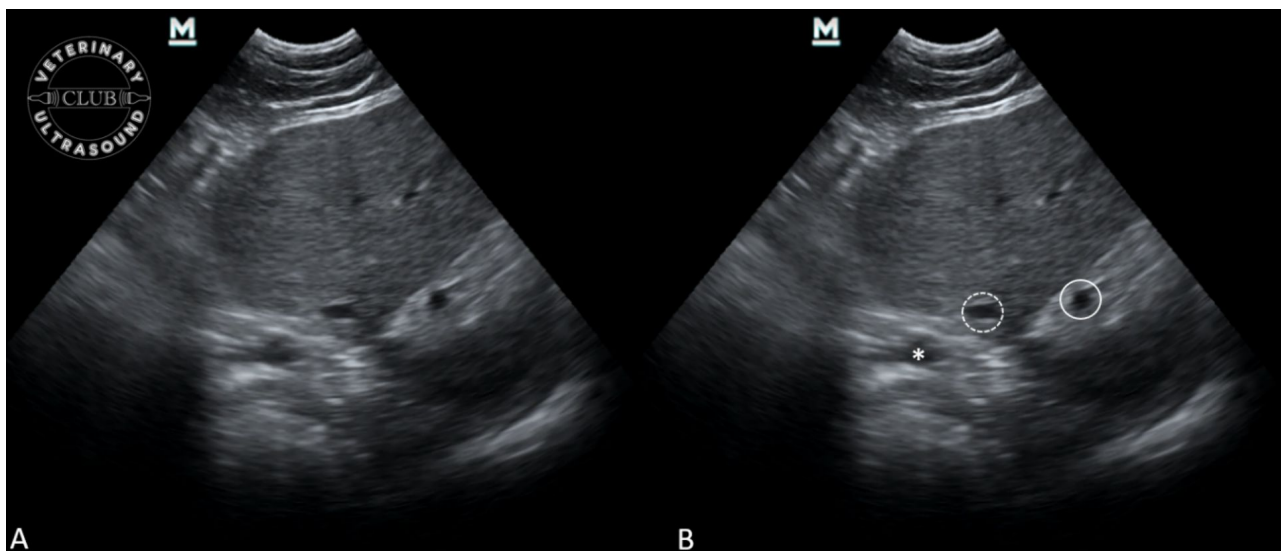


Figure 20. (A) Ultrasound image using the right lateral intercostal approach. In (B), the aorta (asterisk), caudal vena cava (circle with a dashed line), and portal vein (circle with a solid line) are indicated.

Additional information on measurements of the aorta, portal vein, and caudal vena cava

- The portal vein should be measured on the *porta hepatis*, at the entrance of the liver.
- Care should be taken to avoid compressing the caudal vena cava when acquiring the image for measurement.
- In cases of suspicion of portosystemic shunts, the portal vein to aorta (PV/Ao) and portal vein to caudal vena cava (PV/CVC) ratios may prove useful to exclude this hypothesis. In a well-known study on this subject, all cats and dogs with a PV/Ao ratio less or equal to 0.65 exhibited extrahepatic portosystemic shunt or non-cirrhotic idiopathic portal hypertension. Cats and dogs with a PV/Ao ratio greater than or equal to 0.8 and a PV/CVC greater than or equal to 0.75 have been found not to have extrahepatic portosystemic shunts.
- In addition to the values mentioned above, a study has reported normal aorta/caudal vena cava (Ao/CVC) ratios in measurements performed cranial to the bifurcation of the external iliac arteries. In that study, the average diameter ± standard deviation of the aorta was 0.783 ± 0.242 cm, and the average diameter of the caudal vena cava was 0.769 ± 0.251 cm; the average Ao/CVC ratio was 1.0276 ± 0.0663 in dogs with no arterial pressure problems.

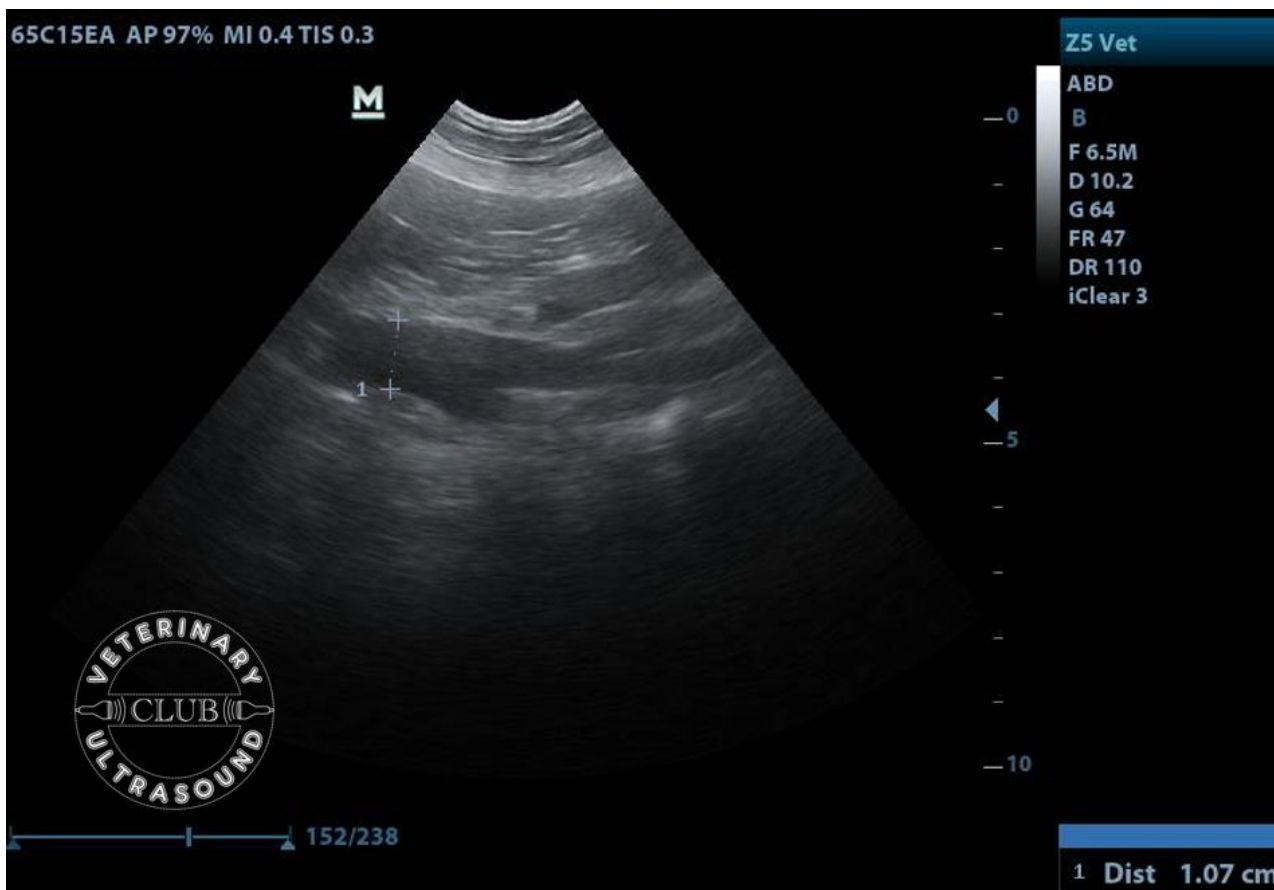


Figure 21. Ultrasound image of the abdominal aorta showing the measurement being made immediately cranial to the bifurcation of the external iliac arteries.

- In another study, the aorta was measured at three points of the abdomen of normal dogs, and exhibited mean diameters of 0.8 cm when measured caudal to the diaphragm, 0.74 cm when measured caudal do renal arteries, and 0.74 cm when measured cranial to iliac arteries bifurcation.

UTERUS

INFORMATION ON THE UTERUS OF QUEENS AND BITCHES		
SPECIES	CHARACTERISTICS OF THE UTERUS	POSTPARTUM INVOLUTION
FELINE	The macroscopic size of the uterus in cats does not show difference in anestrus, estrus and 2 months postpartum (means = 0.39 cm, 0.56 cm, 0.46 cm, respectively)	24 days*
CANINE	End of diestrus, and anestrus: 0.3 to 0.8 cm; difficult to detect.	3 to 4 weeks**
	Proestrus, estrus, metestrus, and beginning of diestrus: easy to detect; 0.1 to 0.3 cm larger than in anestrus, with	First week postpartum: 1.5 to 2 cm
		Between the sixth

	0.1 cm of hyperechoic luminal content; cervix focally thickened.	and seventh weeks postpartum: 0.8 to 1.5 cm
* See additional information on the uterus, provided below. **Average value. See additional information below.		

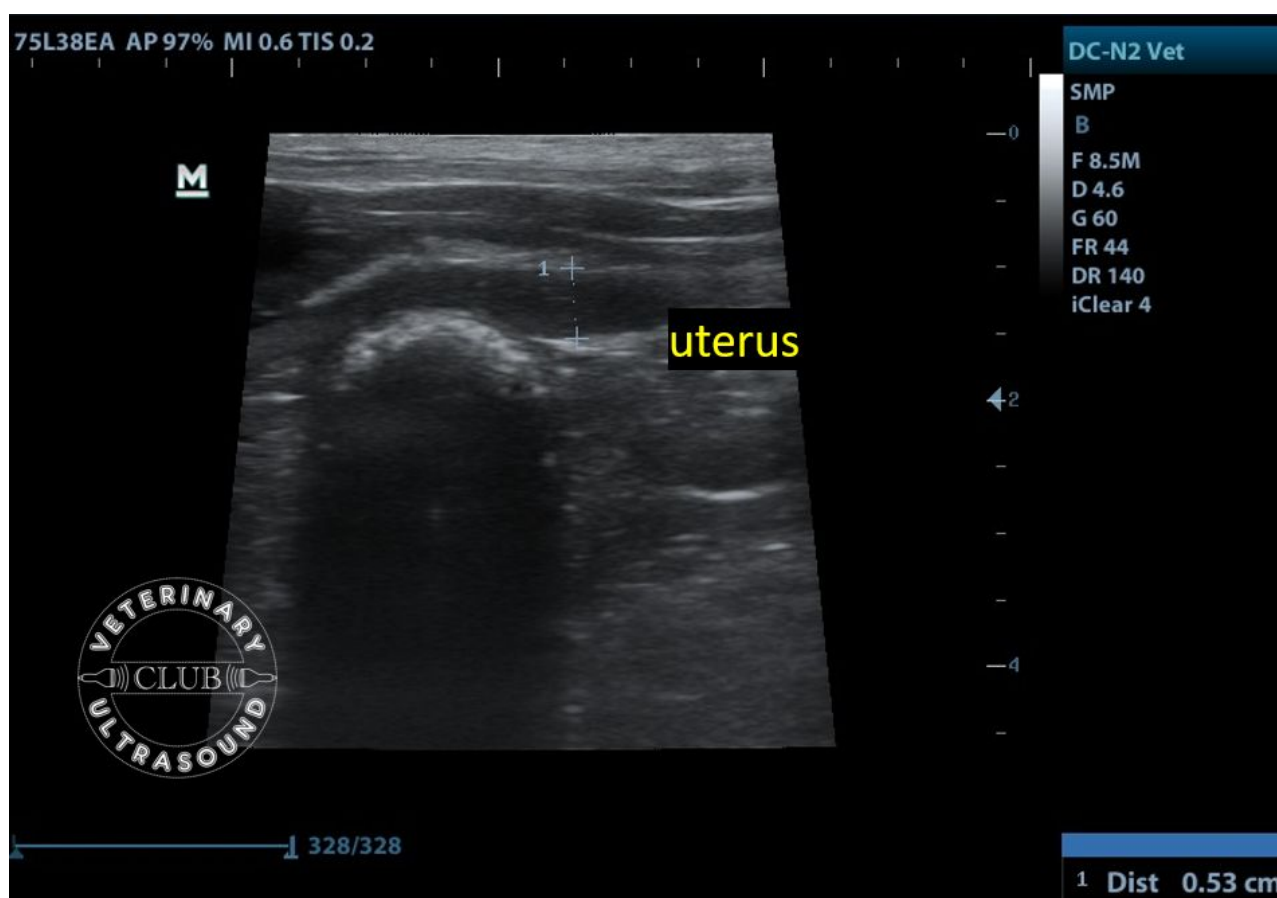


Figure 22. Ultrasound image of the body of the uterus of a bitch. The normal anatomical location of the uterus is ventral to the colon and dorsal to the urinary bladder.

Additional information on the uterus of bitches

- The uterus has 3 layers: mucosa, muscularis, serosa.
- During the ANESTRUS, there are no alterations on the wall or in the fluid of the lumen.
- In the PROESTRUS and in the ESTRUS, the wall becomes thicker (owing to the effects of estrogen), and the amount of liquid in the lumen is small.
- The DIESTRUS is the moment of the estrous cycle at which the wall exhibits the greatest thickness due to the development of endometrial glands (owing to the effects of progesterone).

Postpartum involution

- In the postpartum period, the myometrium becomes evident with three distinct layers (besides the serosa and endometrium).

- Works in which uterine involution was studied using histological analysis have shown that involution can take from 12 to 15 weeks. An ultrasound study in Beagles has shown that, in the first postpartum week, the average diameter of the uterus is 1.1 to 3.8 cm on placental sites, and 0.5 to 1.4 cm between placental sites. After complete involution, 15 weeks postpartum, the uterus measured 0.3 to 0.6 cm in diameter.
- A study in cats found that, in the first 24 hours postpartum, the average size \pm standard deviation of the placental sites was 3.12 ± 0.29 cm, while the average size of the interplacental sites was 2.33 ± 0.43 cm. On the second postpartum day, defining these regions was already difficult. Between 4 and 7 days postpartum, the uterine diameter was 0.49 ± 0.07 cm.

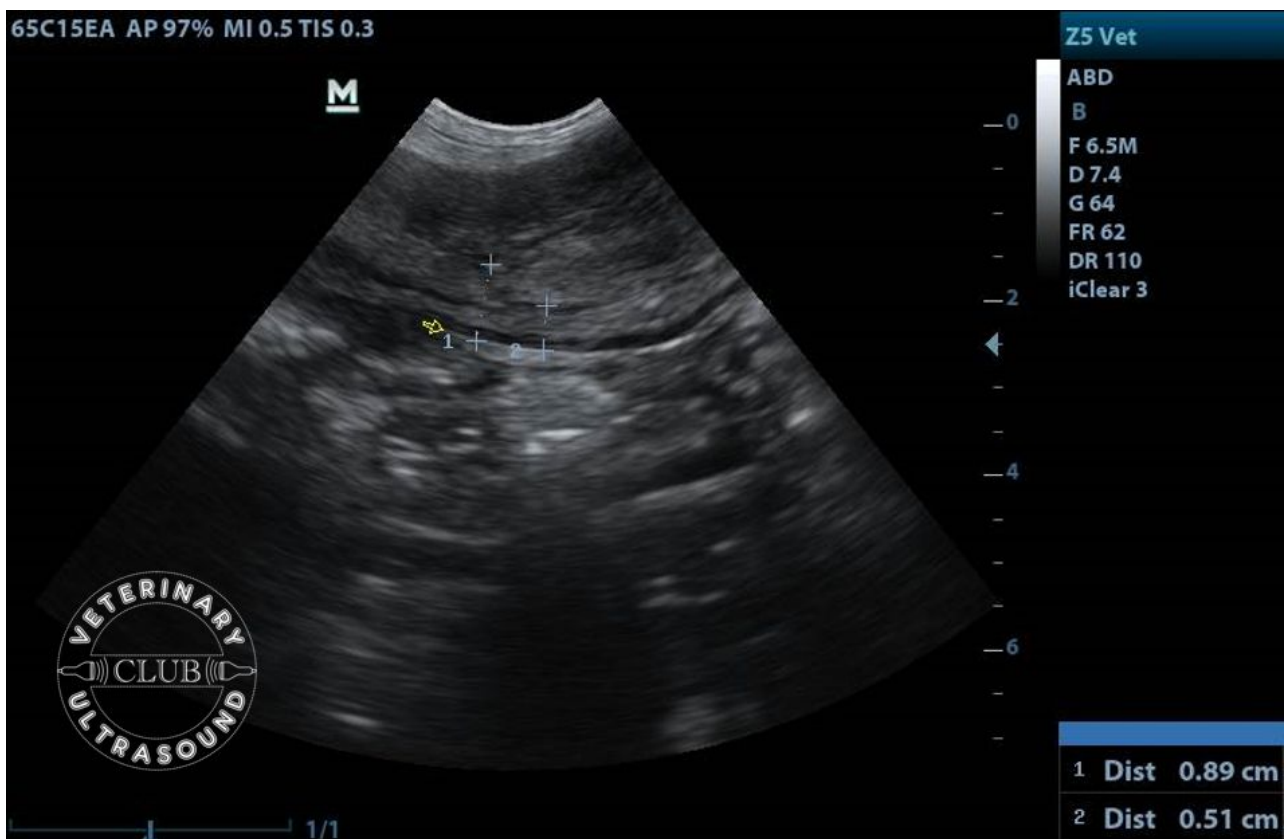


Figure 23. Ultrasound image of the postpartum uterus in a dog. The arrow shows the serosa (external hyperechoic line). Distance 1 (0.89 cm) corresponds to the total thickness of the wall, which comprehends serosa, muscularis (myometrium), and mucosa (endometrium). Distance 2 (0.51 cm) indicates the thickness of the muscularis (myometrium), which has 3 distinct visible layers (hypoechoic, hyperechoic, and hypoechoic).

OVARIES

NORMAL DIMENSIONS OF THE OVARIES IN QUEENS AND BITCHES

SPECIES	OVARY SIZE
FELINE	Less than 1 cm
CANINE	Between 1 and 2 cm

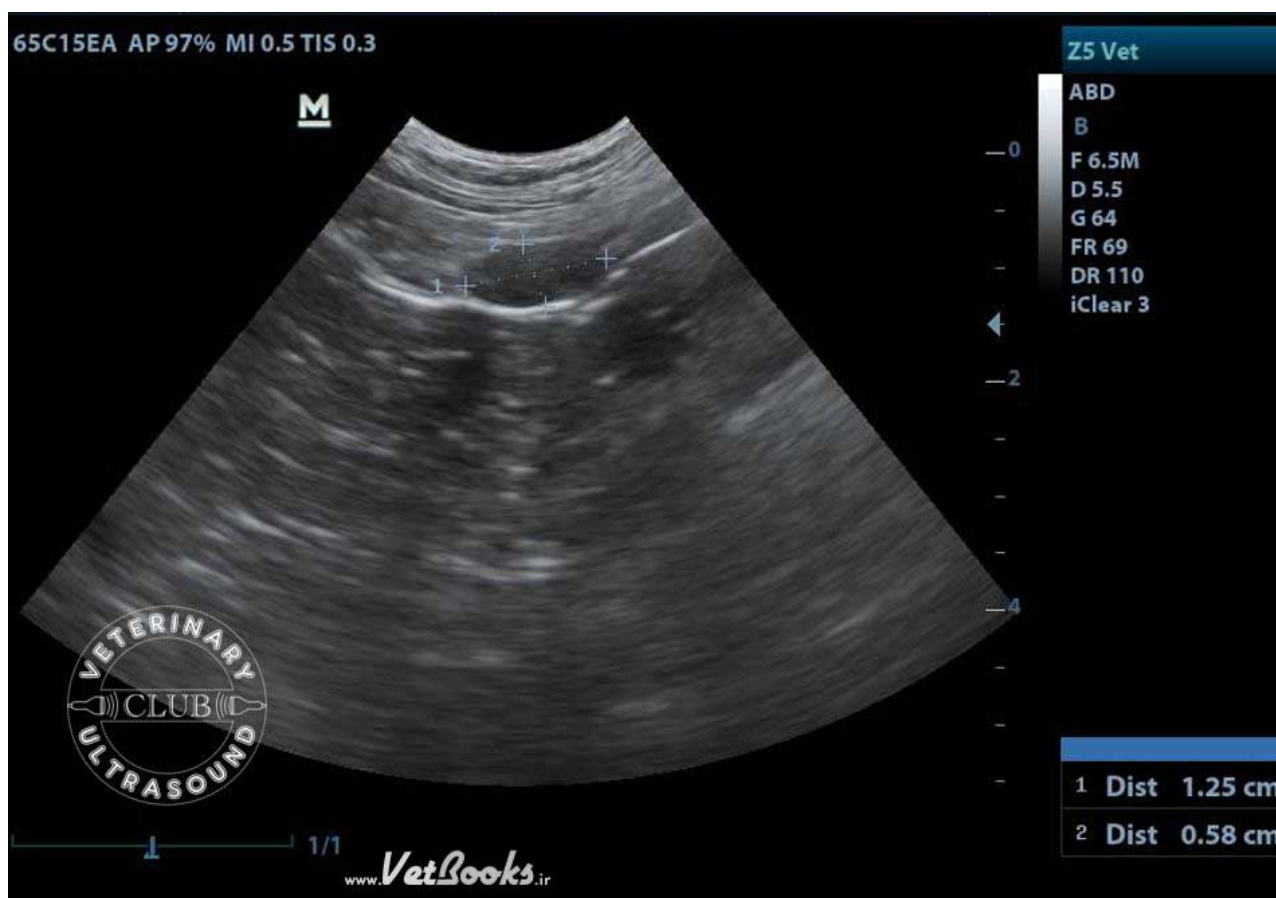


Figure 24. Ultrasound image of the ovary of a bitch. Distance 1 (1.25 cm) represents the length, and Distance 2 indicates the height (0.58 cm).

Additional information on the ovaries of **bitches**

- In the ANESTRUS and in the beginning of PROESTRUS, the ovaries are small, oval, and homogeneous.
- In the PROESTRUS, the ovaries increase and become spherical; at this phase, follicles (up to 10 per ovary) are present. These follicles are anechoic and may be up to 1.1 cm in length.
- During OVULATION, the number of follicles decreases to zero to two follicles per ovary, while the remaining ones reduce in size.
- In the ESTRUS, the ovaries reach their highest size, becoming 300 to 400% larger than in the anestrus. At this phase of the estrous cycle, the corpus luteum is ultrasonographically visible. There may be around three corpora lutea ranging from 0.5 to 0.9 cm in size.

- In the DIESTRUS, the ovaries exhibit an irregular contour. The size of the ovaries decreases, and the echogenicity of the corpus luteum increases.

PROSTATE

The table below contains normal dimensions of the prostate of cats, and average sizes (and corresponding normal ranges) for dogs. For more dimensions according to age and body weight in dogs, see the last table of this section.

NORMAL DIMENSIONS OF THE PROSTATE IN CATS AND DOGS				
SPECIES		LENGTH	HEIGHT	WIDTH
FELINE		1	0.45 to 0.5 cm in diameter	
CANINE	Intact	2.7 (1.6 a 3.9)	2.4 (0.8 a 3.2)	2.7 (1.2 a 3.6)
	Neutered	2.4 (2 a 5.5)	1.5 (1 a 3.5)	1.7 (1.2 a 4.2)

Values are displayed in centimeters as averages, with normal ranges in parentheses.

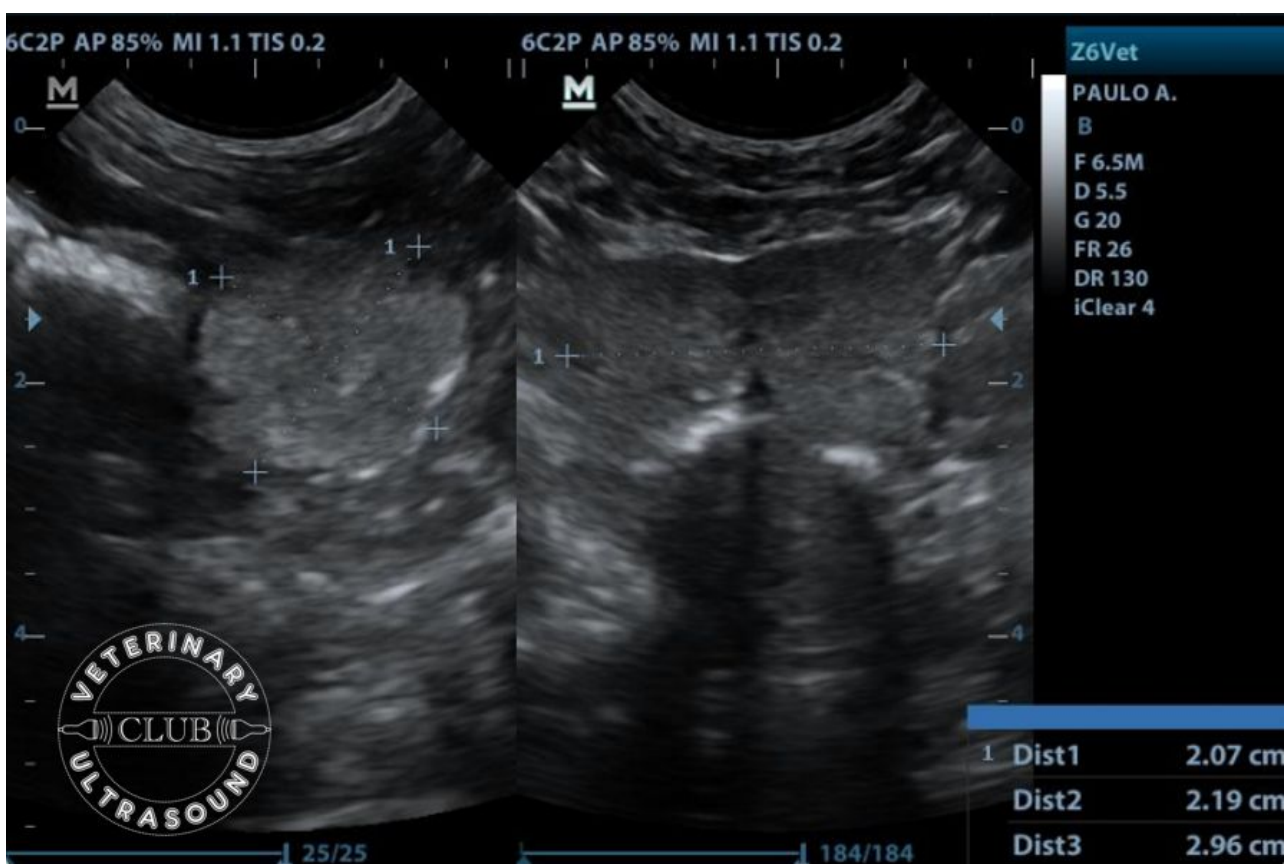


Figure 25. Ultrasound images of the prostate of a dog. The image on the left contains measurements of length and height. The distance between calipers on the image on the right is the width. These values are used to calculate volume using the ellipsoid formula.

Additional information on the prostate

- In cats, the body of the prostate is dorsolateral to the urethra, and is difficult to detect unless it exhibits alterations. Besides the prostate, cats also have two bulbourethral glands lateral to the urethra. These are not evaluated during ultrasound examination.
- The prostate in neutered dogs is homogeneous, round or oval. Intact dogs have a bilobed prostate. The lobes are evaluated in transversal plane, and should be symmetrical. Size and volume of the prostate increase with body weight and age in intact dogs; however, this correlation does not apply to neutered dogs.
- The volume of the prostate can be calculated using various formulas; of these, the most commonly used is the ellipsoid formula, according to which **volume (mL) = 0.52 x length (cm) x height (cm) x width (cm)** .
- The following formulas have been presented by an important study on the prostate; they incorporate age (years) and body weight (kg) to predict prostatic dimensions and volume in **dogs** :

Length = (0.055 x weight) + (0.143 x age) + 3.31
Width = (0.047 x weight) + (0.089 x age) + 3.45
Height on sagittal plane = (0.046 x weight) + (0.069 x age) + 2.68
Height on transversal plane = (0.044 x weight) + (0.083 x age) + 2.25
Volume = (0.867 x weight) + (1.885 x age) + 15.88

Using these formulas, the reference values shown on the table below are obtained.

NORMAL PROSTATE DIMENSIONS (cm) ACCORDING TO AGE AND WEIGHT IN DOGS											
AGE (years)		WEIGHT (kg)									
		5	10	15	20	25	30	35	40	45	50
2	Length	3.87	4.15	4.42	4.7	4.97	5.25	5.52	5.8	6.07	6.35
	Width	3.86	4.1	4.33	4.57	4.8	5.04	5.27	5.51	5.74	5.98
	Transversal height	2.69	2.86	3.08	3.3	3.52	3.74	3.96	4.18	4.4	4.62
	Sagittal height	3.05	3.28	3.51	3.74	3.97	4.2	4.43	4.66	4.89	5.12
	Volume	23.99	28.32	32.66	36.99	41.33	45.66	50	54.33	58.67	63
4	Length	4.16	4.43	4.71	4.98	5.26	5.53	5.81	6.08	6.36	6.63
	Width	4.04	4.28	4.51	4.75	4.98	5.22	5.45	5.69	5.92	6.16
	Transversal height	2.8	3.02	3.24	3.46	3.68	3.9	4.12	4.34	4.56	4.78
	Sagittal	3.19	3.42	3.65	3.88	4.11	4.34	4.57	4.8	5.03	5.26

	height										
	Volume	27.76	32.09	36.43	40.76	45.1	49.43	53.77	58.1	62.44	66.77
5	Length	4.3	4.58	4.85	5.13	5.4	5.68	5.95	6.23	6.5	6.78
	Width	4.13	4.37	4.6	4.84	5.07	5.31	5.54	5.78	6.01	6.25
	Transversal height	2.89	3.11	3.33	3.55	3.77	3.99	4.21	4.43	4.65	4.87
	Sagittal height	5.26	3.49	3.72	3.95	4.18	4.41	4.64	4.87	5.1	5.33
	Volume	29.64	33.98	38.31	42.65	46.98	51.32	55.65	59.99	64.32	68.66
6	Length	4.44	4.72	4.99	5.27	5.54	5.82	6.09	6.37	6.64	6.92
	Width	4.22	4.45	4.69	4.92	5.16	5.39	5.63	5.86	6.1	6.33
	Transversal height	2.97	3.19	3.41	3.63	3.85	4.07	4.29	4.51	4.73	4.95
	Sagittal height	3.32	3.55	3.78	4.01	4.24	4.47	4.7	4.93	5.16	5.39
	Volume	31.53	35.86	40.2	44.53	48.87	53.2	57.54	61.87	66.21	70.54
8	Length	4.73	5	5.28	5.55	5.83	6.1	6.38	6.65	6.93	7.2
	Width	4.4	4.63	4.87	5.1	5.34	5.57	5.81	6.04	6.28	6.51
	Transversal height	3.13	3.35	3.57	3.79	4.01	4.23	4.45	4.67	4.89	5.11
	Sagittal height	3.46	3.69	3.92	4.15	4.38	4.61	4.84	5.07	5.3	5.53
	Volume	35.3	39.63	43.97	48.3	52.64	56.97	61.31	65.64	69.98	74.31
10	Length	5.02	5.29	5.57	5.84	6.12	6.39	6.67	6.94	7.22	7.49
	Width	4.58	4.81	5.05	5.28	5.52	5.75	5.99	6.22	6.46	6.69
	Transversal height	3.3	3.52	3.74	3.96	4.18	4.4	4.62	4.84	5.06	5.28
	Sagittal height	3.6	3.83	4.06	4.29	4.52	4.75	4.98	5.21	5.44	5.67
	Volume	39.07	43.4	47.74	52.07	56.41	60.74	65.08	69.41	73.75	78.08
12	Length	5.3	5.58	5.85	6.13	6.4	6.68	6.95	7.23	7.5	7.78
	Width	4.75	4.99	5.22	5.46	5.69	5.93	6.16	6.4	6.63	6.87
	Transversal height	3.47	3.69	3.91	4.13	4.35	4.57	4.79	5.01	5.23	5.45
	Sagittal height	3.74	3.97	4.2	4.43	4.66	4.89	5.12	5.35	5.58	5.81
	Volume	42.84	47.17	51.51	55.84	60.18	64.51	68.85	73.18	77.52	81.85

TESTICLES

NORMAL DIMENSIONS OF THE TESTICLES IN

CATS AND DOGS					
SPECIES	WEIGHT (kg)	LENGTH	WIDTH	HEIGHT	MEDIASTINAL WIDTH
FELINE	Check for symmetry				
CANINE	1-10	1.5-3.3 cm	1-2.2 cm	0.8-1.6 cm	0.1-0.2 cm
	11-20	2-3.9 cm	1.4-3.2 cm	1.3-2.2 cm	0.1-0.2 cm
	21-30	3-4 cm	1.5-3.6 cm	1.5-2.4 cm	0.1-0.3 cm
	31-40	2.6 a >4 cm	1.7-3.7 cm	1.6-3.2 cm	0.1-0.3 cm
	>40	3.4 a >4 cm	2.6-3.8 cm	1.6-3 cm	0.1-0.3 cm

In dogs, the thickness of the epididymis is 0.4 to 0.8 cm at the head of the epididymis, which is on the cranial aspect of the testicle; 0.2 to 0.7 cm at the body, which runs through the dorsolateral aspect of the testicle; and 0.6 to 1.3 cm at the tail, which is located on the caudal pole of the testicle.

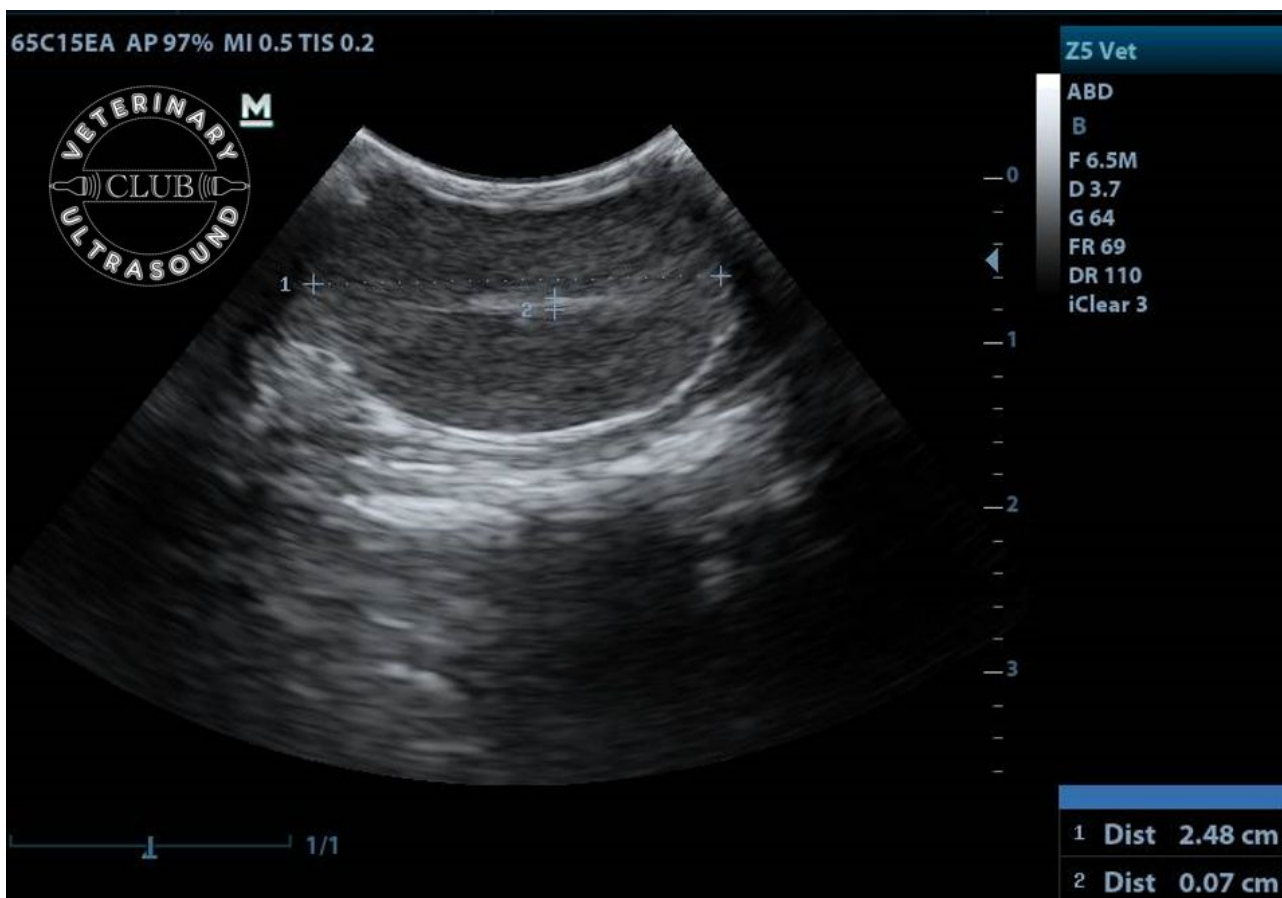


Figure 26. Ultrasound image of the testicle of a dog. The measurements shown are testicular length (Distance 1; 2.48 cm) and width of the mediastinal line (Distance 2; 0.07 cm).

STOMACH AND INTESTINES

The table below contains a summary of thickness in centimeters of different segments of the gastrointestinal tract in cats and dogs. For more details, see the second table of this section.

NORMAL THICKNESS OF VARIOUS PORTIONS OF THE GASTROINTESTINAL TRACT IN CATS AND DOGS						
SPECIES	WEIGHT	STOMACH	DUODENUM	JEJUNUM	ILEUM	CECUM/COLON
FELINE	all	0.2 to 0.4 cm	0.22 cm	0.22 cm	0.28 cm	0.15 cm
CANINE	<15 kg	0.2 to 0.5 cm	0.38 cm	0.30 cm	0.30 cm	0.15 cm
	15-30 kg		0.41 cm	0.35 cm	0.35 cm	
	>30 kg		0.44 cm	0.38 cm	0.38 cm	

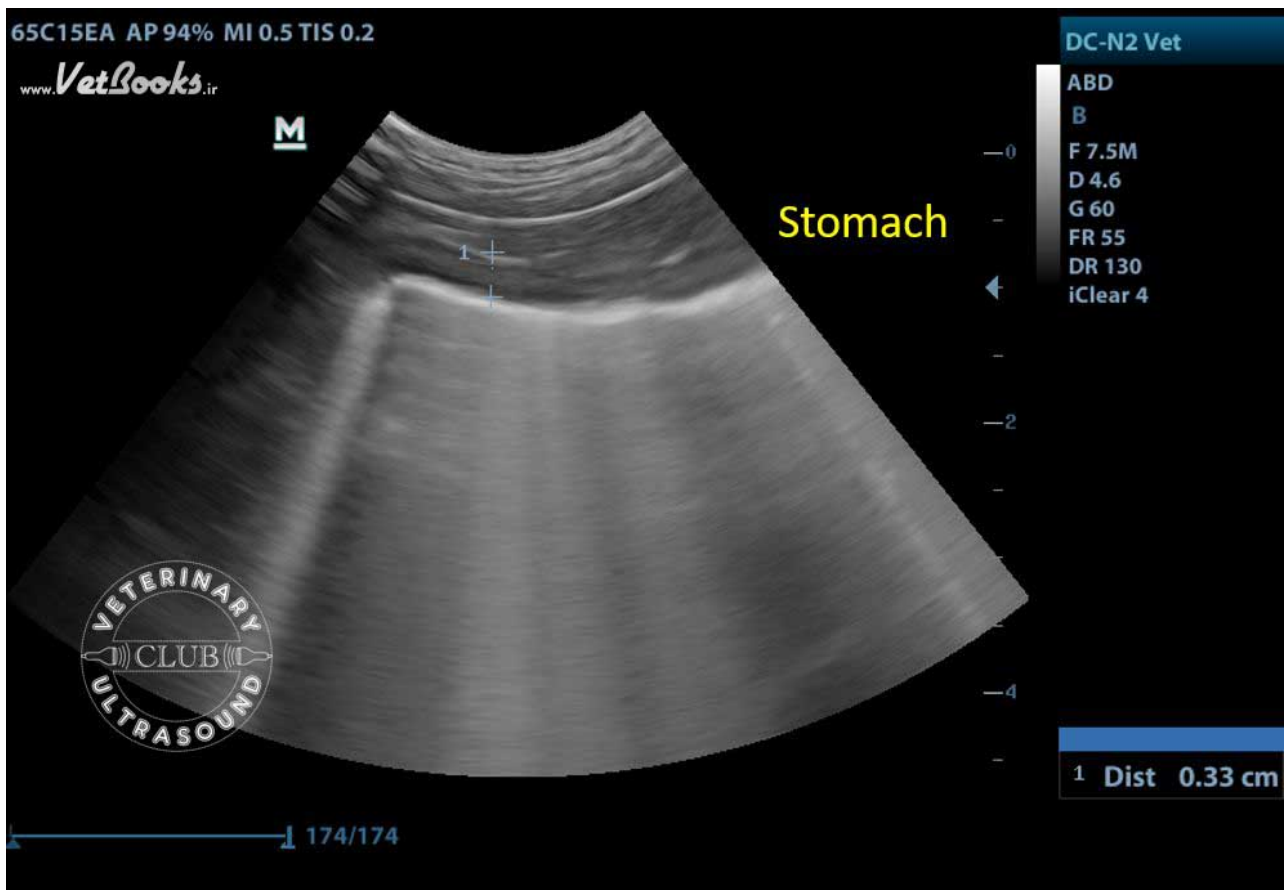


Figure 27. Ultrasound image of the stomach of a dog. The lumen is filled with gas, which caused a reverberation artifact. The distance between calipers corresponds to the thickness of the wall (0.33 cm).

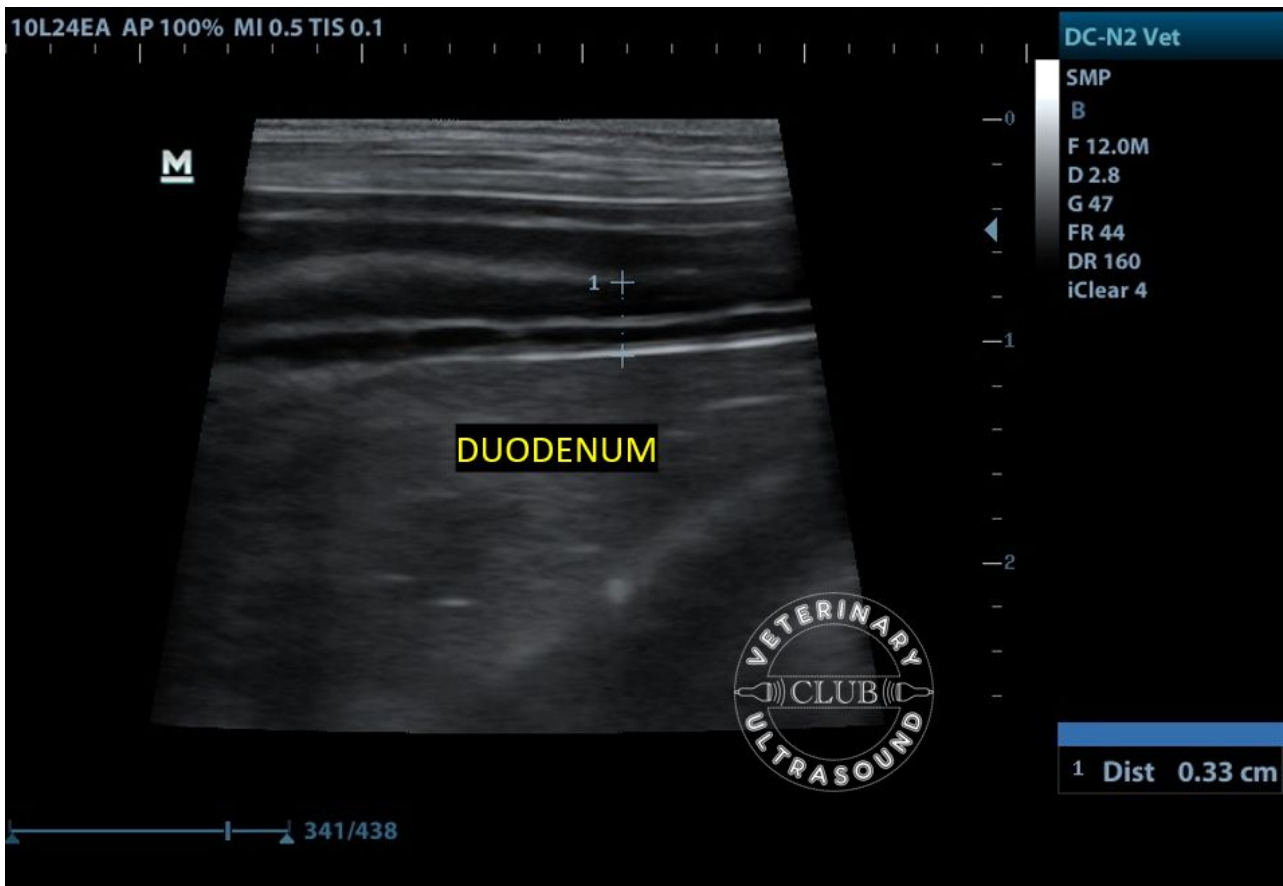


Figure 28. Ultrasound image of the duodenum in a dog. The calipers were positioned on the outermost layer (serosa) and on the innermost portion of the mucosa (mucosal/lumen interface), revealing a wall thickness of 0.33 cm.

Additional information on the intestines

- Intestinal layers can be measured separately to check for thickening of individual layers. The table below shows a summary of averages and ranges (in centimeters) of the thickness of different portions of the intestine as determined in dogs according to body weight.

NORMAL WALL THICKNESS OF LAYERS OF PORTIONS THE INTESTINE OF DOGS				
		< 15 kg	15-30 kg	> 30 kg
DUODENUM	MUCOSA	0.24 (0.16-0.35)	0.26 (0.15-0.37)	0.28 (0.2-0.39)
	SUBMUCOSA	0.06 (0.03-0.08)	0.06 (0.03-0.1)	0.06 (0.03-0.12)
	MUSCULAR	0.05 (0.02-0.08)	0.05 (0.03-0.08)	0.6 (0.02-0.09)
	SEROSA	0.04 (0.02-0.06)	0.04 (0.03-0.06)	0.04 (0.02-0.07)
	TOTAL	0.38 (0.29-0.47)	0.41 (0.3-0.55)	0.44 (0.31-0.57)

JEJUNUM	MUCOSA	0.18 (0.12-0.26)	0.2 (0.15-0.32)	0.22 (0.11-0.32)
	SUBMUCOSA	0.05 (0.03-0.09)	0.06 (0.03-0.1)	0.06 (0.03-0.08)
	MUSCULAR	0.05 (0.02-0.07)	0.05 (0.03-0.08)	0.05 (0.03-0.09)
	SEROSA	0.04 (0.02-0.06)	0.04 (0.03-0.06)	0.04 (0.03-0.06)
	TOTAL	0.3 (0.22-0.41)	0.35 (0.24-0.48)	0.38 (0.27-0.47)
COLON	MUCOSA	0.04 (0.02-0.06)	0.04 (0.02-0.05)	0.05 (0.03-0.07)
	SUBMUCOSA	0.04 (0.02-0.06)	0.03 (0.02-0.04)	0.04 (0.02-0.05)
	MUSCULAR	0.04 (0.02-0.07)	0.03 (0.02-0.05)	0.04 (0.02-0.07)
	SEROSA	0.04 (0.02-0.05)	0.04 (0.02-0.05)	0.04 (0.02-0.05)
	TOTAL	0.15 (0.01-0.02)	0.14 (0.11-0.19)	0.16 (0.11-0.26)
Values are displayed in centimeters as averages, with normal ranges in parentheses.				

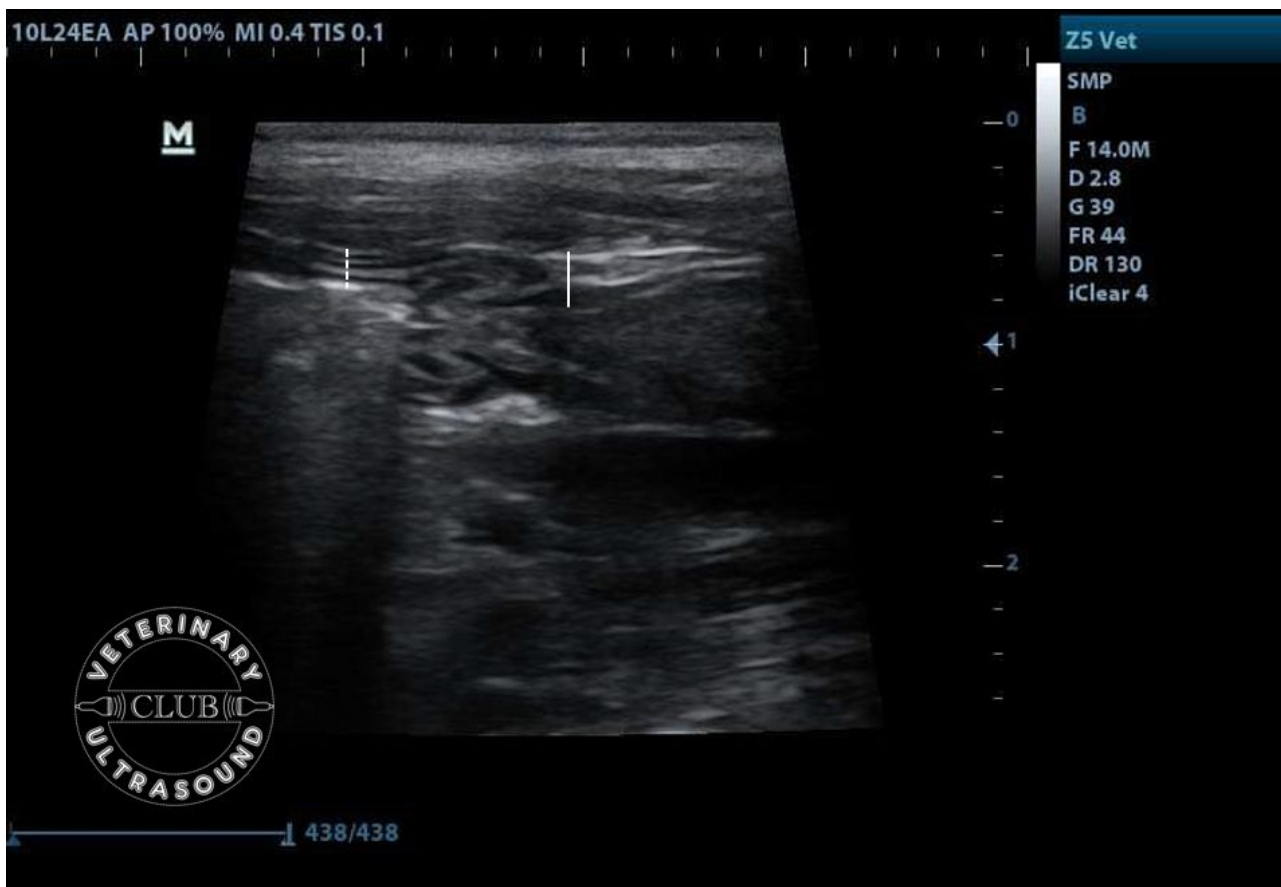


Figure 29. Ultrasound image of the ileocolic junction in a dog. The colonic and ileal walls are marked with dashed and solid lines, respectively.

In cats, two studies are well-known for the evaluation of individual layers of the intestinal wall. Values from both studies were compiled into two separate tables for detailed consultation.

The table below shows median values (centimeters) of thickness of each layer, and total wall thickness of each segment of the gastrointestinal tract in healthy [cats](#) .

NORMAL THICKNESS OF INDIVIDUAL LAYERS OF SEGMENTS OF THE INTESTINE OF CATS					
	MUCOSA	SUBMUCOSA	MUSCULARIS	SEROSA	TOTAL
STOMACH (FUNDUS)	0.12 cm	0.04 cm	0.06 cm	0.03 cm	0.18 cm
STOMACH (BODY)	0.09 cm	0.04 cm	0.06 cm	0.03 cm	0.22 cm
PYLORUS	0.08 cm	0.04 cm	0.06 cm	0.03 cm	0.21 cm
DUODENUM	0.14 cm	0.03 cm	0.04 cm	0.03 cm	0.24 cm
JEJUNUM	0.11 cm	0.03 cm	0.04 cm	0.03 cm	0.23 cm
ILEUM	0.13 cm	0.03 cm	0.08 cm	0.03 cm	0.28 cm
COLON	0.04 cm	0.03 cm	0.03 cm	0.02 cm	0.12 cm

Besides absolute values, the study mentioned above also determined normal values for the ratio between mucosal thickness and diameter of aorta, and the ratio between thickness of the muscularis and diameter of the aorta. In that study, the aorta was measured at the level of the celiac artery in a transversal plane.

RATIOS BETWEEN THE THICKNESS OF INDIVIDUAL LAYERS OF SEGMENTS OF THE INTESTINE AND THE DIAMETER OF THE AORTA IN CATS		
	MUCOSA/AORTA	MUSCULARIS/AORTA
STOMACH (FUNDUS)	0.25	0.12
STOMACH (BODY)	0.18	0.12
PYLORUS	0.16	0.11
DUODENUM	0.27	0.079
JEJUNUM	0.22	0.087
ILEUM	0.25	0.14

COLON	0.08	0.05
--------------	------	------

Another well-known study on individual layers of the intestines has determined the following normal values:

NORMAL THICKNESS OF INDIVIDUAL LAYERS OF SEGMENTS OF THE INTESTINE IN CATS					
	MUCOSA	SUBMUCOSA	MUSCULARIS	SEROSA	TOTAL
DUODENUM	0.12 (0.10-0.15)	0.036 (0.029-0.043)	0.028 (0.030-0.035)	0.029 (0.023-0.036)	0.22 (0.17-0.25)
JEJUNUM	0.12 (0.10-0.15)	0.036 (0.029-0.044)	0.035 (0.025-0.045)	0.031 (0.023-0.039)	0.22 (0.19-0.26)
ILEUM (fold)	0.046 (0.031-0.062)	0.15 (0.095-0.21)	0.066 (0.044-0.095)	0.038 (0.026-0.057)	0.30 (0.25-0.35)
ILEUM (between folds)	0.049 (0.033-0.069)	0.053 (0.040-0.068)	0.065 (0.039-0.083)	0.038 (0.028-0.052)	0.20 (0.16-0.22)

Values are displayed in centimeters as averages, with normal ranges in parentheses.

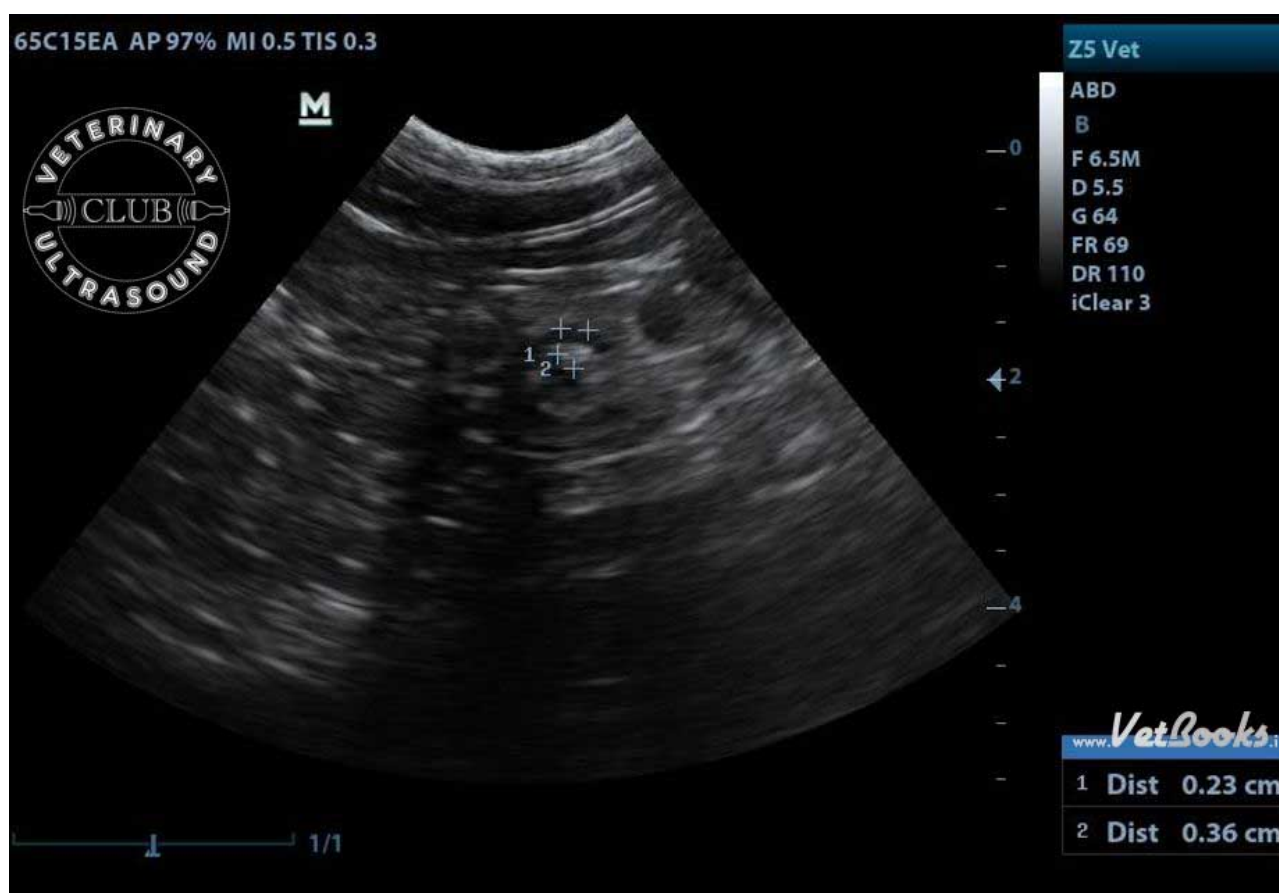

Figure 30. Ultrasound image, in transverse plane, of the ileum of a cat, close the ileoceccocolic junction. See

additional explanation on the magnified version of this image, below.

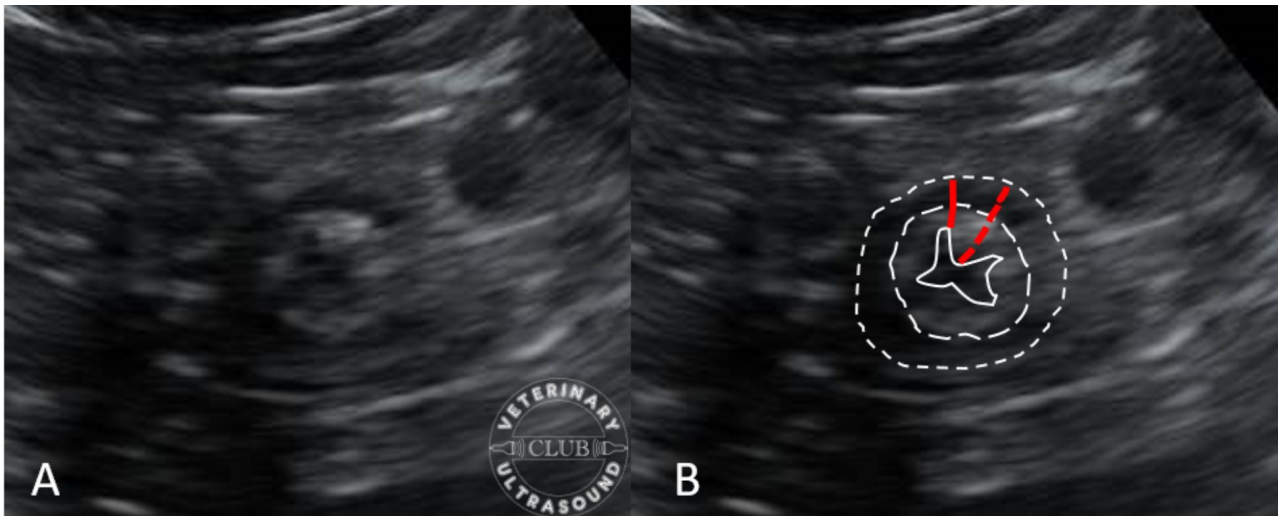


Figure 31. (A), magnified version of the image shown in Figure 30. (B), didactic scheme to explain the image shown in (A). In this scheme, the serosa and the external layer of the submucosa are represented with white dashed lines, and the contour of the lumen is marked with a solid whit line. The folds give the lumen an irregular appearance. The red solid line represents the wall thickness on the fold, and the dashed red line represents the wall thickness between folds. [Note: the red lines will be displayed as gray on devices with grayscale displays; colorblind people may perceive the red lines as gray.]

The **frequency of normal peristaltic movements** in dogs is 4 to 5 contractions per minute on the stomach and proximal duodenum. The other segments of the intestine contract at an average of 1 to 3 contractions per minute. Contractions are not observable in the descending colon.

LYMPH NODES

A recent study described parameters of the abdominal lymph nodes in healthy cats. Data from that study is compiled in the table below.

NORMAL DIMENSIONS OF ABDOMINAL LYMPH NODES IN CATS		
LYMPH NODE	LENGTH	DIAMETER
LUMBAR AORTIC	0.99 (0.21-1.67)	0.32 (0.03-0.074)
RENAL	0.61 (0.47-0.77)	0.35 (0.29-0.41)
HEPATIC	0.76 (0.59-0.95)	0.29 (0.25-0.36)
SPLENIC	0.84 (0.50-1.12)	0.32 (0.19-0.48)
GASTRIC	0.51 (0.46-0.64)	0.19 (0.19-0.19)

PANCREATICODUODENAL	0.84 (0.66-1.30)	0.46 (0.36-0.62)
JEJUNAL	2.01 (1.14-3.90)	0.50 (0.28-0.72)
ILEOCECAL	1.18 (0.67-2.32)	0.41 (0.27-0.48)
COLIC	0.90 (0.46-1.21)	0.31 (0.19-0.52)
CAUDAL MESENTERIC	0.60 (0.60-0.60)	0.21 (0.21-0.21)
MEDIAL ILIAC	1.35 (0.50-2.33)	0.45 (0.13-1.40)
SACRAL	0.96 (0.92-1.00)	0.22 (0.17-0.27)

Values are displayed in centimeters as averages, with normal ranges in parentheses.

The table below shows normal ranges in centimeters for the most frequently examined lymph nodes in dogs.

NORMAL DIMENSIONS OF ABDOMINAL LYMPH NODES IN DOGS			
LYMPH NODE	LENGTH (cm)	HEIGHT (cm)	WIDTH (cm)
JEJUNAL	0.5-20.0	0.16-0.82	0.26-1.47
MEDIAL ILIAC	2.1-2.2	0.46-0.48	0.59-0.61
SUPERFICIAL INGUINAL	1.77-1.79	0.31	0.61-0.68

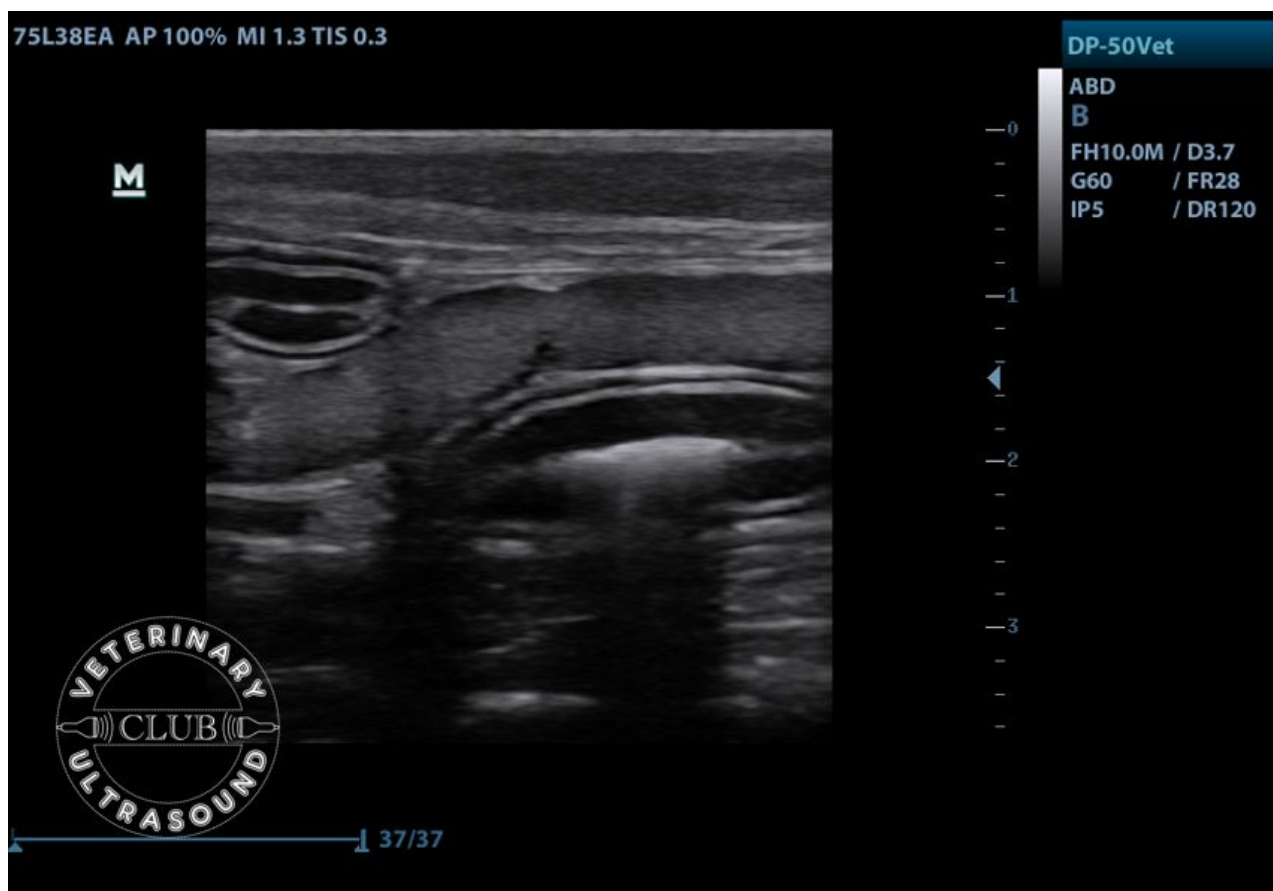


Figure 32. Ultrasound image of canine jejunal lymph nodes exhibiting their characteristic elongated shape.

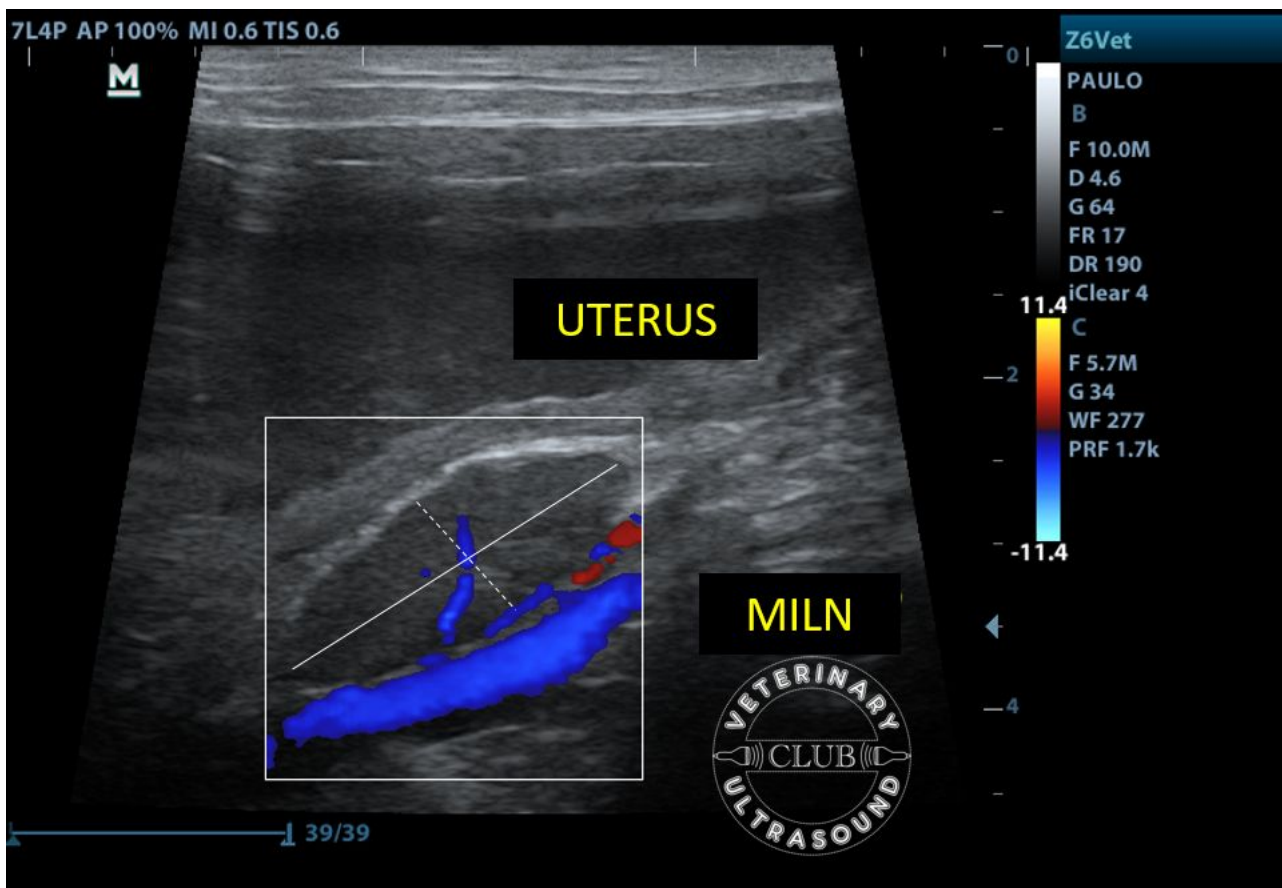


Figure 33. Ultrasound image of a medial iliac lymph node in a dog with a uterine alteration (pyometra). The solid line illustrates the long axis, and the dashed line illustrates the short axis.

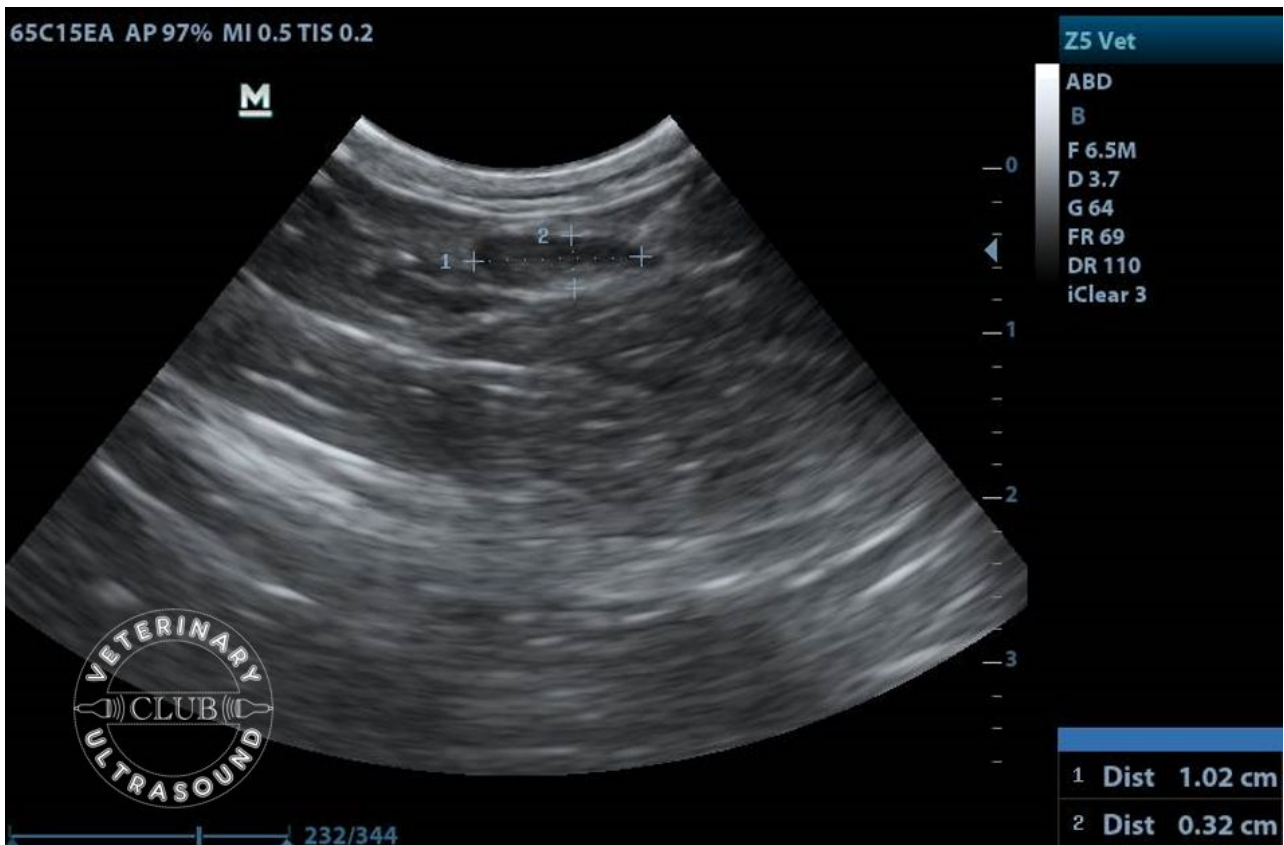


Figure 34. Ultrasound image of an inguinal superficial lymph node in a dog. Distance 1 (1.02 cm) corresponds to the length (long axis), and Distance 2 (0.32 cm) corresponds to the height (short axis).

In dogs, lymph nodes have variable sizes. As mentioned above for the adrenal glands, it is more important to measure thickness than length. In general, **a short axis to long axis ratio under 0.5 is considered normal**, and a short axis to long axis ratio up to 0.7 is considered benign; a short axis to long axis ratio above 0.7 is a characteristic of malignancy. This normal ratio has been validated for medial iliac lymph nodes and superficial lymph nodes. Conversely, this ratio does not apply to the jejunal lymph node, which is naturally more elongated.

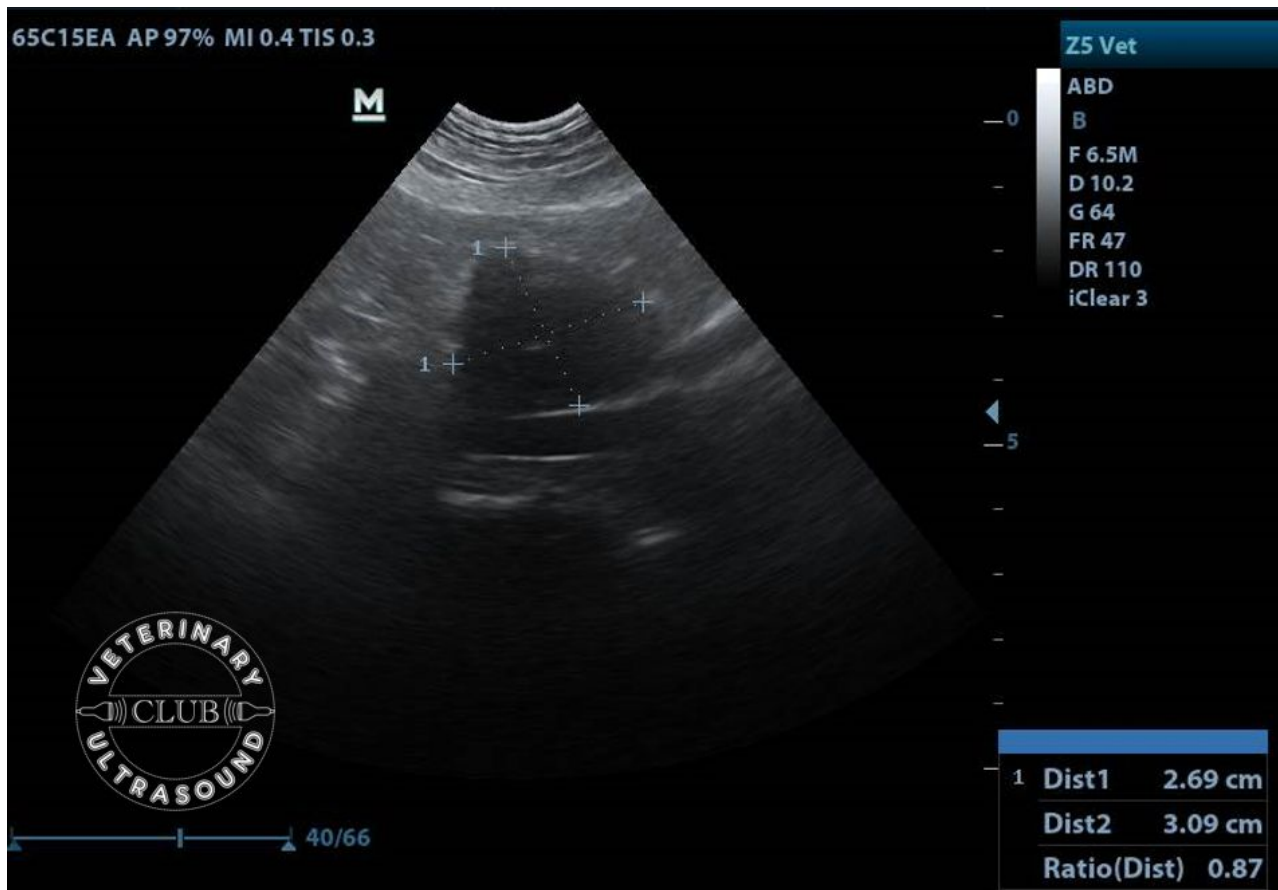


Figure 35. Ultrasound image of a medial iliac lymph node in a dog with a neoplasm. The short axis/long axis ratio is 0.87, which is a characteristic of malignancy.

A study that determined normal sizes of the medial iliac and jejunal lymph nodes in dogs of 4 to 6 weeks of age concluded that, in puppies, these lymph nodes are larger, can be hypoechoic or heteroechoic, and may exhibit unusual shapes.

NORMAL DIMENSIONS OF LYMPH NODES IN CANINE PUPPIES		
LYMPH NODE	LENGTH	WIDTH
Jejunal	1.6 (0.64-3.49)	0.60 (0.23-1.57)
Medial iliac	1.3 (0.54-2.78)	0.43 (0.19-0.82)
Values are displayed in centimeters as averages, with normal ranges in parentheses.		

BIBLIOGRAPHY

The articles from which data was gathered to compile the information shown on this book are listed below, under each corresponding topic. Books used as source of information are

also included in this list.

URINARY BLADDER

Finn-Bodner ST. The urinary bladder . In: Cartee RE, Selcer BA, Hudson JA. (Eds.) Practical Veterinary Ultrasound. Baltimore: Williams & Wilkins, 1995, pp 200-235.

Geisse AL, Lowry JE, Schaeffer DJ, Smith CW. Sonographic evaluation of urinary bladder wall thickness in normal dogs. Vet Radiol Ultrasound. 1997;38(2):132-137. doi:10.1111/j.1740-8261.1997.tb00828.x

KIDNEYS

Barr FJ, Holt PE, Gibbs C. Ultrasonographic measurement of normal renal parameters. Journal of Small Animal Practice. 1990;31:180-184. doi:10.1111/j.1748-5827.1990.tb00764.x

Debruyne K, Haers H, Combes A, et al. Ultrasonography of the feline kidney: Technique, anatomy and changes associated with disease. J Feline Med Surg. 2012;14(11):794-803. doi:10.1177/1098612X12464461

Debruyne K, Paepe D, Daminet S, et al. Comparison of renal ultrasonographic measurements between healthy cats of three cat breeds: Ragdoll, British Shorthair and Sphynx. J Feline Med Surg. 2013;15(6):478-482. doi:10.1177/1098612X12471057

Mareschal A, d'Anjou MA, Moreau M, Alexander K, Beauregard G. Ultrasonographic measurement of kidney-to-aorta ratio as a method of estimating renal size in dogs. Vet Radiol Ultrasound. 2007;48(5):434-438. doi:10.1111/j.1740-8261.2007.00274.x

Paepe D, Bavegems V, Combes A, Saunders JH, Daminet S. Prospective evaluation of healthy Ragdoll cats for chronic kidney disease by routine laboratory parameters and ultrasonography. J Feline Med Surg. 2013;15(10):849-857. doi:10.1177/1098612X13477415

Park IC, Lee HS, Kim JT, et al. Ultrasonographic evaluation of renal dimension and resistive index in clinically healthy Korean domestic short-hair cats. J Vet Sci. 2008;9(4):415-419. doi:10.4142/jvs.2008.9.4.415

Walter PA, Johnston GR, Feeney DA, O'Brien TD. Renal ultrasonography in healthy cats. Am J Vet Res. 1987;48(4):600-607.

RENAL PELVIS

D'Anjou MA, Bédard A, Dunn ME. Clinical significance of renal pelvic dilatation on ultrasound in dogs and cats. Vet Radiol Ultrasound. 2011;52(1):88-94.

URETER

Hardie EM, Kyles AE. Management of ureteral obstruction. *Vet Clin North Am Small Anim Pract.* 2004;34(4):989-1010. doi:10.1016/j.cvsm.2004.03.008

Rozear L, Tidwell AS. Evaluation of the ureter and ureterovesicular junction using helical computed tomographic excretory urography in healthy dogs. *Vet Radiol Ultrasound.* 2003;44(2):155-164. doi:10.1111/j.1740-8261.2003.tb01264.x

SPLEEN

Sayre RS, Spaulding KA. Formulation of a standardized protocol and determination of the size and appearance of the spleen in healthy cats. *J Feline Med Surg.* 2014;16(4):326-332. doi:10.1177/1098612X13508947

ADRENAL GLANDS

Bento PL, Center SA, Randolph JF, Yeager AE, Bicalho RC. Associations between sex, body weight, age, and ultrasonographically determined adrenal gland thickness in dogs with non-adrenal gland illness. *J Am Vet Med Assoc.* 2016;248(6):652-660. doi:10.2460/javma.248.6.652

Combes A, Pey P, Paepe D, et al. Ultrasonographic appearance of adrenal glands in healthy and sick cats. *J Feline Med Surg.* 2013;15(6):445-457. doi:10.1177/1098612X12469523

Soulsby SN, Holland M, Hudson JA, Behrend EN. Ultrasonographic evaluation of adrenal gland size compared to body weight in normal dogs. *Vet Radiol Ultrasound.* 2015;56(3):317-326. doi:10.1111/vru.12236

PANCREAS AND MAJOR DUODENAL PAPILLA

Etue SM, Penninck DG, Labato MA, Pearson S, Tidwell A. Ultrasonography of the normal feline pancreas and associated anatomic landmarks: a prospective study of 20 cats. *Vet Radiol Ultrasound.* 2001;42(4):330-336. doi:10.1111/j.1740-8261.2001.tb00948.x

Hecht S, Henry G. Sonographic evaluation of the normal and abnormal pancreas. *Clin Tech Small Anim Pract.* 2007;22(3):115-121. doi:10.1053/j.ctsap.2007.05.005

Larson MM, Panciera DL, Ward DL, Steiner JM, Williams DA. Age-related changes in the ultrasound appearance of the normal feline pancreas. *Vet Radiol Ultrasound.* 2005;46(3):238-242. doi:10.1111/j.1740-8261.2005.00041.x

Mortier JR, Maddox TW, White GM, Blundell RJ, Monné JM, Lillis SM. Ultrasonographic appearance of the major duodenal papilla in dogs without evidence of hepatobiliary, pancreatic, or gastrointestinal tract disease. *Am J Vet Res.* 2016;77(6):597-603. doi:10.2460/ajvr.77.6.597

Penninck DG, Zeyen U, Taeymans ON, Webster CR. Ultrasonographic measurement of the pancreas and pancreatic duct in clinically normal dogs. *Am J Vet Res.* 2013;74(3):433-437. doi:10.2460/ajvr.74.3.433

GALLBLADDER

Diana A, Guglielmini C, Specchi S, et al. Ultrasonographic evaluation of preprandial and postprandial gallbladder volume in healthy cats. *Am J Vet Res.* 2012;73(10):1583-1588. doi:10.2460/ajvr.73.10.1583

Larson MM. Ultrasound Imaging of the Hepatobiliary System and Pancreas. *Vet Clin North Am Small Anim Pract.* 2016;46(3):453-vi. doi:10.1016/j.cvsm.2015.12.004

Léveillé R, Biller DS, Shiroma JT. Sonographic evaluation of the common bile duct in cats. *J Vet Intern Med.* 1996;10(5):296-299. doi:10.1111/j.1939-1676.1996.tb02065.x

Penninck DG, Brisson JO, Webster CR. Sonographic assessment of gallbladder volume in normal cats. *Vet Radiol Ultrasound.* 2010;51(6):665-666. doi:10.1111/j.1740-8261.2010.01708.x

AORTA, CAUDAL VENA CAVA AND PORTAL VEIN

d'Anjou MA, Penninck D, Cornejo L, Pibarot P. Ultrasonographic diagnosis of portosystemic shunting in dogs and cats. *Vet Radiol Ultrasound.* 2004;45(5):424-437. doi:10.1111/j.1740-8261.2004.04076.x

Holland M, Hudson J, Bao Y, Gaillard P. Aortic to caudal vena cava ratio measurements using abdominal ultrasound are increased in dogs with confirmed systemic hypertension. *Vet Radiol Ultrasound.* 2020;61(2):206-214. doi:10.1111/vru.12822

Kamikawa L, Bombonato PP. Ultrasonography of abdominal aorta and its branches in dogs. *Cienc Rural.* 2007;37(2):412-417. doi:10.1590/S0103-84782007000200018.

Sartor R, Maprim MJ, Takahira RK. Morphometric evaluation, by ultrasonographic exam, of the portal vein, caudal vena cava and abdominal aorta in healthy dogs of different body weights. *Arch Vet Sci.* 2010;13(3):143-148. doi:10.5380/avs.v15i3.17486

TESTICLES AND PROSTATE

Atalan G, Holt PE, Barr FJ, Brown PJ. Ultrasonographic estimation of prostatic size in canine cadavers. *Res Vet Sci.* 1999;67(1):7-15. doi:10.1053/rvsc.1998.0267

Davidson AP, Baker TW. Reproductive ultrasound of the dog and tom. *Top Companion Anim Med.* 2009;24(2):64-70. doi:10.1053/j.tcam.2008.11.003

de Souza MB, Silva LDMD, Moxon R, Russo M, England GCW. Ultrasonography of the prostate gland and testes in dogs. *In Practice.* 2017;39:21-32. doi : 10.1136/inp.i6054

Ruel Y, Barthez PY, Mailles A, Begon D. Ultrasonographic evaluation of the prostate in healthy intact dogs. *Vet Radiol Ultrasound.* 1998;39(3):212-216. doi:10.1111/j.1740-8261.1998.tb00342.x

UTERUS AND OVARIES

Al-Bassam MA, Thomson RG, O'Donnell L. Normal postpartum involution of the uterus in the dog. *Can J Comp Med.* 1981;45(3):217-232.

Barbosa Cda C, de Souza MB, de Freitas LA, da Silva TF, Domingues SF, da Silva LD. Assessment of uterine involution in bitches using B-mode and Doppler ultrasonography. *Anim Reprod Sci.* 2013;139(1-4):121-126. doi:10.1016/j.anireprosci.2013.02.027

Sendag S, Alan M, Eski F, Uslu S, Uslu BA, Wehrend A. Postpartum uterus involution observed by real-time ultrasound scanning and vaginal cytology in Van cats. *J Feline Med Surg.* 2016;18(12):954-958. doi:10.1177/1098612X15598546

Yeager AE, Concannon PW. Serial ultrasonographic appearance of postpartum uterine involution in beagle dogs. *Theriogenology.* 1990;34(3):523-535. doi:10.1016/0093-691x(90)90009-i

INTESTINES

Gladwin NE, Penninck DG, Webster CR. Ultrasonographic evaluation of the thickness of the wall layers in the intestinal tract of dogs. *Am J Vet Res.* 2014;75(4):349-353. doi:10.2460/ajvr.75.4.349

Penninck DG, Nyland TG, Fisher PE, Kerr LY. Ultrasonography of the normal canine gastrointestinal tract. *Vet Radiol.* 1989;30(6):272-276. doi : 10.1111/j.1740-8261.1989.tb01799.x

Winter MD, Londono L, Berry CR, Hernandez JA. Ultrasonographic evaluation of relative gastrointestinal layer thickness in cats without clinical evidence of gastrointestinal tract disease. *J Feline Med Surg.* 2014;16(2):118-124. doi:10.1177/1098612X13499013

LYMPH NODES

Agthe P, Caine AR, Posch B, Herrtage ME. Ultrasonographic appearance of jejunal lymph nodes in dogs without clinical signs of gastrointestinal disease. *Vet Radiol Ultrasound.* 2009;50(2):195-200. doi:10.1111/j.1740-8261.2009.01516.x

Di Donato P, Penninck D, Pietra M, Cipone M, Diana A. Ultrasonographic measurement of the relative thickness of intestinal wall layers in clinically healthy cats. *J Feline Med Surg.* 2014;16(4):333-339. doi:10.1177/1098612X13509080

Krol L, O'Brien R. Ultrasonographic assessment of abdominal lymph nodes in puppies. *Vet Radiol Ultrasound.* 2012;53(4):455-458. doi:10.1111/j.1740-8261.2012.01932.x

Pugh CR. Ultrasonographic examination of abdominal lymph nodes in the dog. *Vet Rad Ultrasound.* 1994;35(2):110-115. doi : 0.1111/j.1740-8261.1994.tb00197.x

Schreurs E, Vermote K, Barberet V, Daminet S, Rudolf H, Saunders JH. Ultrasonographic anatomy of abdominal lymph nodes in the normal cat. *Vet Radiol Ultrasound.* 2008;49(1):68-72. doi:10.1111/j.1740-8261.2007.00320.x

GENERAL ULTRASOUND IMAGING BOOKS

Penninck D, d'Anjou MA (Eds.) Atlas of Small Animal Ultrasonography. 2. ed. Ames: Wiley-Blackwell, 2015

Torroja RN, Pereira YM, Gerlach YE, Miño ED. (Eds.) Diagnostic Ultrasound in Cats. Zaragoza: Servet, 2015.

Table of Contents

URINARY BLADDER	4
KIDNEYS	5
RENAL PELVIS	10
URETER	11
URETHRA	12
SPLEEN	14
ADRENAL GLANDS	15
PANCREAS	17
MAJOR DUODENAL PAPILLA	18
LIVER	20
GALLBLADDER	20
AORTA, PORTAL VEIN E CAUDAL VENA CAVA	23
UTERUS	25
OVARIES	27
PROSTATE	29
TESTICLES	31
STOMACH AND INTESTINES	33
LYMPH NODES	38
BIBLIOGRAPHY	42