

# Atlas of Meat Inspection Pathology

**William S. Monlux, D.V.M., Ph.D.**

**Andrew W. Monlux, D.V.M., M.S., Ph.D.**

**National Animal Disease Laboratory, Ames, Iowa**

**Veterinary Sciences Research Division**

**Agricultural Research Service**

**Agriculture Handbook No. 367**

**UNITED STATES DEPARTMENT OF AGRICULTURE**

**Washington, D.C.**

**Issued May 1972**

PERMITS SERIAL RECORDS  
CO./SERIALS BRANCH

AUG 6 '70

USDA  
NATIONAL AGRICULTURE LIBRARY  
RECEIVED



# CONTENTS

	Page		Page
<b>Introduction</b> .....	1	<b>Neoplastic Diseases—Con.</b>	
<b>Neoplastic Diseases</b> .....	3	Hematopoietic tissue tumors .....	63
Squamous epithelial tumors .....	3	Lymphosarcoma .....	63
Papilloma .....	3	Myeloma and myelosarcoma .....	68
Infectious fibropapillomas (warts) of cattle .....	4	Neoplasms of the nervous system .....	70
Fibropapillomas of the bovine penis, vulva, and vagina .....	6	Auditory (acoustic) nerve tumor .....	70
Squamous-cell carcinoma .....	8	Meningioma .....	71
Neoplasms of the eye .....	11	Nerve sheath tumor (Schwannoma) .....	74
Corneal dermoid in cattle .....	11	Miscellaneous tumors .....	79
Epidermal papilloma of the eye of cattle ..	12	Embryonal sarcoma of the vagina of swine .	79
Epidermal plaque of the eye of cattle ....	14	Melanoma and malignant melanoma .....	80
Squamous-cell carcinoma of the eye of cattle .....	14	Mesothelioma .....	82
Glandular epithelial tumors .....	18	<b>Chronic Infectious Bacterial Diseases That Re-</b> <b>semble Neoplastic Alterations</b> .....	85
Adenoma .....	18	Actinobacillosis .....	85
Adenocarcinoma .....	20	Actinomycosis .....	88
Adenocarcinoma of the intestine .....	22	Brucellosis .....	90
Neoplasms of the adrenal gland .....	23	Cervical anthrax in swine .....	92
Adrenal cortical adenoma and adenocarcinoma .....	23	Coccidioidomycosis .....	94
Neuroblastoma of the adrenal medulla ...	25	Contagious ecthyma in sheep and goats .....	96
Pheochromocytoma .....	26	Mucormycosis .....	99
Neoplasms of the genital tract .....	29	Nasal granuloma of cattle .....	102
Adenocarcinoma of the uterus of the cow	29	Necrobacillosis .....	104
Granulosa-cell tumor of the ovary .....	32	Nocardiosis .....	106
Neoplasms of the kidney .....	34	Paratuberculosis (Johne's disease) .....	109
Adenoma and adenocarcinoma of the kidney .....	34	Ovine caseous lymphadenitis .....	111
Embryonal nephroma .....	36	Staphylococcosis .....	113
Neoplasms of the liver .....	39	Tuberculoid dermatitis of cattle .....	114
Adenoma and adenocarcinoma of the liver	39	Tuberculosis .....	116
Adenoma and adenocarcinoma of the hepatic bile ducts .....	41	<b>Chronic Parasitic Diseases That Resemble Neo-</b> <b>plastic Alterations</b> .....	121
Adenoma and adenocarcinoma of the gallbladder .....	43	Cysticercosis .....	121
Neoplasms of the lung .....	45	Demodectic mange .....	122
Adenoma of the lung .....	45	Echinococcosis .....	124
Primary pulmonary carcinomas .....	47	Fascioliasis .....	125
Secondary pulmonary neoplasms .....	49	Onchocerciasis of cattle .....	128
Connective tissue tumors .....	51	Pentastomiasis .....	129
Chondroma and chondrosarcoma .....	51	Sarcosporidiosis .....	131
Hemangioma and hemangiosarcoma .....	53	Stephanofilariasis .....	132
Leiomyoma and leiomyosarcoma .....	55	<b>Miscellaneous Diseases That Are Frequently Sub-</b> <b>mitted for Diagnostic Clarification</b> .....	135
Lipoma and liposarcoma .....	58	Endocarditis .....	135
Osteoma and osteosarcoma .....	60	Eosinophilic myositis .....	137
Rhabdomyoma and rhabdomyosarcoma ....	61	Fatty muscular dystrophy .....	139
		Focal hepatic necrosis ("sawdust liver"; telangiectasis) .....	140

	Page		Page
<b>Miscellaneous Diseases That Are Frequently Submitted for Diagnostic Clarification—Con.</b>		<b>Miscellaneous Diseases That Are Frequently Submitted for Diagnostic Clarification—Con.</b>	
Hemosiderosis .....	143	Pulmonary adenomatosis of cattle .....	160
Hyperkeratosis of cattle .....	144	Pulmonary adenomatosis of sheep .....	161
Intestinal emphysema in swine .....	147	Spondylitis .....	163
Melanosis .....	149	Steatitis ("yellow fat" disease) in swine .....	165
Nutritional or cachectic fat necrosis .....	151	Swine abscesses .....	167
Nutritional muscular dystrophy ("white muscle" disease) .....	153	Traumatic fat necrosis .....	169
Osteohemochromatosis (porphyria) .....	155	Viral diarrhea of cattle .....	171
Ossification of the lungs .....	156		
Panarteritis .....	158	<b>Miscellaneous Lesions of Interest in Meat Inspection Pathology .....</b>	<b>175</b>

---

Numbers in parentheses in figure legends are used to identify the prints at the National Animal Disease Laboratory.

# Atlas of Meat Inspection Pathology

## INTRODUCTION

An atlas of meat-inspection pathology is a bound collection of photographs, supported by explanatory legends and text, illustrating lesions found in meat-producing animals at the time of slaughter for food. It functions as a ready reference guide for meat inspectors who are searching for current terminology and for assistance in interpreting lesions and in making diagnoses.

For the most part, the meat inspector must make immediate diagnoses of pathologic conditions without recourse to laboratory assistance. It follows, then, that the quality of meat-inspection services is largely dependent on the knowledge of the inspector and the accuracy of his diagnoses. Certainly, the inspector's acquisition of knowledge and accuracy is enhanced by the laboratory; by providing him with additional information about the specimens he submits, the laboratory performs a valuable educational function and serves the dual purpose of substantiating his diagnoses and of preventing him from perpetuating misconceptions. However, experience has demonstrated that often the diagnostic laboratory's most carefully prepared description falls woefully short of clearly explaining the microscopic alterations found in pathologic specimens.

This Atlas is intended to contribute to the meat inspector's knowledge and accuracy by providing him with a readily available visual reference for correlating the gross and microscopic details of the lesions he is most likely to encounter during the meat inspection process. The inadequacy of language in conveying the appearance of lesions to the mind of the reader makes color illustrations mandatory in any atlas of a subject where color appreciation and anatomic configuration are the basis for interpretation of tissue alterations.

The material for this Atlas has been taken, for the most part, from records in the files of the United States Department of Agriculture Veterinary Sciences Research Division Branch Laboratory in Denver, Colo. The Denver laboratory formerly provided diagnostic service for the USDA Federal meat inspection service. The collection of gross and microscopic animal pathologic specimens established at the laboratory by Charles L. Davis, former Director, provided the basis for this

work.<sup>1</sup> During 1953 and 1954, the Denver laboratory cooperated with the USDA Federal meat inspection service in a survey conducted by the USDA for the purpose of determining the incidence of neoplasms in meat-producing animals slaughtered in Denver abattoirs. Nearly all the gross photographs in this Atlas were made from specimens found in Denver abattoirs during the period of the survey.

In meat inspection, the basic problem is not essentially that of diagnosing pathologic conditions for the purpose of disease control, but rather that of evaluating the fitness of the carcass for food and of assuring the public of protection against animal diseases that might be transmissible to man. Thus, the types of lesions found by meat inspectors vary considerably from those that might be routinely encountered during postmortem examinations performed in a veterinary practice or in the pathology department of a veterinary college. The meat inspector's postmortem examinations generally reveal pathologic conditions that would not have immediately endangered the lives of affected animals. Further, the quantity of the animals examined is so large that many conditions are brought into prominence during meat inspection that might be encountered but rarely, if at all, by clinicians.

It is impossible to describe and to provide illustrations of all lesions that are encountered during routine meat inspection. An attempt has been made to include lesions of the kind most frequently submitted by meat inspectors because of either professional interest or problems in diagnosis. In some specific conditions, of which actinobacillosis is an example, emphasis is placed on the older granulomatous type of lesions instead of on the more frequently observed early suppurative alterations, for

---

<sup>1</sup> Work on this Atlas was started by Wayne A. Anderson, former Director of the Denver laboratory, but was interrupted by Dr. Anderson's untimely death. The authors are greatly indebted to Dr. Anderson for his efforts in initiating the work and for those materials and photographs included in the manuscript that he assembled. Appreciation is also extended to the veterinarians, especially J. W. Hovorka and A. L. Stigers, formerly assigned to the Meat Inspection Branch, Agricultural Research Service, USDA, who cooperated with veterinarians at VSR Branch laboratory in Denver in the collection of specimens.

the older lesions are the ones usually submitted to the laboratory for confirmatory diagnosis. In anthrax, consideration has been given only to cervical lesions in swine, since these are observed most frequently during postmortem inspection. Animals affected with generalized rapidly fatal anthrax are seldom brought to the killing floor, and specimens from such animals are seldom submitted to the laboratory for diagnosis.

This work is not intended to serve as a textbook of

pathology or as a reference index, for these subjects have been adequately treated elsewhere. No attempt has been made to describe disease processes in their entirety, and all theoretical discussions have been omitted. Photographs and accompanying text are designed to furnish veterinary meat inspectors and students with information concerning the gross and microscopic characteristics of lesions observed during routine meat inspection and submitted to the laboratory for diagnosis.

# NEOPLASTIC DISEASES

## Squamous Epithelial Tumors

### Papilloma

**Definition.**—A papilloma is a benign tumor of stratified squamous epithelium.

**Distribution and incidence.**—Papillomas are found throughout the United States in all breeds, species, genera, and sexes of animals. Infectious papillomas are most frequently observed in young animals and non-infectious varieties are found in older individuals. Cattle have the highest incidence of papillomas of meat-producing animals because one of the papillomas affecting this species is caused by a virus and is highly infectious.

Lesions in cattle are most commonly observed on the skin of the head, neck, and shoulders, but may be found wherever there is squamous epithelium, including the esophagus, omasum, mouth, vagina, vulva, and penis. In horses, papillomas are usually located on the skin of the prepectoral and shoulder regions, eyelids, upper lip, and external genital organs. Papillomas of sheep and swine have no particularly favored location.

**Macroscopic appearance.**—A papilloma may be nodular, villous, fungoid, spinous, polypoid, papillomatous, or hornlike in appearance. An extremely large one may measure 10 cm. in diameter and 30 cm. in length. Its



Figure 2.—Multiple papillomas in the esophagus of a cow (M222).

surface may be smooth, tufted, shaggy, or nodular. Occasionally, a papilloma takes the form of a hornlike



Figure 1.—Multiple hornlike papillomas of the teat of a cow (E111-D1940).

process projecting from the skin. The base of a papilloma may be broad or it may be so small that the growth is pedunculated. Papillomas protrude to the exterior of the individual or into the lumen of the organ but they do not invade the underlying tissues or extend below the squamous epithelium from which they originate.

**Microscopic appearance.**—In most respects a histologic preparation of a papilloma has the appearance of normal skin. The major differences are centered around the fingerlike processes of stratified squamous epithelium that protrude above the surrounding epithelial surface and contain a connective tissue core. The characteristics of a papilloma on a stratified squamous mucous membrane are similar to those of the skin. The cells of a papilloma are of an adult type. Mitotic figures are infrequently present. Normochromasia is evident, indicating the tumor is benign.

A very important diagnostic observation to make when studying papillomas is that the basal layer of the epithelium is intact. In contrast, malignant cells of squamous epithelial tumors (squamous-cell carcinoma) penetrate the basal layer of the epithelium and infiltrate the underlying corium and subcutaneous tissue.

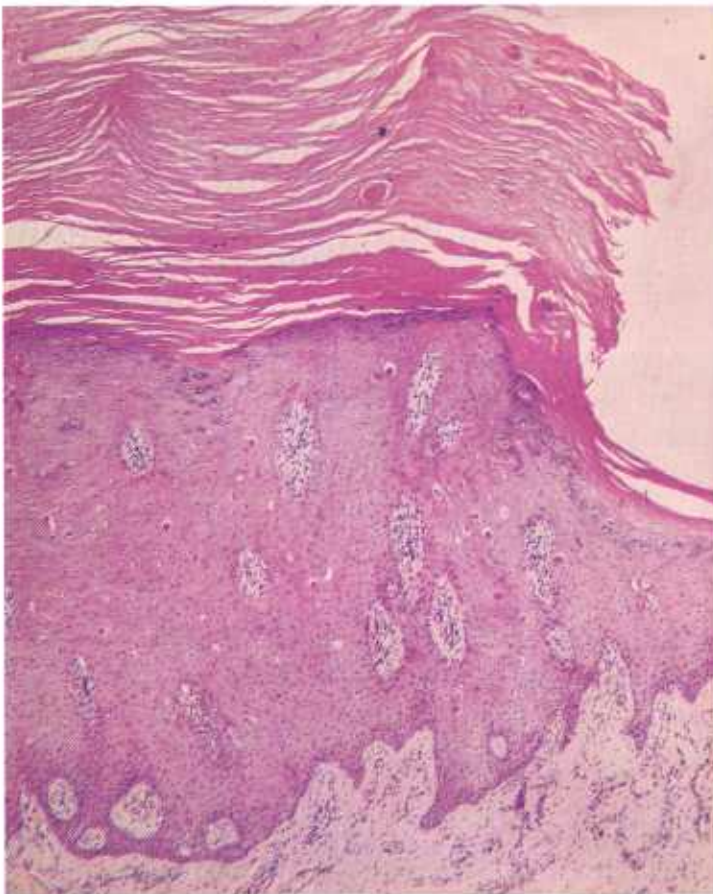


Figure 3.—Histologic appearance of the papilloma of the teat (E111-D1940) shown in figure 1. The epithelial cells are normal in size and shape and have a normal staining reaction. The basement membrane is intact and there is no indication of invasion into the underlying tissues. A thick layer of cornified epithelium covers the surface and gives the tumor its hornlike external appearance. Hematoxylin-eosin stain.  $\times 50$ .

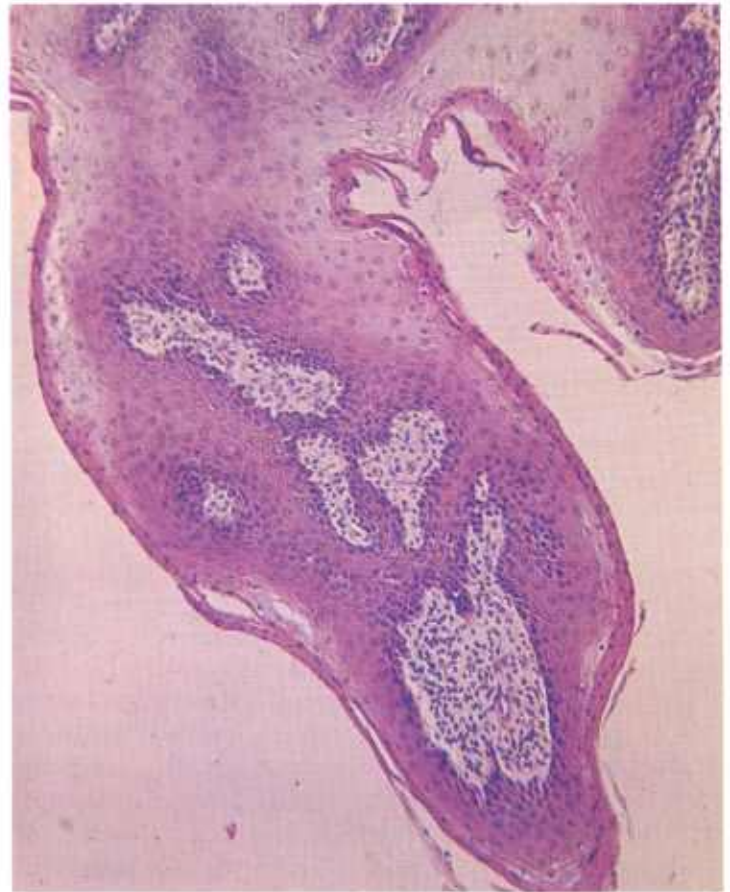

Figure 4.—Histologic appearance of one of the papillomas of the esophagus (M222) shown in figure 2. The tumor cells are normal in size and shape and have a normal staining reaction. The growth protrudes into the lumen of the esophagus rather than into the underlying tissues. A thin layer of keratinized epithelium covers the surface of the tumor. Hematoxylin-eosin stain.  $\times 125$ .

### *Infectious fibropapillomas (warts) of cattle*

**Definition.**—Infectious fibropapillomas (warts) of cattle are the result of a viral disease and are characterized by the appearance of papillomas on various parts of the body.

**Distribution and incidence.**—Infectious fibropapillomas are found in all breeds of cattle throughout the United States. All sexes are equally affected. They are most commonly observed in cattle under 1 year of age although older animals may be involved.

Warts are found on all stratified squamous epithelial surfaces. In cattle under 1 year of age, they are most frequently located on the head and ears, around the eyes and mouth, and on the sides of the neck and shoulders. In cows, warts usually occur on the udder, teats, vulva, and vagina. In mature bulls, one of the common locations is on the penis. Abattoir observations indicate that as many as 25 percent of cattle hides have warts during the summer months. Many hides are rendered almost valueless when the skin has been extensively affected.

**Macroscopic appearance.**—Warts vary greatly in both size and shape. They may occur as single growths meas-



Figure 5.—A mass of papillomas on the back of a Holstein cow (NFC100).

uring less than a centimeter in diameter or as multiple large protruding masses that measure as much as 15 cm. in diameter and cover large areas of the skin surface. They may assume the shape of low nodular plaques or protrude as villous, fungoid, spinous, polypoid, or hornlike masses. In calves, these warty growths may become large and pendulous.

The surface of a wart is usually gray, rough, scaly, and dry. When incised, its cut surface reveals an external layer of keratinized epithelium and an internal

core of moist white connective tissue. When large numbers of warts are present, particularly when they are of the cauliflower type and involve the neck and shoulders, their surfaces become moist and tend to bleed and slough as the result of trauma and to emit a very offensive odor of putrefaction.

**Microscopic appearance.**—Tissue response to infection with the papilloma virus depends on the type of tissue affected. If the virus affects the skin, the principal response is hyperplasia of the epithelium with only slight hyperplasia of the underlying connective tissue. However, when the virus affects a squamous epithelial mucous membrane, there is comparatively little hyperplasia of epithelium but there is an abundant connective tissue proliferation in the submucosa.

When stratified squamous epithelium is invaded by the papilloma virus, affected cells undergo hyperplasia and the enlarging mass of cells protrudes into the underlying connective tissue. This mass of growing cells spreads laterally and finally protrudes externally as papillomas with acanthotic, parakeratotic, and hyperkeratotic alterations in the neoplastic epithelium. No infiltration of epidermal cells through the basement membrane of the stratified squamous epithelium occurs. The principal cause of the increased thickness of the epidermis is the increased growth of the stratum spinosum (acanthosis). The amount of keratinization varies considerably in accordance with the growth's age and, perhaps, with the animal's individual keratinizing characteristics. Some growths have relatively small amounts of keratin whereas others produce dense, horny types of keratinized epithelium. Foci of intensely staining proliferating basal cells are present in the stratum germinativum. Some cells in the keratogenic zone have cytoplasmic ballooning and contain eosin-staining spherules and deeply staining basophilic keratohyaline granules.

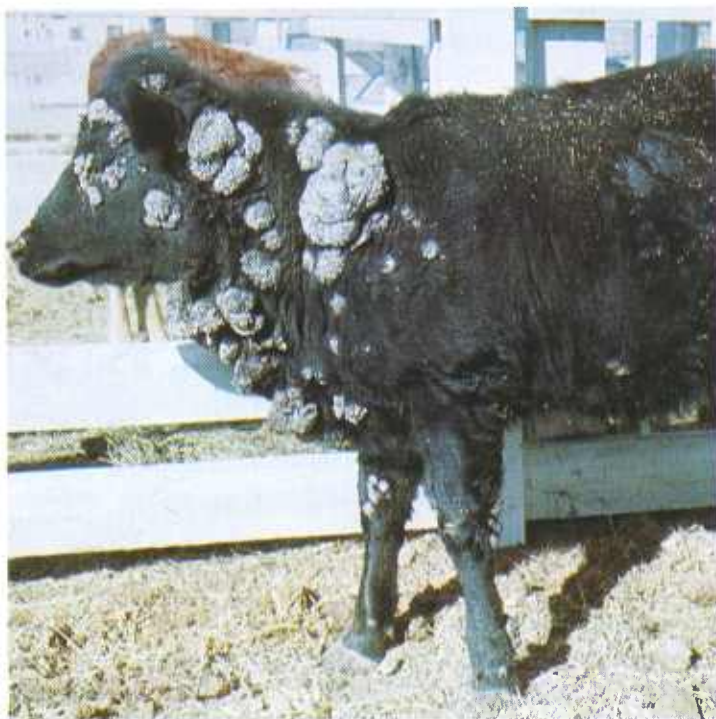

Figure 6.—Multiple papillomas involving the skin of an Angus steer (DWB100).

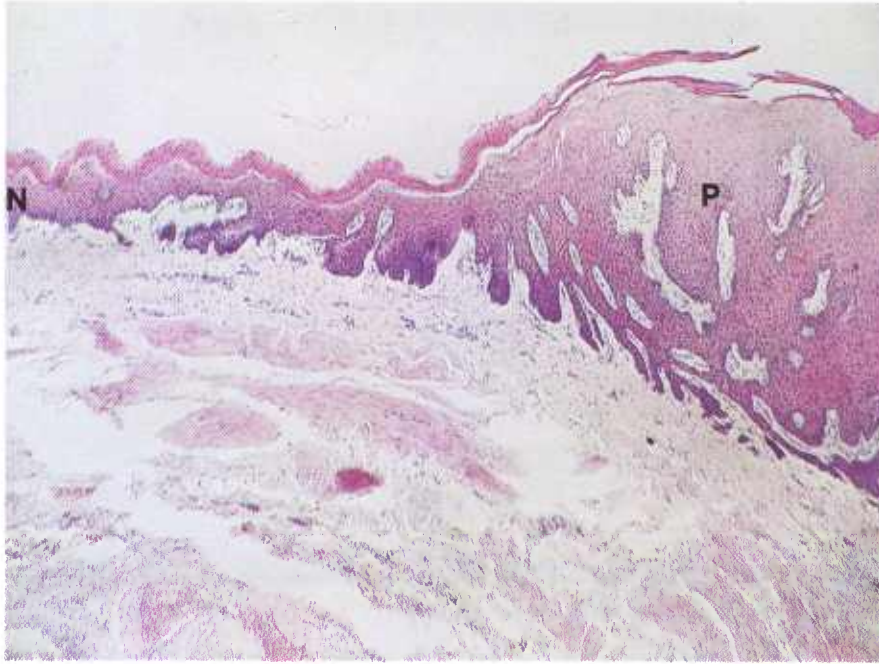


Figure 7.—Papilloma of the esophagus of a bovine animal (WSM218). The normal epithelium (N) has become hyperplastic (P) and has emitted downgrowths into the underlying connective tissue. Hematoxylin-eosin stain.  $\times 60$ .

Connective tissue cells in the dermis and submucosa undergo hyperplasia when invaded by the papilloma virus. These hyperplastic cells are often arranged in whorls around blood vessels, an arrangement that may be confused with that of a hemangiopericytoma. No cytoplasmic or intranuclear inclusion bodies are present. Occasionally, the fibroblasts contain eosin-staining spherules that probably represent products of cellular degeneration.

Usually, some degree of bacterial invasion occurs in the vicinity of the papilloma, particularly in areas where the growth is subjected to trauma or where putrefactive organisms invade the tumor's debris. If surgical or medicinal methods are used to remove the wart, there is usually an inflammatory response to the surgical procedure or the chemical agent employed. This response is lymphocytic, macrocytic, suppurative, or hyperplastic in type.

#### *Fibropapillomas of the bovine penis, vulva, and vagina*

**Definition.**—Fibropapillomas of the penis, vulva, and vagina of cattle are benign growths that involve epithelium and connective tissue. They are caused by the bovine papilloma virus.

**Distribution and incidence.**—Fibropapillomas of the penis, vulva, and vagina are found in all breeds of cattle throughout the United States. They are diseases of young bulls, steers, and heifers. Occasionally, older cattle are affected. Since cutaneous warts are commonly found in cattle herds, there is ample opportunity for the mucosa of the penis, vulva, and vagina to become infected with the papilloma virus.

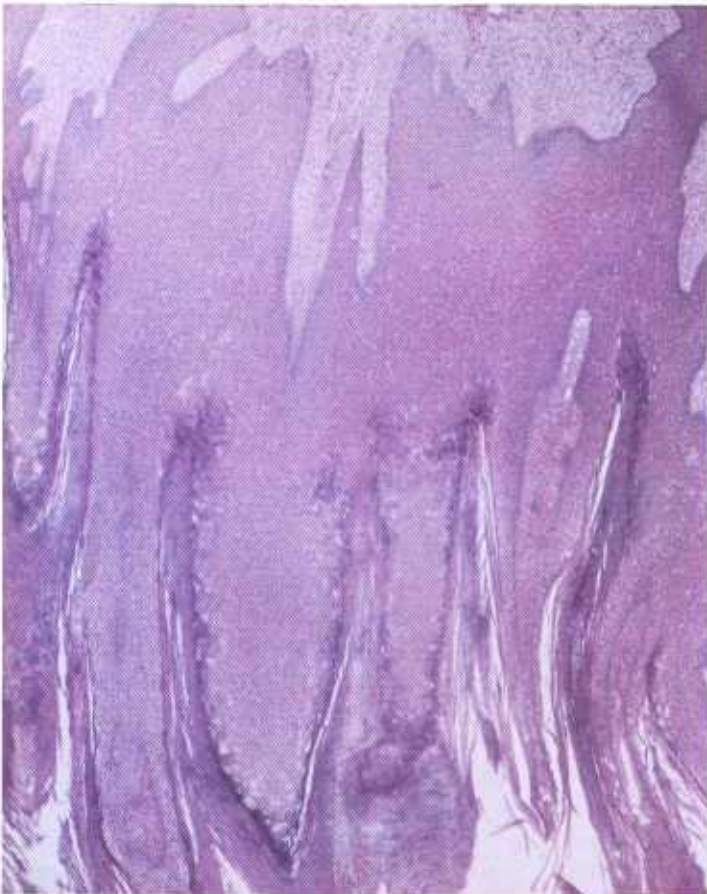

Figure 8.—Papilloma of the skin of a bovine animal (NFC101) that shows the hyperplastic and hyperkeratotic nature of the growth. Hematoxylin-eosin stain.  $\times 25$ .

It has been established that this tumor is produced by the infectious bovine papilloma virus. A subcutaneous injection of papilloma virus obtained from skin or genital lesions will produce a connective tissue response, with minimal proliferation of epithelium, very similar to that observed in fibropapillomas of genital surfaces. In the genitalia, the neoplastic proliferation of connective tissue is so extreme that the histologic appearance is that of a fibrosarcoma with only hyperplastic changes in the epithelium. These growths on the genitalia are benign, do not metastasize, and will regress and disappear within a period of several months. If surgical removal is attempted, the neoplasms often recur because tissue exposed during surgery is contaminated with virus.

**Macroscopic appearance.**—Fibropapillomas usually occur as single neoplasms on the mucous membranes of the penis, vulva, or vagina. These growths, which seldom measure more than 5 cm. in their greatest diameter, have a cauliflowerlike appearance and are attached to the mucous surfaces by broad bases. Most of the tumors have ulcerated surfaces, probably as the result of trauma. The cut surface is pink or grayish white and has a glistening appearance. The larger tumors may have necrotic centers.

**Microscopic appearance.**—Fibropapillomas of genital

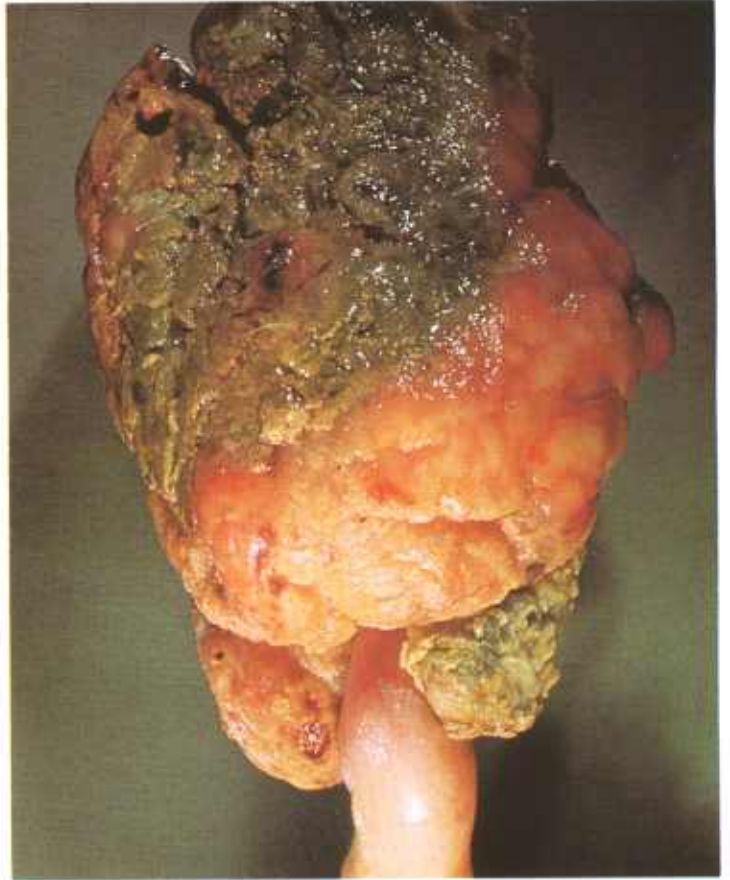

Figure 10.—External surface of an infectious fibropapilloma of the glans penis of a bull (A364-D2990). Note the necrotic external surface of the growth.

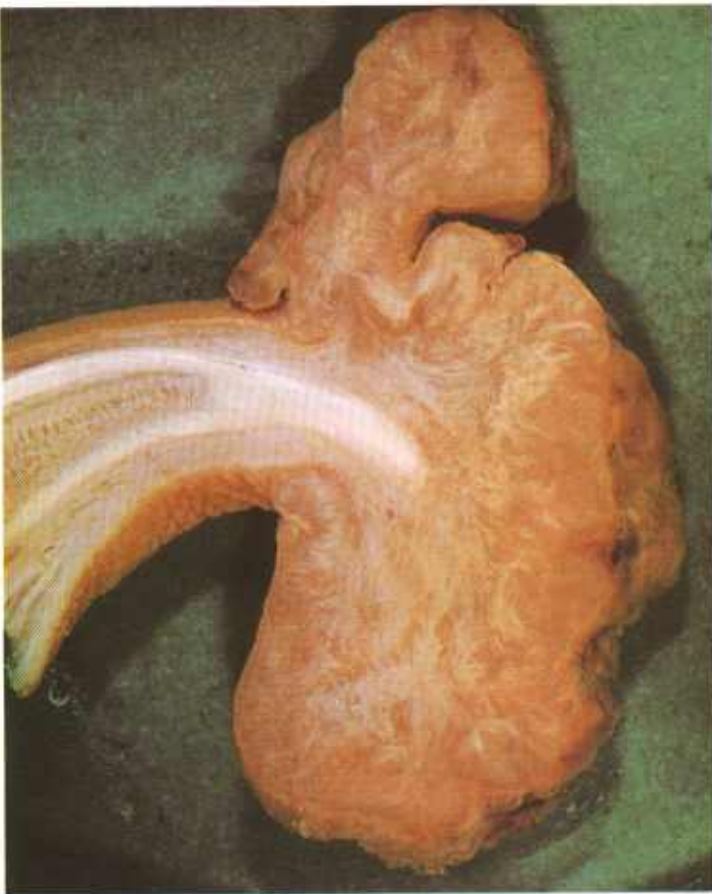


Figure 9.—Cross section of an infectious fibropapilloma of the glans penis of a bull (A90-D103). Note that the growth is compact and sclerotic and has an ulcerated surface.

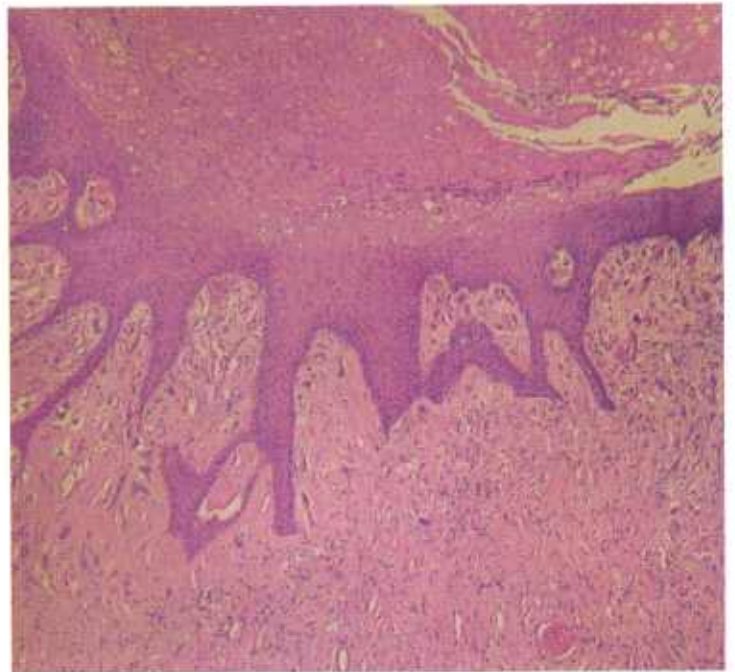

Figure 11.—Histologic preparation of an infectious fibropapilloma of the glans penis of a bull (D2990). The main mass of the tumor consists of connective tissue covered by a layer of hyperplastic epithelium that is sending long narrow projections of tumor cells into the underlying neoplastic connective tissue. Hematoxylin-eosin stain.  $\times 50$ .

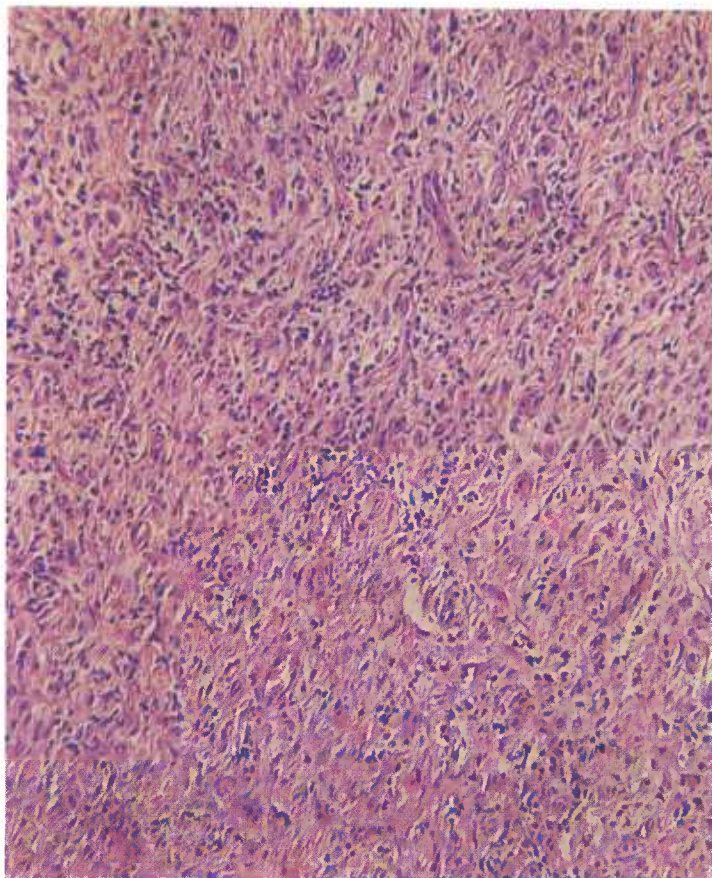


Figure 12.—Histologic preparation of the infectious fibropapilloma of the glans penis (D2990) shown in figure 10. The main mass of the tumor is composed of connective tissue infiltrated with lymphocytes. Hematoxylin-eosin stain.  $\times 125$ .

tissues consist of connective tissue covered with stratified squamous epithelium of varying thickness. Young tumors have the appearance of fibrosarcomas because the connective tissue is composed of young fibroblasts and mitotic figures are common. In older tumors the connective tissue is mature, mitotic figures are uncommon, and collagen fibers are prominent. Among the collagen fibers, however, extra large fibroblasts remain with nuclei that contain one or more glassy, lightly stained eosinophilic bodies. The connective tissue is covered with stratified squamous epithelium that is 10 to 50 cells thick. Long, narrow projections of this epithelium extend into the main connective tissue mass. Surface ulceration follows hydropic degeneration of the affected epithelial cells.

### Squamous-Cell Carcinoma

**Definition.**—A squamous-cell carcinoma is a malignant tumor of stratified squamous epithelium. Squamous-cell carcinoma of the eye will be discussed separately.

**Distribution and incidence.**—Squamous-cell carcinomas are found in meat-producing animals throughout the United States. They are most frequently observed in Hereford cattle, Ayrshire cattle, sheep, and Angora

goats. No sex predominance has been demonstrated. In the USDA's 2-year survey (see p. 1), 0.4 percent of the cattle tumors and 6 percent of the sheep tumors collected were of this type.

A defect in cutaneous pigmentation is the alteration most frequently associated with the appearance of this neoplasm. It is more common in nonpigmented or partially pigmented eyelids of Hereford cattle than in those breeds in which eyelid pigment is more abundant.

Squamous-cell carcinomas are quite common in the vulvar skin of Ayrshire cattle when pigment defects are present. When the defective vulvar skin is exposed to sunlight and, perhaps, to other irritating factors for a prolonged period, a papilloma may appear that later may become a squamous-cell carcinoma.

Squamous-cell carcinomas are often observed in the vicinity of brands, where epithelial and pigment defects are present. Apparently, prolonged irritation by sunlight and other factors causes tissue changes in the altered skin that eventually result in the appearance of a neoplasm at the site of injury.

Tumors of this type are quite common in the skin of

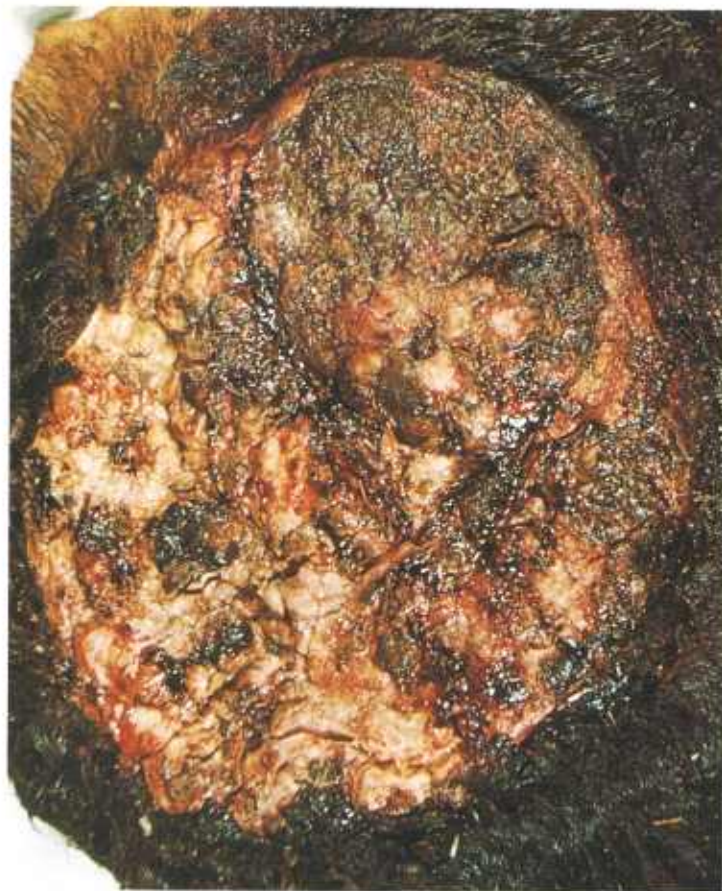

Figure 13.—Squamous-cell carcinoma of the skin of a 7-year-old Hereford cow (A387-D3151). The growth consists of a raised, ulcerated, cauliflowerlike growth in the skin of the gluteal region. A scar suggesting an old brand is present in an adjacent area of skin. The grayish-yellow growth measures 20 by 17 by 2 cm. and is infiltrating the underlying connective tissue and muscle.

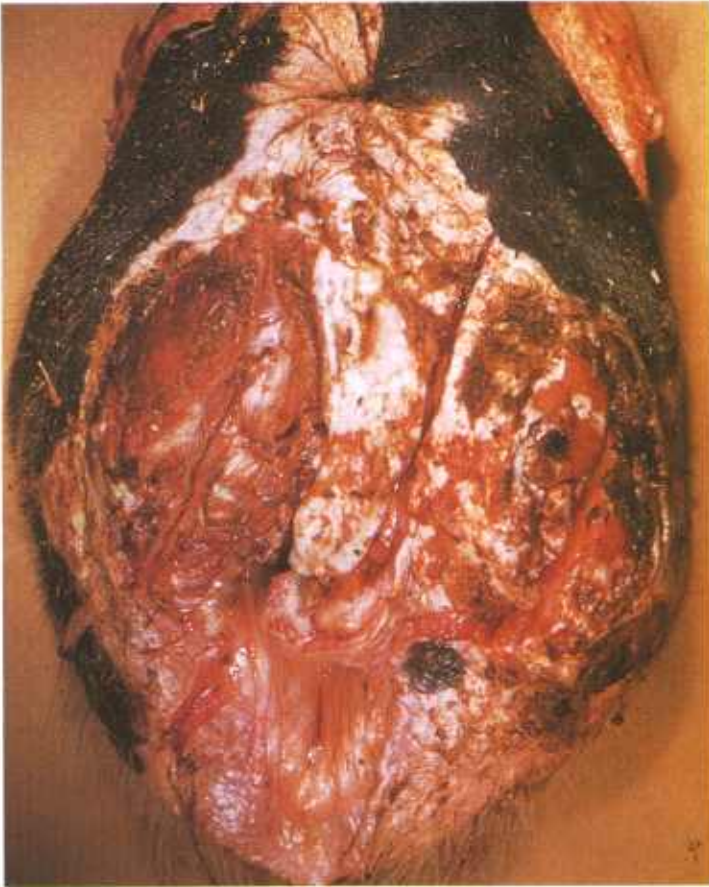


Figure 14.—Squamous-cell carcinoma of the vulva of a cow (A40-127527). Note that part of the skin in the region of the vulva is not pigmented. Ulceration of the tumor surface is present.

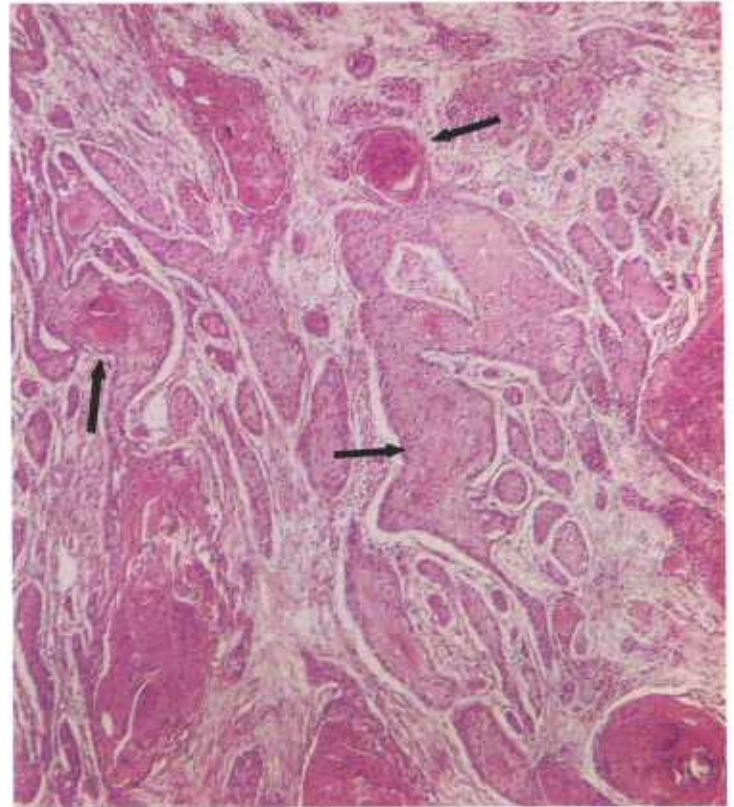


Figure 16.—Histologic appearance of the squamous-cell carcinoma (A218-D2267) shown in figure 15. As is typical of squamous-cell carcinomas, the neoplastic cells are arranged in cords, nests, or masses supported by a connective tissue stroma. Several areas of the tumor are undergoing keratinization with the formation of epithelial pearls (arrows). Hematoxylin-eosin stain.  $\times 50$ .

the frontal-parietal region of sheep in the arid regions of the Southwestern United States where the sunlight is intense. Inasmuch as many sheep affected with squamous-cell carcinomas are white faced, the lack of pigmentation of the skin may be a factor in causing the

appearance of this neoplasm, even though the skin surface is protected to some extent by wool.

Squamous-cell carcinomas of the skin are also quite common in Angora goats. They are most frequently found in the perineal, anal, and vulvar regions.

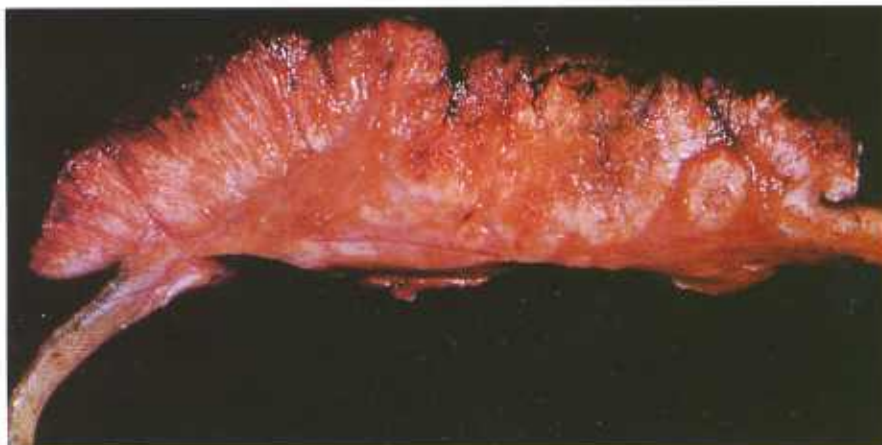

Figure 15.—A raised cauliflowerlike squamous-cell carcinoma measuring 17 by 16 by 3 cm. is present in the skin of the right hip of a 3-year-old Holstein cow (A218-D2267). The yellowish-gray, granular, papillary mass is invading the underlying connective tissue and muscle. Metastatic tumors are present in the lungs and regional lymph nodes.

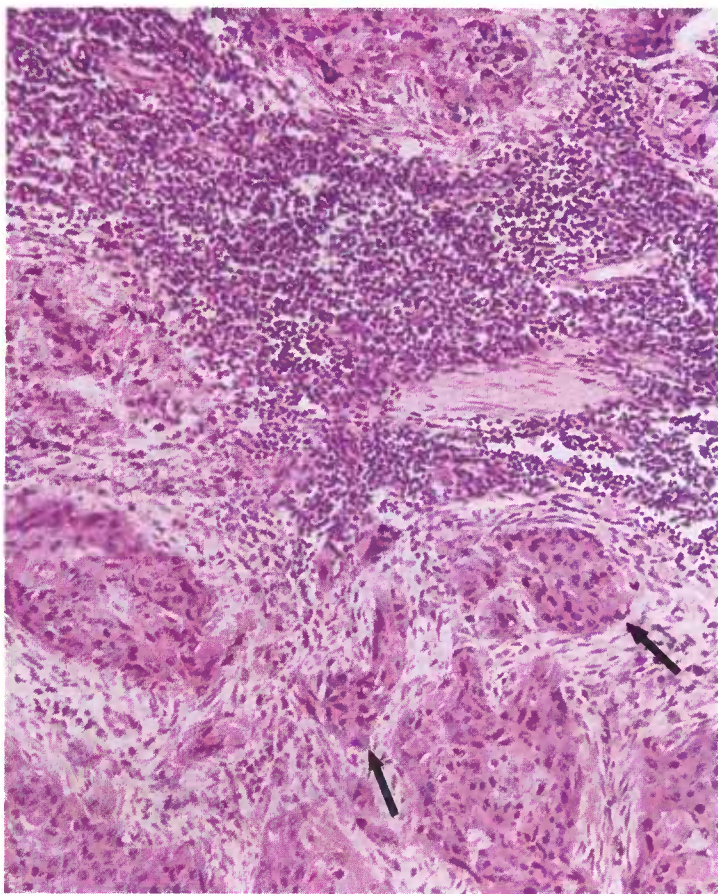


Figure 17.—Metastases (arrows) in a lymph node from the squamous-cell carcinoma (A387-D3151) shown in figure 13. Note that the neoplastic cells have a typical squamous-cell appearance. Hematoxylin-eosin stain.  $\times 125$ .

**Macroscopic appearance.**—Squamous-cell carcinomas, because of the type of cell involved, are primarily neoplasms of the skin. They are particularly common in areas where there are alterations in cutaneous pigmentation and where dry keratinized epithelium changes to a mucous membrane type. When metaplasia of columnar or transitional epithelium occurs, squamous-cell carcinomas may originate in other organs (urinary bladder, lung, upper respiratory tract).

The squamous-cell carcinoma has an invasive structure in contrast to the protrusive structure of the papilloma. If the neoplastic invasion of the underlying tissue is either extensive or rapid, or both, it is usually accompanied by necrosis. Putrefaction of the accumulated exudate and filth on the surface of the neoplasm results in a very foul odor. The amount of keratin on the surface of the tumor depends upon the rate of growth—the slower the rate of growth, the greater the amount of keratin produced.

The exposed cut surface reveals a noticeable contrast between the parenchyma and stroma. The parenchyma is arranged in nodules or cords of white, yellow, or gray homogeneous tissue interspersed with areas of hemorrhage and necrosis and separated by white fibrous bands of connective tissue. The consistency of the parenchyma

may be soft or firm and dry or moist, according to the amount of keratin present. Because of tumor metastasis and bacterial invasion, the regional lymph nodes are frequently enlarged.

**Microscopic appearance.**—The basic cell type of the squamous-cell carcinoma is the squamous epithelial cell of the skin. The neoplastic cells of the carcinomas of low malignancy resemble the cells of the stratum germinativum or the prickle-cell layer of the normal epidermis, whereas the cells of the highly malignant tumors are often of the undifferentiated embryonal cell type. According to the degree of malignancy, all gradations of cell differentiation between these two cell types may be found in the same neoplasm.

The neoplastic cells are arranged in cords or nests with the growing as well as the most embryonal cells adjacent to the supporting connective tissue stroma where nutrient is obtained. As the neoplasm grows, those cells farthest from the source of nutrient in the center of the cord or nest undergo keratinization and produce structures known as epithelial pearls. The nuclei of many of the neoplastic cells contain a large

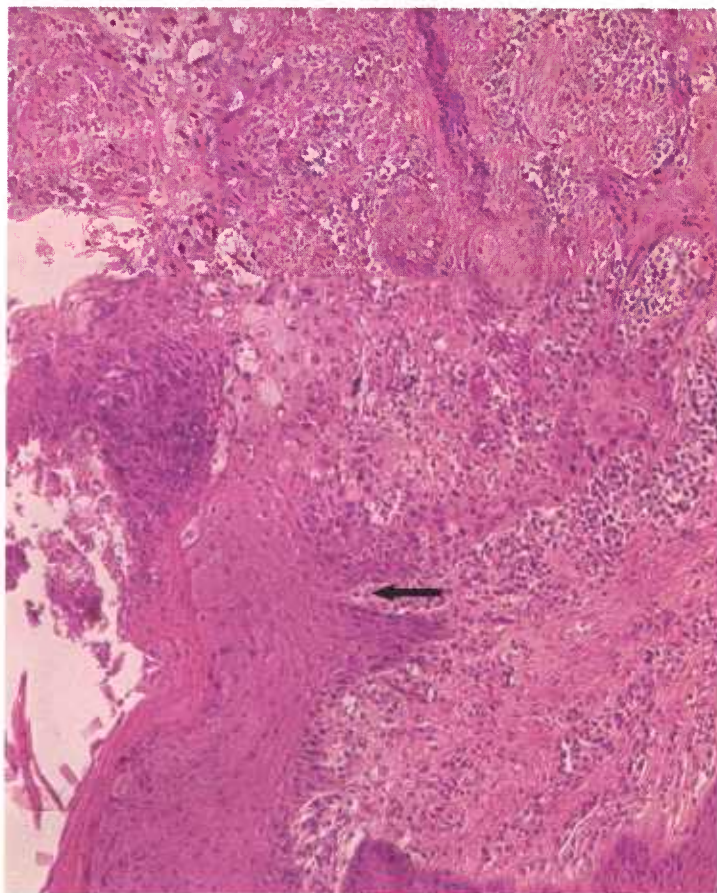


Figure 18.—Histologic preparation of a squamous-cell carcinoma of the vulva of an old ewe (D3180). The neoplasm consists of a red, rugose, polypoid mass measuring 9 by 5 by 1 cm. Metastases are present in the regional lymph nodes. The arrow indicates the point where the hyperplastic epithelium changes to a neoplastic squamous-cell type of tissue. Hematoxylin-eosin stain.  $\times 125$ .

nucleolus. Numerous mitotic figures are present in the more malignant neoplasms. Malignant cells are not limited to the epidermis or mucosa but also infiltrate the underlying tissues. These infiltrating cells grow at random in the direction of least tissue resistance. In very rapidly growing neoplasms, proliferating cells occur in large groups and are supported by very little stroma. Individual groups of cells in slower growing tumors are separated from one another by strands or sheets of stroma. This cellular arrangement differs from that found in sarcomas, where the parenchyma and stroma are intermingled. Chronic inflammation and bacterial invasion accompany neoplastic invasion.

## Neoplasms of the Eye

### *Corneal dermoid in cattle*

**Definition.**—Corneal dermoids are disturbances in development in which growths consisting of stratified squamous epithelium, sebaceous glands, and hair appear on the cornea.

**Distribution and incidence.**—Corneal dermoids are found throughout the United States. Breed and sex predominance have not been determined. Most of the dermoids we have observed have occurred in the Hereford breed of cattle. Four corneal dermoids were found among the 722 bovine ocular tumors collected during the course of the 2-year survey conducted by the USDA in Denver (see p. 1).

**Macroscopic appearance.**—Corneal dermoids are found at the limbus of the eyeball. One or both eyes may be affected. The appearance of the new growth is that of a piece of skin transplanted onto the surface of the eyeball. Corneal dermoids may have the thickness and texture of normal skin. Hair protrudes from their external surface. They are round or elliptical and may measure as much as 2 cm. in diameter and 1 cm. in thickness.

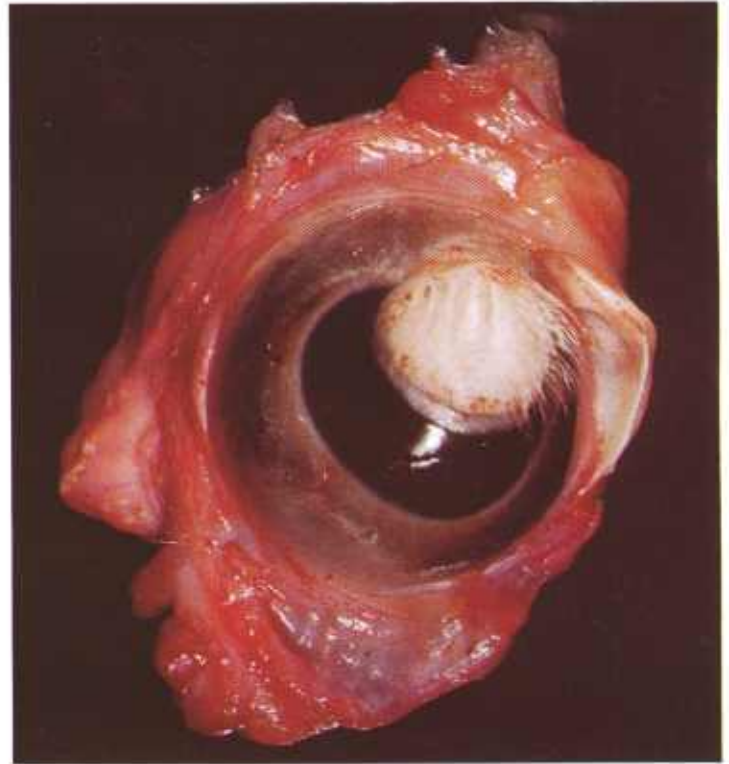


Figure 19.—Unilateral corneal dermoid in the eye of a 2-year-old Hereford steer (E125-D2418). Hair is growing from the surface of the growth.

Since the larger growths extend to the center of the cornea, some impairment of sight may occur. Keratitis and conjunctivitis are often present because of the mechanical irritation produced by the mass and its protruding hair.

**Microscopic appearance.**—The histologic appearance of the corneal dermoid is that of normal skin with sebaceous glands, hair follicles, and hair. Growth is confined to the surface of the cornea and sclera and no invasion

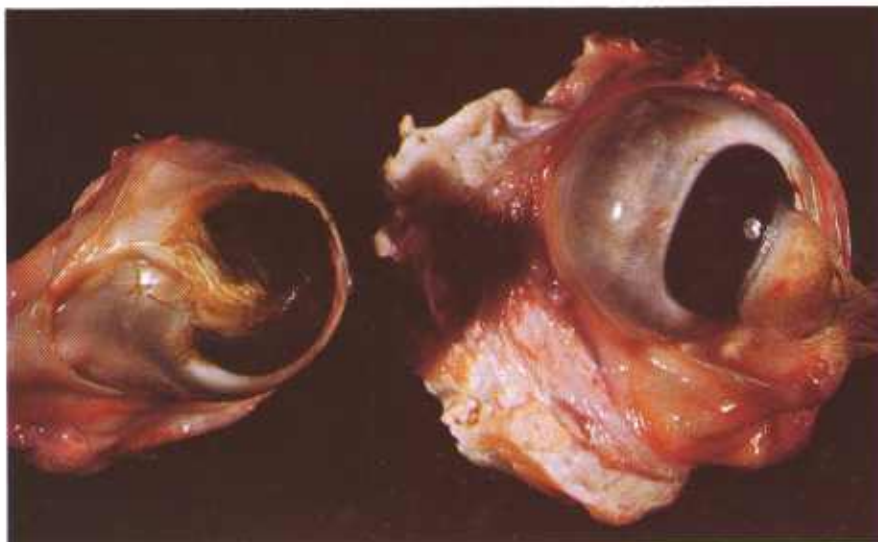


Figure 20.—Bilateral corneal dermoids in the eyes of an old Hereford cow (E162-131562).

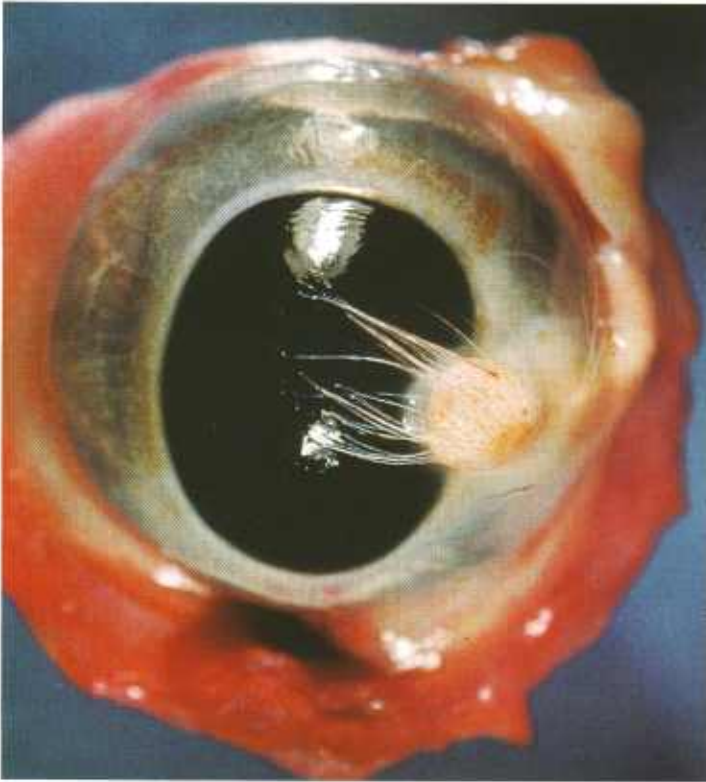


Figure 21.—Unilateral corneal dermoid measuring 20 by 20 by 10 mm. in the eye of a 2-year-old Hereford steer (E161-131408). The growth is located at the inner canthus of the eye.

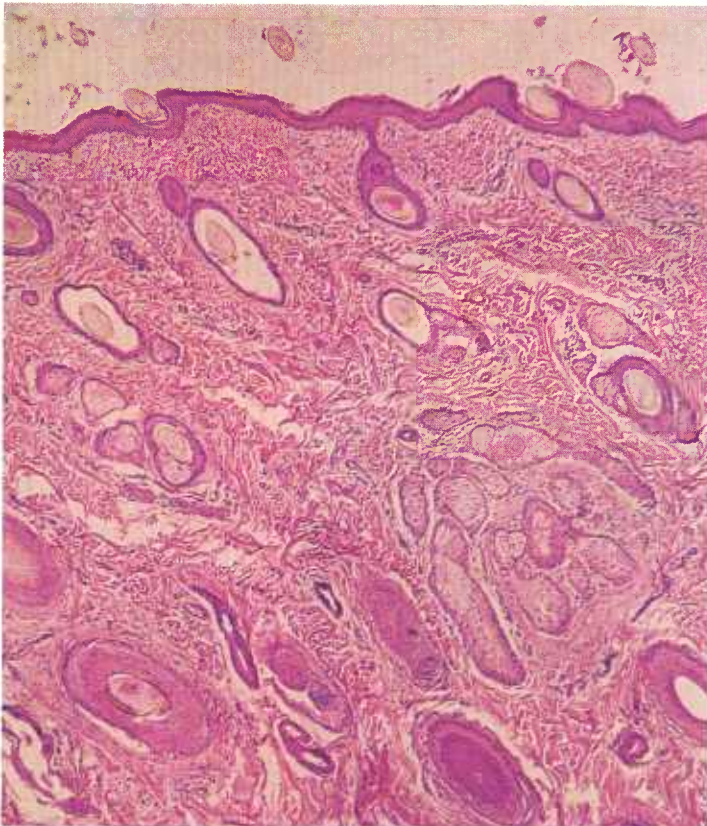


Figure 22.—Histologic preparation of the corneal dermoid (E161-131408) shown in figure 21. Note that all skin structures (epithelium, hair, hair follicles, and sebaceous glands) are present. Hematoxylin-eosin stain.  $\times 50$ .

of underlying structures occurs. Corneal dermoids are considered to be disturbances of development and are not neoplastic.

#### *Epidermal papilloma of the eye of cattle*

**Definition.**—Epidermal papillomas are benign, papillary, epithelial outgrowths from the cornea, bulbar conjunctiva, and adjacent skin. They are considered to be premalignant stages of squamous-cell carcinoma of the eye of cattle.

**Distribution and incidence.**—Epidermal papillomas are found throughout the United States but are most commonly observed in cattle on the western ranges, where they are particularly common in Hereford cattle. During the USDA's 2-year survey (see p. 1), 5 percent of the tumors collected were epidermal papillomas of the eye.

**Macroscopic appearance.**—Epidermal papillomas are most frequently located at the corneal-scleral junction. They are yellowish white and irregularly shaped, and they consist of stalks, spines, or rounded protuberances that contain a central core of connective tissue covered to varying depths by tumefied epithelium.

**Microscopic appearance.**—Epidermal papillomas have a marked hyperkeratosis and parakeratosis of the stratum corneum. At least one projection of this cornified epithelium equals or exceeds the average height of the remainder of tumefied epithelium in these growths.

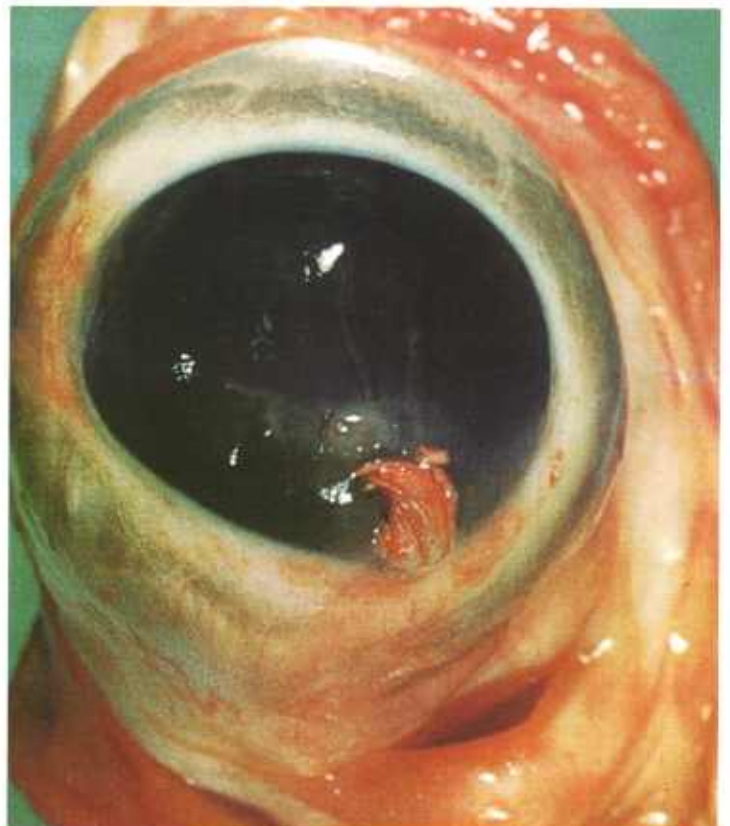


Figure 23.—Epidermal papilloma of the eye in a 6-year-old Hereford cow (A334-131336). The tumor has a 3- by 3-mm. base at the limbus. Papillary projections from this point of attachment are 1 to 10 mm. in length.

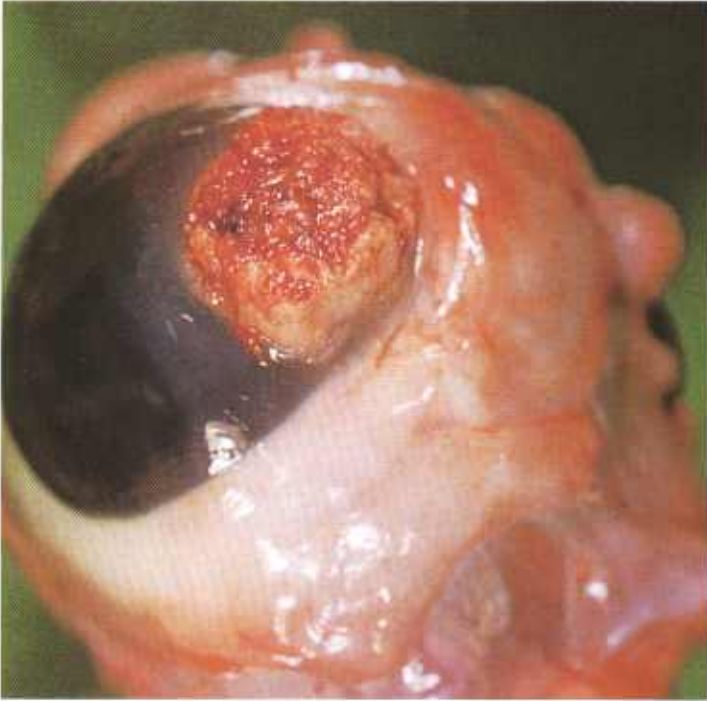

Figure 24.—Epidermal papilloma (15 by 10 by 4 mm.) of the eye of a 6-year-old Guernsey cow (A225-D2289).

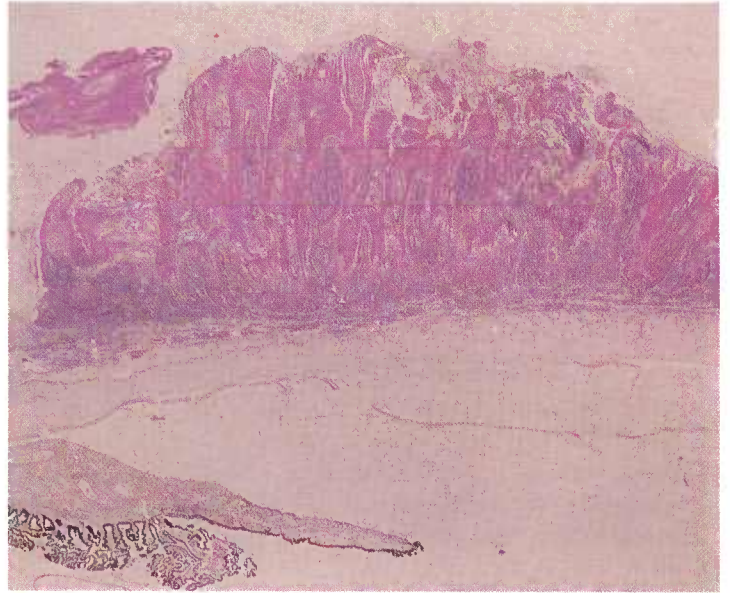


Figure 26.—An epidermal papilloma (A225-D2289) that has deep indentations of cornified neoplastic epithelium around central connective tissue cores. The gross appearance of this growth is illustrated in figure 24. Hematoxylin-eosin stain.  $\times 8$ .

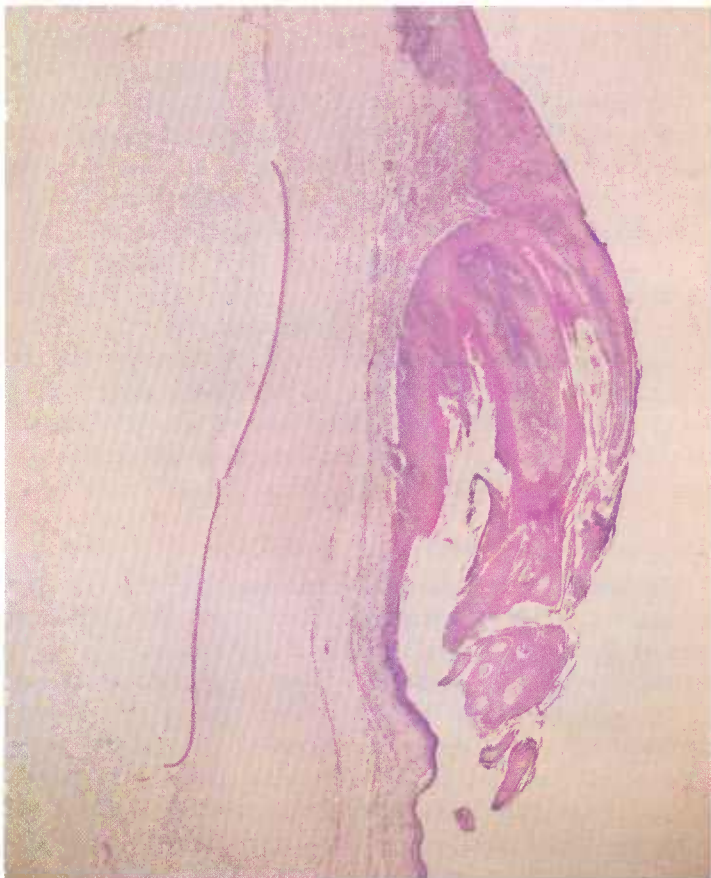

Figure 25.—Histologic appearance of the epidermal papilloma (A334-131336) shown in figure 23. There is no neoplastic infiltration of the underlying tissues, the growth projects as spine-like structures with central connective tissue cores, and the surface is covered by stratified squamous epithelium having marked hyperkeratosis and parakeratosis of the stratum corneum. Hematoxylin-eosin stain.  $\times 15$ .

Bowman's membrane of the cornea may appear thin and may even disappear in places where there are corneal papillomas, but there is always an acceptable basal line to the tumefied epithelium of either the cornea or conjunctiva. Dyskeratotic changes such as hyperchromatism may occur in the epithelium and are more common than corresponding changes in epidermal plaques. Small intradermal nests of anaplastic cells (carcinoma

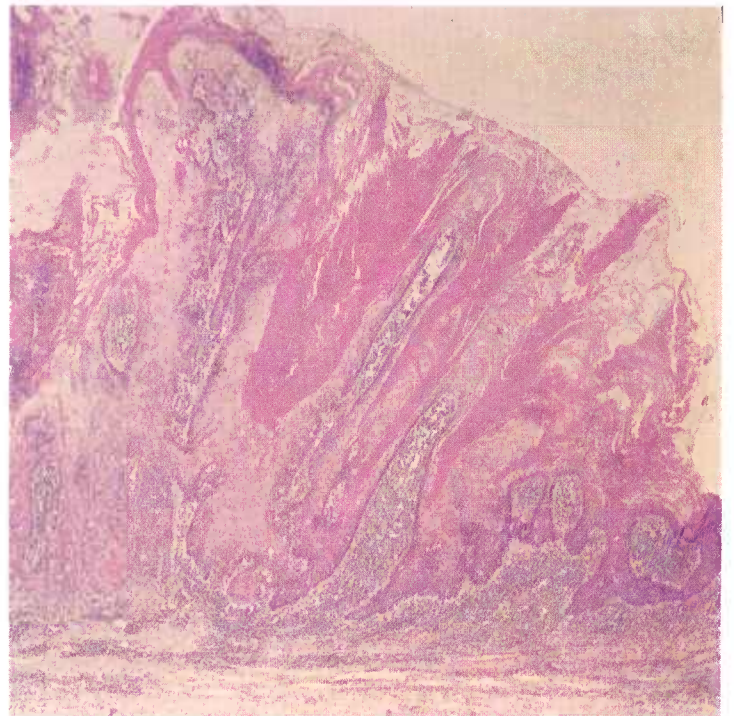


Figure 27.—A higher magnification of the epidermal papilloma (A225-D2289) shown in figure 26. Hematoxylin-eosin stain.  $\times 20$ .

in situ) may appear in the tumors; these may occur singly or may be found in several areas. When present, they may exhibit such cellular phenomena as increased numbers of mitotic figures, enlargement of nuclei and nucleoli to form giant or sometimes double nuclei, pronounced variation in size and shape of individual cells, and presence of small, isolated cornified bodies (epithelial pearls). Subepithelial inflammatory reactions may be marked, and there may be a pseudoepitheliomatous hyperplasia with great enlargement of rete pegs.

### *Epidermal plaque of the eye of cattle*

**Definition.**—An epidermal plaque is a thickening of the epithelium of the cornea, bulbar conjunctiva, and adjacent skin. It is considered to be a premalignant stage of squamous-cell carcinoma of the eye of cattle.

**Distribution and incidence.**—Epidermal plaques are found in cattle and occasionally in other genera of animals throughout the United States but are most common on the western ranges, where they occur predominantly in Hereford cattle. During the USDA's 2-year survey, mentioned on page 1, 10 percent of the tumors collected were epidermal plaques of the eye.

**Macroscopic appearance.**—The epidermal plaque appears as a raised, irregular shaped, yellowish-white, opaque mass usually located at the corneal-scleral junction. One or both eyes may be involved. The surface is relatively smooth and is not ulcerated, and it does not possess papillary outgrowths from its surface. Secondary inflammatory alterations are usually minimal.

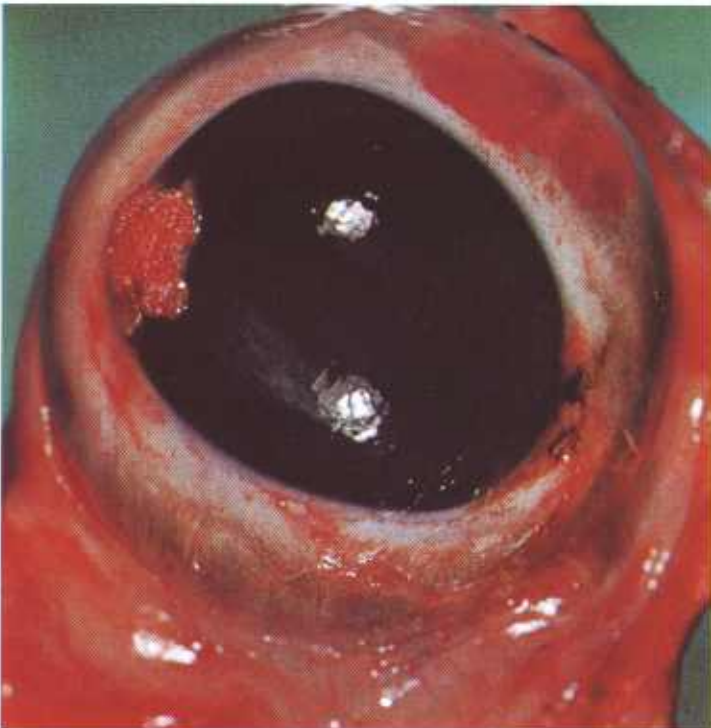

Figure 28.—An epidermal plaque on the cornea and bulbar conjunctiva of a 6-year-old Hereford cow (D2202). The plaque covers an 8- by 10-mm. area.



Figure 29.—A histologic preparation of the epidermal plaque (D2202) shown in figure 28. Note the characteristic thickening of the prickle-cell layer of the epithelium. Hematoxylin-eosin stain.  $\times 10$ .

**Microscopic appearance.**—In epidermal plaques, the epithelium is at least two times its normal thickness because the prickle-cell layers proliferate until they exceed the average height of the rest of the tumefied epithelium.

The growths do not have papillary surfaces, but inward growths of the tumors may occasionally cause islands of connective tissue to form that resemble the connective tissue cores of papillomas. Although Bowman's membrane of the cornea may appear thin and may even disappear where there are corneal plaques, there is always an acceptable base line to the tumefied epithelium of either the cornea or conjunctiva. Dyskeratotic changes such as hyperchromatism may occur in the thickened epithelium but are usually limited to individual cells. Formation of anaplastic cells within the growths is rare. Subepithelial inflammatory reactions may be marked and there may be a pseudoepitheliomatous hyperplasia with great enlargement of rete pegs.

### *Squamous-cell carcinoma of the eye of cattle*

**Definition.**—Squamous-cell carcinoma of the eye is a malignant tumor originating from squamous epithelial cells of the eyeball, eyelid, and adjacent skin.

**Distribution and incidence.**—Squamous-cell carcinoma of the eye of cattle is found throughout the United States but is most frequently observed in western range country where there is a predominance of the Hereford breed. The tumor is seen most frequently in Hereford cattle and less commonly in other beef and dairy breeds, with the exception of the Aberdeen Angus breed. No examples of this type of tumor removed from Aberdeen Angus cattle have been submitted to the Denver laboratory. A similar tumor is occasionally observed in sheep and horses but is seldom found in swine. Among the tumors collected during the USDA's 2-year survey of

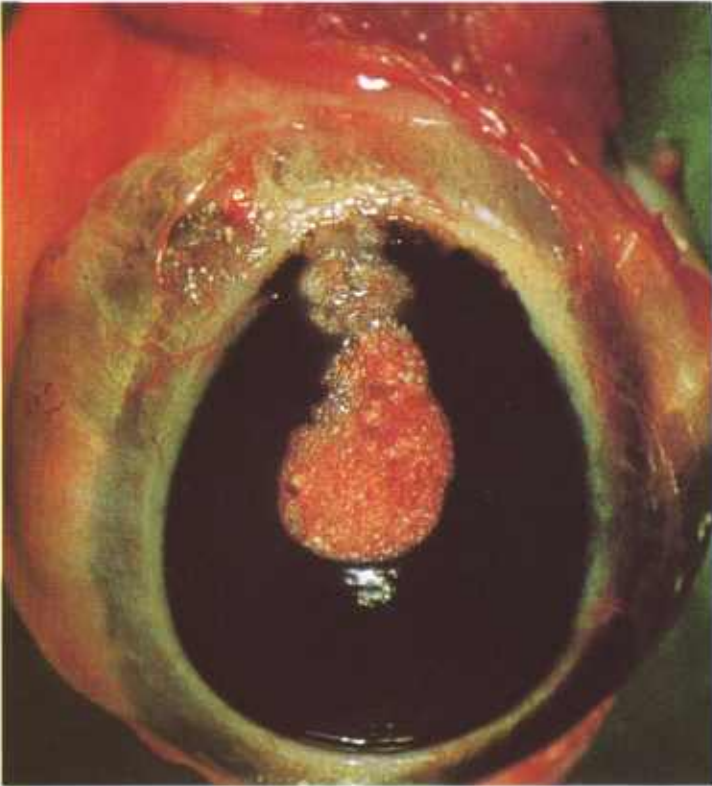

Figure 30.—A squamous-cell carcinoma of the eye in a 9-year-old Hereford bull (A211-D2237). Histologically, the cornea is invaded near the limbus.

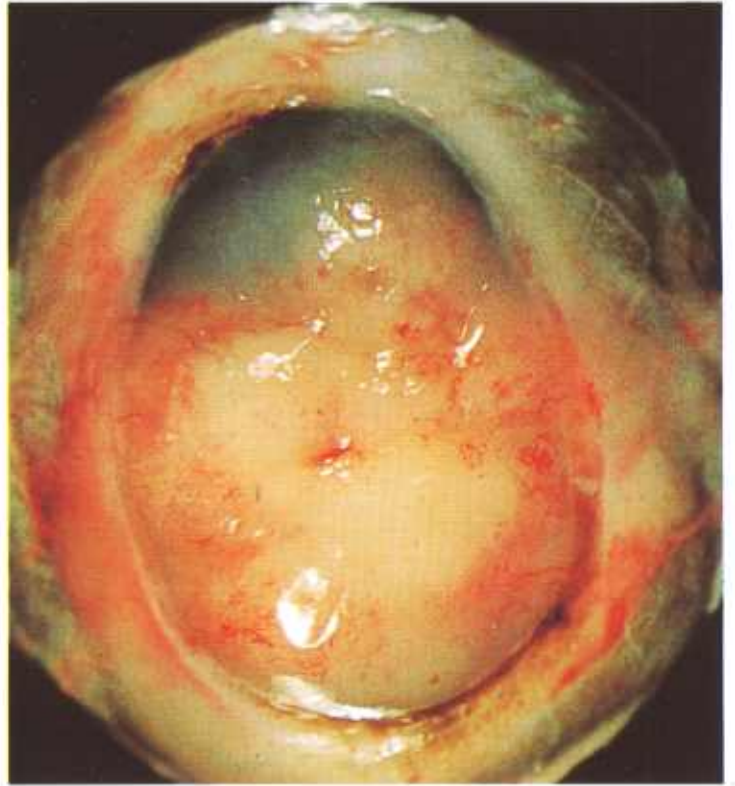


Figure 32.—A squamous-cell carcinoma that has extended under the still-intact corneal epithelium of the eye of an old Hereford cow (A321-131808). The point of origin of the tumor was not determined.

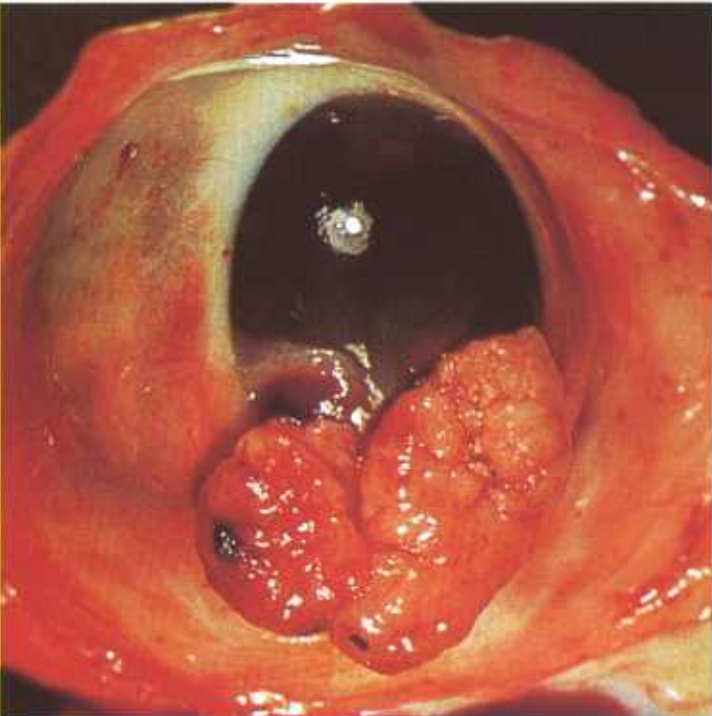


Figure 31.—Squamous-cell carcinoma of the eye of an old cow (A216-D2263). Both of the cow's eyes contain a squamous-cell carcinoma. The growth consists of a large, protruding, polypoid mass (30 by 15 by 10 mm.) attached by a small base (5 by 3 mm.) at the corneal scleral junction. Fingerlike projections (not visible) of squamous cells containing many mitotic figures are invading the underlying tissue at the base of the tumor.

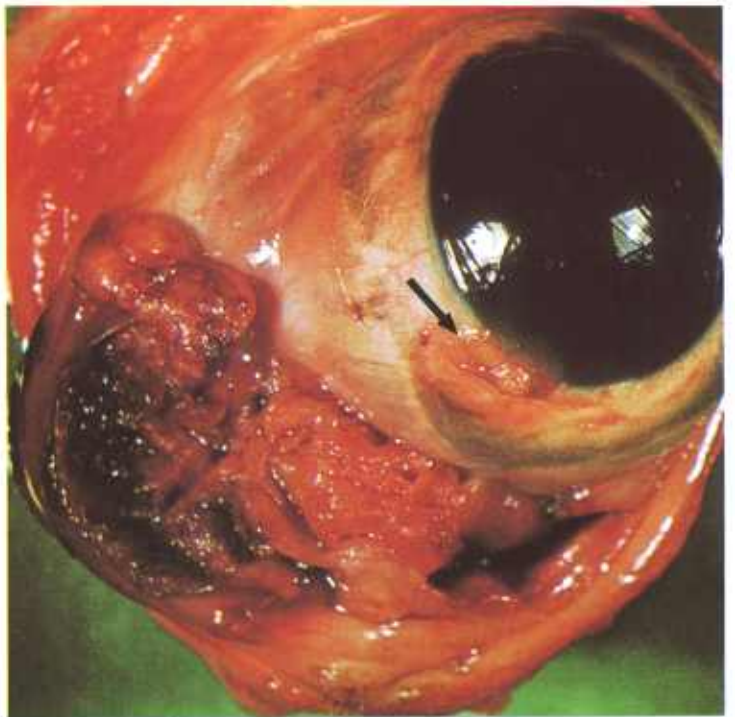


Figure 33.—A large ulcerating squamous-cell carcinoma (4 by 2 by 1 cm.) that almost replaces the membrana nictitans of an 8-year-old cow (A206-D2191). A small early squamous-cell carcinoma (arrow) measuring 7 by 3 by 1 mm. is also present at the limbus.

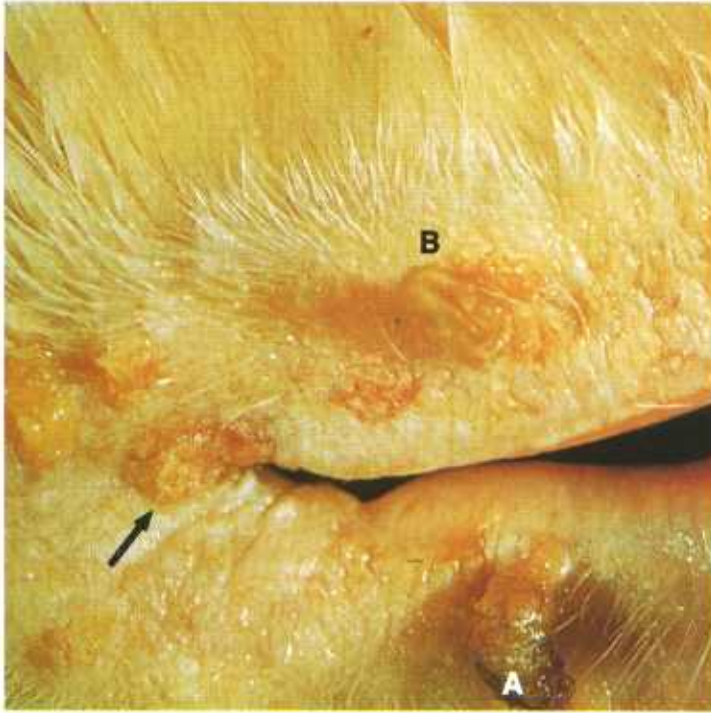


Figure 34.—Squamous-cell carcinoma (arrow) at the lateral canthus of the eyelid in an old Hereford cow (A324-131788). A large papillary tumor (A) on the lower eyelid is an early squamous-cell carcinoma. The smaller growth (B) above it on the upper eyelid is a papilloma.

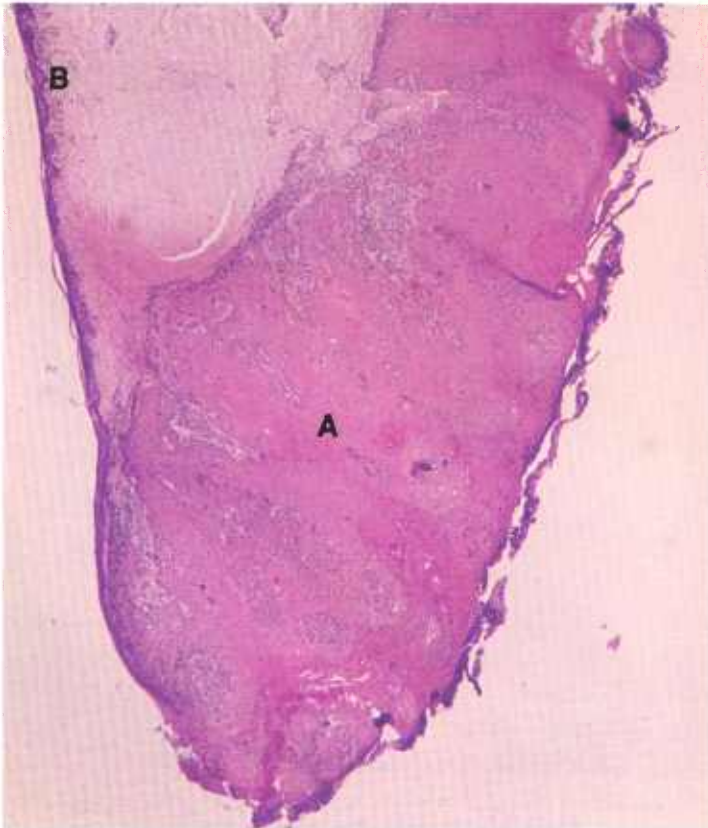

Figure 35.—Squamous-cell carcinoma of the membrana nictitans in a 6-year-old Hereford cow (131428). Note the extreme thickening of the tumefied epithelium (A) in comparison with the normal epithelium (B). Hematoxylin-eosin stain.  $\times 20$ .

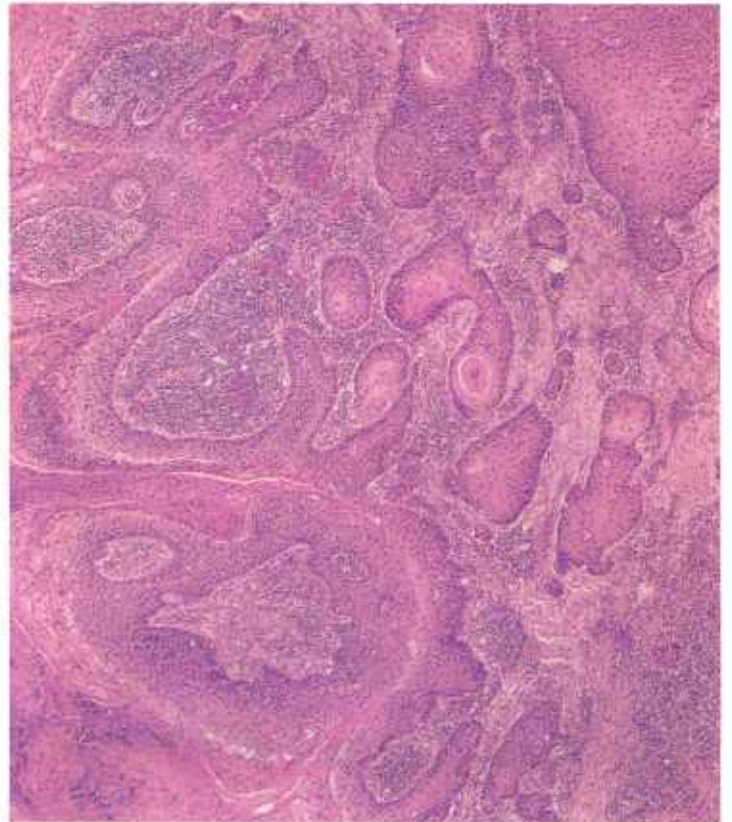


Figure 36.—A histologic preparation of the squamous-cell carcinoma of the eyelid (A324-131788) shown in figure 34. An acceptable basal line to the tumefied epithelium is not present and nests of tumor cells are located within the substantia propria of the conjunctiva. Hematoxylin-eosin stain.  $\times 50$ .

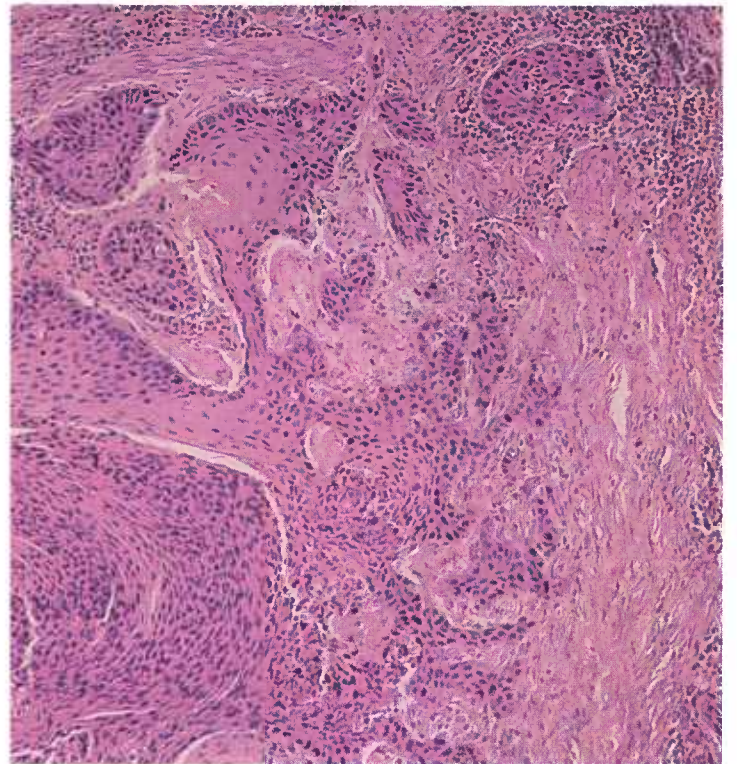


Figure 37.—A higher magnification of the neoplasm (A324-131788) shown in figure 36. Hematoxylin-eosin stain.  $\times 125$ .

neoplasms found in Denver abattoirs (see p. 1), 62 percent were squamous-cell carcinomas of the eye, 4 percent were early squamous-cell carcinomas, 10 percent were premalignant stages of epidermal plaques, and 5 percent were premalignant stages of epidermal papillomas.

**Macroscopic appearance.**—Squamous-cell carcinomas of the eye are found at the corneal-bulbar conjunctival junction in over 50 percent of the affected animals. These neoplasms appear as progressively expanding growths with superficial surfaces that frequently ulcerate. They often spread across the surface of the cornea and extend into the scleral and periocular tissues, but only rarely invade the anterior chamber of the eye.

Tumors of the eyeball metastasize, primarily by way of the lymph vessels, only after a long period of progressive growth. Metastases are most frequently observed in the parotid lymph nodes and the lungs.

Tumors arising on the nictitating membrane, eyelids, or adjacent skin are similar in appearance to the ocular growths but tend to ulcerate earlier and metastasize much sooner than tumors of the eyeball.

**Microscopic appearance.**—The general microscopic appearance of this ocular tumor is similar to that of other squamous-cell carcinomas of the skin.

*Early squamous-cell carcinoma.* Nests of neoplastic cells at the base of an epithelial eye tumor apparently break through the basal cell layer of the tumefied epithelium and invade the underlying tissues. These nests of rounded subconjunctival groups of rather ana-

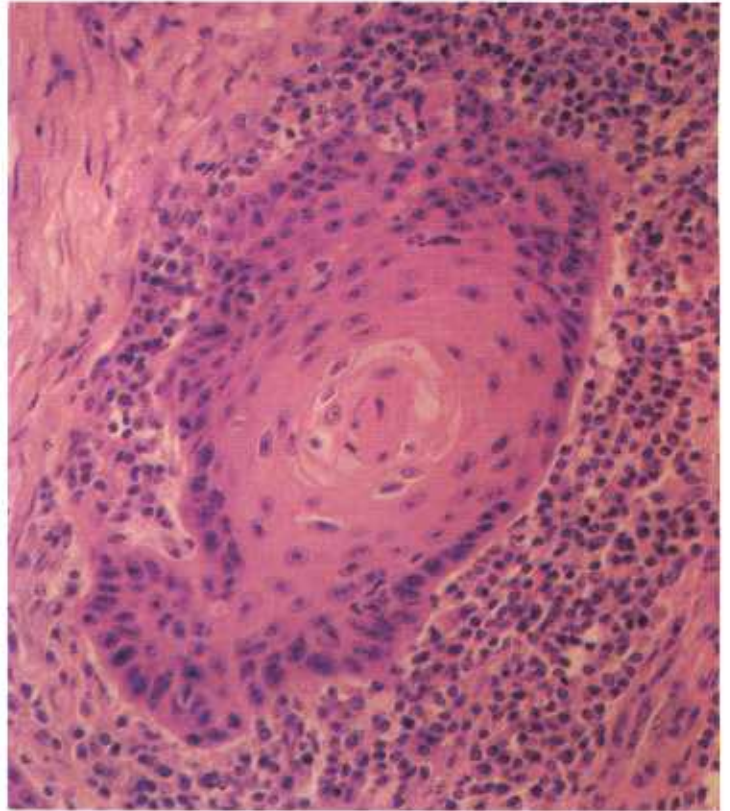


Figure 38.—A developing epithelial pearl in a nest of neoplastic cells in the squamous-cell carcinoma (A324-131788) shown in figure 36. The formation of epithelial pearls is a common histologic alteration in squamous-cell carcinomas. Hematoxylin-eosin stain.  $\times 320$ .

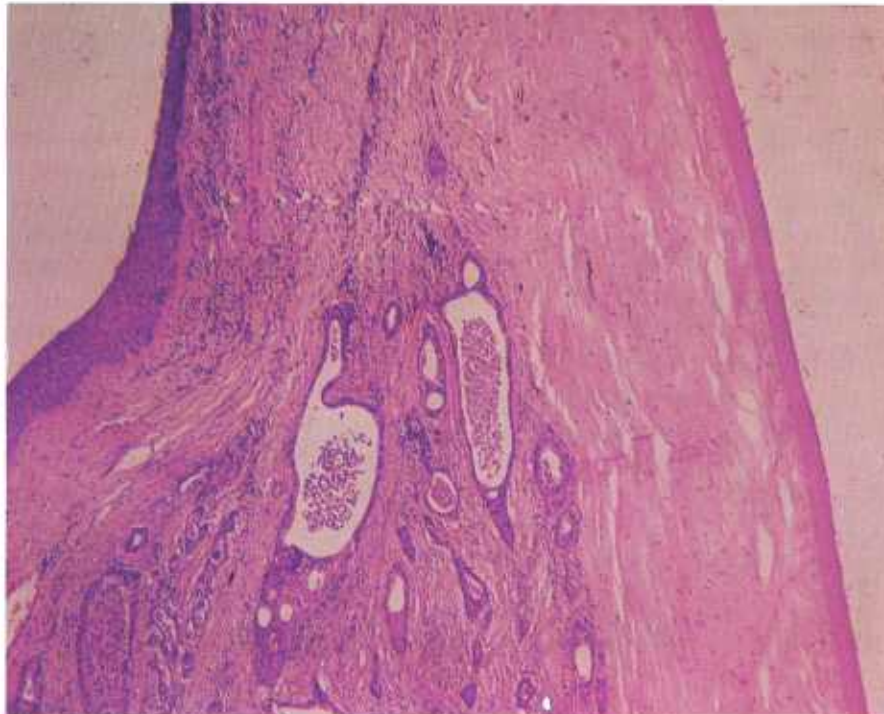


Figure 39.—A squamous-cell carcinoma that is invading laterally between the corneal epithelium and Descemet's membrane in a mature Hereford cow (131798). The tumor cells are invading within the lumens of the lymphatics. Hematoxylin-eosin stain.  $\times 50$ .

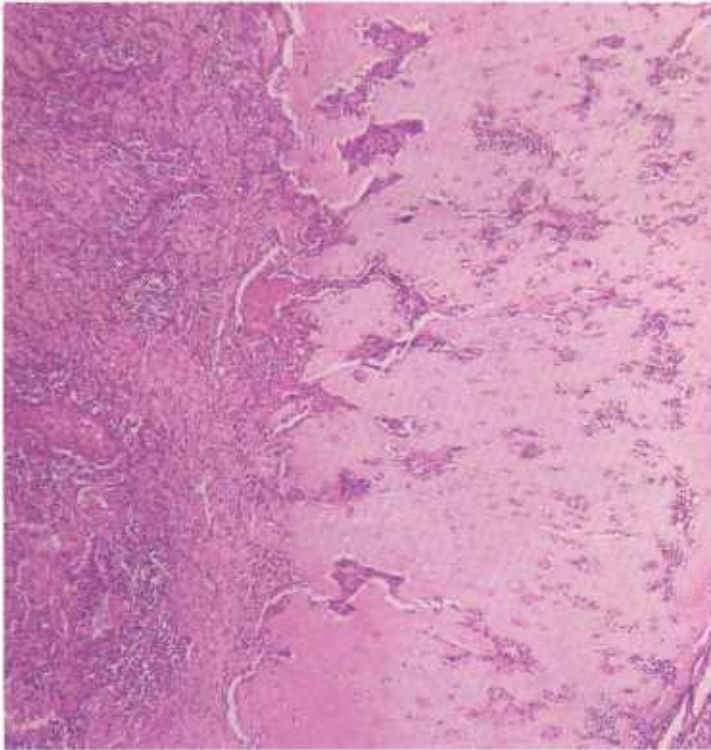


Figure 40.—Invasion of the cartilage of the membrana nictitans by a squamous-cell carcinoma in an old Hereford cow (131783). Hematoxylin-eosin stain.  $\times 50$ .

plastic cells often have a central cornified center (sometimes advanced enough to be a classic epithelial pearl). If the tumor is on the cornea, the underlying Bowman's membrane is no longer intact or may have completely disappeared. Except for the carcinomatous changes in its basal area, the tumor may resemble a plaque or papilloma. However, when compared with papillomas, most early carcinomas have a much greater tendency to form intradermal nests of anaplastic cells. Further, it is not uncommon for large areas of the basal cell layer of the tumefied epithelium to be replaced by these nests of anaplastic cells. Most of the invasive carcinomatous groups of cells still maintain intercellular bridges (prickles), particularly when there is cornification of their centers.

Occasionally, spindling of small groups of neoplastic cells is seen. In these areas the cytoplasmic bridges are absent and the cells may be difficult to differentiate from those of a reticulum-cell sarcoma or from the macrophages invariably present as a component of a secondary tissue reaction. There may be a marked pseudoepitheliomatous hyperplasia with greatly enlarged or

elongated rete pegs in basal parts of the growths adjacent to the invasive areas. The rete pegs usually have slender, tapering projections that contrast with the rounded, invasive, neoplastic masses of cells that most characteristically distinguish an early carcinoma. The hyperplastic rete pegs may have a distinctive basal cell perimeter that can often be recognized, even if the plane of the section results in the rete pegs appearing as a single group of cells or as several isolated groups of cells.

Subepithelial inflammatory reactions are prominent and include infiltrations of lymphocytes, plasma cells, fibroblasts, and macrophages, and increased vascularization and fibrosis of the substantia propria of the cornea and conjunctiva. Although the substantia propria of the cornea is normally almost devoid of blood vessels and lymphatics, these vessels increase rapidly in number in the subepithelial tissues, apparently in direct relation to the degree of irritation produced by the growing tumor.

*Late squamous-cell carcinoma.* Whereas the tumors classed as early squamous-cell carcinomas are distinguished by what is considered to be one or more initial carcinomatous invasive growths into the substantia propria, fully developed carcinomas include all eye tumors that have secondary or more advanced outgrowths from the invaded areas.

There may be a deep invasion through the substantia propria of the cornea to Descemet's membrane; there may be lateral invasion under intact corneal, conjunctival, or cutaneous epithelium; or there may be a reversed invasion through the tumefied epithelium (probably responsible for many of the ulcerating, necrotic surfaces). In the more highly differentiated carcinomas, multiple epithelial pearls may be found, and it is not unusual for individual pearls to reach a size so large that they replace half of the normal depth of the cornea. Anaplasia and other malignant changes are advanced. Some groups of epithelial tumor cells may be fusiform and others may be found in extremely cellular arrangements with indistinct cytoplasmic boundaries. Mitotic activity and formation of giant, double, or lobed nuclei usually increase in crude proportion to the malignancy of the tumor. A few tumors show definite neoplastic glandular formations in parts of their structure: thus, an origin in or near glands associated with the eye has been postulated. Scattered areas of necrosis are common in the larger tumors. In the more malignant tumors, invasion of veins or lymphatics may be demonstrable, as well as metastasis to lymph nodes or body organs.

## Glandular Epithelial Tumors

### Adenoma

**Definition.**—An adenoma is a benign tumor of glandular epithelium.

**Distribution and incidence.**—Adenomas are found in all meat-producing animals throughout the United

States. There seems to be no favored organ for their location. No generic, species, breed, or sex predominance has been established. They are more common in older animals.

**Macroscopic appearance.**—The gross appearance of

adenomas varies considerably according to their location and the tissues from which they arise. In parenchymatous organs they are usually sharply circumscribed and encapsulated. In hollow organs such as the stomach and intestine, they protrude into the lumen and may become polypoid in shape. They are then designated as polypoid adenomas or adenomatous polyps. A diffuse polypoid adenomatosis of the large intestine of swine is occasionally seen.

**Microscopic appearance.**—Adenomas may be sharply circumscribed, standing out clearly from the surrounding tissue, or they may look so much like the gland from which they originated that the difference between the tumor and normal tissue can scarcely be distinguished. Although the amount of glandular tissue may be far in excess of normal and the acini may be lined with more than one layer of cells, it is important to note that the proliferating epithelium is contained within its basement membrane. The secretions of an adenoma are sometimes retained in the acini, causing the acini to become extremely distended and their epithelium to atrophy. When this occurs, the tumors are designated as cystadenomas. Tumors of this type are most commonly found in the thyroid gland. Occasionally, the proliferating epithelium may push into the lumen of the acini and take the form of branching papillae. It is then identified as a papillary adenoma. Adenomas are always potentially dangerous since some become malignant and infiltrate surrounding tissues or metastasize to distant organs.

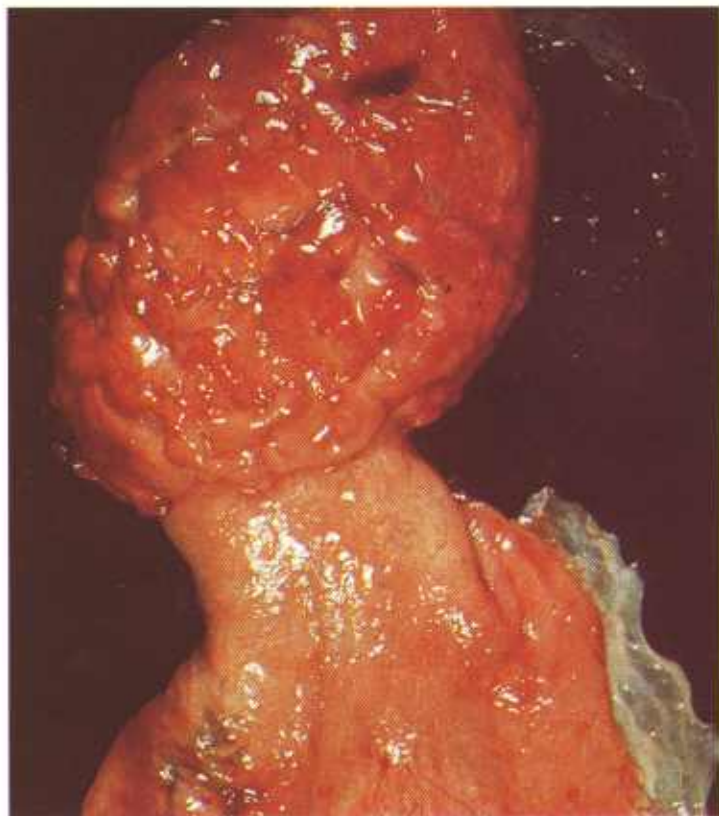


Figure 41.—Adenoma of the gallbladder of an old Hereford bull (A307-D2735). A yellowish-pink, papillary, rugose mass (10 by 7 by 3 cm.) is growing from the mucous membrane of the fundic end of the gallbladder. No invasion of the underlying tissues has occurred.

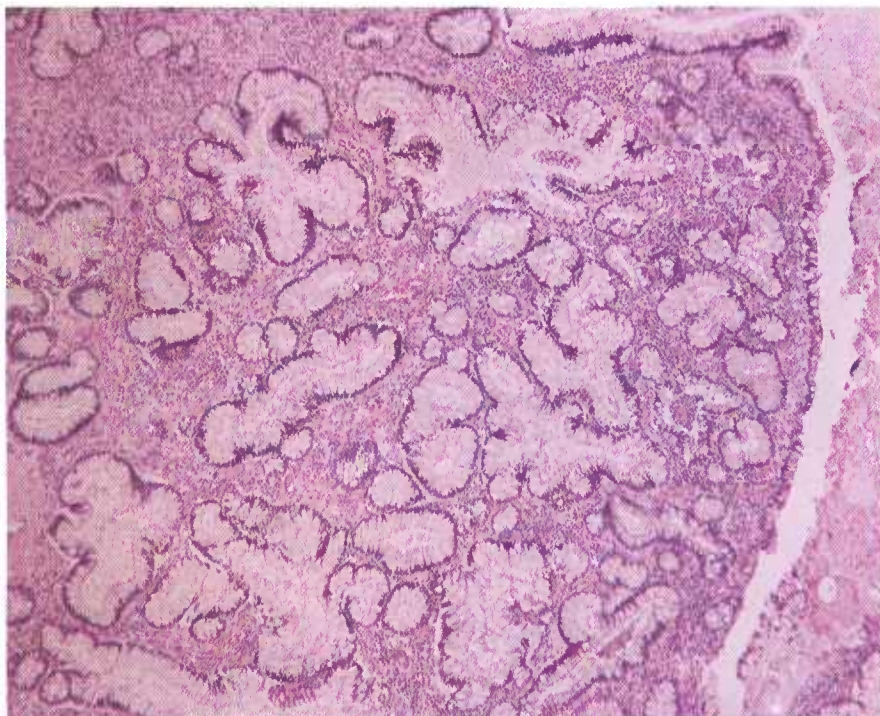


Figure 42.—Papillary cystadenoma of the urinary bladder of an old cow (D1129). The tumor consists of a large pedunculated mass that is protruding into the lumen of the bladder. The growth weighs 3 pounds and contains multiple cysts filled with mucus. No invasion of the wall of the urinary bladder or the regional lymph nodes has occurred. Hematoxylin-eosin stain.  $\times 50$ .

The cells of an adenoma are very similar to the cells from which they originated and show none of the embryonal characteristics observed in the cells of malignant tumors. The nuclei of the adenoma are normal in appearance or are only slightly enlarged; in fact, they are so similar to the nuclei of normal cells that the two types can scarcely be distinguished. Multinucleated cells are uncommon in adenomas, in contrast to the numerous multinucleated cells or giant cells present in malignant neoplasms. Mitotic figures are few and are usually no more evident than in normal tissue. The cells stain normally and do not show the hyperchromasia of malignant cells. Some adenomas show slight degenerative changes (cloudy swelling, fatty degeneration, and hydropic degeneration), probably as the result of a slightly impaired blood supply.

### Adenocarcinoma

**Definition.**—An adenocarcinoma is a malignant tumor of glandular epithelium.

**Distribution and incidence.**—Adenocarcinomas are found in all meat-producing animals throughout the United States. During the USDA's 2-year survey, mentioned on page 1, 4.6 percent of the cattle tumors and 26 percent of the sheep tumors collected were found to be adenocarcinomas. None were found in swine. Adenocarcinomas are usually found in older animals. No breed or sex incidence has been established.

**Macroscopic appearance.**—The gross appearance of an adenocarcinoma varies with its age and its physical loca-

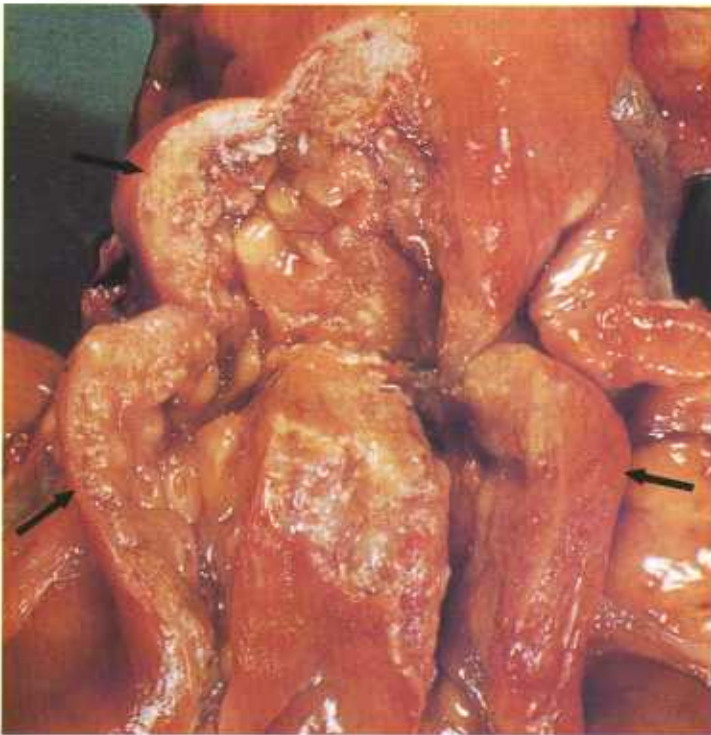


Figure 43.—Adenocarcinoma of the uterus of a 12-year-old Hereford cow (A394-D3090). The adenocarcinoma (arrows) is infiltrating the wall of the uterus.

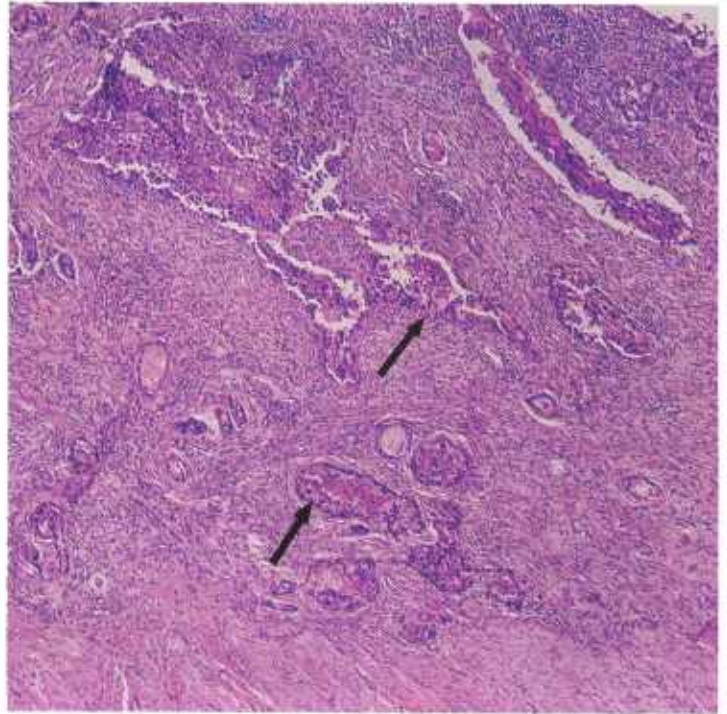


Figure 44.—Adenocarcinoma of the uterus of an 8-year-old Hereford cow (D2332). The neoplasm (arrows) is infiltrating the wall of the uterus and is forming alveoli. The alveoli are lined by neoplastic glandular tissue and their lumens are filled with desquamated necrotic neoplastic cells. Hematoxylin-eosin stain.  $\times 50$ .

tion, and with the basic tissue involved. On mucous surfaces it may simply be a well-defined, rather flat and undulating thickened area that has the characteristics of a chronic focal inflammation. At the other extreme, it may be a protruding, conspicuous, cauliflowerlike growth, or it may occur as an ulcerating lesion with invasion of the underlying tissues.

No matter what the external appearance of the tumor may be, the underlying tissues are infiltrated. The extent of growth of a primary adenocarcinoma in an internal organ follows no set rule. It may be rounded and sharply defined or it may diffusely permeate the organ in which it is located. Metastatic adenocarcinomas spread to distant organs by way of the venous circulation to the liver, heart, and lungs, and eventually spread from the lungs to other organs by way of the arterial circulation. Metastases to lymph nodes take place through the lymphatic system. Focal masses of tumor cells on the pleura, pericardium, and peritoneum arise from transplantations of neoplastic cells between contacting serosal surfaces.

The exposed cut surface of adenocarcinomas is usually homogeneous yellow, yellowish-gray, or gray tissue that may contain areas of necrosis, hemorrhage, and calcification. Accumulations of glandular secretions within the growths result in the formation of cysts. Some adenocarcinomas are firm and have considerable stroma whereas others are soft and have minimal stroma.

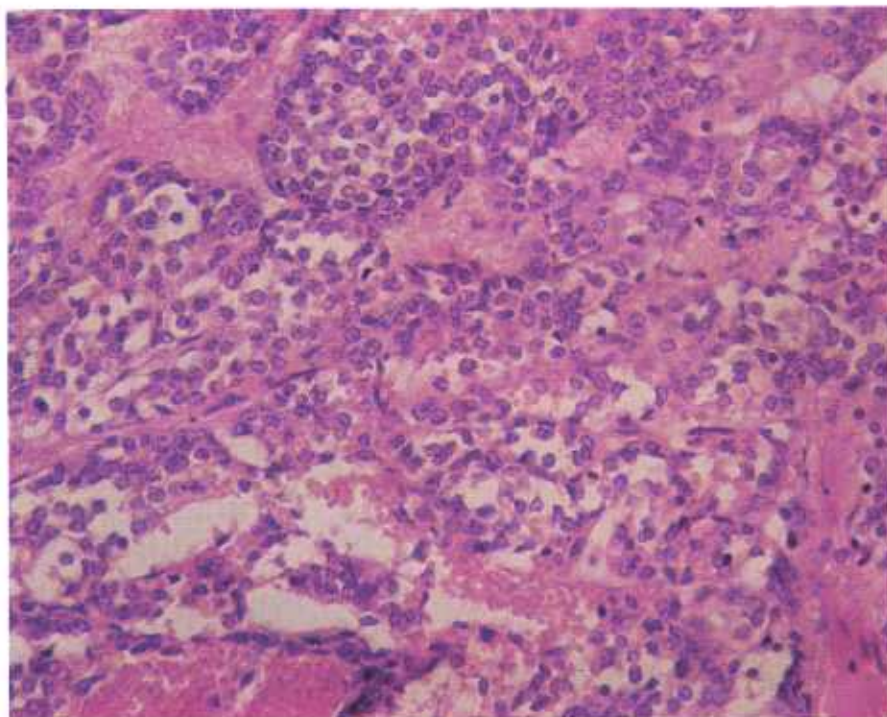


Figure 45.—Adenocarcinoma of the thyroid of an old ewe (D2233). A glandular arrangement of the epithelium is not apparent, although the cells are growing in groups resembling acini. Hematoxylin-eosin stain.  $\times 320$ .

**Microscopic appearance.**—The growth characteristics of adenocarcinomas and adenomas differ. The adenoma is composed of a growing mass of well-differentiated glandular epithelial cells that show minimal neoplastic transformation and that form acini, alveoli, or tubules quite similar in appearance, except for proper orientation, to those of a normal organ.

In contrast to the adenoma, the adenocarcinoma has an exaggerated proliferation of an embryonic type of glandular epithelial cells that sometimes produce acini, alveoli, or tubules and that infiltrate into the tunica propria of tubular structures or into the interstitial tissue of glandular organs. Cells of adenocarcinomas possess the usual characteristics of malignancy—large, rather vesicular nuclei with large nucleoli and many mitotic figures. They frequently retain the special characteristics of the cells from which they originated. This is particularly the case in regard to their secretory function, in both their primary and metastatic forms. The characteristics of the cells of a metastatic tumor are sometimes so akin to those of the primary tumor that they will reveal the nature of the parent growth before it has been examined. The proliferating epithelial cells grow without restraint, no longer produce the architectural design of the organ, and infiltrate the surrounding tissue. The invading cells take the line of least resistance—into loose connective tissue, lymph spaces, and thin-walled blood vessels. When invading these structures, the infiltrating cells are arranged in the form of cords or tubules that branch and rebranch in all directions. The tunica propria and interstitial tissue resist

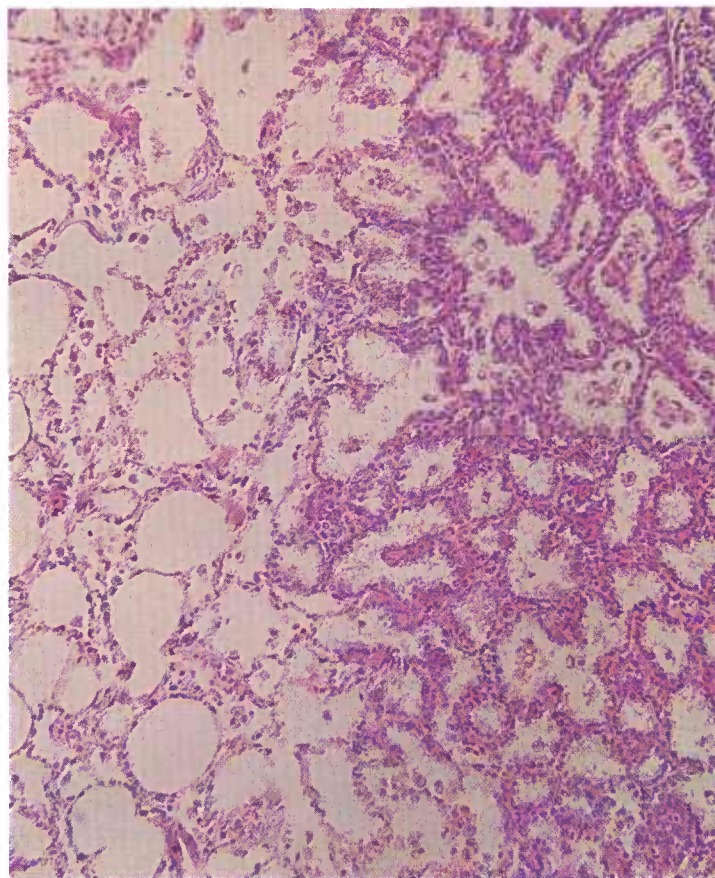


Figure 46.—Pulmonary metastasis from the adenocarcinoma of the thyroid (D2233) shown in figure 45. The proliferating neoplastic cells are spreading over the surface of the pulmonary alveoli. Hematoxylin-eosin stain.  $\times 125$ .

invasion with a mild chronic inflammatory response.

The rapidity with which adenocarcinomas spread varies with the species of animal as well as the type of tumor. In rapidly growing adenocarcinomas, retrogressive changes may be so extensive that the identity of the neoplasms can be determined only in the areas of their most recent growth.

### Adenocarcinoma of the Intestine

**Definition.**—Adenocarcinomas of the intestine are malignant tumors originating from the epithelium of the intestinal tract.

**Distribution and incidence.**—Very little is known about the geographic distribution of this tumor because so few have been found. In the USDA's 2-year survey of neoplasms found in Denver abattoirs (see p. 1), 0.1 percent of the cattle tumors were adenocarcinomas of the intestine. None were found in swine or sheep. Most of these intestinal malignancies involve the small intestine; the colon, cecum, and rectum are seldom involved.

**Macroscopic appearance.**—Adenocarcinomas of the intestine are polypoid, fungating masses that measure 2 to 10 cm. in diameter and protrude into the lumen of the intestine. They are gray, yellowish gray, or brown; when a brown color is present, it is apparently caused by the action of digestive enzymes and hydrochloric acid on areas of hemorrhage in the superficial parts of the neoplasm. Occasionally, these carcinomas occur as an annular ring in the wall of the intestine. In these cases, the external appearance of the involved area of the in-

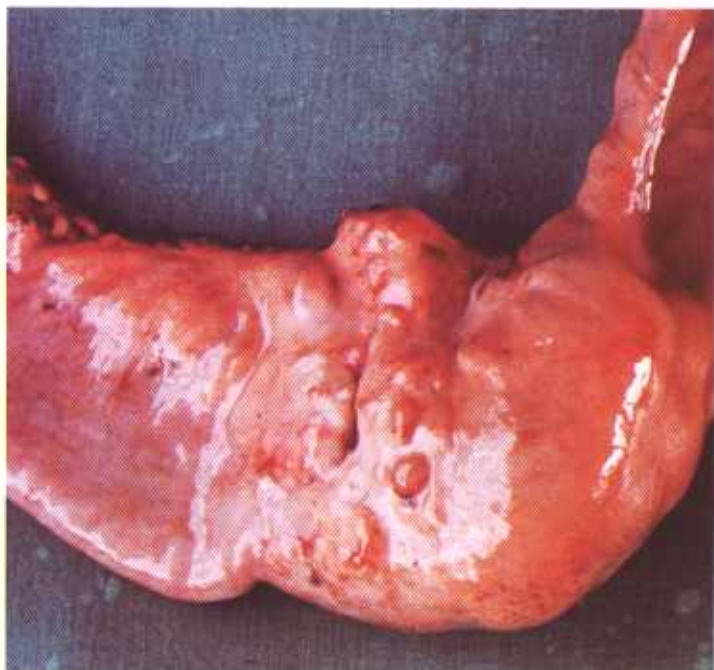


Figure 47.—Adenocarcinoma of the small intestine of an old cow (MISU236). The growth involves the entire circumference of the intestine and resembles the healing site of an intussusception.



Figure 48.—Histologic preparation of an adenocarcinoma of the jejunum of a 9-year-old cow (D2855). Hematoxylin-eosin stain.  $\times 50$ .

testine is that of a partially healed intussusception. The luminal surface of the neoplasm is usually ulcerated. The growth infiltrates into the wall of the intestine and

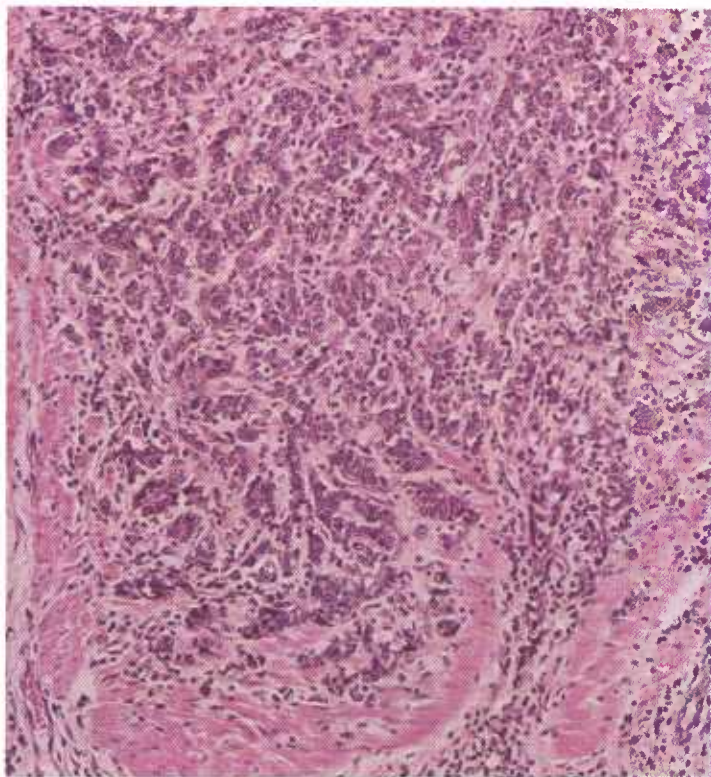


Figure 49.—A higher magnification of the adenocarcinoma (D2855) shown in figure 48. Hematoxylin-eosin stain.  $\times 125$ .

## Neoplasms of the Adrenal Gland

### *Adrenal cortical adenoma and adenocarcinoma*

**Definition.**—Adrenal cortical adenomas and adenocarcinomas are tumors of glandular epithelium that arise from cells of the adrenal cortex.

**Distribution and incidence.**—Tumors of this type are found throughout the United States and are most frequently observed in old animals. About 75 percent of the bovine cortical adrenal tumors are found in cattle over 6 years of age and approximately 90 percent have been found in females. No breed predominance has been determined, although most of the specimens submitted for diagnosis to the Denver laboratory during a period of 22 years have occurred in Herefords. Of the neoplasms collected during the USDA's 2-year survey (see p. 1), adrenal cortical adenomas and adenocarcinomas account for 3 percent of the bovine tumors and 8 percent of the ovine tumors. These tumors represent the second most common group of epithelial neoplasms found in cattle and are surpassed only by the squamous-cell carcinoma of the eye.

It is difficult, if not impossible, to draw a sharp line of demarcation between adrenal hyperplasias, adrenal adenomas, and adrenal adenocarcinomas. It is especially difficult to determine when an adenoma has become an adenocarcinoma. Since endocrine imbalances are not associated with the presence of adenomas or adenocar-

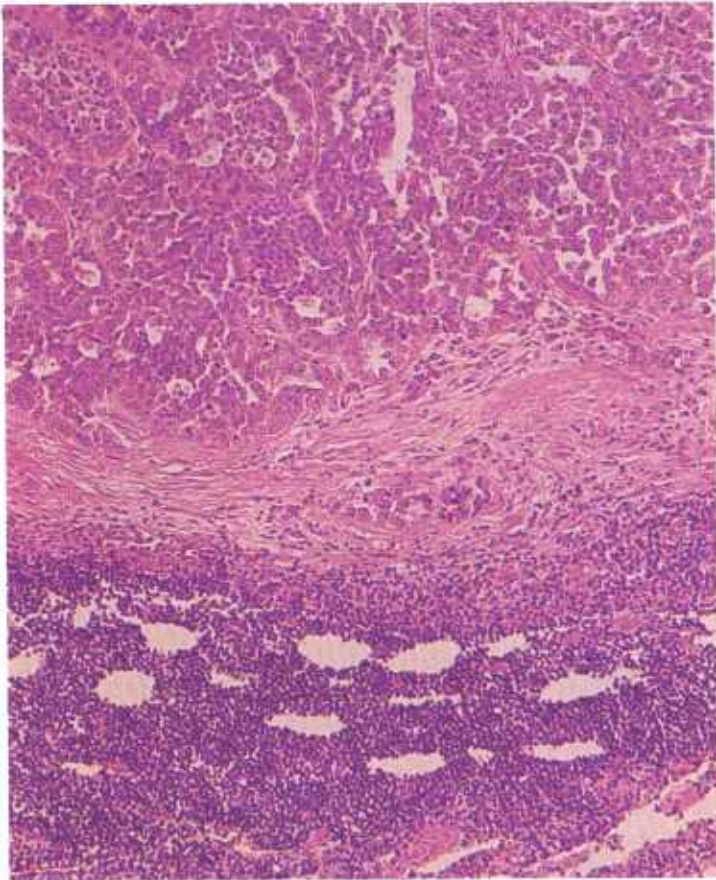


Figure 50.—Histologic preparation of a mesenteric lymph node invaded by the adenocarcinoma (D2855) shown in figure 48. Hematoxylin-eosin stain.  $\times 125$ .

may extend through the serosa into the peritoneal cavity. Obstruction of the small intestine seldom occurs until late in the course of the disease and is then usually associated with the annular-ring type of involvement. Rupture of the intestinal wall at the site of the tumor or peritonitis secondary to bacterial invasion of the neoplastic tissue may occur.

Metastases are found in the mesenteric, cecal, and colic lymph nodes and in the liver and lungs. The metastases are white or gray and may contain areas of necrosis and hemorrhage. They are only lightly encapsulated.

**Microscopic appearance.**—This tumor is a typical adenocarcinoma composed of columnar cells arranged in acini and of tubules that resemble cells of the intestinal mucosa from which they are derived. The cytoplasmic content of these cells varies somewhat, according to the part of the intestine involved. Most of the cells produce mucus but some of the least anaplastic cells of tumors of the small intestine contain secretory granules. The tumor is usually not cystic, but contains areas of necrosis and hemorrhage. Stroma is meager and the amount of encapsulation is slight. The surface of the primary neoplasm protruding into the lumen of the intestine is usually necrotic and partially digested.

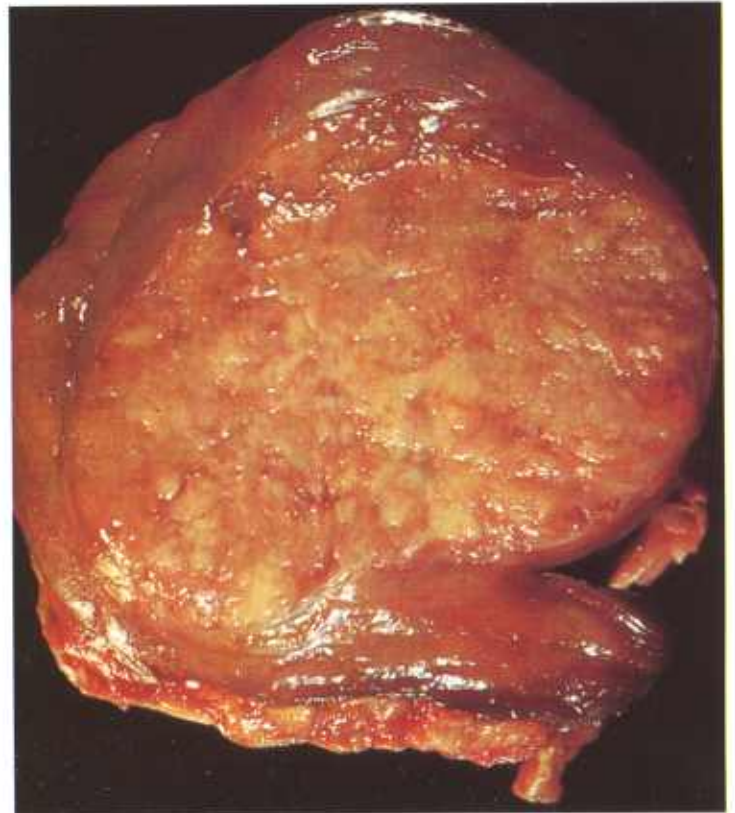


Figure 51.—Adenoma of the adrenal of a 6-year-old cow (A355-D2923). An irregular, oval, gray, thinly encapsulated tumor (9 by 7 by 6 cm.) that contains poorly defined lobules.

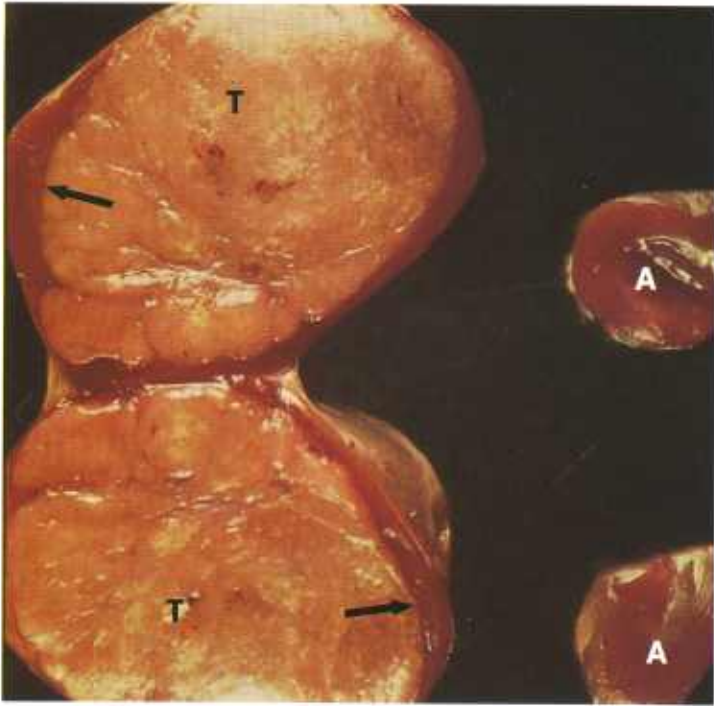


Figure 52.—Longitudinal cross section of an adenoma of the adrenal of a sheep (A430-D3289), compared to a normal adrenal (A). The tumor (T) is gray, slightly lobulated, soft in consistency, and thinly encapsulated. It measures 4 by 3 by 2 cm. Remnants of the affected adrenal (arrows) are present in one part of the capsule.

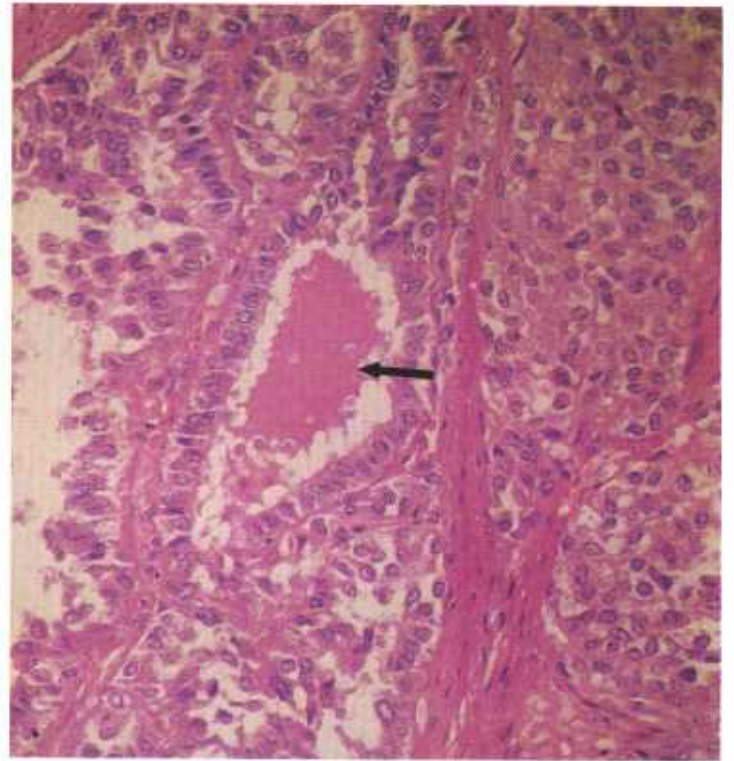


Figure 54.—Histologic preparation of an adenoma of the adrenal in an old Hereford cow (D1331). The neoplastic glandular epithelium is arranged in acini that contain a homogeneous-eosin-staining material (arrow). Hematoxylin-eosin stain,  $\times 320$ .

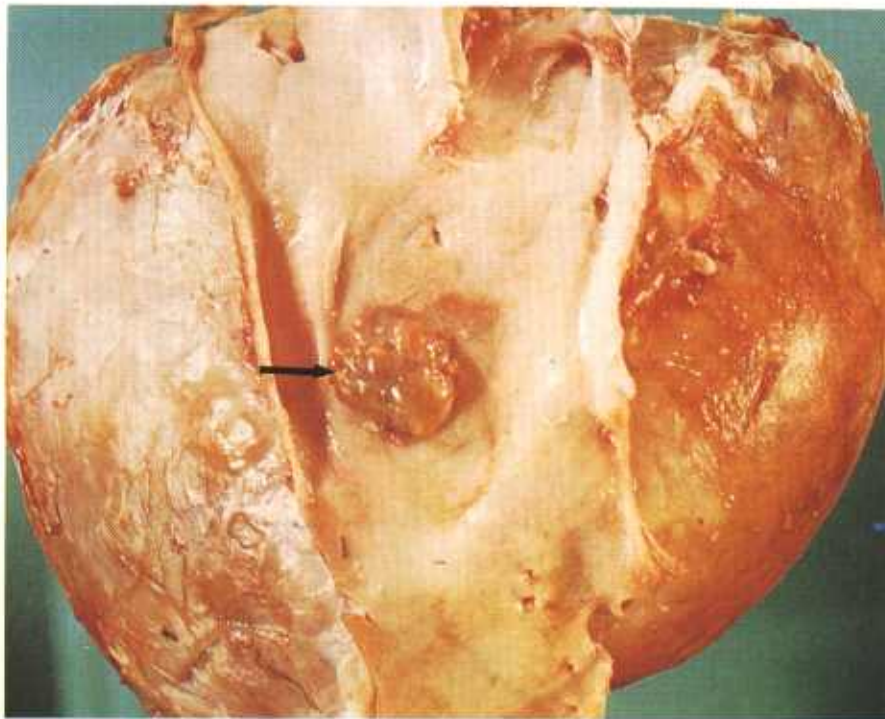


Figure 53.—Adenocarcinoma of the adrenal of a 3-year-old cow (A390-D3092). The tumor consists of a firm, thickly encapsulated mass (19 by 15 by 10 cm.) adhering to the aorta. A solid, thickly encapsulated mass (arrow) measuring 25 by 20 by 10 mm. protrudes through the wall of the aorta. The aortic surface of this protruding mass is covered with a thin but complete capsule. There are many large areas of necrosis in this neoplasm. Fine granules of calcium and small areas of hemorrhage are particularly prominent in the necrotic tissue.

cinomas of the adrenal, the determination of variations in adrenal hormone production is of no assistance in diagnosis.

Very few bovine adrenal adenocarcinomas metastasize. Of the 78 bovine adrenal carcinomas submitted for diagnosis to the Denver laboratory over a period of 22 years, only two (1.5 percent) had metastasized to other organs. Ovine adrenal adenocarcinomas are more malignant. Records at the laboratory indicate that 40 percent metastasize to other tissues and organs. The presence of nodules of adrenal cortical tissue in the adrenal and the periadrenal fat of all species of animals should not be confused with metastases since these nodules are considered to be hamartias and areas of hyperplasia and not areas of neoplasia.

**Macroscopic appearance.**—Adenomas and adenocarcinomas of the adrenal are remarkably similar in appearance. In attempting to establish a basis for the diagnosis of adrenal cortical carcinomas in cattle, we have concluded that, in the absence of metastases, the factors of invasiveness and size are the two most important diagnostic considerations. Their size when seen at the time of slaughter is consistently large; nearly all are more than 5 cm. in diameter and their maximum diameter may be 25 cm. Bilateral involvement of the adrenals is seldom observed. The exposed cut surface reveals that these tumors are divided into irregular gray, yellow, or orange lobules. Some of the lobules are firm, others are cystic, and many contain finely granular deposits and large masses of calcium. Areas of hemorrhage and ne-

crosis may be present. Except for a few of the smaller ones, adrenal cortical tumors have a thick, fibrous capsule. When a tumor of this type comes in contact with rather firm adjacent tissue (liver, kidney, or aorta), the contact surface of its capsule often becomes very thin. If it presses upon the wall of the aorta, it causes pressure atrophy of the aortic wall. Continued neoplastic pressure on the aortic wall results in an encapsulated protrusion of the tumor into the lumen of the aorta.

**Microscopic appearance.**—Cells of the adrenal cortical adenoma and adenocarcinoma resemble those of the adrenal cortex: when selected parts of the adrenal cortical tumors are examined, it may be difficult to see any appreciable alteration from the normal adrenal gland. The cells of the tumor contain an abundance of fat, giving it a yellow or orange color. These tumors are encapsulated, usually lobulated, and frequently cystic. They often contain corpora amylacea and at times enclose areas of calcification, hemorrhage, and hemosiderosis.

Adrenal cortical neoplasms in sheep are not as distinctive in their microscopic appearance as are the bovine tumors. The formation of fibrous trabeculae and small calcified bodies is minimal in comparison to corresponding changes in typical bovine cortical tumors. In ovine carcinomas, the neoplastic polygonal cells of the tumor are sometimes two or three times the size of normal cortical cells and have large hyperchromatic nuclei and an appreciable number of mitotic figures. That the more anaplastic appearance of ovine tumors is significant is borne out by their higher incidence of metastasis (40 percent).

### *Neuroblastoma of the adrenal medulla*

**Definition.**—Neuroblastomas of the adrenal are tumors composed of neuroblastic cells.

**Distribution and incidence.**—Neuroblastomas occur in meat-producing animals throughout the United States. No generic, species, breed, age, or sex predominance has been established. During the USDA's survey, mentioned on page 1, 0.3 percent of the bovine tumors collected were found to be neuroblastomas. None were found in pigs and sheep.

**Macroscopic appearance.**—Neuroblastomas of the adrenal medulla may involve one or both adrenals. They are white, gray, or yellow growths with diameters ranging from a few millimeters to as much as 30 cm. Neuroblastomas may be either uniform or slightly lobulated and either soft or fleshy in consistency, and they may contain areas of hemorrhage and necrosis. Metastases to other organs are not common but do occur and are most frequently located in the liver.

**Microscopic appearance.**—The tumors are identical in structure to neuroblastomas of the central nervous system. They have small round or oval cells, each composed mainly of a nucleus and very little cytoplasm. The nuclei stain intensely with hematoxylin. Certain cells are arranged in the form of rosettes in some part of the primary tumor or its metastases.

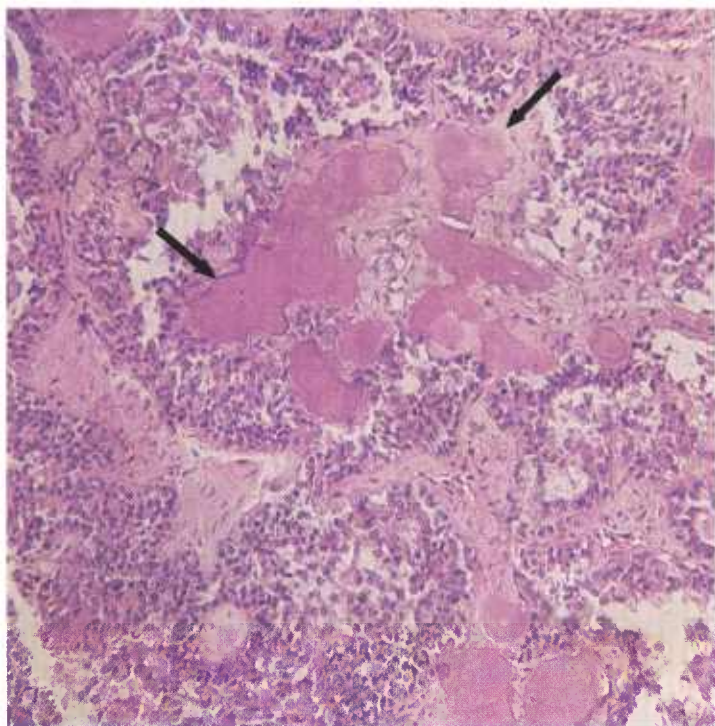


Figure 55.—Histologic preparation of the adenoma of the adrenal (A355-D2923) shown in figure 51. The epithelium has an acinar arrangement and the lumens of the acini contain calcified masses (arrows). Hematoxylin-eosin stain.  $\times 125$ .

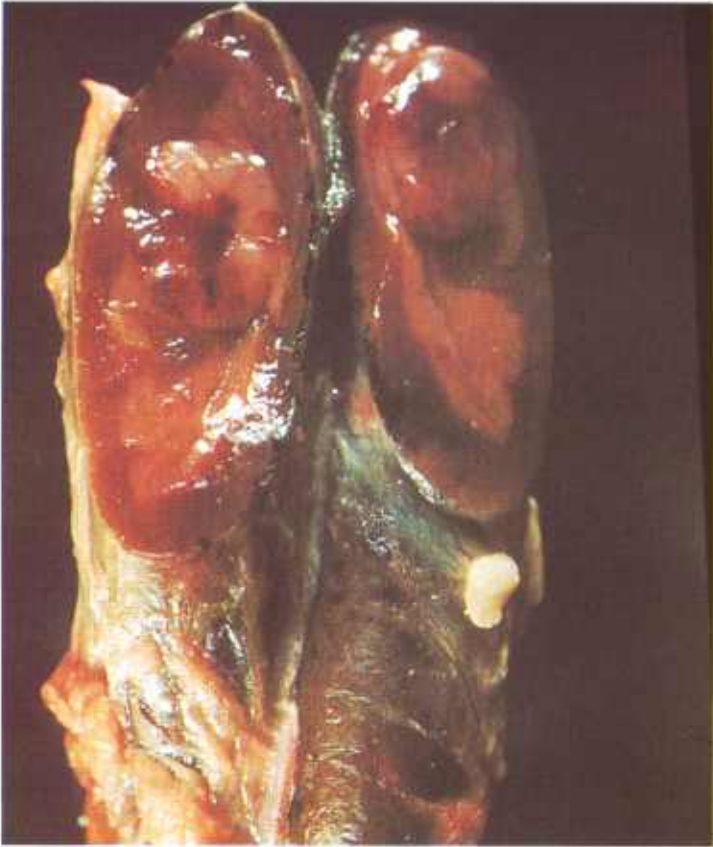


Figure 56.—Neuroblastoma of the adrenal medulla in a 10-year-old cow (A350-D2863). Two oval, grayish-white tumors measuring 5 and 13 mm. in their greatest diameter are present in opposite poles of the left adrenal.

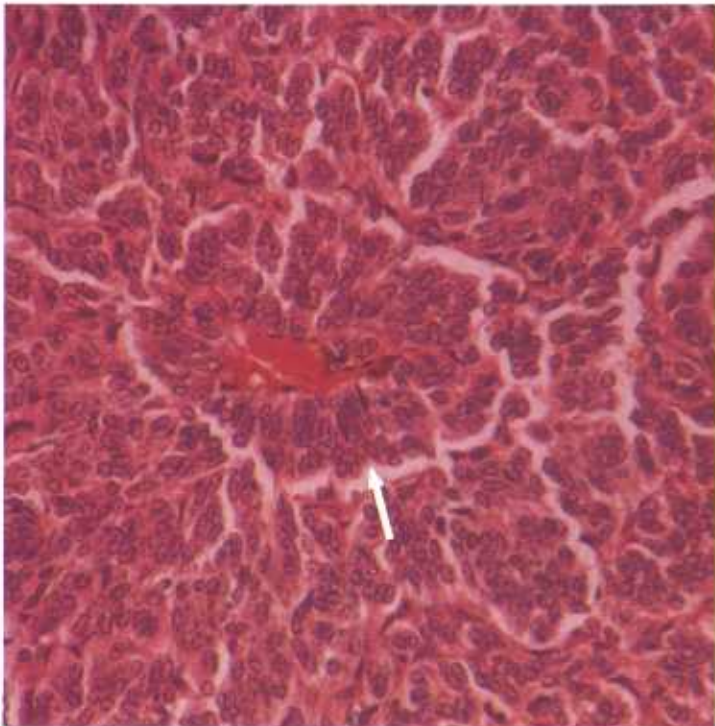


Figure 57.—Histologic preparation of the neuroblastoma of the adrenal (A350-D2863) shown in figure 56. The arrow shows a rosette arrangement of tumor cells around a blood vessel. Hematoxylin-eosin stain.  $\times 320$ .

### *Pheochromocytoma*

**Definition.**—Pheochromocytomas are tumors originating from cells of the adrenal medulla.

**Distribution and incidence.**—Pheochromocytomas are found in meat-producing animals throughout the United States. No generic, species, or breed predominance has been established. Most of the tumors occur in old females. During the USDA's 2-year survey of neoplasms found in Denver abattoirs (see p. 1), 0.2 percent of the cattle tumors and 14 percent of the sheep tumors were identified as pheochromocytomas. None were found in swine.

Apparently, pheochromocytomas of animals differ considerably from similar tumors in man. Even in large animal pheochromocytomas, no clinical signs of excessive production of adrenalin (hypertension, incoordination, and tachycardia) have been observed. In animals, the tumors are white, yellowish white, or gray, whereas in humans they are usually brown. When fixed in chromate solutions, the animal tumors do not become brown,

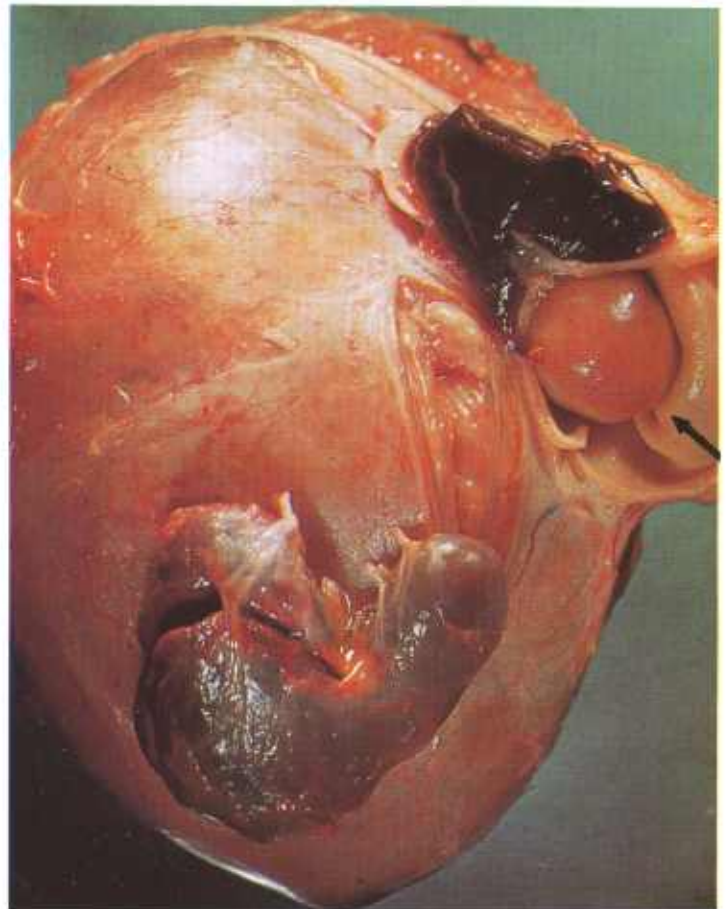


Figure 58.—Pheochromocytoma of the adrenal of an old cow (A382-D2989). The tumor is yellow and consists of an encapsulated, solid, encephaloid growth. It measures 10 by 7 by 5 cm. and is attached to two remnants of the adrenal. An oval encapsulated mass (arrow) measuring 2 cm. in its greatest diameter protrudes from the tumor through the wall of the posterior aorta. The luminal surface of the aortic protrusion is covered with an intact connective tissue capsule.

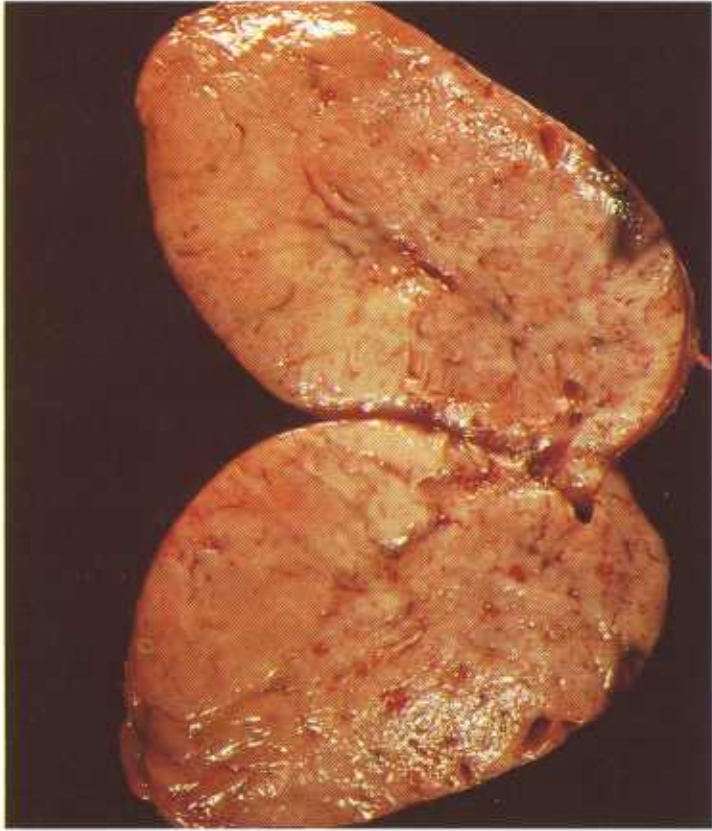


Figure 59.—Cross section of a pheochromocytoma of the adrenal of an old ewe (A402-D3102). An oval, yellowish-gray, encephaloid tumor (10 by 6 by 5 cm.) has replaced the adrenal gland. The tumor has penetrated into the lumen of the vena cava at two points as pedunculated nodules covered by intact capsules. No metastasis to other organs has occurred.

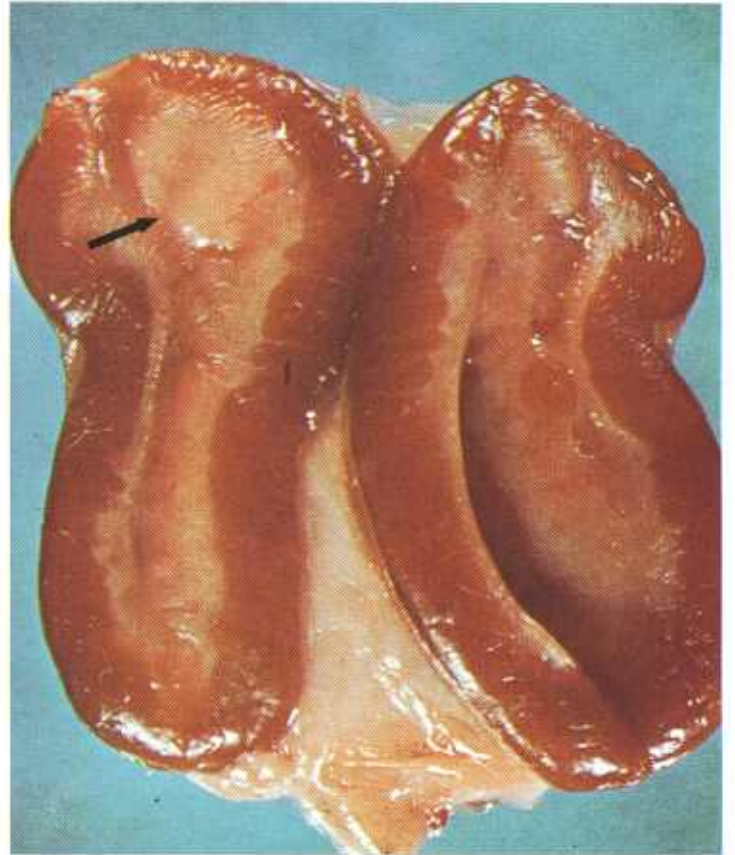


Figure 60.—Pheochromocytoma of the adrenal of an old ewe (A384-D3087). It is an irregularly shaped, firm, yellow tumor (arrow) measuring 6 mm. in its greatest diameter. The growth is located at the cortico-medullary junction of one pole of the adrenal.

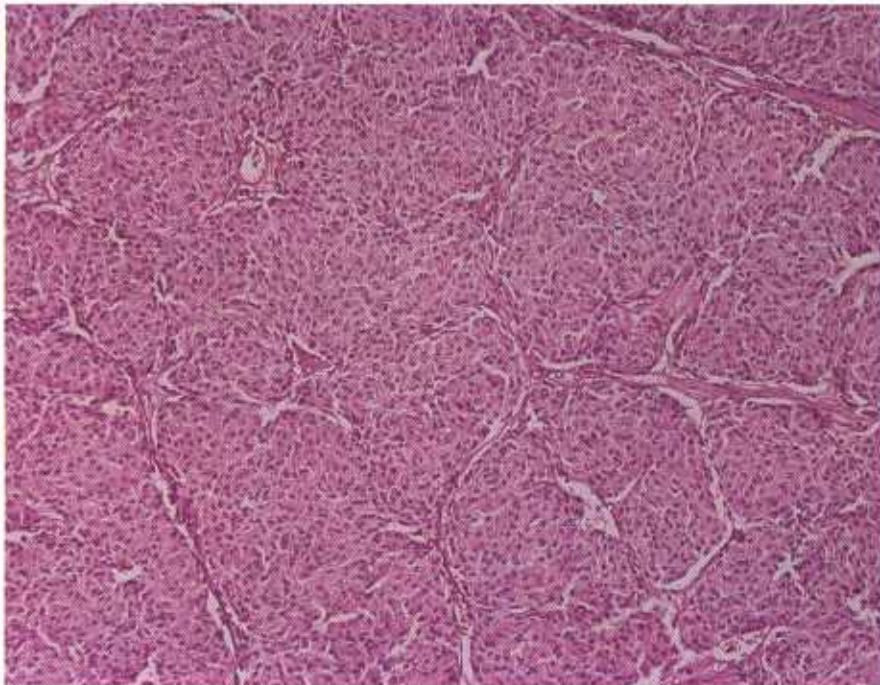


Figure 61.—Pheochromocytoma of the adrenal of an old ewe (D2660). The tumor is composed of polygonal cells which, with their hyperchromatic nuclei and abundant acidophilic cytoplasm, resemble the cells of the adrenal medulla. The neoplastic cells are growing in small solid nests separated by a delicate vascular connective tissue stroma. Hematoxylin-eosin stain.  $\times 125$ .

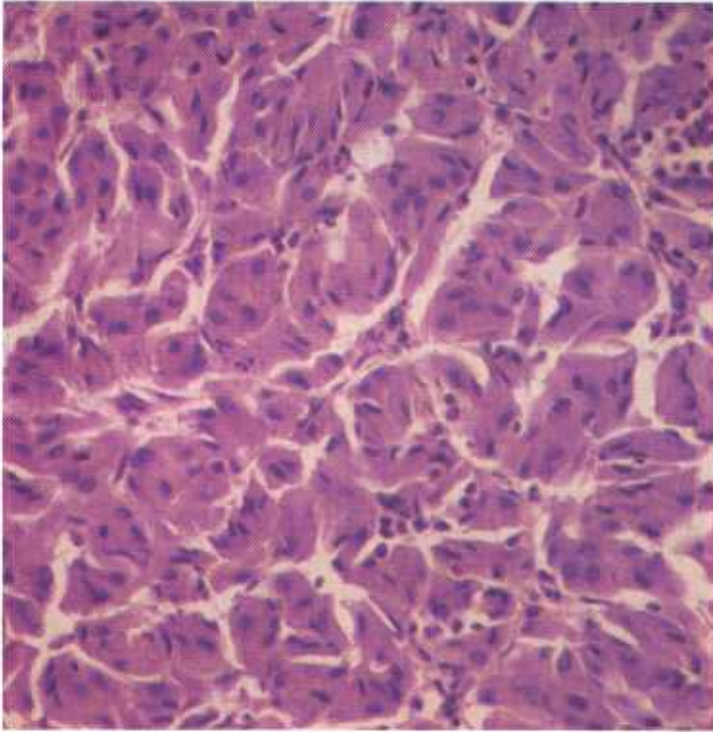


Figure 62.—Pheochromocytoma of the adrenal of an old ewe (D2679). The tumor is made up of groups of rather large polygonal cells with hyperchromatic nuclei and abundant acidophilic cytoplasm. The cells are separated by a delicate connective tissue stroma. Hematoxylin-eosin stain.  $\times 320$ .

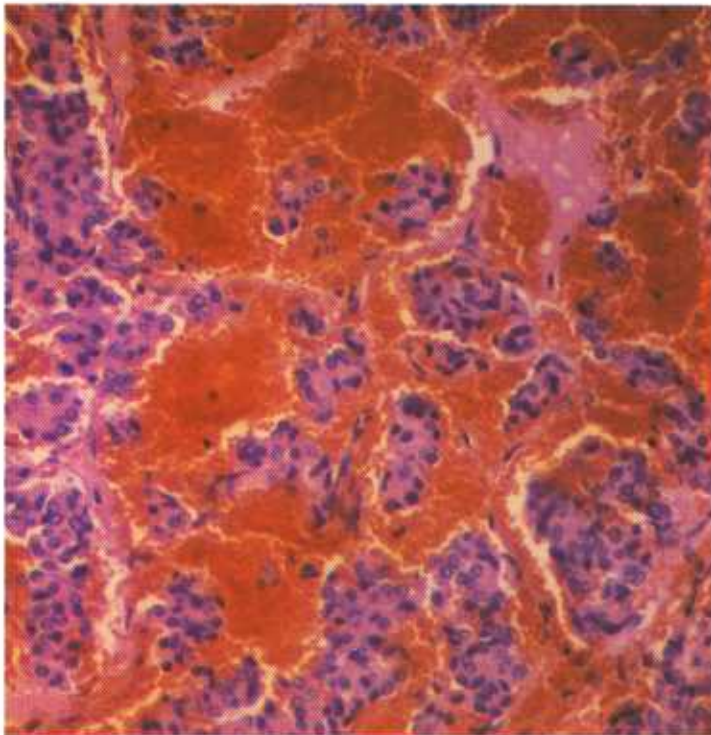


Figure 63.—Pheochromocytoma of the adrenal of an old ewe (D3044). The tumor is composed of groups of large polygonal cells that have hyperchromatic nuclei and abundant acidophilic cytoplasm, and are supported by a delicate vascular connective tissue stroma. Many areas of hemorrhage are present within the tumor. The neoplasm has extended into the adjacent aorta. Hematoxylin-eosin stain.  $\times 320$ .

whereas human pheochromocytomas do. Further, the brown staining of the periadrenal fat observed in association with pheochromocytomas in man has not been observed in similar tumors in animals.

**Macroscopic appearance.**—These tumors are firm, lobulated, thinly encapsulated growths that cannot be differentiated from adrenal cortical tumors on the basis of their appearance at postmortem examination. They are usually large, up to 12 cm. in diameter, and commonly distort the adrenal to such an extent that a point of origin cannot be distinguished. The neoplasms usually occur as unilateral growths, but occasionally bilateral adrenal involvement is observed. Like the cortical tumors, pheochromocytomas often adhere to or press upon the aorta or vena cava; the resulting atrophy of the vessel wall is probably responsible for the thinly encapsulated outpouchings into the lumen of these vessels perpetrated by some of the larger tumors. Metastases seldom occur.

**Microscopic appearance.**—Pheochromocytomas consist of large pleomorphic cells that resemble those of the adrenal medulla. The cells have granular cytoplasm and nuclei that are irregular in both size and shape and contain a moderate amount of chromatin. Only a few, if any, brown chromaffin granules are found in the cytoplasm of the cells when they are fixed in chromate fixatives. The neoplastic cells are arranged in nests or clusters that are separated from each other by thin-walled capillaries and a slight amount of connective tissue stroma.

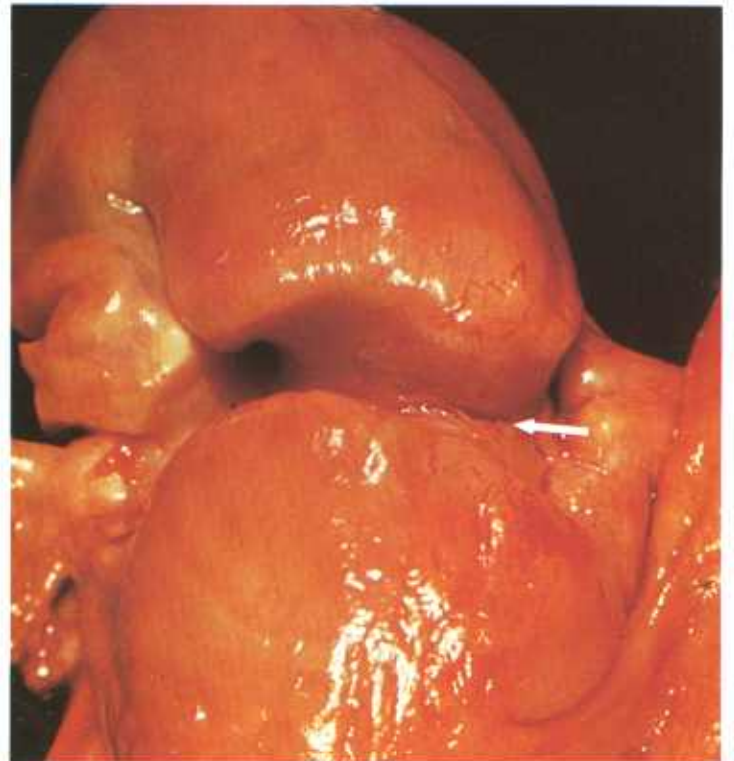


Figure 64.—Adenocarcinoma of the uterus in an 8-year-old Hereford cow (A279-D2662). Note the rather characteristic annular constriction (arrow) of the uterine horn.

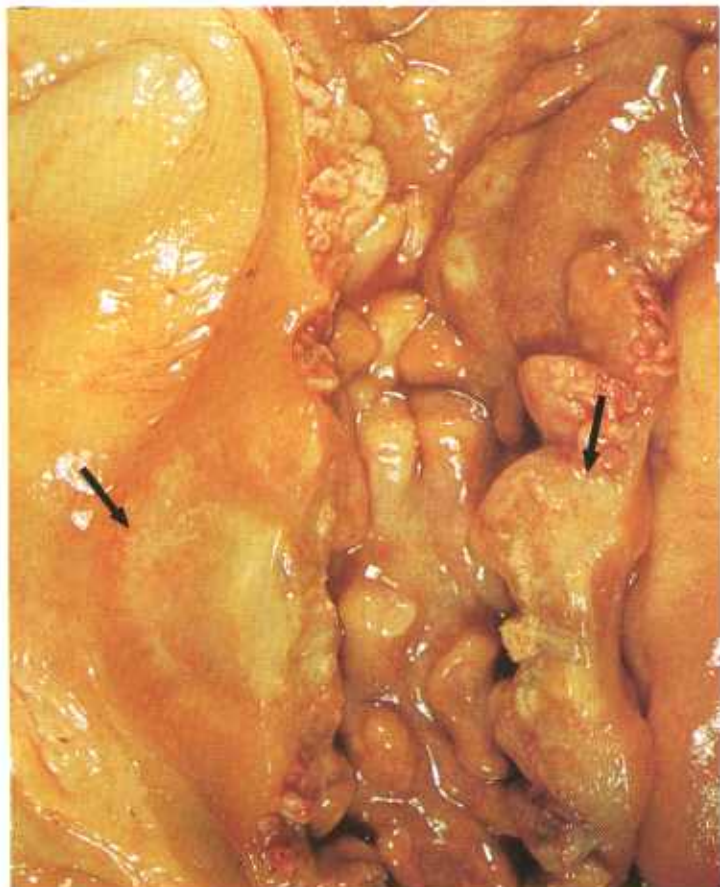

Figure 65.—Adenocarcinoma of the uterus in a 12-year-old Hereford cow (A337-D2786). This tumor (arrows) is disc-shaped and has a depressed serosal surface. No ulceration of the serosal surface has occurred. A zone of hyperemia exists at the junction of the neoplasm and the uterine wall.

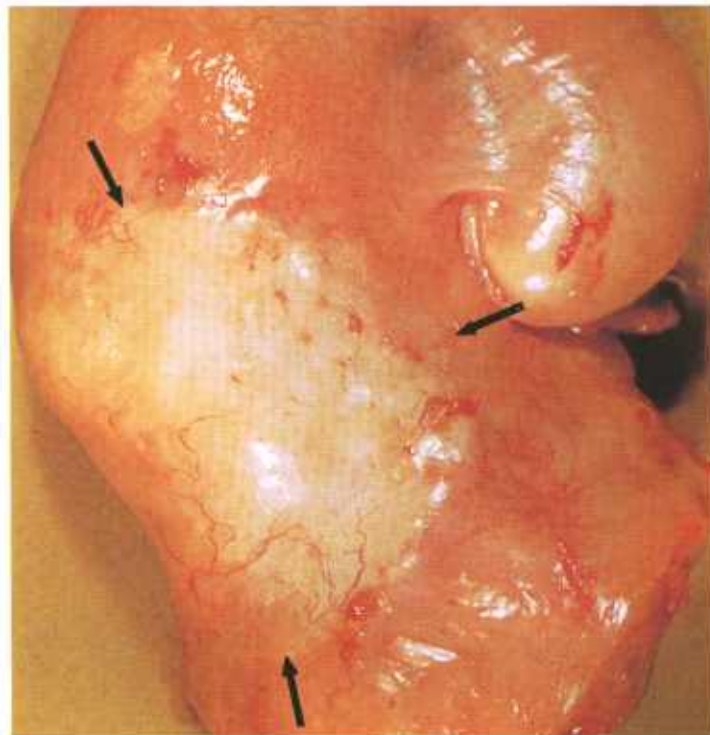


Figure 66.—Adenocarcinoma (arrows) of the uterus in a 7-year-old cow (A57-D1354). The neoplasm has a sclerotic appearance. Note that the serosal surface is depressed and no ulceration is present. The uterine serosa adjacent to the tumor is slightly hyperemic and has a small amount of fibrin on its surface.

## Neoplasms of the Genital Tract

### *Adenocarcinoma of the uterus of the cow*

**Definition.**—Adenocarcinoma of the uterus of the cow is a malignant tumor of the genital tract that arises from the uterine mucosa.

**Distribution and incidence.**—Adenocarcinoma of the uterus is found throughout the United States. During the USDA's 2-year survey, mentioned on page 1, this tumor accounted for 3 percent of the bovine neoplasms collected. None were found in swine or sheep. No breed predilection has been determined. These tumors are most frequently observed in cattle from 7 to 12 years of age.

Adenocarcinoma of the uterus may occur in either horn of the uterus or in the uterine area sometimes referred to as the body. It is the second most common malignant glandular tumor of cattle. Of the bovine epithelial tumors in general, it is the third most common, being surpassed only by the adrenal cortical tumor and the squamous-cell carcinoma of the eye. The association of sterility with uterine carcinoma has not been established.

**Macroscopic appearance.**—The most constant feature of the growth is its tendency to form a sclerotic, annu-

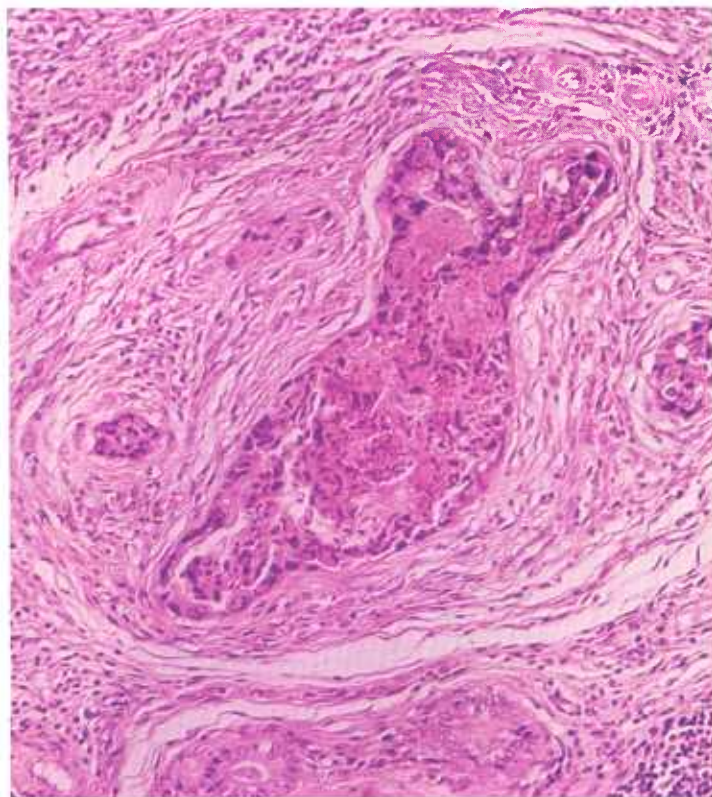


Figure 67.—Adenocarcinoma of the uterus in an 8-year-old Hereford cow (D2332). Tumor glands filled with necrotic cellular debris in an abundant connective tissue stroma are characteristic features of this neoplasm, duplicated in its metastases. Hematoxylin-eosin stain.  $\times 180$ .

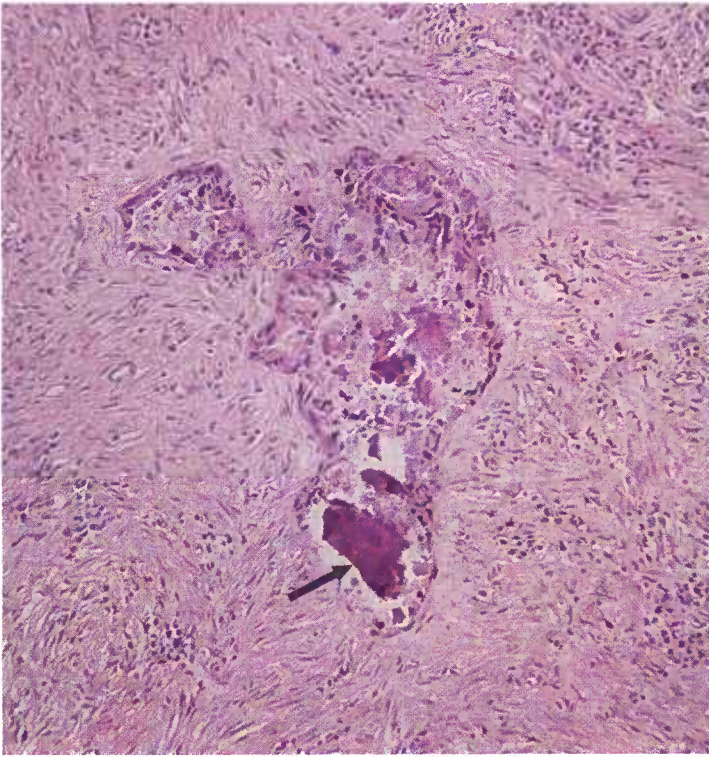


Figure 68.—Histologic preparation of a uterine adenocarcinoma in a 7-year-old cow (D2973). Calcification (arrow) of the necrotic debris within a neoplastic glandular space is a common alteration in this type of neoplasm. Hematoxylin-eosin stain.  $\times 125$ .

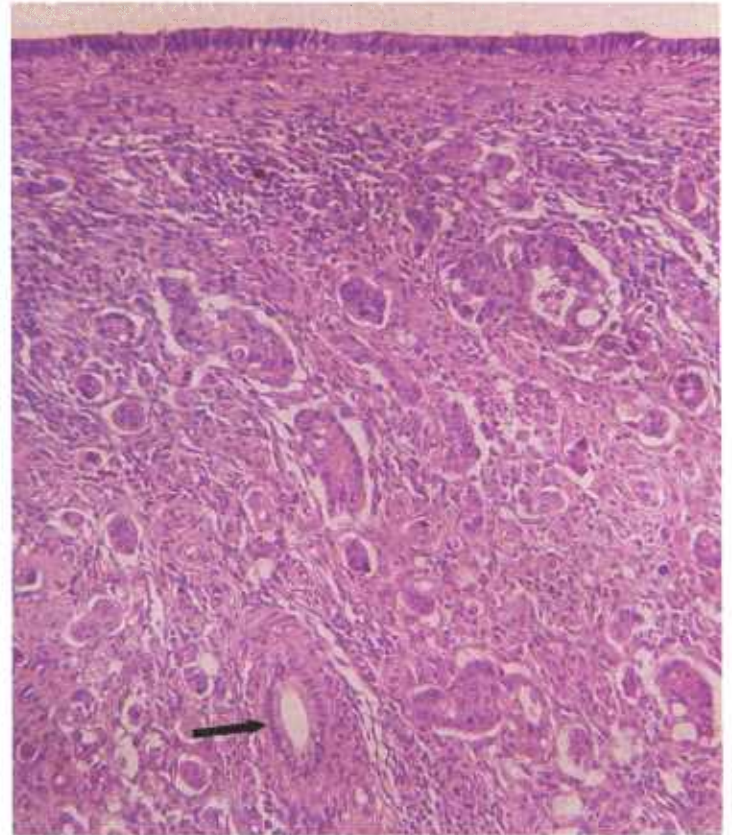


Figure 70.—Histologic preparation of a uterine adenocarcinoma in a 10-year-old Hereford cow (D2691). Groups of tumor cells are infiltrating beneath an intact uterine surface epithelium. Note the hyperplastic uterine gland (arrow) that is still recognizable in the distorted endometrium. Hematoxylin-eosin stain.  $\times 125$ .

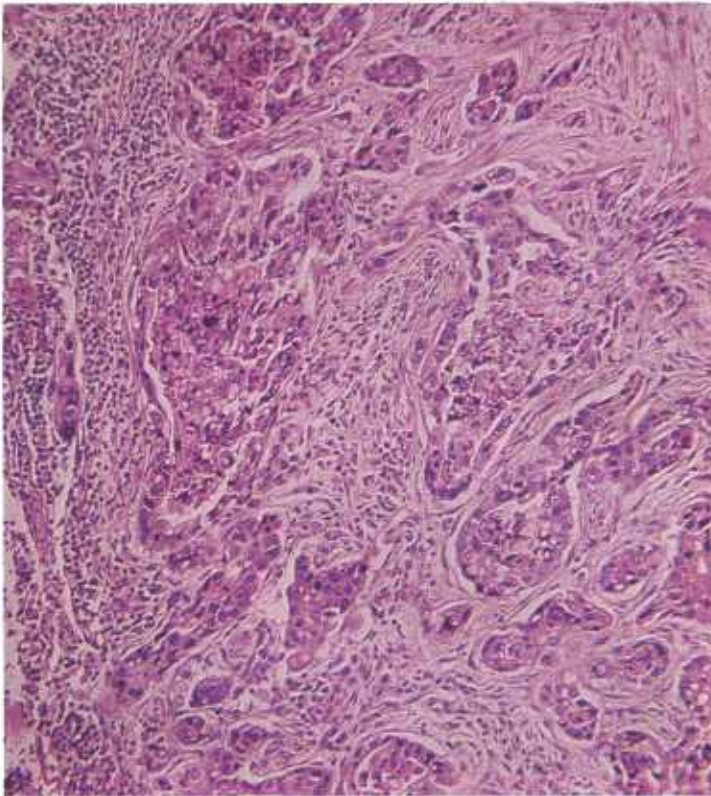


Figure 69.—Histologic preparation of the pulmonary metastases of the uterine adenocarcinoma in a cow (A279-D2662) shown in figure 64. Note that the neoplastic glands, supported by an abundant connective tissue stroma, are filled with necrotic cells.

lar constriction without perforation of the serosa and with little or no extension onto the surface of the endometrium. The tumor, as well as its metastases and transplants, varies from yellow to gray and is quite firm and dense because of the connective tissue it contains.

One characteristic of this tumor is that neoplastic cells from the serosal surface of the uterus are transplanted onto the abdominal viscera. As a result, tumor nodules are present in the broad ligaments of the uterus, and other nodules are scattered over the visceral and parietal peritoneum. Transplantation tumor nodules are quite commonly found on the serosa of the spleen and liver. Metastatic tumor masses are located in the internal iliac and sublumbar lymph nodes and in the lung.

**Microscopic appearance.**—Uterine adenocarcinomas are composed of cuboidal or columnar cells arranged in acini, tubular structures, or cords. The cells are hyperchromatic, have large chromatin-rich nuclei, and contain many mitotic figures. Metastases of the bovine uterine adenocarcinoma maintain a degree of differentiation and a limit to anaplastic changes. Even in the transplanted and metastatic nodules, the glandular pattern is maintained. This is particularly important because many adenocarcinomas of other organs lose this

glandular pattern and form anaplastic masses in both the primary and secondary tumor sites. Within these glandular structures, both in the primary and secondary sites, there are masses of cellular, often necrotic, debris. Most of the growth has a very fibrous stroma.

Progressive growth of the neoplasm on the surface of the uterine epithelium does not occur. The tumor is usually located deep in the endometrium and spreads laterally under an intact surface epithelium, infiltrating through the muscular layers of the myometrium. Groups of tumor cells are found in the periphery of the thick-walled blood vessels in the myometrium. These tumor cells seem to be enclosed within thin-walled vessels, probably lymphatics or dilated veins. The general route of neoplastic invasion through the myometrium is from the endometrium to the serosa. Extension of neoplastic tissue to the serosal surface of the uterus enables the cells to gain entrance into the peritoneal cavity and to effect transplantation onto the visceral and parietal peritoneum. Metastases to the pelvic and sublumbal lymph nodes occur by way of the lymphatic system.

**Summary.**—Since the primary site of uterine carcinoma is often overlooked, it is important to remember

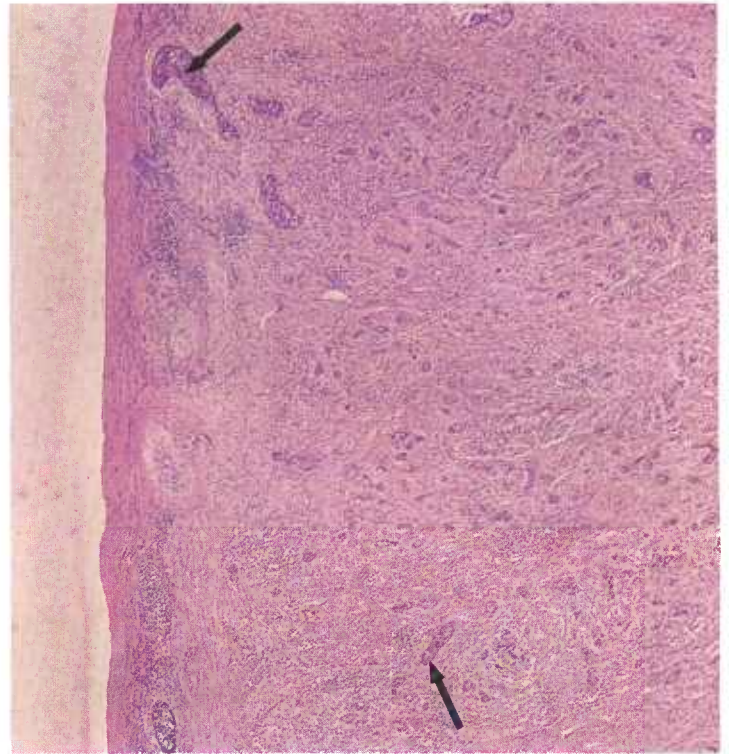


Figure 72.—Histologic preparation of the uterine adenocarcinoma (A279-D2662) shown in figure 64. The lymphatic spread of uterine adenocarcinomas through the muscularis to the serosa is facilitated by the presence of an abundance of lymphatics in the uterine wall. Note the lymphatics (arrows) are distended with tumor cells. Hematoxylin-eosin stain.  $\times 50$ .

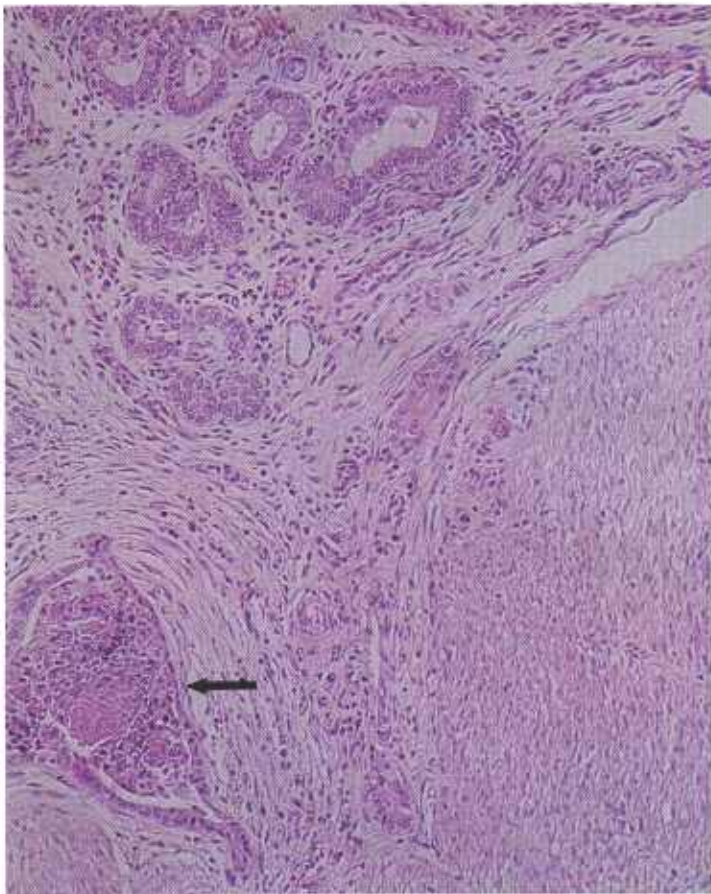


Figure 71.—Histologic preparation of a uterine adenocarcinoma in a 9-year-old cow (D2824). Neoplastic cells of a uterine adenocarcinoma sometimes infiltrate through the muscularis and are found at the base of the glands of the endometrium. Note the neoplastic gland (arrow) in the muscularis near morphologically normal glands. Hematoxylin-eosin stain.  $\times 125$ .

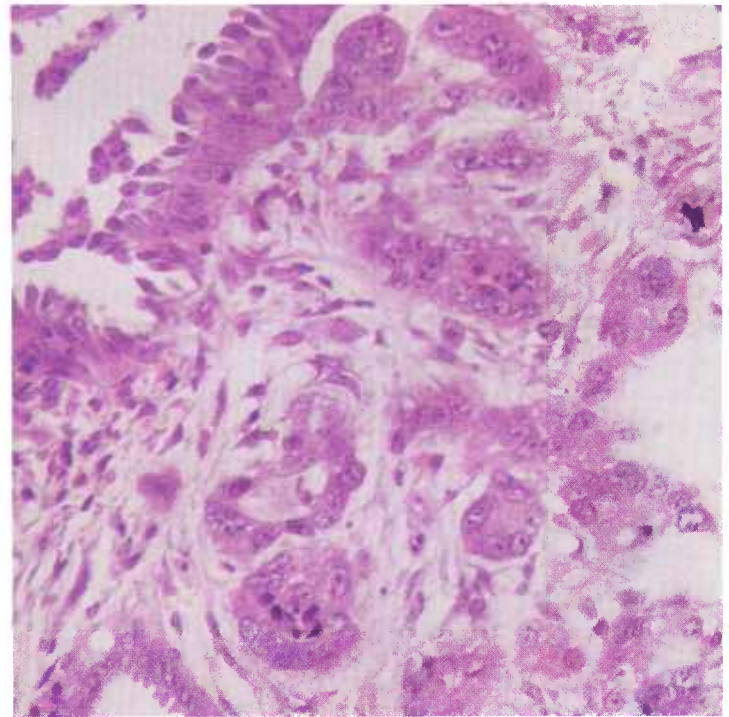


Figure 73.—Histologic preparation of a fallopian tube in a 7-year-old Hereford cow (D2477) affected with a uterine adenocarcinoma. Note the nests of tumor cells in the submucosal tissues of the fallopian tube that suggest the progressive spread of the neoplasm from the uterus along the lymphatics. Hematoxylin-eosin stain.  $\times 320$ .

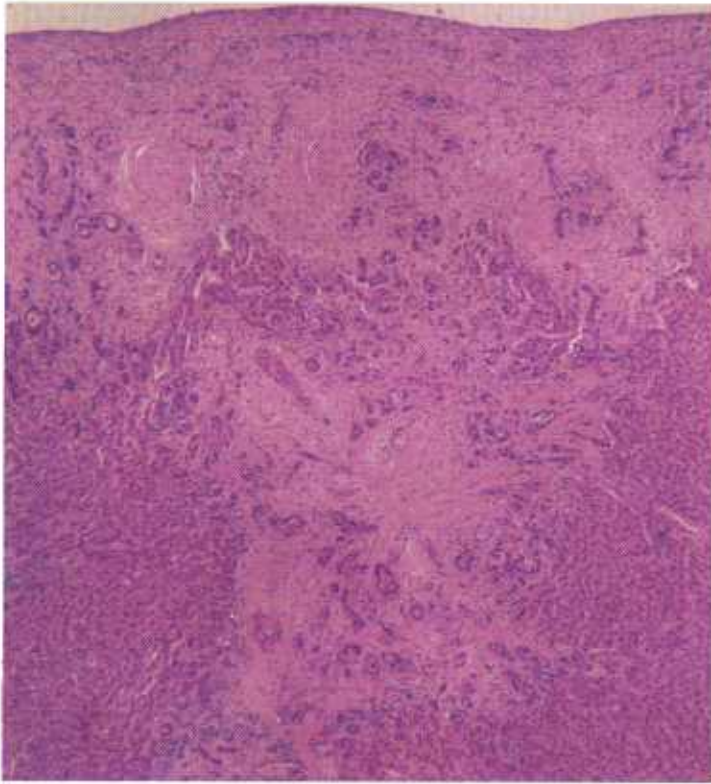


Figure 74.—Histologic preparation of a liver metastasis of the uterine adenocarcinoma (A337-D2786) shown in figure 65. Progressive spread of the adenocarcinoma from a peritoneal implant into the liver parenchyma has occurred. Note the glandular arrangement of the tumor cells and the prominent cirrhosis associated with the presence of the neoplasm. Hematoxylin-eosin stain.  $\times 50$ .

the characteristics of this tumor, especially in differentiating it from primary lung neoplasms. (1) Uterine adenocarcinomas maintain a degree of differentiation both in primary and secondary sites. (2) The lumen of the glands comprising the neoplasm contains an abundance of cellular debris. (3) Uterine carcinomas display extreme fibrosis in both primary and secondary sites. (4) Parietal and visceral peritoneal transplants are numerous. (5) An annular ring is usually present in the uterine wall at the site of the neoplasm. In most instances, the primary site is small and there is very little increase in size or weight of the organ.

### *Granulosa-cell tumor of the ovary*

**Definition.**—The granulosa-cell tumor of the ovary is a neoplastic growth of granulosa cells or the closely related theca cells, which are both derived from the same stem cells.

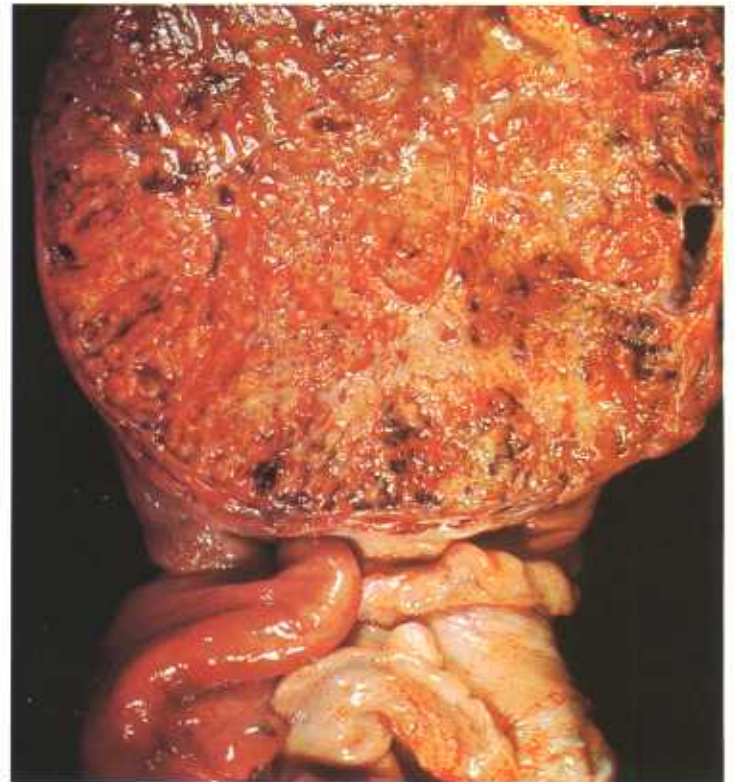


Figure 75.—Cross section of an encapsulated granulosa-cell tumor of the ovary in a 3-year-old Hereford cow (A285-D2703). An oval, solid, encapsulated, smooth-surfaced growth measuring 15 by 16 by 18 cm. and weighing 1,264 grams has replaced the right ovary. Many large veins are visible on the surface of the tumor. The cut surface reveals a very vascular growth containing small cystic spaces and yellow areas of necrosis scattered through a characteristically lobulated grayish-yellow mass. No remnants of the affected ovary are present. The opposite ovary is normal in appearance and no metastases are present in other organs.

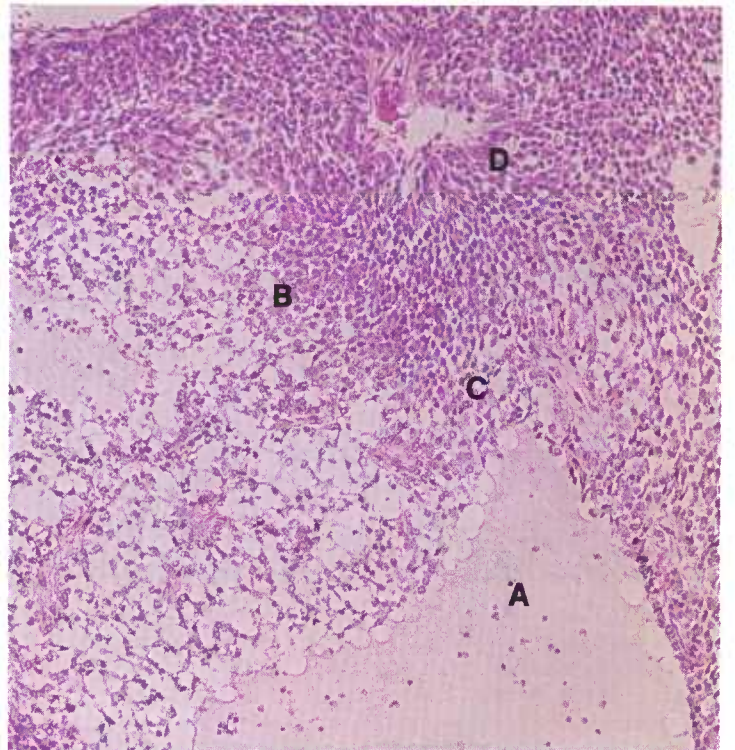


Figure 76.—Histologic preparation of the ovarian granulosa-cell tumor (A285-D2703) shown in figure 75. The characteristic features of these neoplasms are (A) cyst formation, (B) typical granulosa cells, (C) granulosa cells arranged at right angles to the cysts, and (D) granulosa cells arranged at right angles to the blood vessels. Hematoxylin-eosin stain.  $\times 125$ .

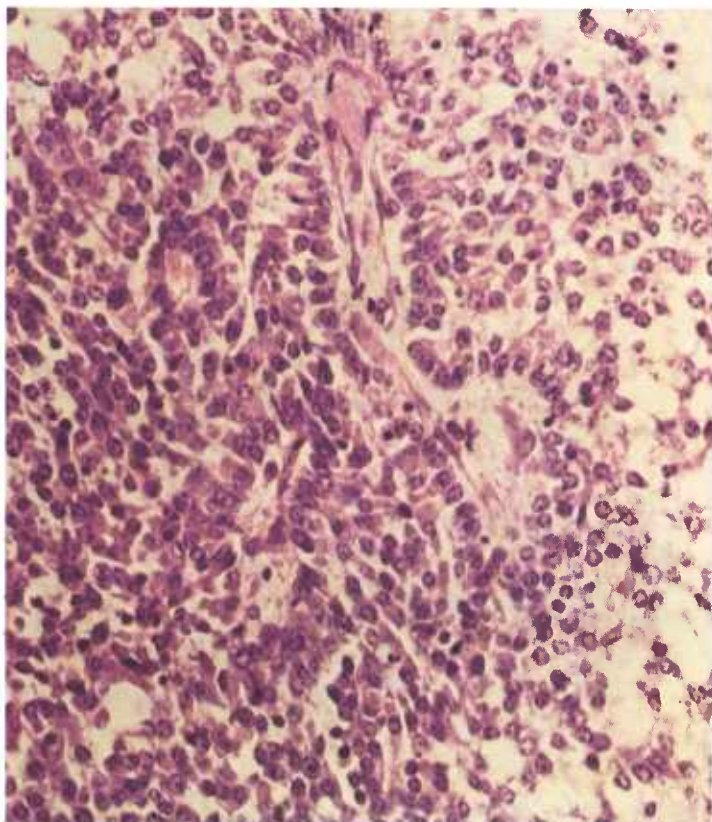


Figure 77.—Higher magnification of the ovarian granulosa-cell tumor (A285-2703) shown in figure 76. Note that the granulosa cells are arranged at right angles to a blood vessel. Hematoxylin-eosin stain,  $\times 320$ .

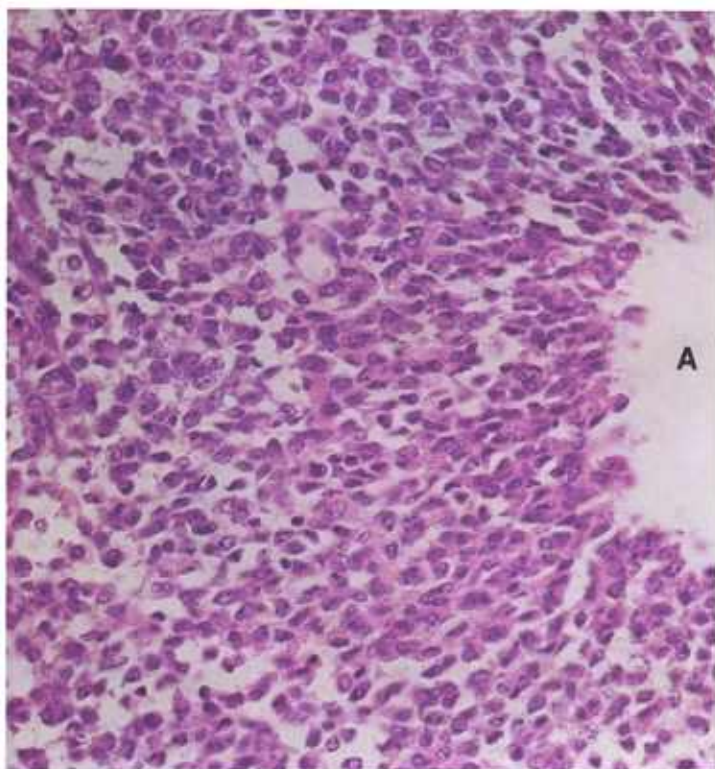


Figure 78.—Granulosa-cell tumor of the ovary in a 2-year-old cow (D1807). Note that the granulosa cells are arranged at right angles to the lumen of the cyst (A). Hematoxylin-eosin stain,  $\times 320$ .

**Distribution and incidence.**—This neoplasm is found throughout the United States. It is most commonly observed in cattle, infrequently in sheep, and seldom in other genera. The tumor occurs in young as well as in older animals. Over half of the cattle tumors are found in cows under 4 years of age. During the USDA's 2-year survey of neoplasms found in Denver abattoirs (see p. 1), 0.7 percent of the bovine neoplasms collected were granulosa-cell tumors. None were found in sheep or swine during the 2-year period.

**Macroscopic appearance.**—These neoplasms are large and often measure 10 to 20 cm. in their greatest diameter—even larger tumors have been reported. Because of their size it may be impossible to identify remnants of the affected ovary or to determine whether multiple tumors are present in the same ovary. The tumor usually involves one ovary, although both ovaries may be affected.

Most granulosa-cell tumors of the ovary have a thick, fibrous capsule and either project from the ovary or engulf it. When incised, the growth is found to be divided by thick fibrous bands into lobules containing large cystic spaces filled with a watery red fluid. These cysts are surrounded by moderately firm tissue that may be yellow, gray, pink, or red. Areas of hemorrhage and necrosis are also present.

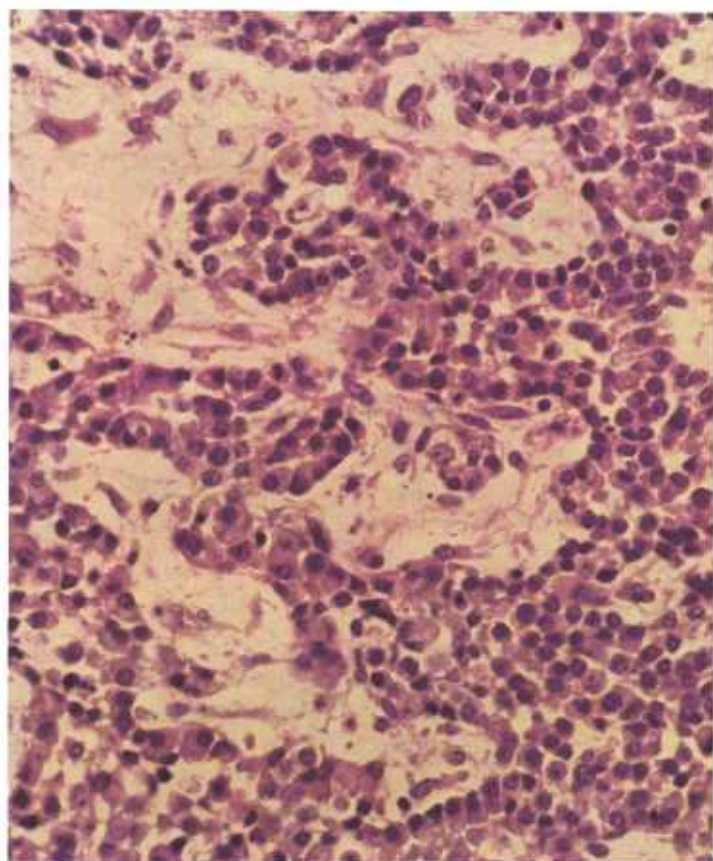


Figure 79.—Histologic preparation of the ovarian granulosa-cell tumor (A285-D2703) shown in figure 75. Note the cells are attempting to form glandular structures or graffian follicles. Hematoxylin-eosin stain,  $\times 320$ .

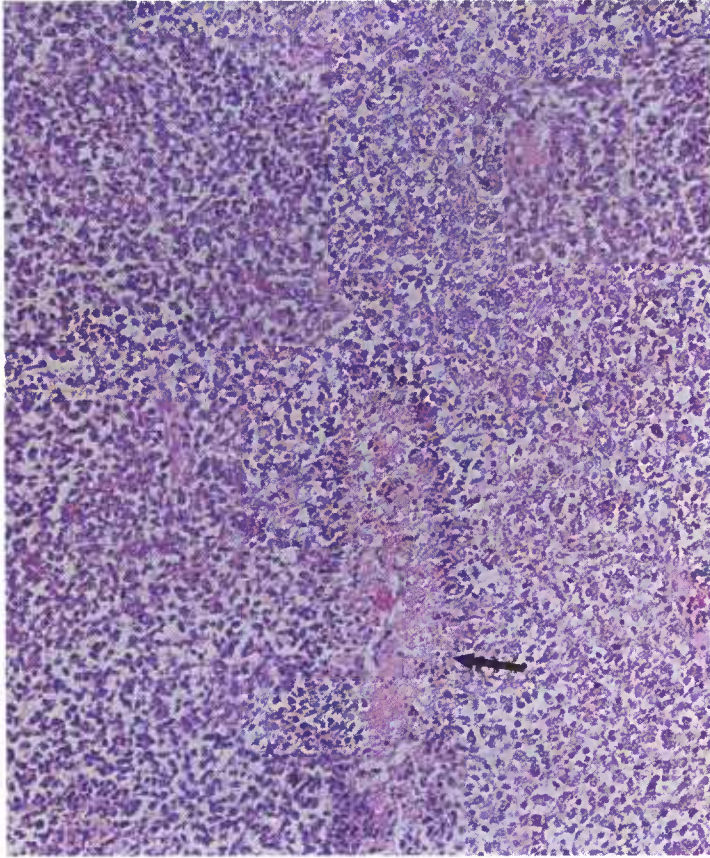


Figure 80.—Granulosa-cell tumor of the ovary in a 3-year-old Hereford cow (D3189). An area of necrosis (arrow) is a common alteration in this type of tumor. Hematoxylin-eosin stain.  $\times 125$ .

Although granulosa-cell ovarian tumors are large, locally destructive, possessed of areas of necrosis, and apparently malignant, they seldom metastasize to other tissues or organs. A few cattle have numerous tumor implants on the peritoneum caused either by spillage of cells from a ruptured neoplastic cyst or by transperitoneal metastasis. Metastases in other tissues or organs are usually confined to the internal iliac and mediastinal lymph nodes.

**Microscopic appearance.**—Since there are apparently no anatomical or behavioral differences between theca-cell tumors, luteal-cell tumors, and granulosa-cell tumors, there is no reason to refer to all three names; therefore, only the term “granulosa-cell tumor” has been retained.

These tumors are composed of large, polyhedral cells with rather small, centrally placed nuclei and abundant cytoplasm. The cells have a morphologic resemblance to granulosa cells. In many parts of the tumor, these cells are arranged in large masses with no apparent growth pattern. In other areas, they are arranged around fluid-filled spaces or appear in the form of distinct rosettes. Often, large areas of necrosis are found within the tumor and these, together with the very vascular connective tissue stroma, contribute to the formation of large cysts that are scattered throughout the growth.

## Neoplasms of the Kidney

### *Adenoma and adenocarcinoma of the kidney*

**Definition.**—Adenoma and adenocarcinoma of the kidney are neoplasms that originate from renal epithelium.

**Distribution and incidence.**—Renal epithelial tumors are uncommon findings during the meat inspection process. During the USDA's 2-year survey (see p. 1), 0.2 percent of the bovine tumors and 1.5 percent of the ovine tumors collected were adenocarcinomas of the kidney. No adenomas of the kidney were found during the same period. Neither type was found in swine. No information is available as to the sex or breed incidence of these neoplasms. They are most frequently observed in old animals.

**Macroscopic appearance.**—Adenomas of the kidney range in size from those measuring but a few millimeters to massive growths measuring as much as 20 cm. in diameter. These tumors comprise rather firm white or yellowish-white masses of tissue that may contain retention cysts. Usually, only one kidney is in-

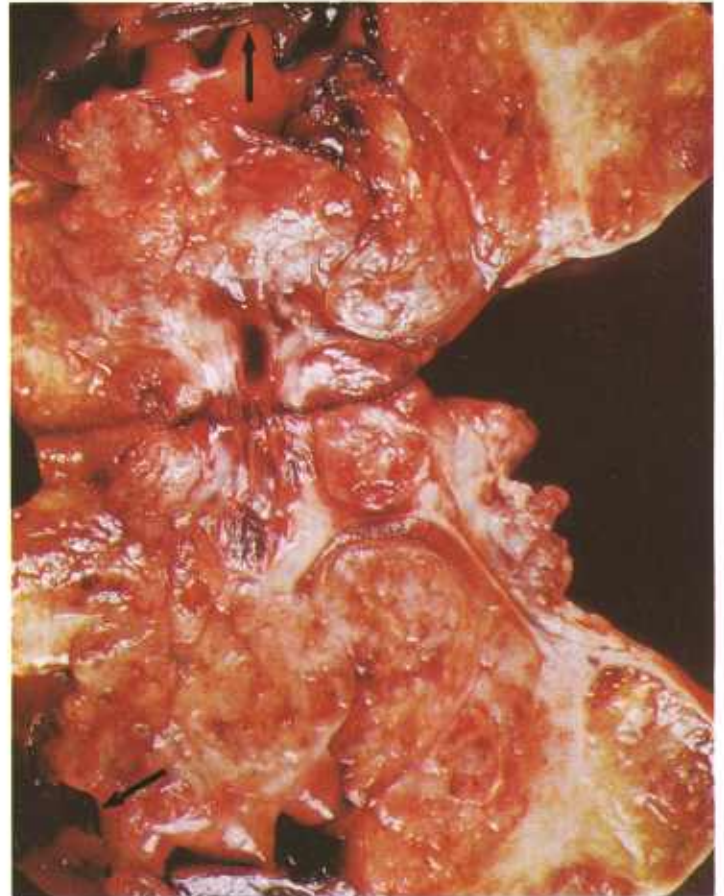


Figure 81.—Adenocarcinoma of the kidney of an old ewe (A423-D3234). A lobulated, encapsulated mass (18 by 6 by 5 cm.) has replaced nearly all of the kidney. A few remnants (arrows) of the kidney can still be seen. The tumor is firm, grayish-yellow, and very vascular, and in some areas it contains considerable mucin. Metastases are present in the lymph nodes, liver, and lungs.

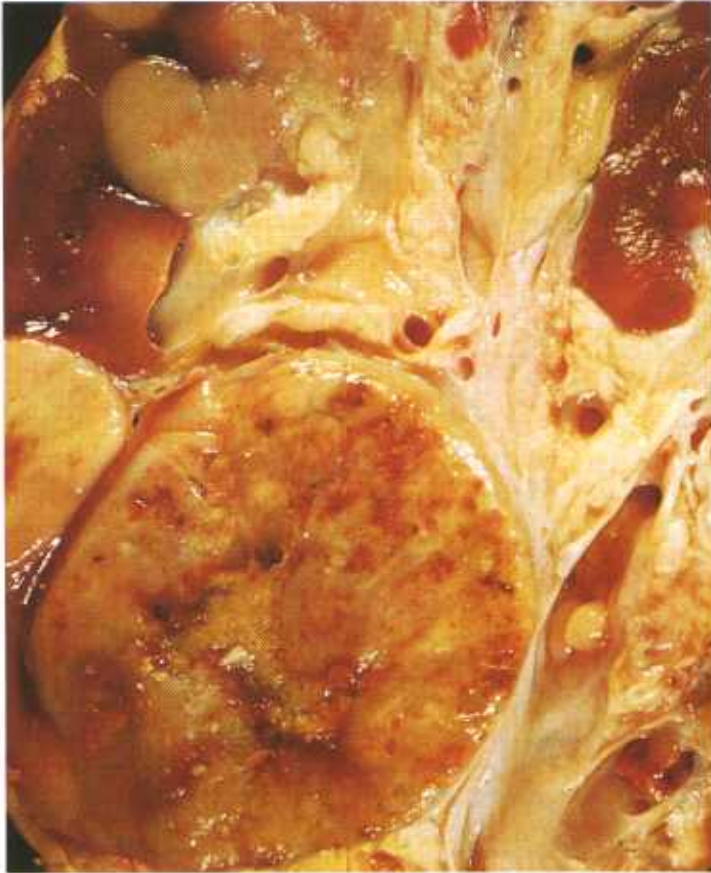

Figure 82.—Adenocarcinoma of the kidney of an old cow (A389-D3110). A vascular tumor that contains areas of necrosis and measures 8 cm. in diameter is present in the kidney, together with several smaller tumors. Similar tumors are present in the opposite kidney. Invasion of the aorta has occurred, and multiple metastatic tumors are present in the liver and the lungs.

involved. Growth of the tumor is by expansion rather than by infiltration into the surrounding renal parenchyma. The larger neoplastic masses cause considerable pressure atrophy of the kidney, and at times the renal parenchyma is represented only as a thin line of atrophic tissue adjacent to the capsule. Necrosis and hemorrhage are minimal if they occur at all.

Renal adenocarcinomas occur as single or multiple growths in one or both kidneys. These tumors are firm gray or yellow growths, predominantly oval and varying from 2 to 8 cm. in diameter. They are thinly encapsulated and may contain areas of hemorrhage and necrosis. Some of the growths penetrate the capsule, calyces, and pelvis of the kidney. Occasionally the adjacent walls of the aorta, vena cava, and hepatic vein are invaded and the tumor protrudes as rounded masses into the lumens of these structures. Metastatic tumors are found in the regional lymph nodes, liver, and lungs.

**Microscopic appearance.**—The renal adenoma is composed of tubular structures in a connective tissue stroma. These tubular structures have a mature type of cuboidal or columnar epithelium resembling that of the renal tubular epithelium. The neoplastic cells are

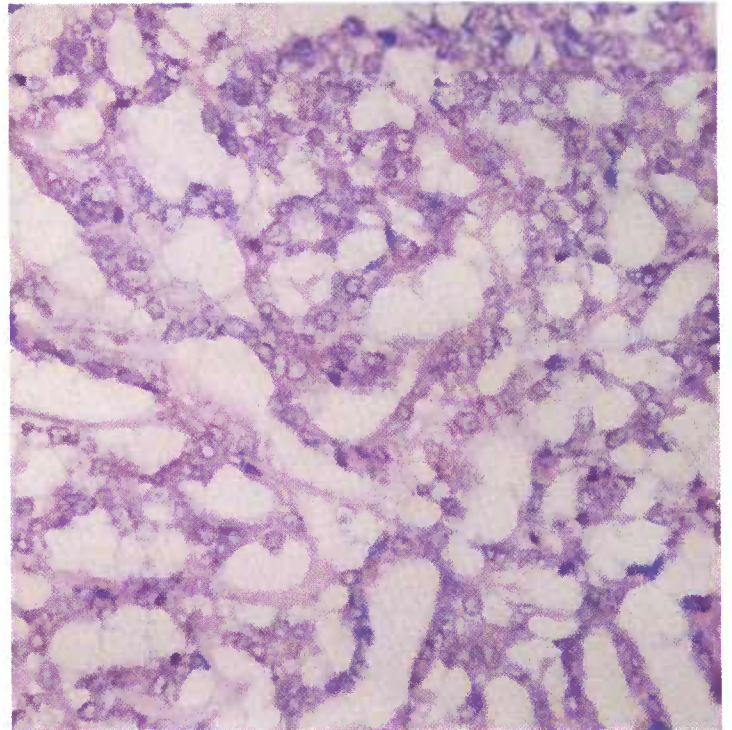


Figure 83.—Histologic preparation of the renal adenocarcinoma shown in figure 81 (A423-D3234). The tumor has a tubular pattern in which cuboidal cells with relatively large, pale vesicular nuclei form many small glandlike structures. Many of the cells are vacuolated and because of this characteristic, these tumors are often referred to as clear-celled carcinomas. Hematoxylin-eosin stain.  $\times 320$ .

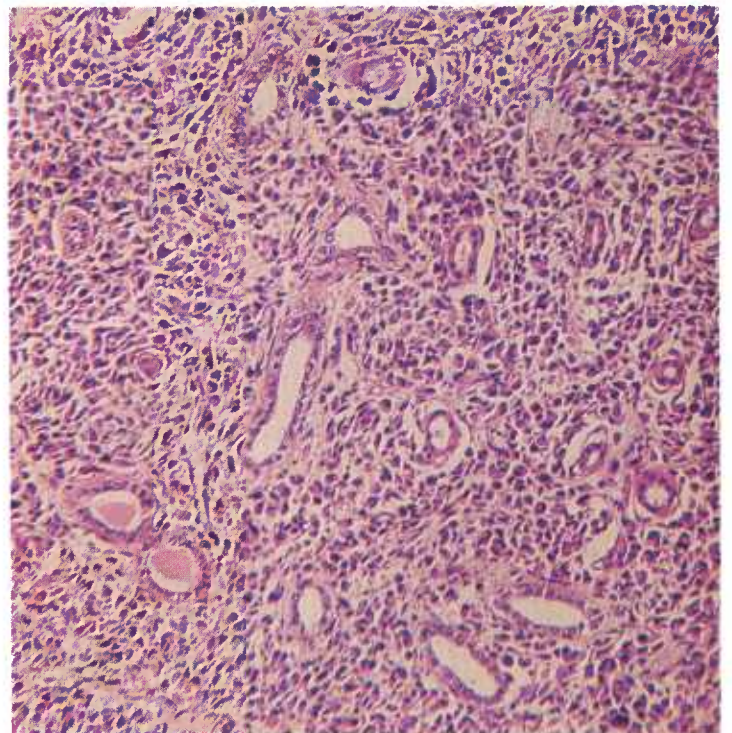


Figure 84.—Histologic preparation of the renal adenocarcinoma (A389-D3110) shown in figure 82. The neoplasm consists of a few tubules scattered through a mass of anaplastic, polygonal eosinophilic cells that have irregularly oval, hyperchromatic nuclei. Hematoxylin-eosin stain.  $\times 125$ .

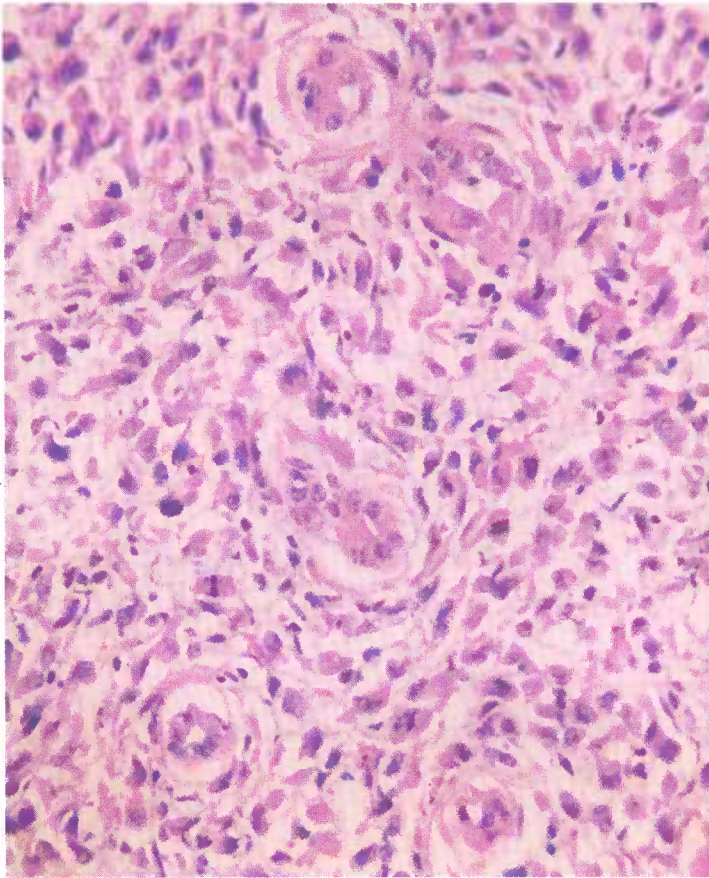


Figure 85.—A higher magnification of the renal adenocarcinoma (A389-D3110) shown in figure 84. The anaplastic polygonal cells have irregularly oval, hyperchromatic nuclei that contain many mitotic figures. Hematoxylin-eosin stain.  $\times 320$ .

regular in size and shape and contain a few mitotic figures.

The adenocarcinoma of the kidney is composed of cuboidal and columnar renal tubular epithelial cells arranged in tubules or solid masses. When arranged in tubules, the cells may have granular pink cytoplasm similar to the cells in the upper part of the nephron unit, or they may have clear cytoplasm containing lipid and glycogen like the cells in the collecting tubules. The cells with clear cytoplasm are considered to be the most characteristic type of cell in renal adenocarcinomas. When arranged in solid masses, the cells have a more anaplastic appearance. The cells vary considerably in size and shape and contain many mitotic figures. Unlike embryonal nephromas, which seldom metastasize and then late in the course of the disease, renal adenocarcinomas metastasize extensively and early in their development.

### *Embryonal Nephroma*

**Definition.**—The embryonal nephroma is a tumor composed of embryonal tissue (remnants of the Wolffian body) located in or adjacent to the kidney.

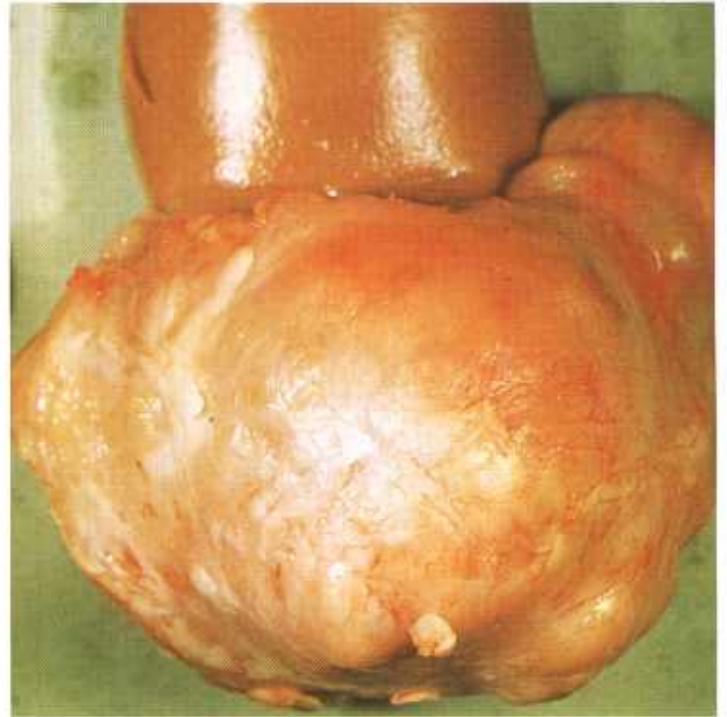


Figure 86.—The external appearance of a firm, grayish-white, encapsulated embryonal nephroma (10 by 8 by 8 cm.) present in one pole of the kidney in a 1-year-old pig (A80-D1384).

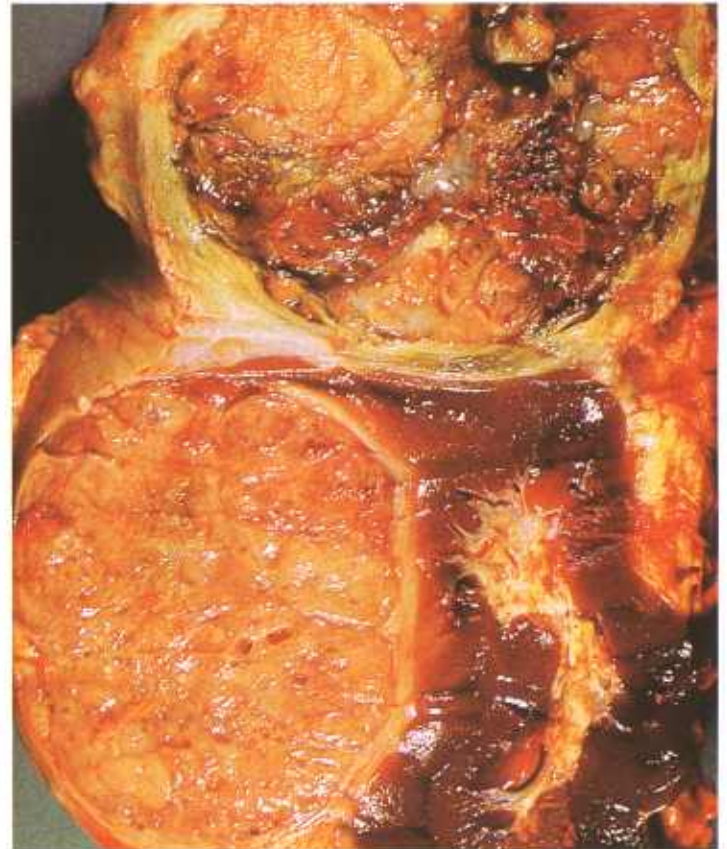

Figure 87.—Cross section of an irregularly lobulated yellow embryonal nephroma (20 by 11 by 11 cm.) containing many small cysts and involving about two-thirds of the kidney in an 18-month-old Hereford steer (A255-D2341).

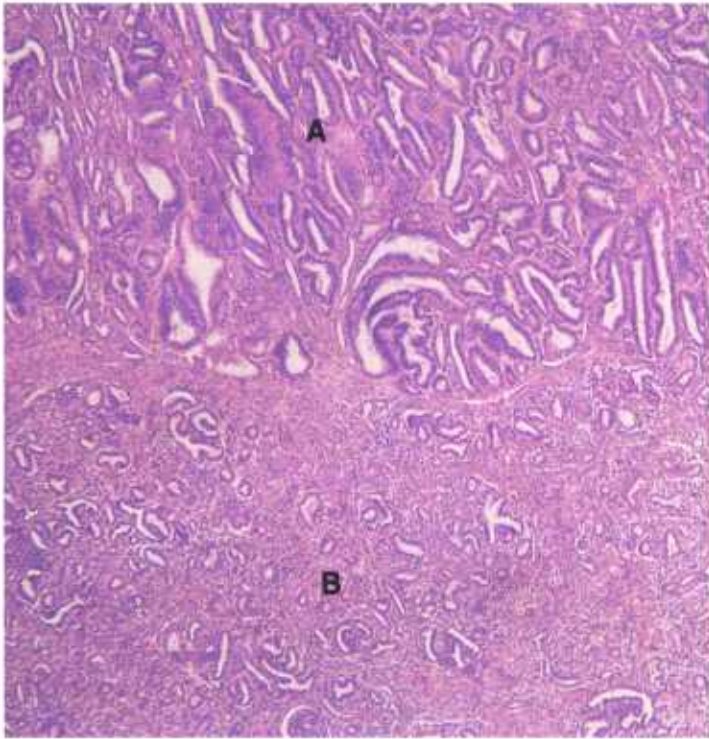


Figure 88.—Histologic preparation of an embryonal nephroma in a 3-year-old sow (D671). The growth consists of two types of tissue and is very cellular. One area (A) of the tumor is forming tubular structures while a more solid adjacent area (B) is forming structures resembling glomeruli. Hematoxylin-eosin stain.  $\times 50$ .

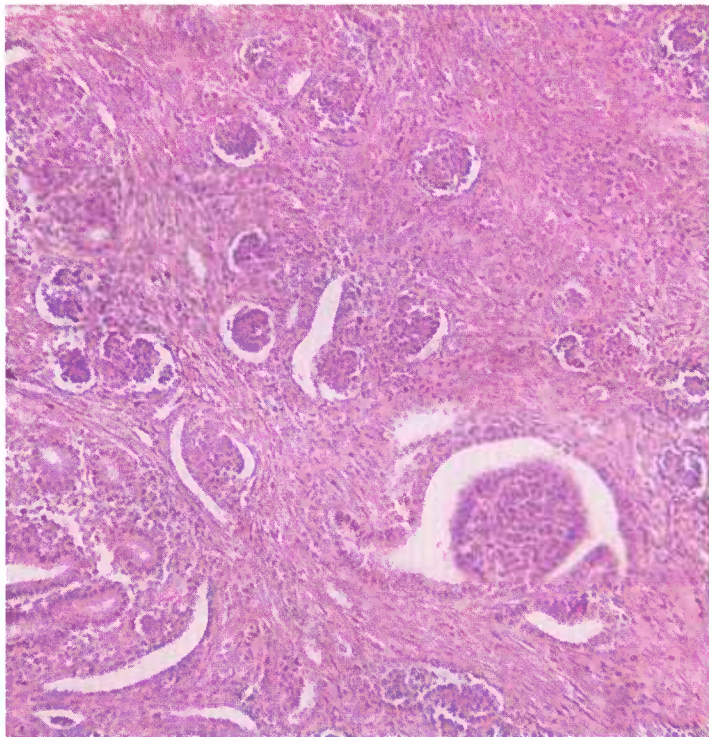


Figure 89.—Histologic preparation of an embryonal nephroma in a 1-year-old sow (D735). Supported by an abundant connective tissue stroma, epithelial elements are forming structures that resemble glomeruli. Hematoxylin-eosin stain.  $\times 125$ .

**Distribution and incidence.**—This neoplasm is found throughout the United States, occurs in all genera of meat-producing animals, and is most frequently observed in pigs. During the USDA's 2-year survey (see p. 1), 46 percent of the porcine tumors collected were of this type. The tumor occurred three times more frequently in female than in male swine, and approximately 80 percent were found in swine under 1 year of age. None were found in cattle or sheep during the same period.

**Macroscopic appearance.**—These tumors have a tendency to arise at either pole of the kidney and a few are found only loosely attached to, or separated from, the parenchyma. A third of the affected animals have either bilateral or multiple renal growths. The embryonic appearance of these tumors complements the frequency of their appearance in young swine. These tumors may become quite large: some are found to weigh 10 to 40 pounds and to measure 20 to 40 cm. in their greatest diameter. Although they increase in size during their development, only about 13 percent metastasize or show any tendency to invade adjacent renal parenchyma.

The tumors are characteristically white or light gray, are very firm, and are thickly encapsulated. Cysts and areas of necrosis are present in the larger and faster growing nephromas. Pressure atrophy of the adjacent renal tissue occurs. The tumors project from the surface of the kidneys and are distinctly lobulated.

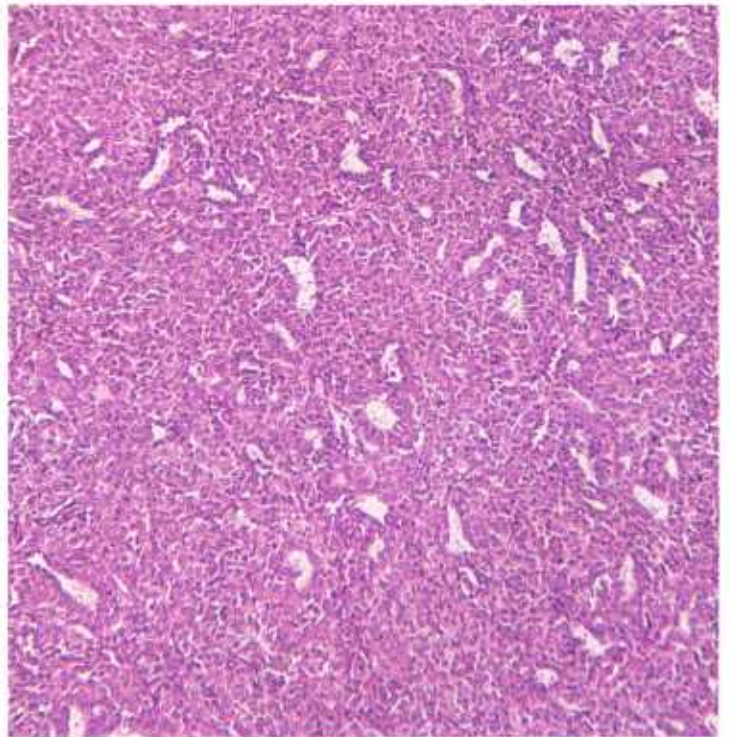


Figure 90.—Histologic preparation of an embryonal nephroma in a 6-month-old gilt (D184). The growth is a solid type having a few tubular structure formations in a dense mass of epithelial cells. Hematoxylin-eosin stain.  $\times 125$ .

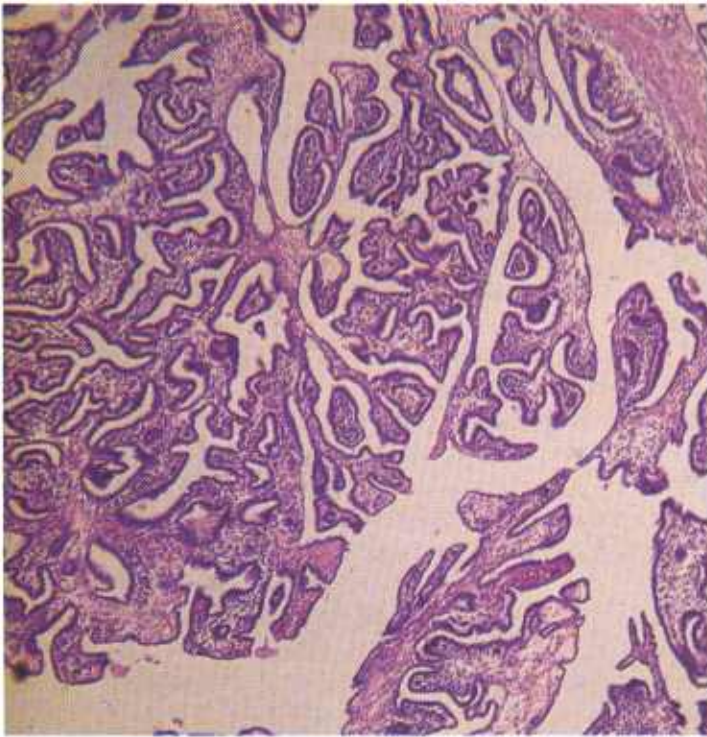


Figure 91.—Histologic preparation of an embryonal nephroma in a 6-month-old gilt (D2644). An example of the papillomatous type of growth that occurs in this neoplasm. Hematoxylin-eosin stain.  $\times 50$ .

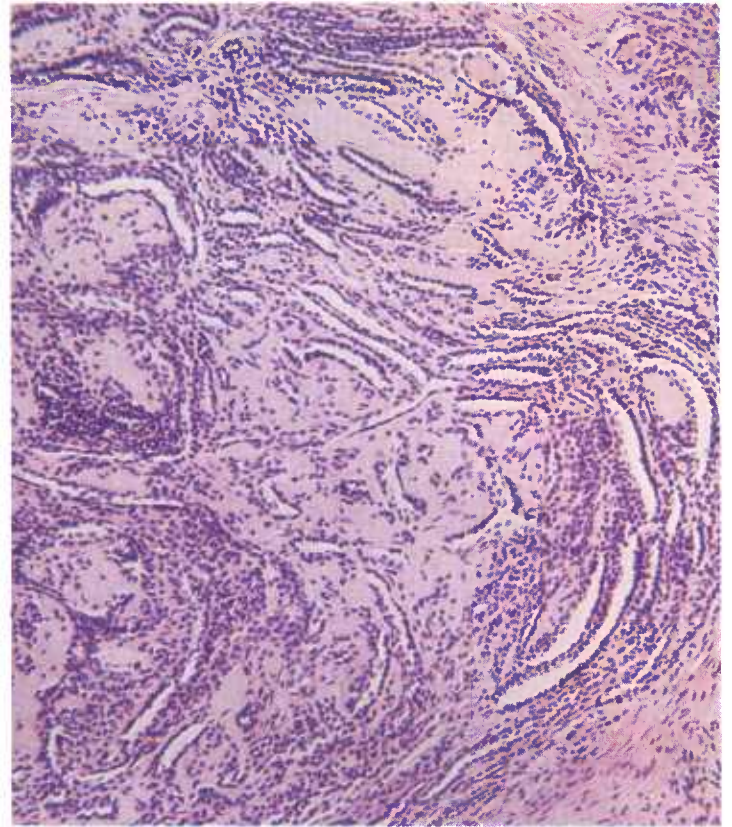

Figure 93.—Histologic preparation of an embryonal nephroma in an 8-month-old pig (D986). The tumor consists of tubular structures in a dense connective tissue stroma. Hematoxylin-eosin stain.  $\times 125$ .

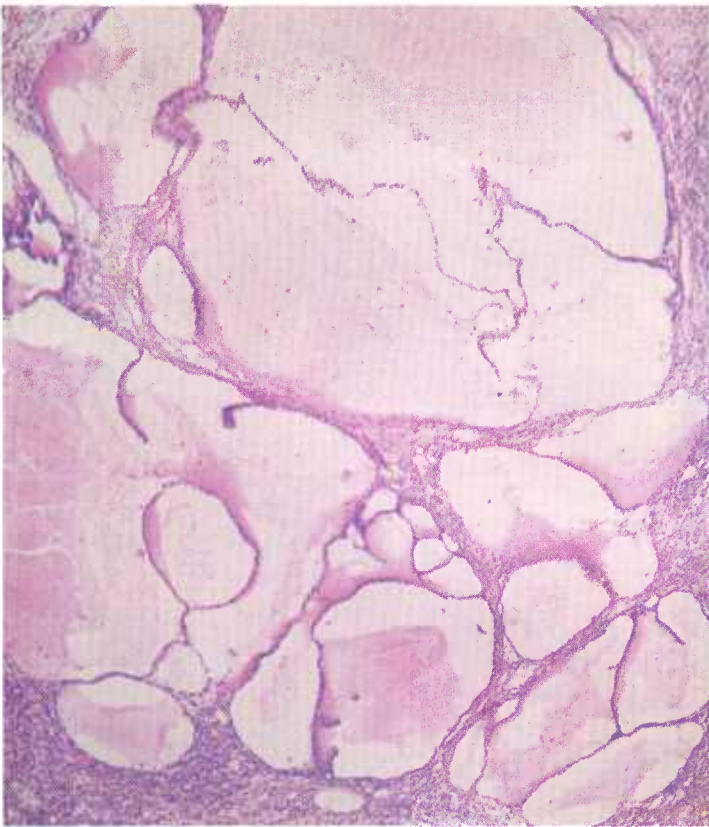


Figure 92.—Histologic preparation of a cystic embryonal nephroma in an 8-month-old gilt (D2931). The tumor is composed of cysts lined with epithelial cells and filled with a homogeneous material that stains pink with eosin. Hematoxylin-eosin stain.  $\times 50$ .

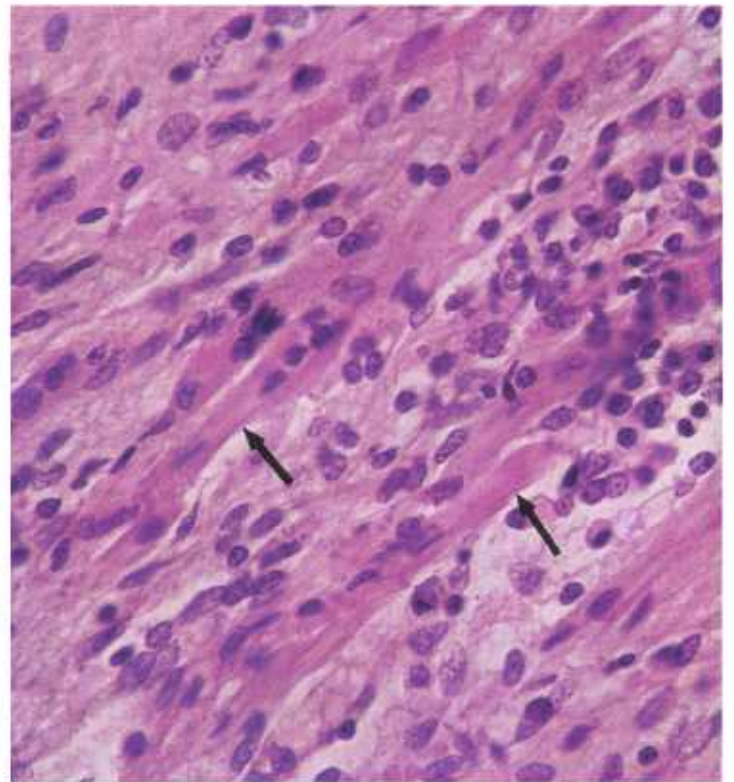


Figure 94.—Histologic preparation of an embryonal nephroma in a 3-year-old sow (D703). The tumor contains striated muscle cells (arrows). Hematoxylin-eosin stain.  $\times 500$ .

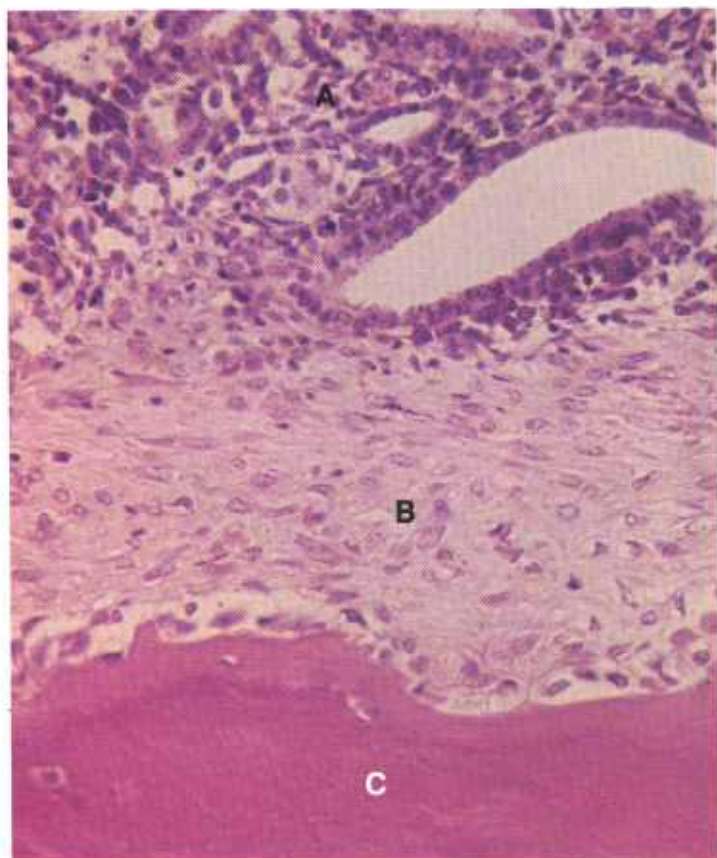


Figure 95.—Histologic preparation of an embryonal nephroma in an 8-month-old gilt (D3253). The tumor is composed of epithelial elements (A), white fibrous connective tissue (B), and bone (C). Hematoxylin-eosin stain.  $\times 320$ .

**Microscopic appearance.**—Histologically, the nephroma is a heterogeneous mixture of tissue elements with connective tissue and epithelium predominating. Strands of connective tissue from the well-developed capsule of connective tissue permeate the parenchyma of the tumor, subdividing it into masses of various sizes and shapes. In some areas the parenchyma has the appearance of a fibrosarcoma and in others of an adenoma. The cells of the sarcomatous areas are round, ovoid, or spindle-shaped. The cells of the adenomatous parts seem to be attempting to form alveoli, branching blind tubules, and occasionally, renal corpusclelike bodies. The cells forming alveoli and tubules are cuboidal or columnar. Those forming renal corpusclelike bodies are flat or cuboidal. To complicate the pattern of the tumor, sinuses and crypts filled with blood or hyaline material may be mixed with the other elements. Occasionally, smooth and striated muscles are present and, less commonly, cartilage and bone may be found. Some of the epithelial cells are in the state of mitosis.

## Neoplasms of the Liver

### *Adenoma and adenocarcinoma of the liver*

**Definition.**—Adenomas and adenocarcinomas of the liver are tumors that arise from hepatic cells. They

should not be confused with another type of liver tumor that originates from hepatic bile ducts.

**Distribution and incidence.**—Hepatic-cell tumors are found in meat-producing animals throughout the United States. In the USDA's 2-year survey (see p. 1), 0.8 percent of the bovine tumors and 11 percent of the ovine tumors collected were of this type. No hepatic-cell tumors were found in swine. These tumors are apparently more common in cows than in bulls or steers; no sex predominance has been observed in sheep. No breed incidence has been established. With few exceptions, these tumors occur in old animals.

**Macroscopic appearance.**—Hepatic-cell tumors are usually large, often measuring 10 to 20 cm. in their greatest diameter, and generally occur as single, slowly growing masses located in the right half of the liver. When palpated, most hepatic-cell tumors have a consistency similar to that of liver. A fibrous capsule, usually thin, may enclose the neoplasm, separating it from the adjacent liver. When a relatively thick capsule is present, the free surface of the growth may have a slightly nodular appearance.

These tumors are usually light brown and may approach the color of normal liver. The more malignant growths are gray or white, with yellow and green dis-

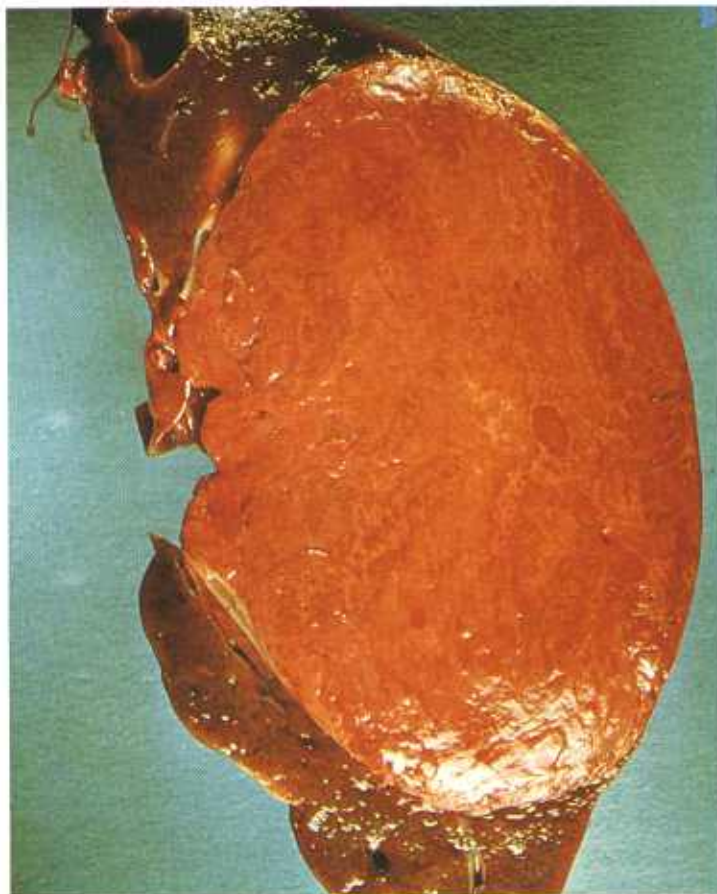

Figure 96.—A soft, fatty, oval adenocarcinoma of the liver of a 7-month-old sheep (A432-D3419). The tumor is separated from the liver by a thin capsule. No invasion of other organs has occurred.

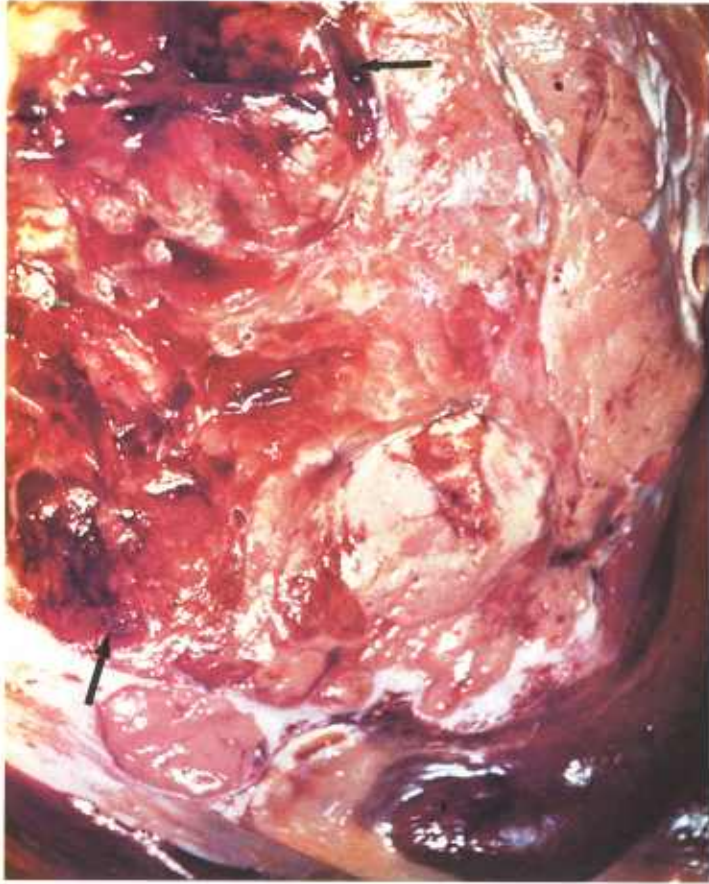


Figure 97.—A soft, buff-colored adenocarcinoma measuring 20 cm. in diameter is present in the liver of an adult ram (A88-D1430). The central part of the tumor contains areas of hemorrhage and necrosis (arrows). Metastatic tumors (not visible) are present in the portal lymph nodes.

colorations in areas where bile is entrapped. They may contain brown or reddish-purple areas if much hemorrhage or necrosis exist within. Color changes in sheep adenomas of the liver are less predictable. Many of the ovine tumor cells undergo a fatty metamorphosis that causes a white or gray color change in the growth. Reddish punctate areas of hematopoiesis are present throughout many of the growths occurring in sheep.

Metastases occur late in the course of the disease and are few in number. Before metastases occur in adjacent lymph nodes and more distant organs, multiple satellite growths usually appear in the liver.

**Microscopic appearance.**—Most of the bovine hepatic-cell tumors and many of the corresponding ovine tumors are composed of mature cells. Hepatic-cell tumors of the liver consist of characteristic polyhedral-shaped hepatic cells (usually larger than normal liver cells) that contain eosinophilic, granular cytoplasm and large nuclei with thick nuclear membranes. The large nuclei with their large nucleoli, particularly when examined in giant cell formations, are helpful in identifying the less highly differentiated tumors.

A distinctive characteristic of hepatic-cell tumors is the persistence of hepatic cord patterns in most of the

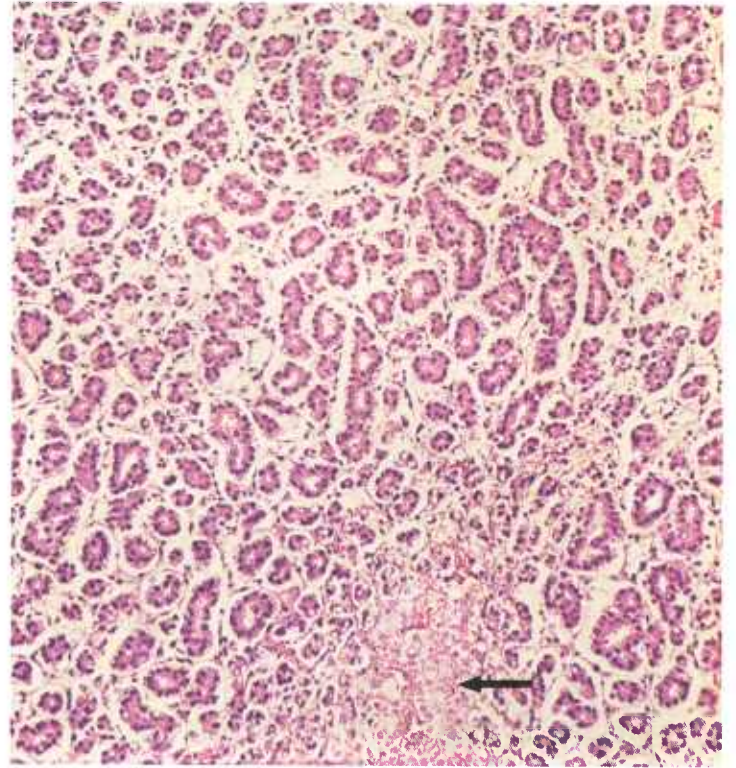


Figure 98.—A histologic preparation of an adenocarcinoma of the liver of a 1-year-old sheep (D2436). The tumor cells are arranged in alveoli that are separated by a delicate connective tissue stroma. An area of necrosis (arrow) is present. Hematoxylin-eosin stain.  $\times 125$ .

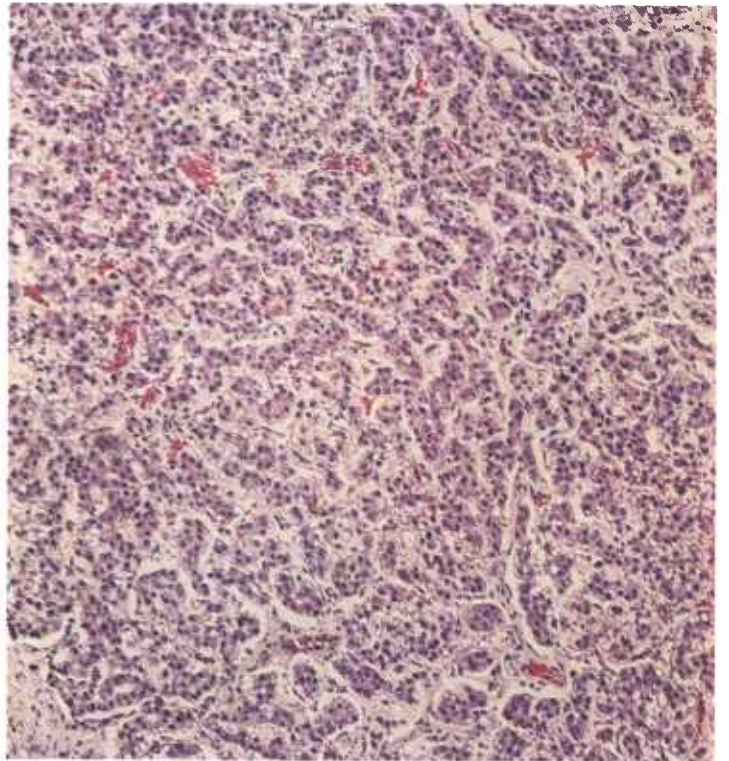


Figure 99.—A histologic preparation of a soft, brown, nodular adenocarcinoma of the liver of a 5-year-old ewe (D1491). The tumor is composed of epithelial cells arranged in elongated structures that resemble hepatic cords. Many of the tumor cells contain fat droplets. Hematoxylin-eosin stain.  $\times 125$ .

growths. These cords of cells may be two or three cells wide and resemble normal hepatic cords, or they may occur as masses of cylindrical projections that are 15 to 20 cells wide. Usually the only stroma associated with these tumor cell patterns is that accompanying the capillaries that ensheath the individual cords. This cord pattern of growth is helpful in differentiating hepatic-cell tumors from bile duct carcinomas.

Hepatic-cell tumors lack central veins, hepatic triads, and bile duct systems. The absence of these structures is an aid in diagnosis. Because of the absence of a bile duct system, any bile produced by the neoplastic cells cannot be eliminated except by diffusion. As a result, bile pigment can often be seen within the neoplastic tissue. Canaliculi, which may form cystic spaces, can be found within the hepatic-cell tumor. If bile is found either in these canaliculi and cystic spaces or within tumor cells, the identity of the tumor is established. Its large cystic spaces, filled with a homogeneous material and bordered by neoplastic cells, may confuse the examiner unless he realizes that the material is bile and the spaces are dilated canaliculi.

The difference between hepatic-cell tumors and hepatic bile duct tumors may be difficult to demonstrate because, embryologically, both hepatic cells and bile

duct cells are derived from the same stem cell. Since the hepatic cells and the bile duct cells have a common embryologic origin, it is understandable that in the more anaplastic neoplasms a point of anaplasia is reached when it is probably impossible to differentiate between the two types of neoplasms.

#### *Adenoma and adenocarcinoma of the hepatic bile ducts*

**Definition.**—Adenomas and adenocarcinomas of the hepatic bile ducts are limited to those tumors that arise from the intrahepatic bile duct system.

**Distribution and incidence.**—Hepatic bile duct tumors are probably found in meat-producing animals throughout the United States. During the USDA's 2-year Denver survey (see p. 1), 0.1 percent of the bovine tumors and 1.5 percent of the ovine tumors collected were found to be adenomas and adenocarcinomas of the bile ducts. No sex or breed predominance has been established. All of the neoplasms we have observed have occurred in old animals.

**General comments.**—Tumors of the intrahepatic bile ducts can easily be confused with other pathologic conditions: tumors of the hepatic cells, congenital or acquired cysts of the biliary ducts, hyperplasia with a

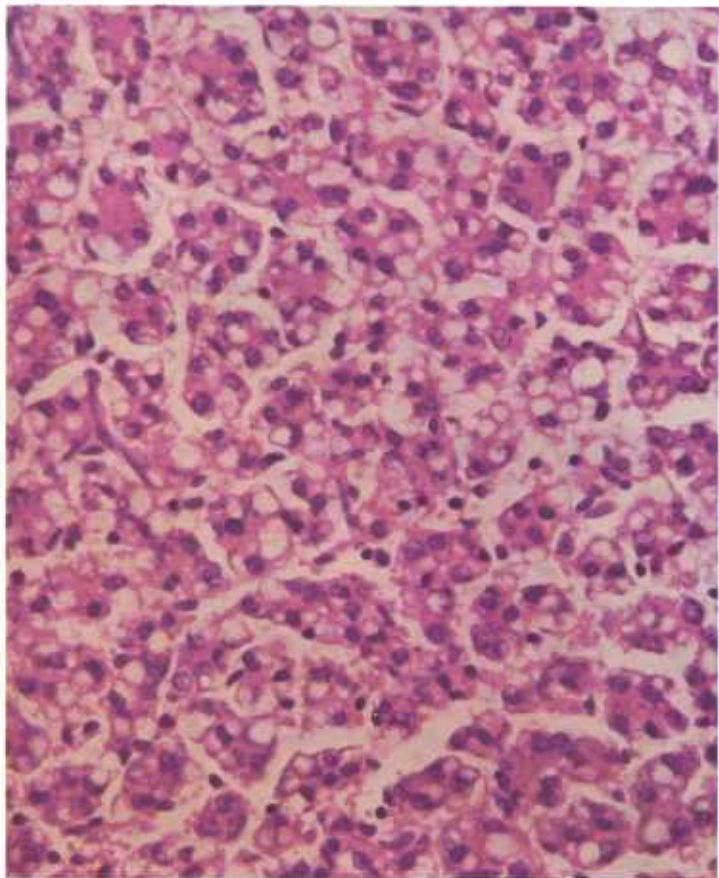


Figure 100.—A histologic preparation of an adenoma of the liver in a 1-year-old sheep (D3246). The tumor cells are arranged in cords and their cytoplasm contains many fat droplets. Hematoxylin-eosin stain.  $\times 320$ .

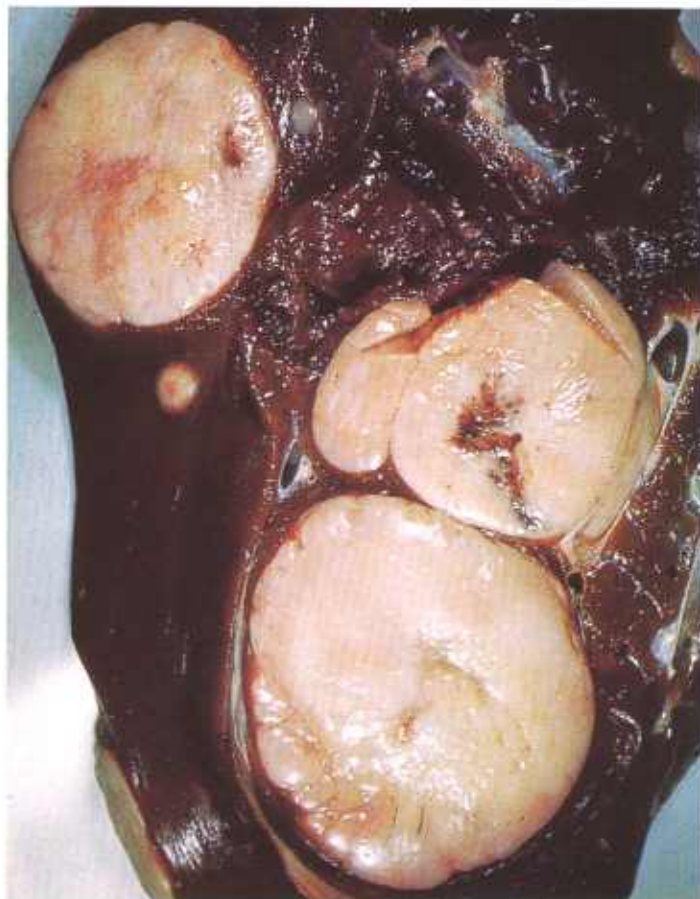

Figure 101.—Adenocarcinoma of the bile ducts of a ewe (A99-D1449). Multiple soft, tan tumor nodules that measure as much as 6 cm. in diameter are present in the liver.

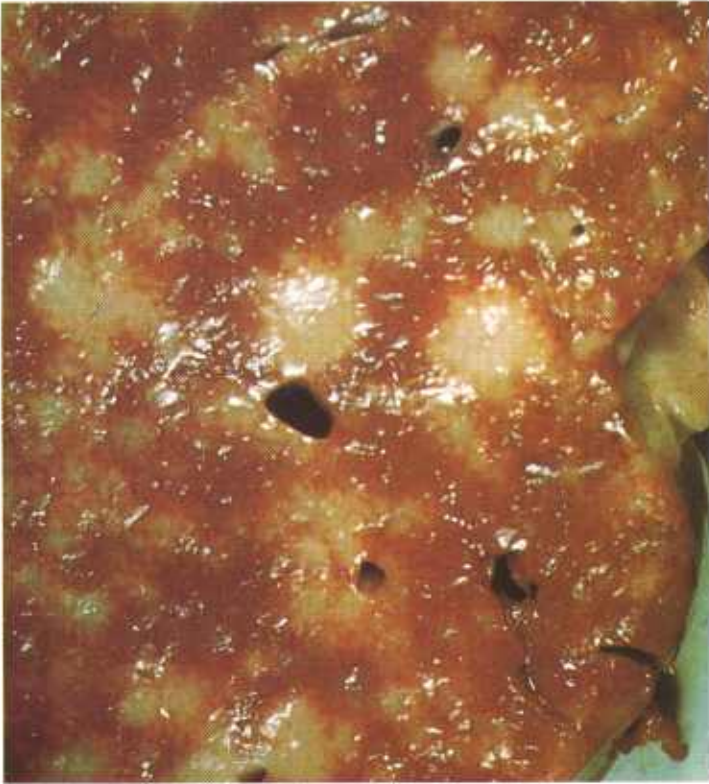

Figure 102.—Adenocarcinoma of the bile ducts of a 5-year-old ewe (A84-D1412). There is diffuse involvement of the liver with multiple white tumor nodules that are slightly discolored with bile.

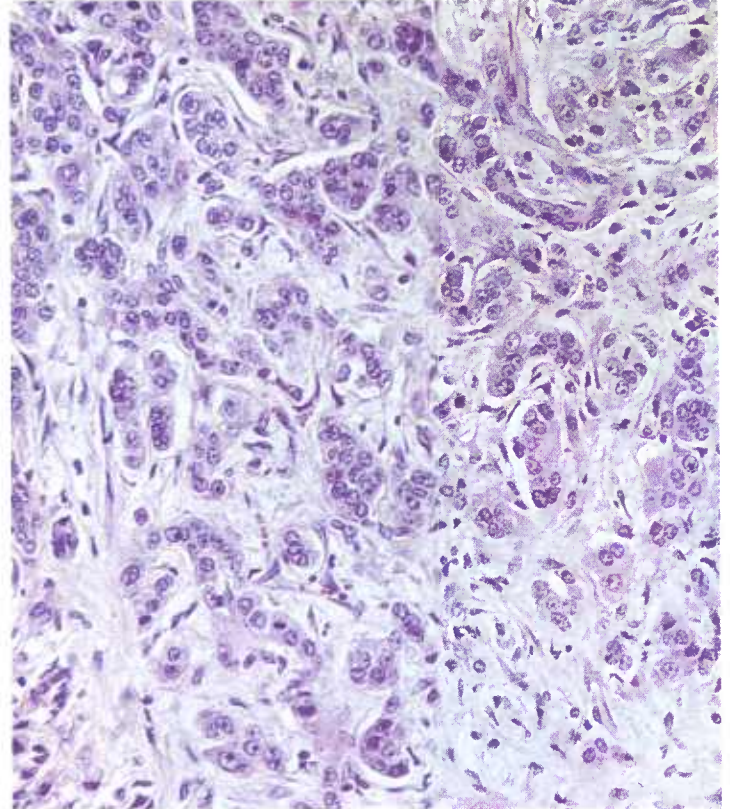


Figure 104.—A histologic preparation of the adenocarcinoma (A84-D1412) shown in figure 102. The neoplastic cells are attempting to form bile ducts. Hematoxylin-eosin stain.  $\times 320$ .

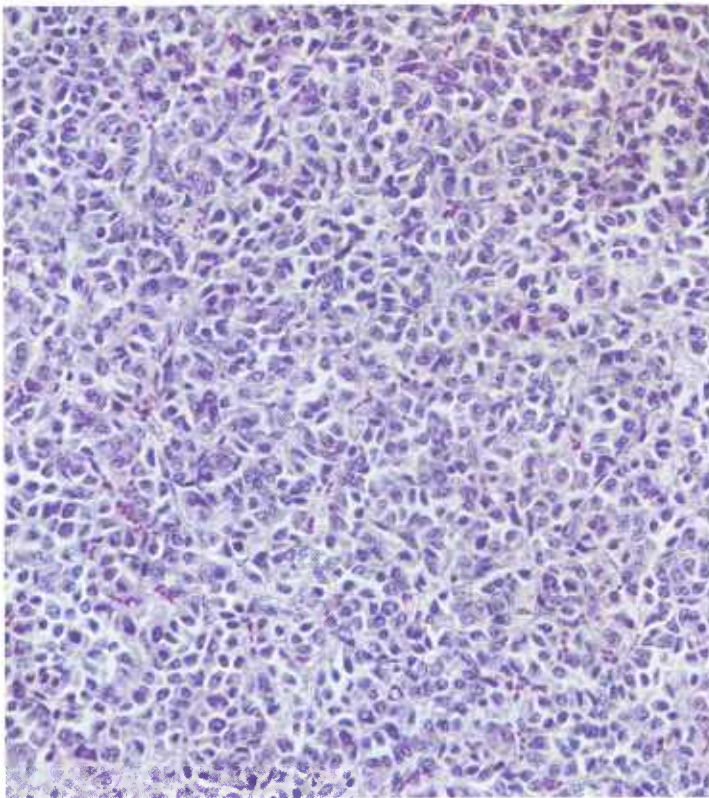


Figure 103.—A histologic preparation of the adenocarcinoma (A99-D1449) shown in figure 101. The growth is very cellular, and the cells have a tendency to be arranged in acini and tubular structures. Hematoxylin-eosin stain.  $\times 125$ .

wide range of causes—such as the invasion of the biliary ducts by flukes—and hyperplasia caused by highly chlorinated naphthalenes or poisonous plants—such as senecio, tarweed, vetch, and spurge. Hepatic bile duct tumors can also be confused with metastases from other glandular tumors, including those of the extra-hepatic biliary ducts and gallbladder. For this reason, a very careful examination of the viscera must be made to determine whether a primary neoplasm is present in some other organ.

**Macroscopic appearance.**—Hepatic bile duct tumors usually occur as large solitary masses that measure as much as 25 cm. in their greatest diameter. Their size and shape are very similar to those of hepatic-cell tumors. They are usually gray, grayish white, or yellowish white, are firm in consistency, and are often cystic. Most have a minimal connective tissue stroma and do not form a distinct capsule; however, they do tend to have more connective tissue stroma than hepatic-cell tumors.

**Microscopic appearance.**—Tumors of the hepatic bile ducts are composed of cuboidal or columnar cells and are usually arranged in an acinar pattern. Distinct hepatic bile duct formation can usually be found in some part of the neoplasm. Occasionally, areas of the tumor will contain large polyhedral-shaped cells that resemble hepatic cells. Histologically, these tumors are true adenocarcinomas. They do not produce bile and are not bile stained. The neoplastic cells can produce mucus; and the accum-

ulation of mucus within the tumor results in the formation of cysts. The tumors have a minimal connective tissue stroma and do not form a distinct capsule between the neoplastic tissue and the adjacent hepatic parenchyma.

Because of the difficulty in differentiating tumors of the hepatic bile ducts from the more anaplastic hepatic-cell tumors of the liver, it is important to remember that the neoplastic acini and tubules in hepatic bile duct tumors frequently contain mucus but never bile. Further, hepatic bile duct tumors, in their rather frequent invasions of the portal vein, often take the form of papillary or cystic projections instead of assuming the hepatic cord pattern characteristic of hepatic-cell tumors.

### *Adenoma and adenocarcinoma of the gallbladder*

**Definition.**—Adenomas and adenocarcinomas of the gallbladder are neoplasms that arise from the mucous membrane of that organ.

**Distribution and incidence.**—Gallbladder neoplasms are probably quite common in cattle throughout the United States, although their presence is usually not

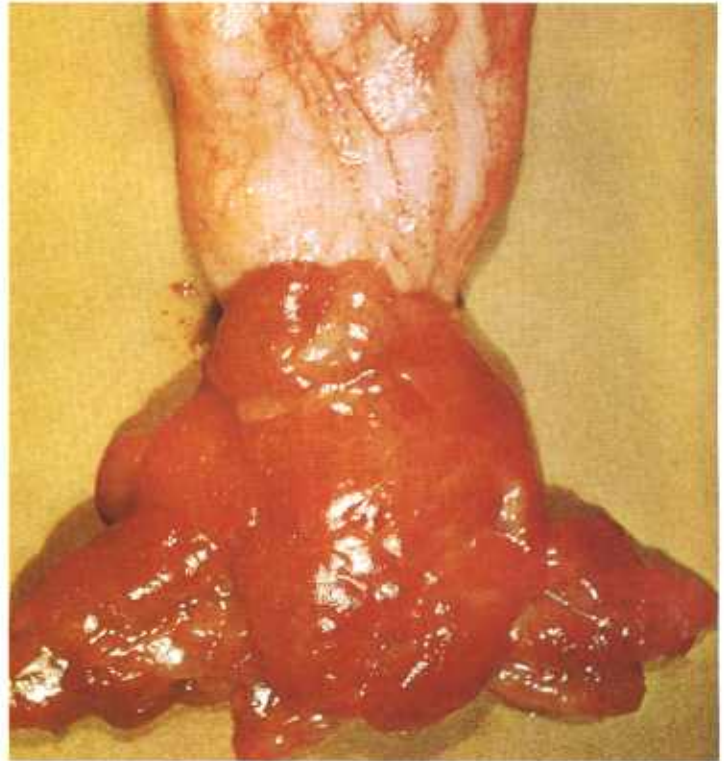


Figure 106.—Adenoma of the gallbladder of a 5-year-old cow (A42-D1344). A papillary, mucinous growth that contains multiple small cysts is attached to the fundus of the gallbladder.

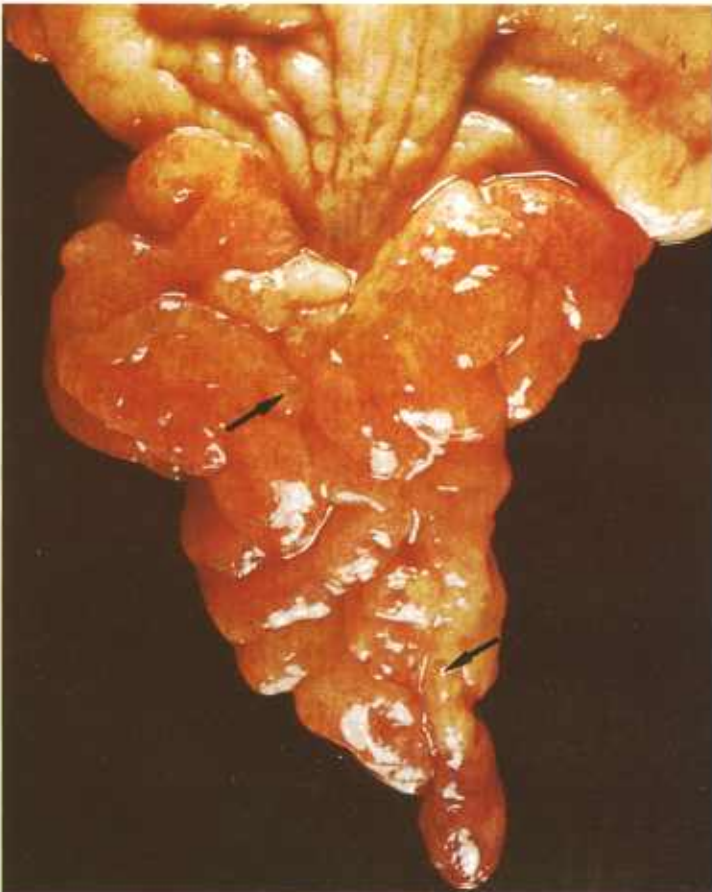


Figure 105.—Adenoma of the gallbladder of a 3-year-old Hereford steer (A412-D3166). A papillary, yellowish-pink growth (10 by 3 by 1 cm.) covered with a mucous membrane and containing multiple small cysts is arising from the fundic end of the gallbladder.

recognized. The USDA's 2-year survey of neoplasms collected in Denver abattoirs (see p. 1), found 1.0 percent of the bovine neoplasms to be of this type. None were found in other genera. Tumors of the gallbladder are most frequently seen in young steers and heifers at slaughter, although they are also found in older bulls and cows. No breed predominance has been established.

It is probable that the incidence of adenomas would be quite high if the meat inspection procedure led to the gallbladder's receiving the same careful scrutiny that is afforded the liver and the common bile duct. As it is, the practice of immediately discarding the gallbladder results in its being given only a cursory exterior examination, unless the painstaking inspector elects to palpate it or incise it or unless a large invasive growth is present. In contrast to adenomas of the gallbladder, carcinomas of the organ are believed to be very uncommon, since invasion of the gallbladder wall and penetration of the liver could scarcely escape detection at postmortem inspection.

**Macroscopic appearance.**—Tumors of the gallbladder occur as papillary cystadenomas and occasionally as papillary cystadenocarcinomas. They originate from the mucosa of the gallbladder and nearly all of the growths arise in the fundus. Their size is varied, and they may be as much as 5 to 7 cm. in diameter. These tumors sometimes distend the gallbladders moderately, occupying most of the lumen, and on occasion, protrude into the neck. It is uncommon to find visible external evidence of neoplasia. In appearance the papillary cyst-

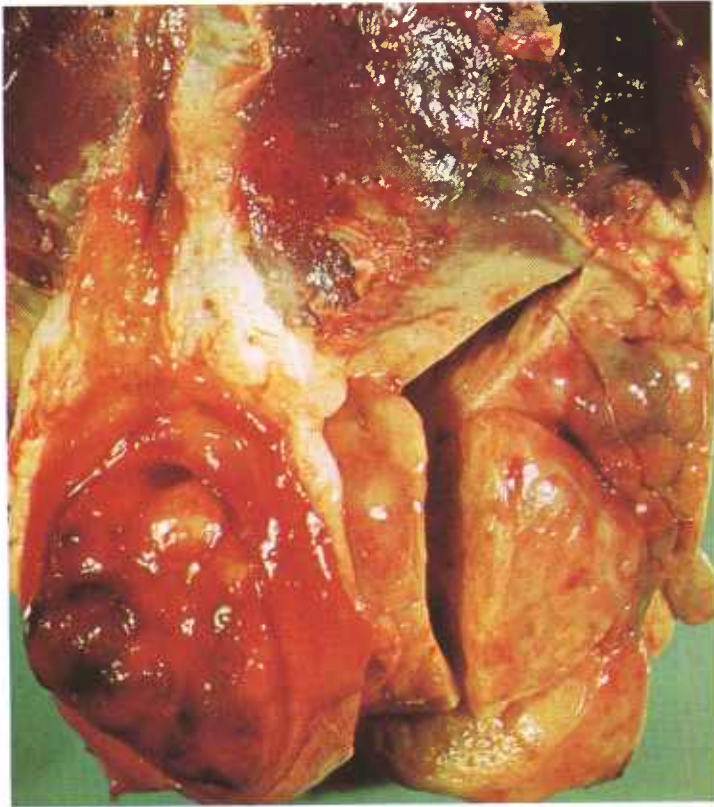

Figure 107.—Adenocarcinoma of the gallbladder of a 6-year-old Hereford cow (A306-D2736). The tumor consists of a firm, yellowish-red, rugose growth measuring 10 cm. in diameter. The neoplasm has penetrated the gallbladder wall and has invaded the adjacent liver tissue. Metastatic tumors are present in the portal lymph nodes (not visible).

adenoma is a solitary red or gray epithelial-covered mass attached to the wall of the gallbladder by a thick, short stalk. The diameter of the basal area of attachment ranges from 1 to 4 cm. and in some instances the tumor assumes a sessile character. Frequently, the surface of the growth forms teatlike or cone-shaped papillary projections that protrude for 2 to 4 cm. into the lumen of the gallbladder. Again, the surface may have a cauliflowerlike appearance. Occasional tumors have a rugose character or a surface raised in smooth, rounded masses and indistinct lobules. Numerous cysts are present in many of the tumors and the entire growth usually has a mucinous character. Frequently, the affected gallbladder contains considerable quantities of thick, tenacious, mucinous exudate.

The only papillary adenocarcinoma in our possession is a firm, yellowish, rugose tumor that measures 10 cm. in diameter, and has a point of origin midway between the neck and fundus. The growth has invaded the wall of the gallbladder and has extended into the adjacent liver. The portal lymph nodes are tumified. No other metastases are present. In contrast to the benign growths this tumor is readily apparent on visual examination of the liver and gallbladder.

**Microscopic appearance.**—The mucosal surface of benign papillary cystadenomas of the gallbladder are cov-

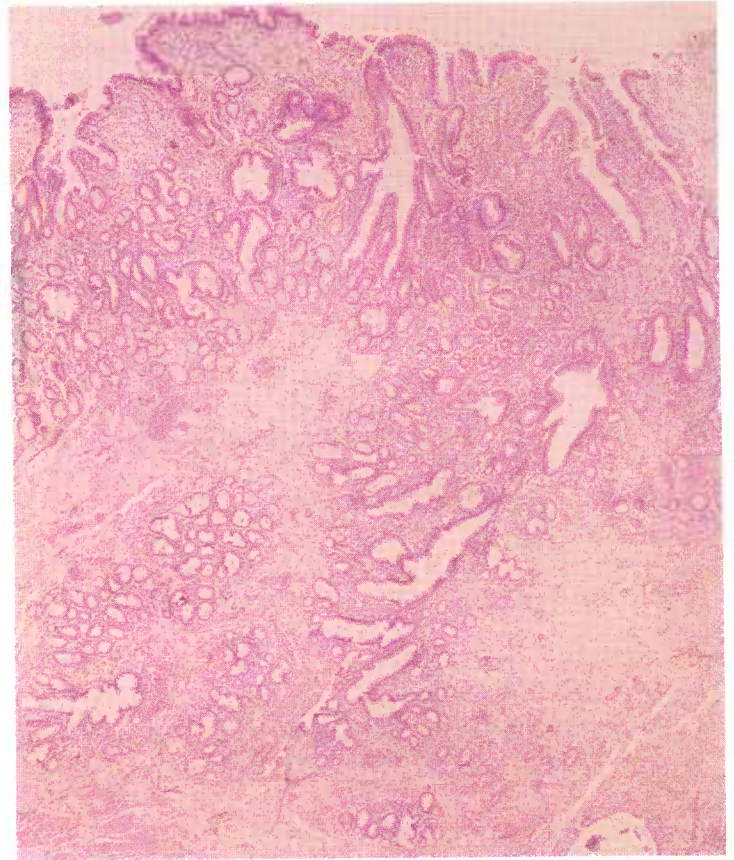


Figure 108.—A histologic preparation of an adenoma of the gallbladder in an old Hereford cow (D2138). The tumor is composed of columnar epithelium that has a papillary and glandular arrangement. Hematoxylin-eosin stain.  $\times 20$ .

ered by a single layer of tall columnar epithelial cells continuous with the epithelium of the adjacent normal gallbladder mucosa. This epithelial covering is thrown into long-branched infoldings that extend for a considerable distance into the underlying connective tissue stroma and are in turn continuous with the papillary, glandlike structures that make up the bulk of the neoplasm. When these tubular alveolar structures are cut in cross section, they look like regular acinic spaces lying in a loose edematous connective tissue stroma. They are frequently dilated and are sometimes so distended that they form cystlike spaces that may be grossly visible. The tall columnar neoplastic cells resemble the epithelial lining of the normal gallbladder mucosa and have clear cytoplasm and basally placed oval nuclei. They are uniformly arranged in single layers lining the alveolar spaces, with their deeply staining nuclei appearing as dark borders around the perimeters of the spaces.

Deep within the growth, usually close to the muscularis, there is also a proliferation of low columnar cells arranged in an adenomatous pattern. The cytoplasm of these cells is frequently granular and stains deeply with eosin. The cells resemble the cells of the mucous glands of the normal gallbladder.

Adenocarcinoma of the gallbladder resembles its be-

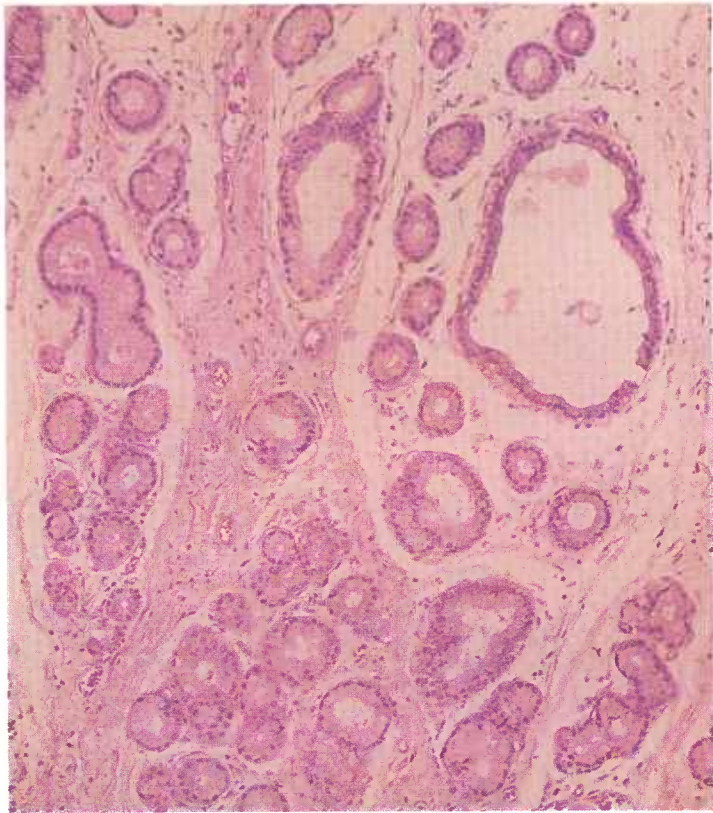


Figure 109.—A histologic preparation of an adenoma of the gallbladder in a 2-year-old steer (D1562). The tumor is composed of mucin-producing glandular epithelium arranged in alveoli supported by an edematous connective tissue stroma. Hematoxylin-eosin stain.  $\times 125$ .

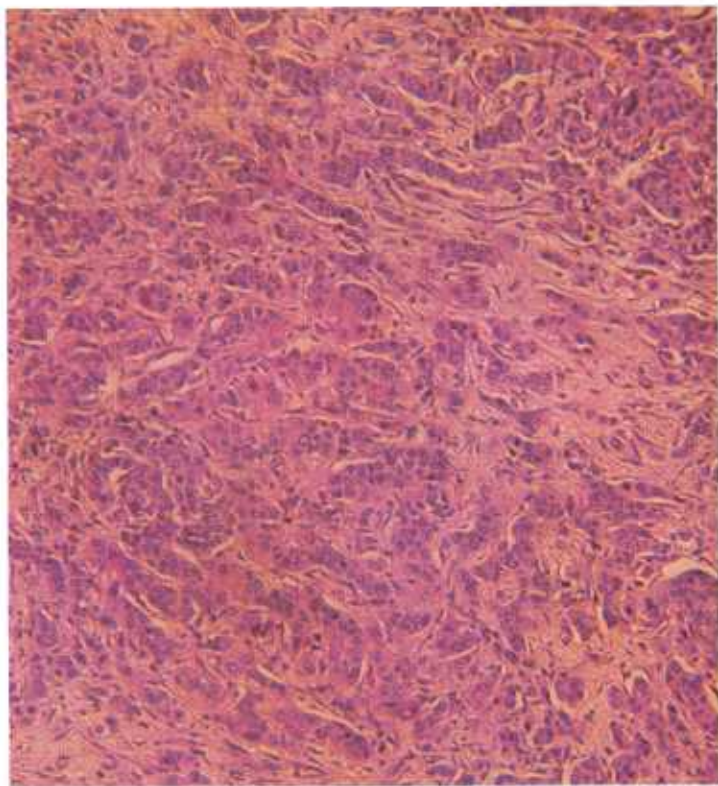


Figure 110.—A histologic preparation of the adenocarcinoma of the gallbladder (A306-D2736) shown in figure 107. Hematoxylin-eosin stain.  $\times 125$ .

nign counterpart in the superficial part of the primary growth that protrudes into the lumen of the gallbladder. Deep within (and extending into the liver), the growth becomes more fibrous and nests of tumor cells resembling the low columnar cells of mucous glands are found scattered through a dense collagenous connective tissue matrix. The glandular pattern persists, but the neoplastic cells are arranged as irregularly shaped groups of anaplastic cells. They frequently form a stratified epithelium instead of an ordered single-cell layer. Many of the acini are filled with debris, and scattered focal areas of necrosis, with beginning calcification, are present. Mitotic figures are readily discerned and no encapsulation is evident.

## Neoplasms of the Lung

### *Adenoma of the lung*

**Definition.**—Adenomas of the lung are benign neoplasms that probably result from developmental defects (hamartomas) of lung tissue.

**Distribution and incidence.**—Although adenomas of the lung are believed to occur throughout the United States, no information is available as to the geographic distribution of this neoplasm. In the USDA's 2-year Denver survey (see p. 1), 0.1 percent of the bovine tumors collected were adenomas of the lung. None were found in swine or sheep. No sex incidence has been established. Pulmonary adenomas are most frequently ob-

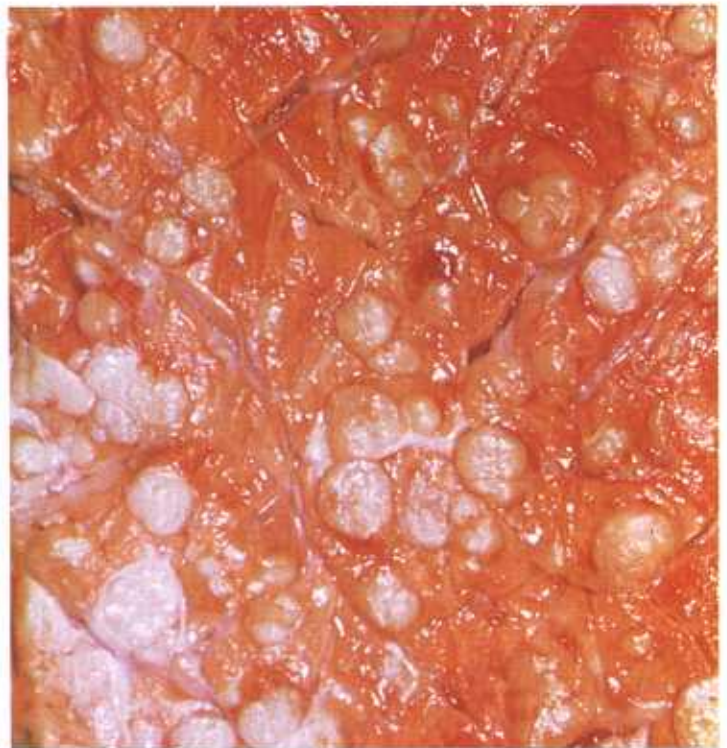

Figure 111.—Cut surface of an adenoma of the lung in a 2-year-old Hereford cow (A6-D1241). Multiple soft, gray nodules that measure 1 mm. to 1.5 cm. are scattered through all lobes of the lung.

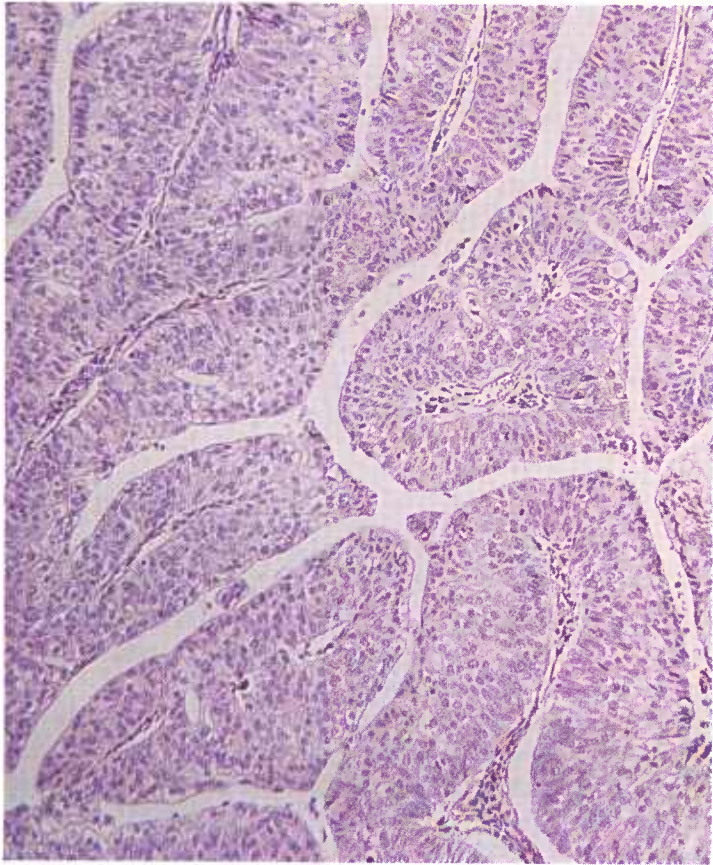


Figure 112.—Histologic preparation of an adenoma of the lung of a 2-year-old steer (D2155). The glandular epithelium is several cells thick and has a pseudostratified appearance. Hematoxylin-eosin stain.  $\times 125$ .

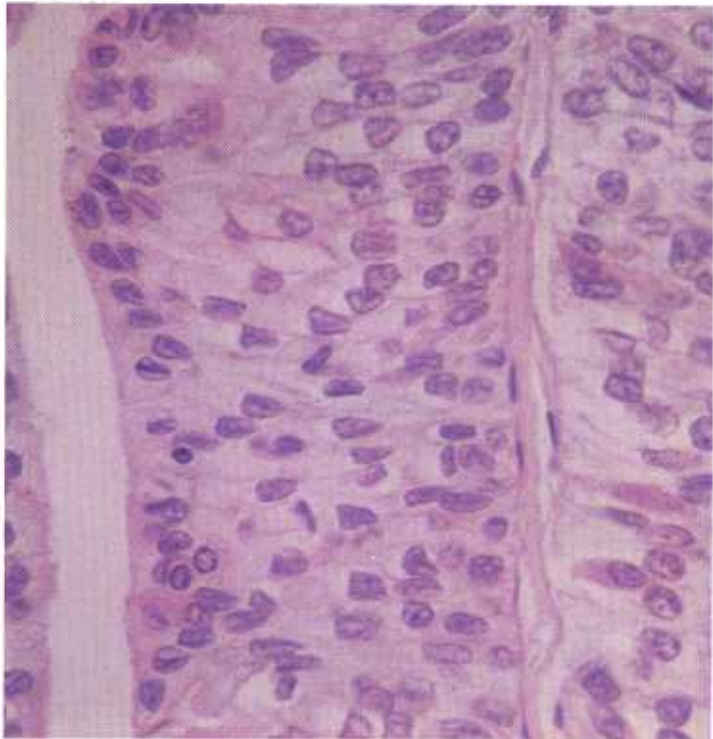


Figure 113.—A higher magnification of the histologic preparation of the adenoma (D2155) shown in figure 112. Hematoxylin-eosin stain.  $\times 500$ .

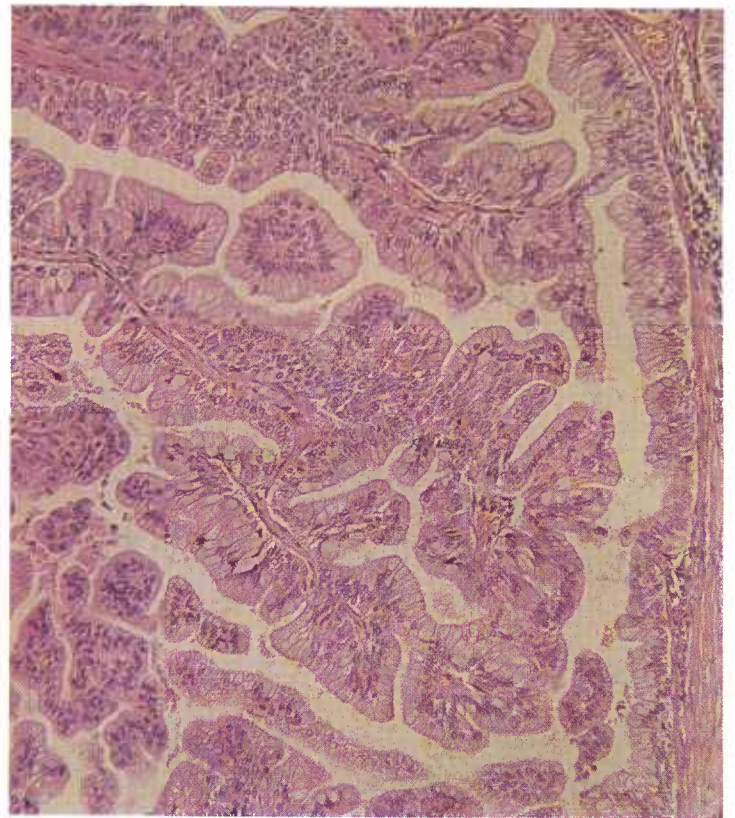


Figure 114.—Histologic preparation of an adenoma of the lung of a 2-year-old Hereford cow (A6-D1241). Note the columnar and stratified appearance of the epithelium and the frondlike papillary mode of growth of this tumor. A gross picture of this neoplasm is shown in figure 111. Hematoxylin-eosin stain.  $\times 125$ .

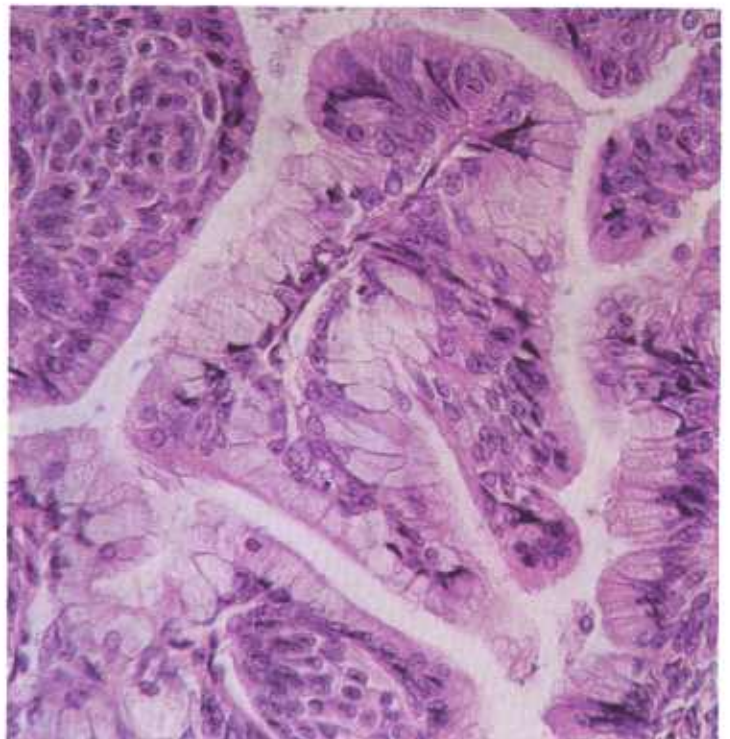


Figure 115.—A higher magnification of the histologic preparation of the adenoma (A6-D1241) shown in figure 114. Hematoxylin-eosin stain.  $\times 320$ .

served in young cattle, whereas pulmonary carcinomas are usually found in older animals.

**Macroscopic appearance.**—Adenomas of the lung are grayish-white or yellow. They occur as single or multiple masses of fibrous, partially calcified neoplastic tissue and are generally less than 2 cm. in diameter. When they occur in multiple form, their member growths are often confluent and are remarkably similar in gross appearance. These multiple growths usually replace much of the parenchyma of the lung and, because of the large amount of neoplastic tissue they contain, keep the lung from collapsing noticeably at the time the host animal is slaughtered.

**Microscopic appearance.**—Adenomas of the lung are composed of cuboidal- and columnar-type cells. Their microscopic pattern of growth is almost identical and quite distinctive. A markedly papillary mode of growth is found in all of the larger lesions, with the epithelium varying from single layers of cuboidal or columnar cells to distinctly stratified layers of the same type of cells.

Adenomas of the lung grow by expansion and do not infiltrate the surrounding pulmonary tissue, invade the pleural cavities, or metastasize to regional lymph nodes or distant organs. The tumor cells have a benign morphology and do not have the anaplastic appearance of malignant carcinomas of the lung. Their appearance indicates that the growths are multicentric and supports the assumption that pulmonary adenomas are developmental defects (hamartomas).

### *Primary pulmonary carcinomas*

**Definition.**—Primary pulmonary carcinomas are those malignant growths that arise from pulmonary tissues and are not metastases from tumors in other tissues or organs.

**Distribution and incidence.**—Primary pulmonary neoplasms are found in domesticated animals throughout the United States. Apparently, they are not as common as similar lung tumors in man, and there is no evidence that their incidence has increased during the past few years. During the 2-year survey conducted by the USDA to determine the incidence of neoplasms in meat-producing animals slaughtered in Denver abattoirs, mentioned on page 1, 0.3 percent of the bovine tumors collected were found to be carcinomas of the lung. None were found in swine and sheep. No breed or sex incidence has been established. Adenomas of the lung occur in younger cattle and primary pulmonary carcinomas occur in older animals.

**Macroscopic appearance.**—Primary pulmonary neoplasms occur as single or multiple neoplasms within the parenchyma of the lung. They are yellow, yellowish gray, gray, or white. They may contain areas of necrosis, calcification, and hemorrhage, and may be encapsulated. The right lung has the highest incidence of neoplasms and the diaphragmatic lobe is the most frequent site. The tumors are located within the body of the lobes of the lung and seldom at the hilus.

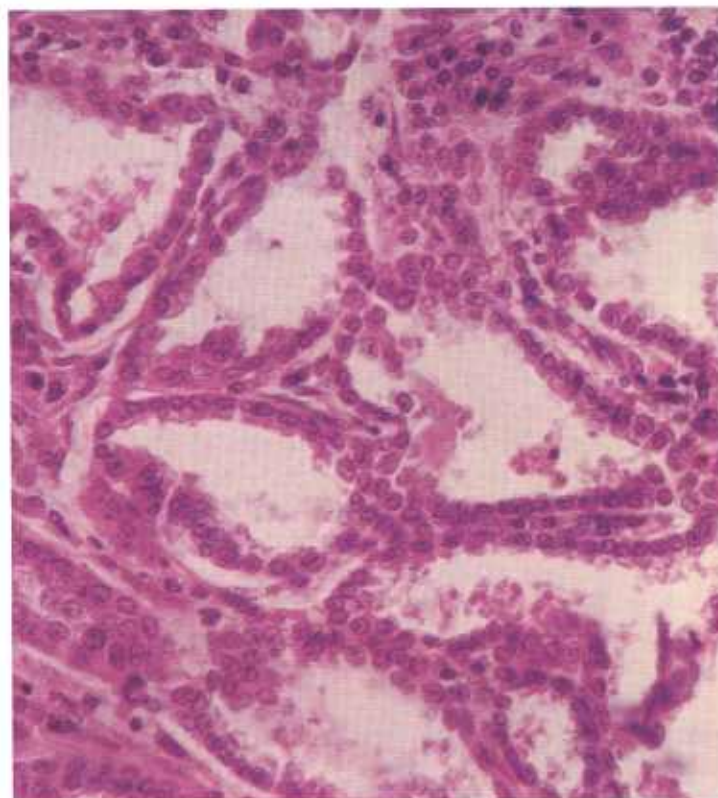


Figure 116.—Adenocarcinoma of the lung of an 8-year-old cow (D977). The tumor is forming alveoli lined by a low columnar type of epithelium. Hematoxylin-eosin stain.  $\times 320$ .

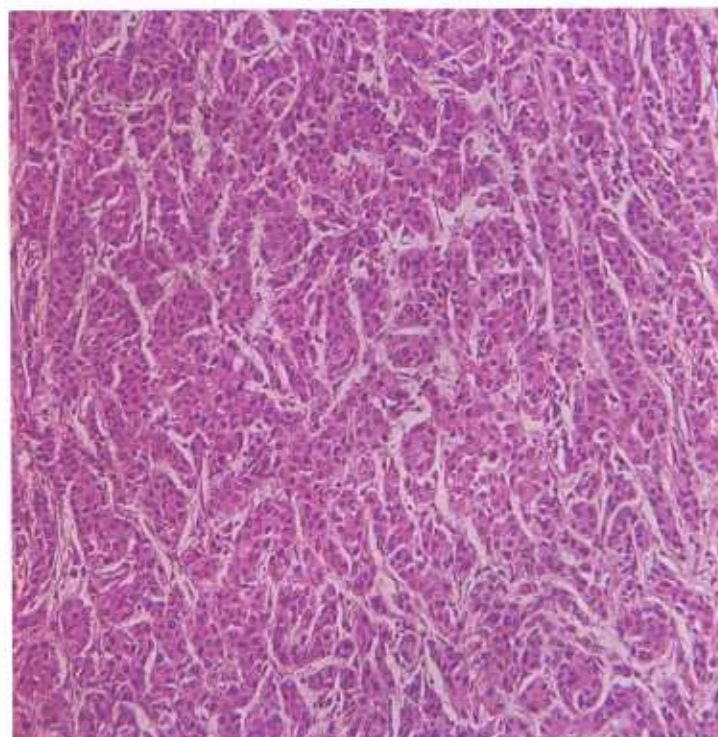


Figure 117.—Histologic preparation of an adenocarcinoma of the lung (undifferentiated-cell type) of an old cow (D2761). The tumor is composed of undifferentiated cells with small, hyperchromatic nuclei and considerable eosinophilic cytoplasm. The neoplastic cells are arranged in small nests and cords separated by a connective tissue stroma. Hematoxylin-eosin stain.  $\times 125$ .

Malignant pulmonary tumors are divided into three large groups: (1) primary-focal, (2) multiple-focal, and (3) diffuse-infiltrating. The primary-focal group contains those carcinomas whose primary location in the lung has been determined and which may or may not metastasize throughout the lungs. The primary lesion is usually sharply circumscribed but not encapsulated; if a capsule is present, it is very thin. Small daughter neoplasms are commonly found in the lung tissue surrounding the primary lesion. The multiple-focal group includes those tumors that have multiple lesions in one or more lobes of one or both lungs. These tumors are multicentric or the primary lesion cannot be distinguished from its metastases. Tumors of the multiple-focal group are usually sharply circumscribed with no encapsulation or with only a very thin capsule. The third group includes the diffuse-infiltrating carcinomas, which cause a general malignant involvement of one or more lobes of one or both lungs.

**Microscopic appearance.**—If a microscopic classification is used, pulmonary tumors can be divided into four types: (1) the squamous-cell type, (2) the columnar-cell type, (3) the undifferentiated-cell type, and (4) the mixed-cell type. The squamous-cell type of tumor varies greatly in the amount of keratinization present in each

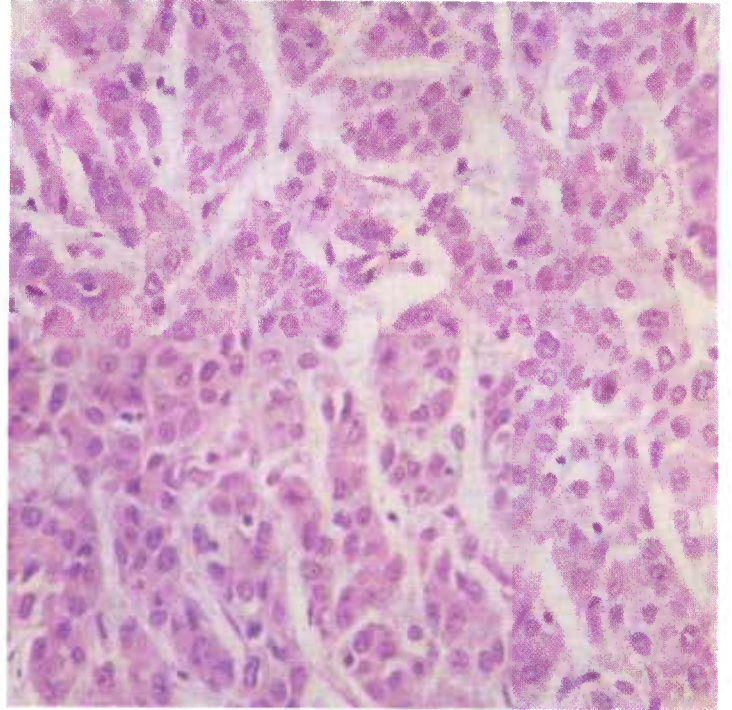


Figure 119.—A higher magnification of the histologic preparation of the adenocarcinoma (D2761) shown in figure 117. Hematoxylin-eosin stain.  $\times 320$ .

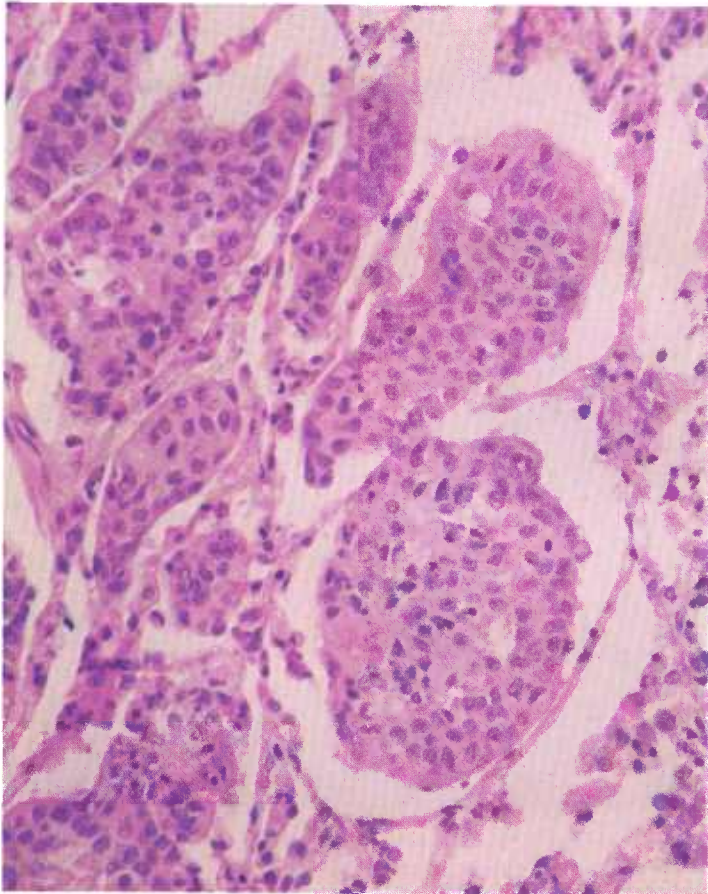


Figure 118.—Adenocarcinoma of the lung (undifferentiated-cell type) of an old cow (D2761). Groups of tumor cells are supported by remnants of the alveolar walls. Hematoxylin-eosin stain.  $\times 320$ .

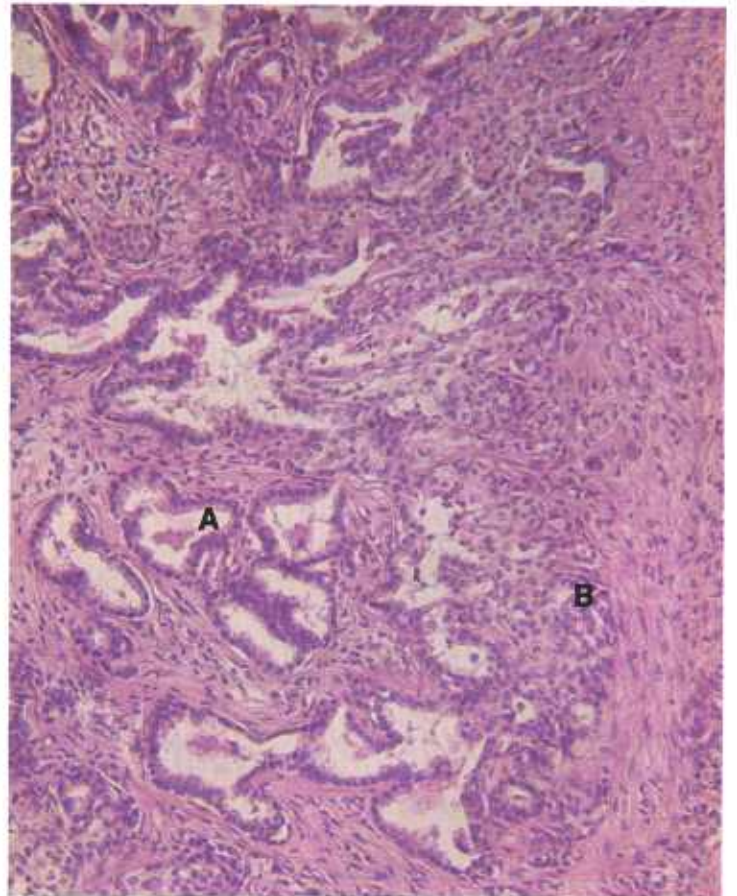


Figure 120.—Lymph node metastasis of the adenocarcinoma of the lung (D977) shown in figure 116. Both columnar-cell type (A) and undifferentiated-cell type (B) of growth are seen. Hematoxylin-eosin stain.  $\times 125$ .

and occasionally contains epithelial pearls. The columnar-cell type of tumor is composed of cells that vary in shape from cuboidal to high columnar and are arranged as solid masses or in cords, alveoli, or tubules. The undifferentiated-cell type of tumor contains very anaplastic cells that do not have the morphology of squamous, cuboidal, or columnar cells. These cells occur singly or in small groups in a loose connective tissue stroma or are arranged in compact masses or cords. The mixed-cell type of tumor is composed of a mixture of cuboidal, columnar, squamous, and undifferentiated cells.

The character of the stroma of the pulmonary carcinomas varies greatly. In some carcinomas the stroma is meager and in others it is very abundant and may make up the bulk of the tumor. In structure, the stroma may be loose and open, or firm, compact, and even hyalinized, and it may contain islands of cartilage and bone.

Some of the carcinomas contain large amounts of mucin that occur as extracellular or intracellular globules. Mitotic figures are occasionally present. Some of the neoplastic epithelial cells are ciliated and care must be taken not to mistake them for normal epithelial cells of the bronchi, which are also ciliated. Intranuclear bodies—apparently large, swollen, altered nucleoli—are quite numerous in the neoplastic cells. In general, the greater the amount of retrogressive change, the more numerous are these bodies. Apparently, they are an indication of necrobiotic change within the cell nuclei.

### *Secondary pulmonary neoplasms*

**Definition.**—Secondary pulmonary neoplasms are tumors that originate in some organ other than the lung and reach the lung by infiltration or metastasis.

**Distribution and incidence.**—Secondary pulmonary neoplasms are commonly found in all meat-producing animals that have malignant tumors. Theoretically, all malignant neoplasms will eventually reach the lung. Actually, many fail to do so because the host dies from causes other than neoplasia or dies as the result of local neoplastic injury or is slaughtered for food.

Whenever pulmonary neoplasms are found, careful examination of other tissues and organs, and the hide as well, must be made to determine the location of the primary tumor. This task can be greatly facilitated if a systematic examination of routes of lymph and blood flow is made. Scars in the hide or other organs may indicate that a tumor has previously been removed by surgery. If a suitable history is available, some indication of the site of a surgically removed neoplasm can be determined. The genital tract, thyroid, adrenal, liver, and the eye are organs that should be scrutinized very carefully when the location of the primary site of a metastatic pulmonary neoplasm is sought. In cattle, the bovine uterus should receive the most careful examination. Since abattoir procedure often separates the hide, head, and genital tract from the remainder of the carcass before the lungs are examined, primary neoplasms in these organs may be overlooked.

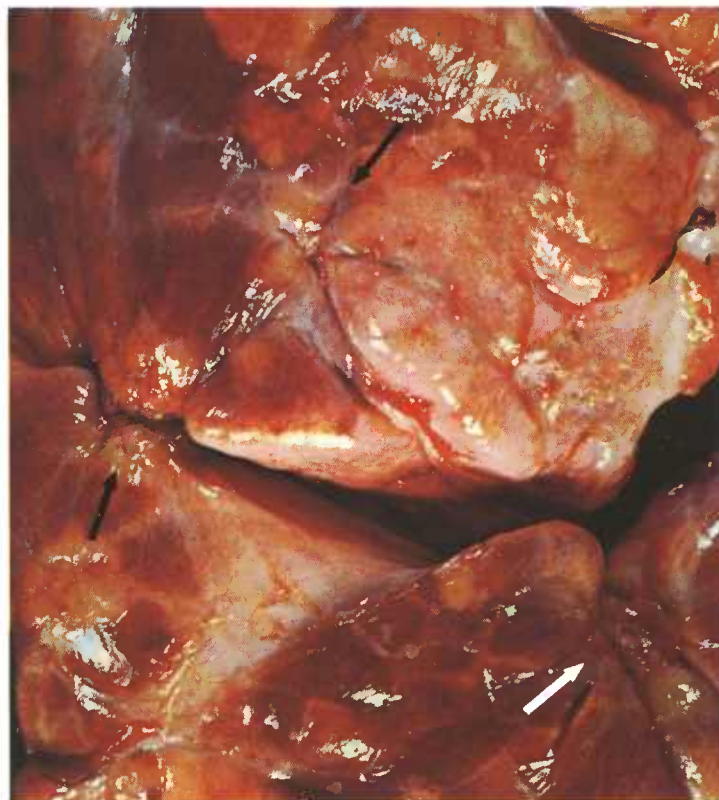

Figure 121.—Metastatic adenocarcinoma of the uterus in the lung of a 7-year-old cow (A340-D2973). Many gray or yellow fibrous, irregularly shaped growths (5 to 40 mm. in their greatest diameter) are scattered throughout the parenchyma of all lobes of both lungs. Note the craterlike, stellate-scar type of lesions (arrows) characteristic of metastatic uterine carcinomas in the lung.

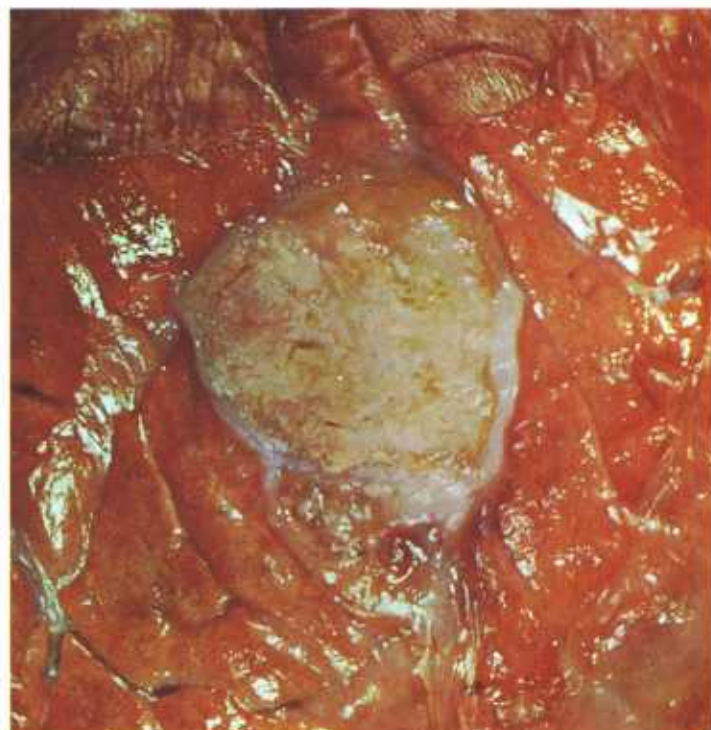


Figure 122.—Metastatic adenocarcinoma of the lung in a Hereford cow (A62-127864). The primary site of the carcinoma could not be determined.

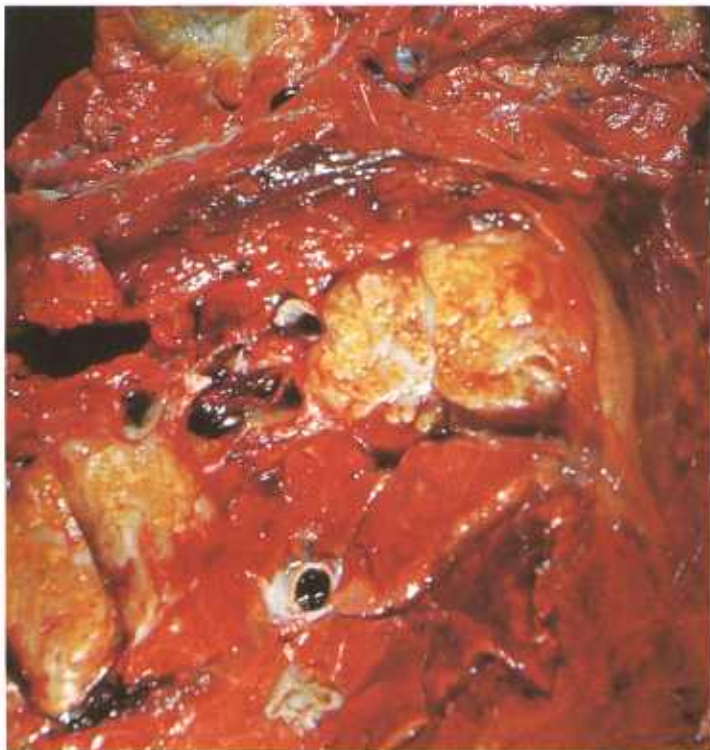

Figure 123.—Metastatic adenocarcinoma of the lung of a 5-year-old cow (A50-D1739). Multiple yellow tumor nodules with necrotic centers are found throughout the parenchyma of the lung. The primary site of the carcinoma could not be determined.

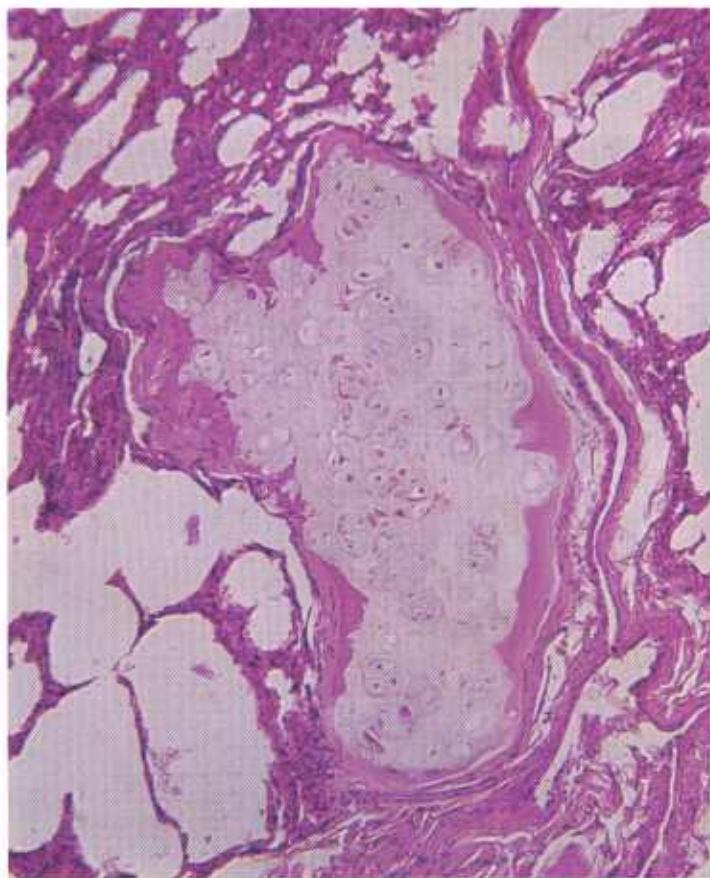


Figure 124.—Metastatic chondrosarcoma in the lung of an 8-month-old sheep (D2603). Hematoxylin-eosin stain.  $\times 125$ .

**Macroscopic appearance.**—Most secondary pulmonary neoplasms are quite similar in appearance. They are found in all lobes of the lungs and occur as single masses or as multiple growths within the pulmonary parenchyma. Their color is white, yellow, gray, black, or orange. According to the type of tumor involved, the consistency of the neoplasm varies considerably. Tumors composed of bone and cartilage are firm and hard and may contain recognizable bone, osteoid tissue, or cartilage. Tumors composed of other types of tissue are soft, edematous, mucinous, or solid. They may be encapsulated and they generally contain calcification, necrosis, and hemorrhage.

**Microscopic appearance.**—The microscopic appearance of the tumor varies with the type of neoplasm that is present. The cell type may be readily recognized so that the identity of the tissue or organ from which the metastasis arose can be easily determined. At other times, the cells of pulmonary neoplasms are so anaplastic that they have little resemblance to the cells from which they originated.

It should be emphasized that metastases are the most anaplastic part of the neoplastic invasion and bear the least resemblance to the tissue from which they originated. Experience in the microscopic identification of tumors and attention to cytological details often enable the pathologist to make a definitive diagnosis.

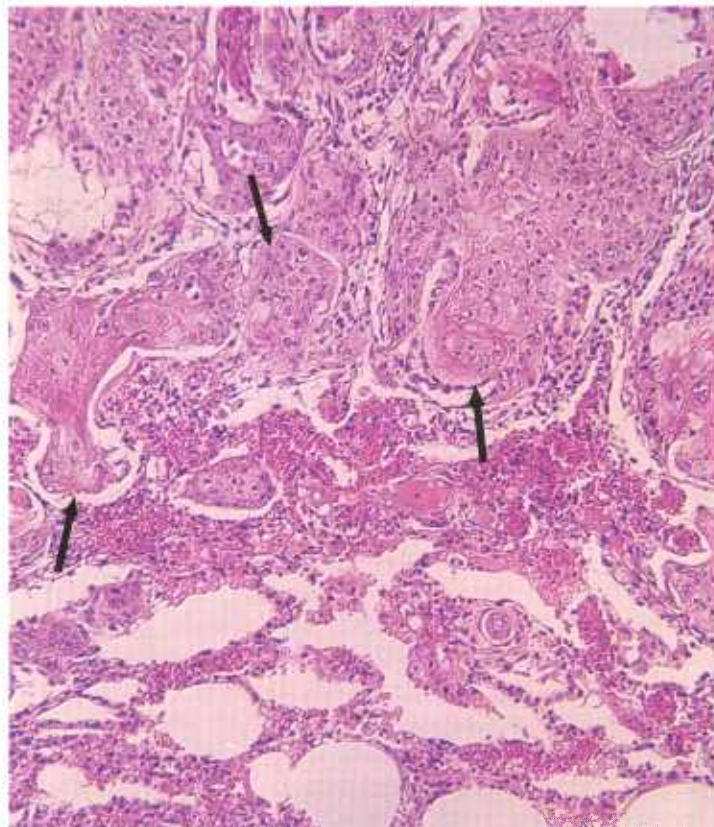


Figure 125.—Metastatic squamous-cell carcinoma in the lung of a 3-year-old Holstein cow (D2267). The primary tumor is located in the skin of the right hip. Epithelial cells (arrows) are infiltrating the pulmonary tissues. Hematoxylin-eosin stain.  $\times 125$ .

## Connective Tissue Tumors

### Chondroma and Chondrosarcoma

**Definition.**—Chondromas and chondrosarcomas are tumors composed principally of neoplastic cartilage cells.

**Distribution and incidence.**—Chondromas and chondrosarcomas are most frequently observed in sheep. During the 2-year survey (see p. 1) conducted by the USDA to determine the incidence of neoplasms in meat-producing animals slaughtered in Denver abattoirs, 4.5 percent of the ovine neoplasms were found to be chondrosarcomas (no chondromas were collected). No breed or sex predominance for these tumors has been determined. Although they are found in meat-producing animals throughout the United States, neither chondromas nor chondrosarcomas were detected in the cattle and swine examined during the USDA's 2-year survey.

Chondromas and chondrosarcomas occur in regions where cartilage is normally present—for example, at the epiphyses of long bones of the extremities, the costochondral and chondrosternal articulations, and in the cartilages of the nasal passages, larynx, trachea, and bronchi. In sheep, they are seen most frequently on osteochondral junctions of the ribs, scapulas, humeri,

and femurs. Chondrosarcomas are more frequently found during meat inspection than are chondromas. However, there is no distinct division between a large group of the potentially malignant skeletal chondromas and chondrosarcomas that increase noticeably in size during a period of 2 to 3 months. It is often necessary to study the entire tumor to find small areas of malignant transformation.

**Macroscopic appearance.**—Chondromas and chondrosarcomas are hard tumors that almost always occur singly. They may attain a weight of 10 pounds in sheep and 20 pounds in cattle. Sometimes they have a thick fibrous capsule. At other times the capsule scarcely covers the tumor mass and in some chondrosarcomas, it only partially encloses the growth. The tumors are attached to previously existing cartilage or bone, except for those that arise from metaplasia of connective tissue.

On cross section, chondromas consist of well-defined lobulated masses of translucent, bluish-white, glistening tissue. Although these tumors are attached to the bone or cartilage from which they originated, they are almost completely demarcated since they usually protrude from the tissues from which they were derived instead of expanding these tissues. At times there may

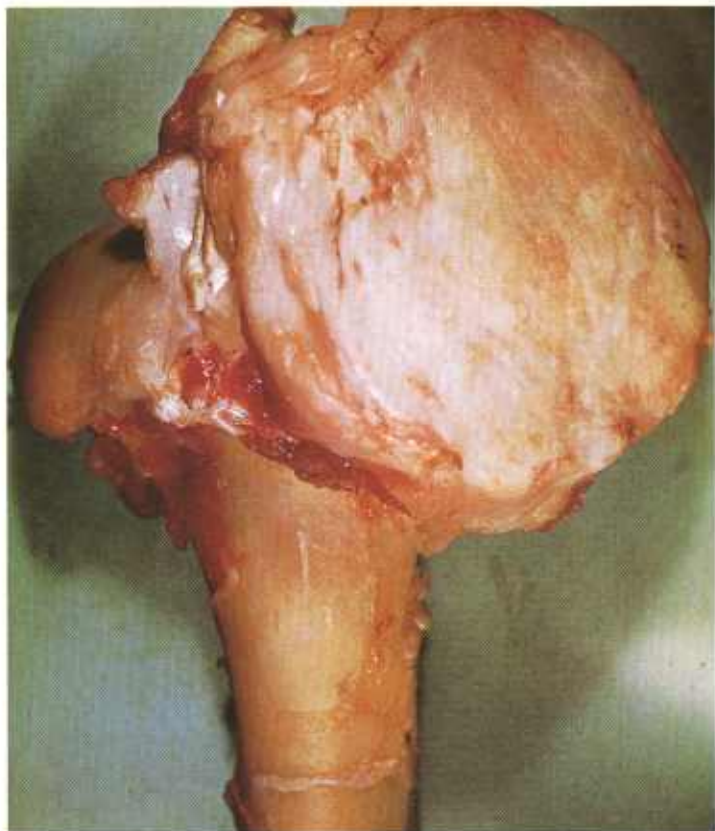

Figure 126.—A hard, slightly lobulated, well-defined chondroma located in the epiphyseal region of the proximal end of the humerus of an adult ewe (A115-D1464). No metastatic tumors are present.

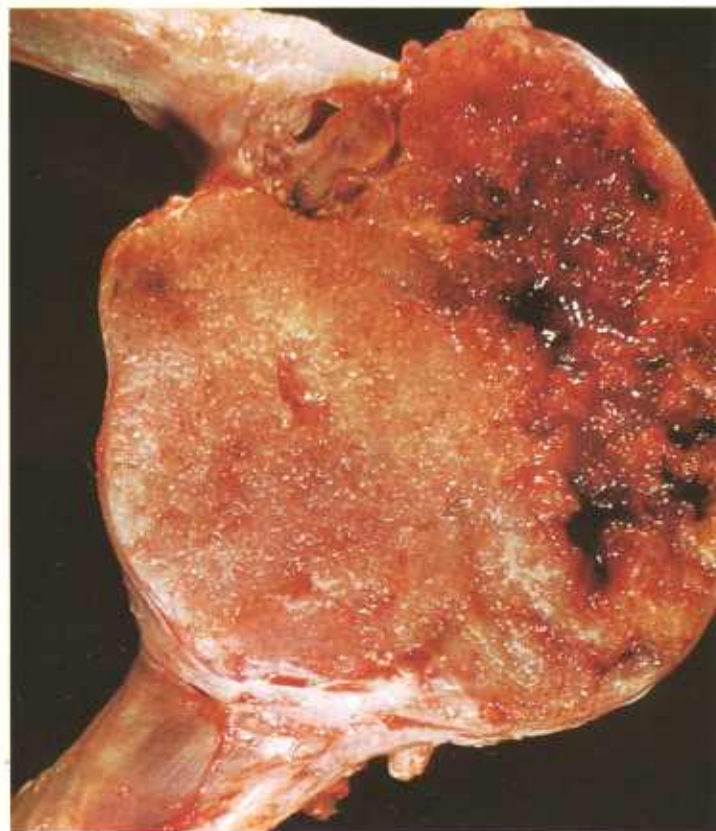


Figure 127.—A dense, lobulated, well-defined chondrosarcoma present in the distal end of the radius and ulna in an old ewe (A404-D3101). The tumor is invading the bone, bone marrow, and joint cavity.

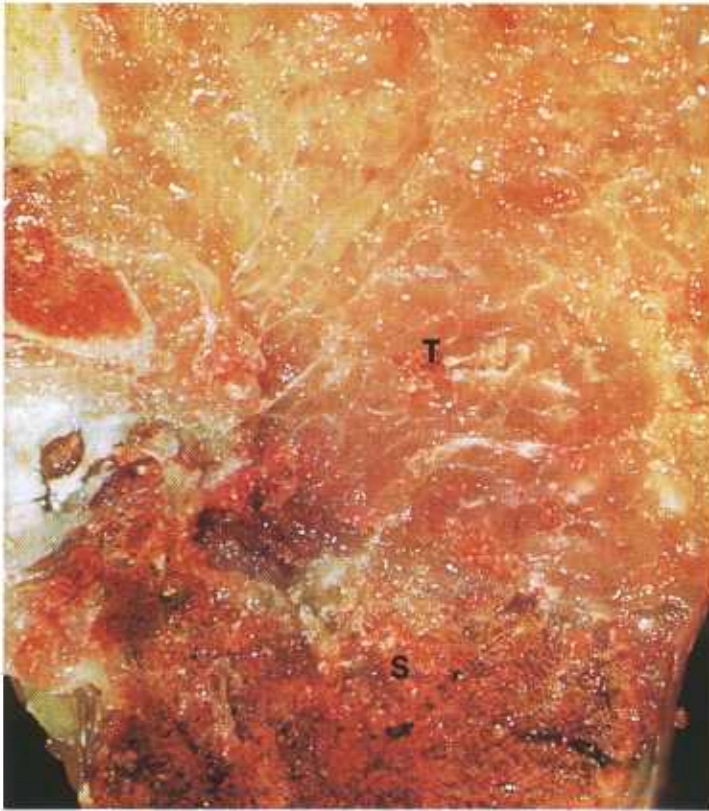

Figure 128.—A translucent, lobulated, grayish-blue chondrosarcoma (T), measuring 16 by 9 by 8 cm., is invading the sternum (S) of an aged ewe (A286-D2676).

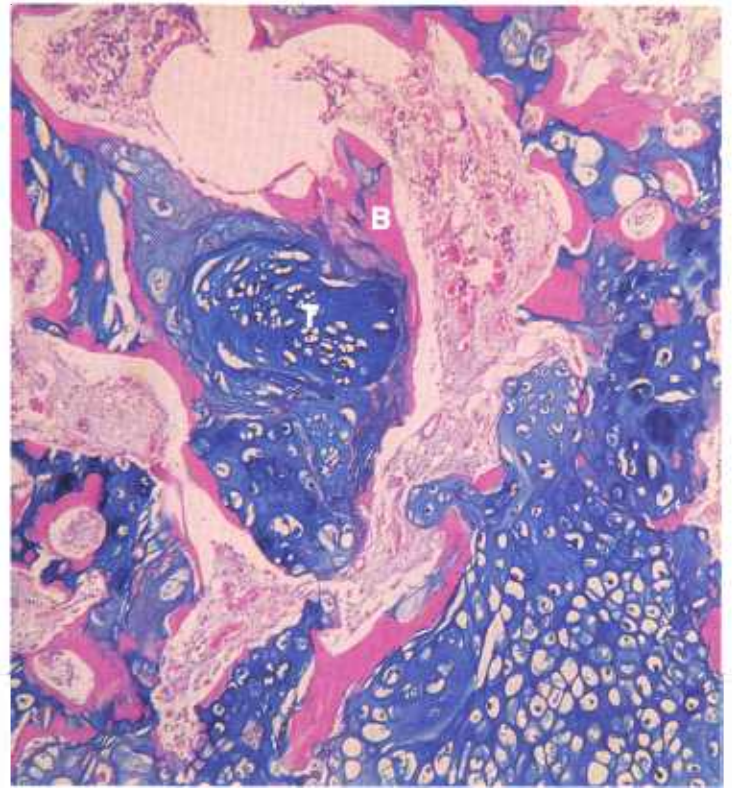


Figure 130.—Histologic preparation of the chondrosarcoma (A286-D2676) shown in figure 128. Note the blue-stained tumor tissue (T) that is invading the marrow of the red-stained bone (B). Alcian blue and eosin stain.  $\times 50$ .

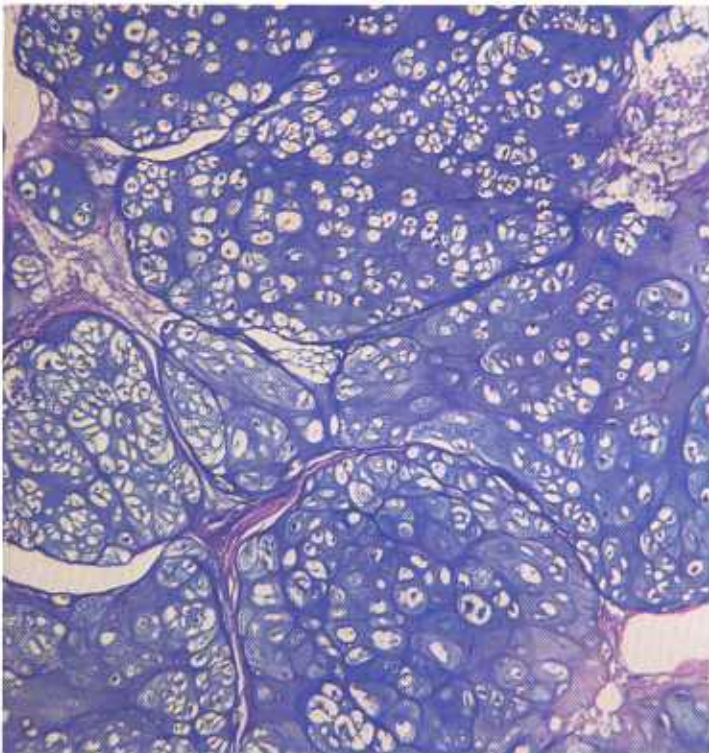


Figure 129.—Histologic preparation of the chondrosarcoma of the sternum (A286-D2676) shown in figure 128. Note that the neoplastic cells are not arranged in the normal pattern of cartilage, the growth is distinctly lobulated, the cells are varied in size and shape, and no blood vessels are present within the lobules. Alcian blue and eosin stain.  $\times 50$ .

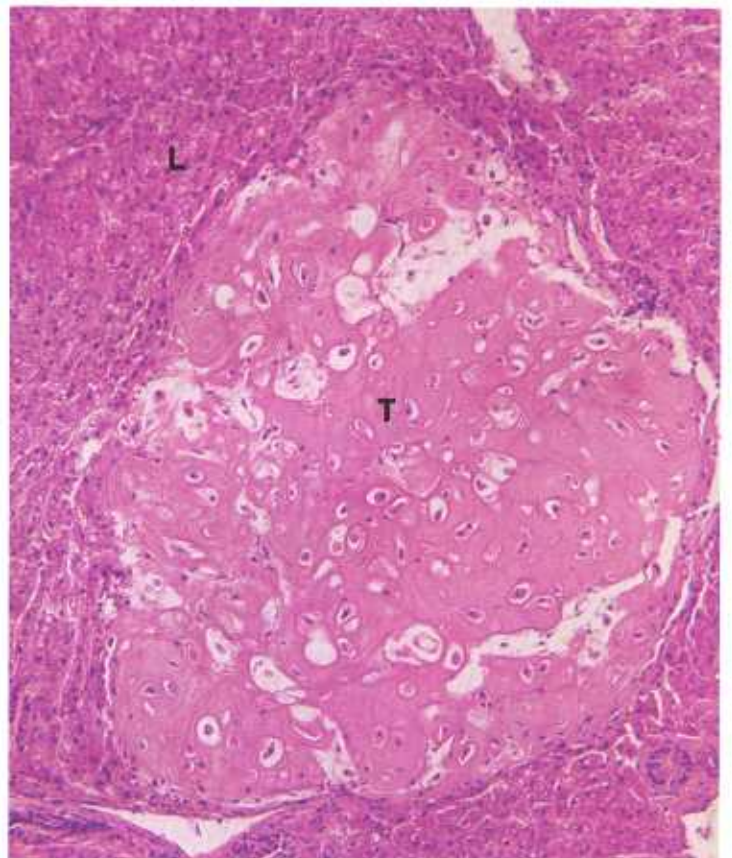


Figure 131.—Metastatic chondrosarcoma (T) in the liver (L) of an 8-month-old ewe (D2603). Hematoxylin-eosin stain.  $\times 125$ .

be small cysts or calcified areas in the growth, together with zones of mucoid degeneration and fibrous connective tissue.

Cross sections of chondrosarcomas show a more confluent type of growth, with only parts of the tumor being lobulated. These tumors maintain a resemblance to hyaline cartilage. They may be only partially encapsulated and may be poorly demarcated from adjacent cartilage or bone, and they may actually invade, expand, or replace these tissues. A few invade adjacent connective tissue and muscle, and may even extend into the bone marrow.

**Microscopic appearance.**—Some chondromas are very cellular; others are not. The cells are arranged singly rather than in groups as in normal cartilage, and are of varied shapes and sizes. At the periphery they are usually small; at the center, large. Varying amounts of hyaline matrix are present between the cells (it is essential that some matrix be present if the growth is to be classified as a chondroma). As in normal cartilage, there are no blood vessels; however, nourishment diffuses through the cartilage to the cells from blood vessels in the capsule. This arrangement limits the size of the lobules: when the distance of diffusion becomes excessive, cellular growth becomes restricted or the neoplastic tissue undergoes degeneration or necrosis, or both.

Chondrosarcomas are much more cellular than chondromas and their individual cells have many anaplastic features. Nuclei are varied in size and shape and are hyperchromatic, and mitotic figures are numerous. The cells are spindle-shaped, round, or rhomboid, and the chondroid matrix is often meager. Lacunae are not well formed and areas of calcification and cysts of varying sizes may be present. Tumor cells may infiltrate into adjacent tissues and will frequently metastasize to the lungs without involving the regional lymph nodes.

## Hemangioma and Hemangiosarcoma

**Definition.**—A hemangioma is a benign tumor arising from the endothelial cells of blood vessels. Malignant types are designated as hemangiosarcomas.

**Distribution and incidence.**—Hemangiomas and hemangiosarcomas are found in all genera of domesticated animals throughout the United States. No species, breed, or sex differences have been established. During the USDA's 2-year survey, mentioned on page 1, 0.6 percent of the cattle tumors and 3 percent of the sheep tumors collected were hemangiomas. Hemangiosarcomas comprised 0.1 percent of the cattle tumors and 1.5 percent of the sheep neoplasms. These tumors are most often observed in the extremities, the thoracic wall, the perianal region, the liver, and the spleen.

Extreme caution should be exercised in diagnosing tumors composed of blood vessels as hemangiomas or hemangiosarcomas. Most so-called hemangiomas or hemangiosarcomas are actually either blood vascular

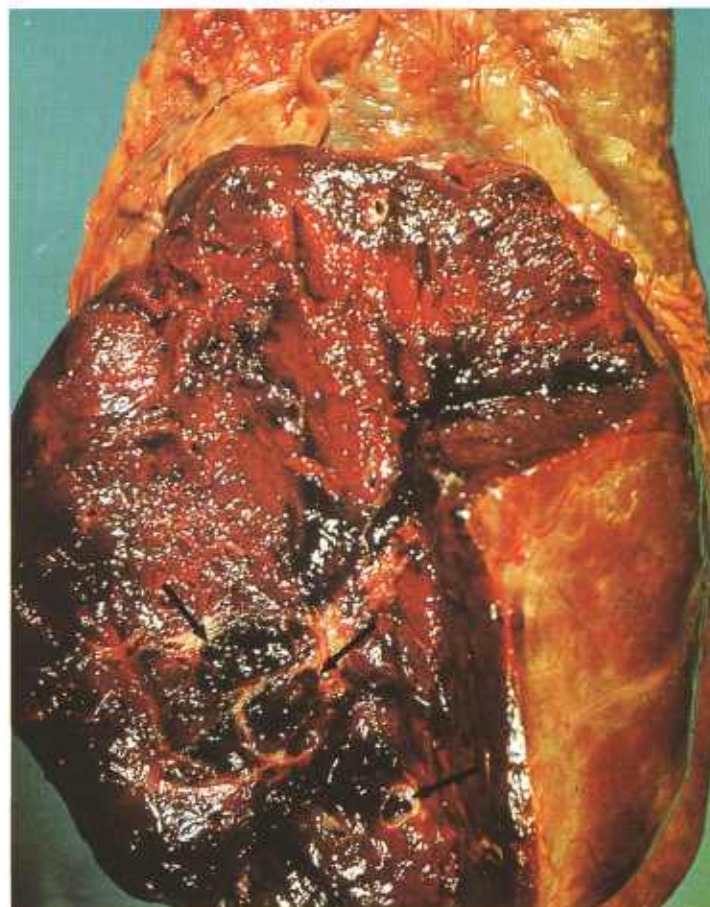

Figure 132.—Angioma of the spleen in a 5-year-old Hereford steer (A236-D2787). The oval, firm, red growth is protruding from the visceral surface of the spleen. It is indistinctly lobulated, poorly encapsulated, and covered by serosa. This angioma measures 15 by 14 by 7 cm. About three-fourths of the surface has been removed to show a partial cross section of the growth. Many thinly walled blood spaces are visible (arrows).

hamartias (developmental defects in the blood vascular system) or very vascular sarcomas of some other basic cell type, such as fibrosarcomas.

Care should also be taken not to confuse hemangiomas or hemangiosarcomas with telangiectasis, which is a dilatation of preexisting vessels. Telangiectasis is most commonly observed in the livers of cattle. The endothelium lining the telangiectic cavities is adult in type and shows none of the cellular characteristics of neoplasia. In addition, telangiectasis usually occurs as multiple lesions throughout the liver and effects no invasion into the regional lymph nodes or metastasis to other organs.

Quite frequently, the circulatory changes associated with inflammation, which cause large numbers of capillaries to be produced, are confused with hemangiomas. To insure against diagnostic errors, the investigator must be able to recognize the connective tissue and vascular arrangement of chronic inflammation, and must be familiar with the history and location of the inflammation.

**Macroscopic appearance.**—Hemangiomas and heman-

giosarcomas are dark red or purple and are soft in consistency. They bleed profusely when traumatized. In size they range up to 15 cm. or more in diameter and they may weigh as much as 2,000 grams. Although the tumors are generally red or purple, their coloration is correlated with their vascularity and varies with the ratio of endothelial cells and supporting tissue to the number of lumina. In hemangiomas, variations in the ratio of structural elements affect consistency as well as color. The more vascular type is red and soft; the more cellular type resembles a fibrosarcoma and is firmer or denser in consistency.

**Microscopic appearance.**—The more vascular type of hemangioma consists of newly formed capillaries usually lined by a single layer of endothelial cells. Occasionally, two or three layers of cells are present. The capillaries are surrounded by varying amounts of collagenous fibers. The more solid types of hemangioma have relatively few lumina, but each lumen is lined with several layers of endothelial cells.

Hemangiomas may be typed as capillary, cavernous, or solid. The capillary type is composed of capillaries with lumens that are more or less normal in size. The cavernous type is composed of capillaries that are

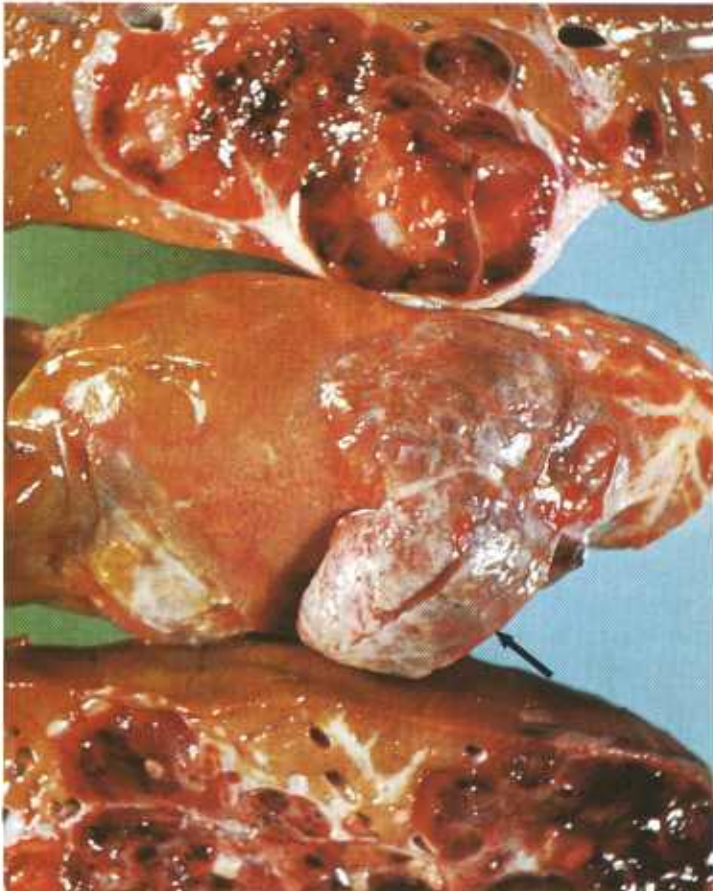


Figure 133.—A blood-filled, lobulated, firm, partially encapsulated hemangiosarcoma (10 by 3 by 4 cm.) is present in the liver of a 1-year-old sheep (A386-D2979). Part of the tumor (arrow) protrudes as an irregularly shaped mass (4 by 3 by 2 cm.) above the surface of the liver.

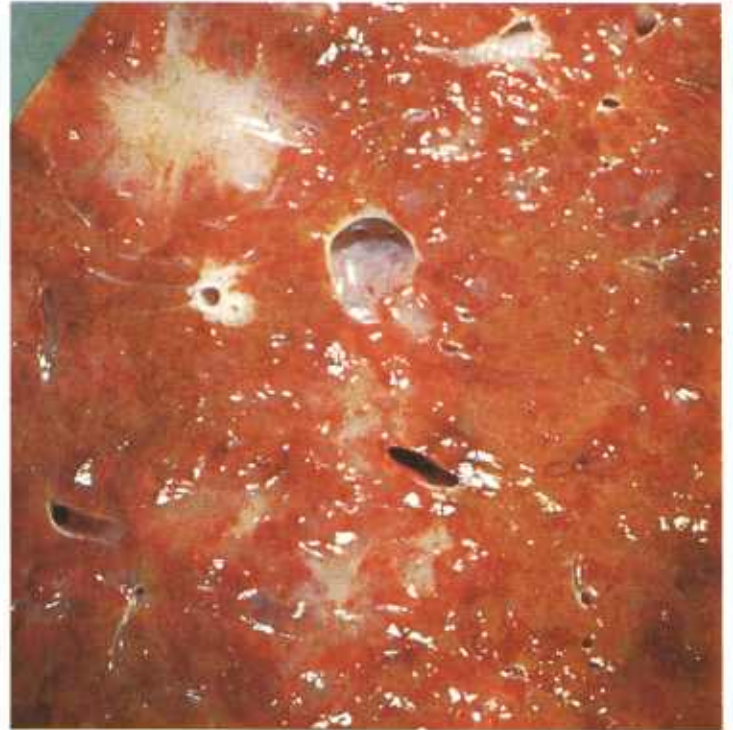

Figure 134.—Hemangiosarcoma of the liver of a 10-year-old cow (A385-D2924). There is a diffuse infiltration of the liver and metastatic tumors (not visible) are present in the regional lymph nodes. The growth is composed principally of capillaries filled with blood.




Figure 135.—Diffuse infiltration of the thigh muscles of a 2-year-old bull (A85-D1417). The hemangiosarcoma is composed of capillaries and a few large cavernous spaces filled with blood.

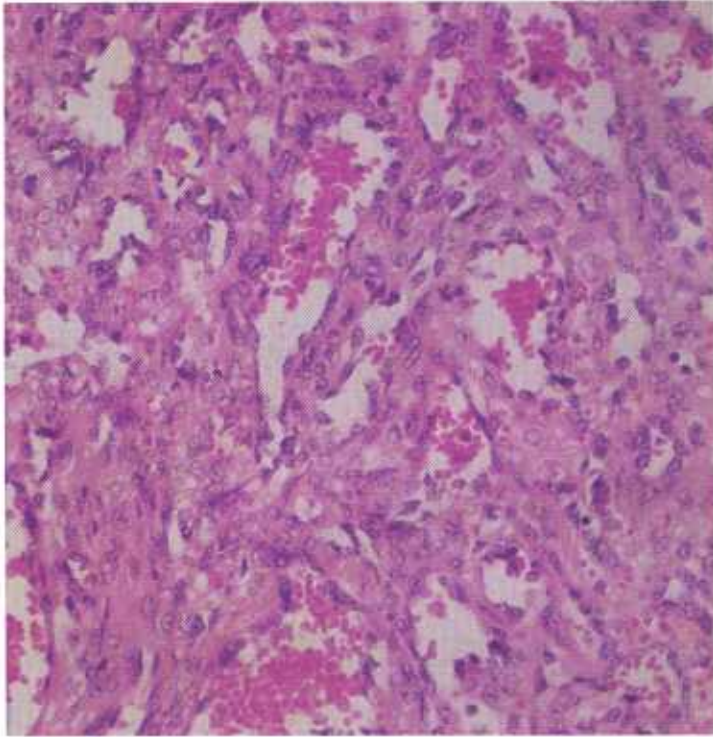


Figure 136.—Histologic preparation of the hemangiosarcoma of the spleen of an 8-year-old cow (D1922). The tumor consists of vascular channels lined with endothelial cells. Blood is present within the lumen of some of the vessels. Hematoxylin-eosin stain,  $\times 320$ .

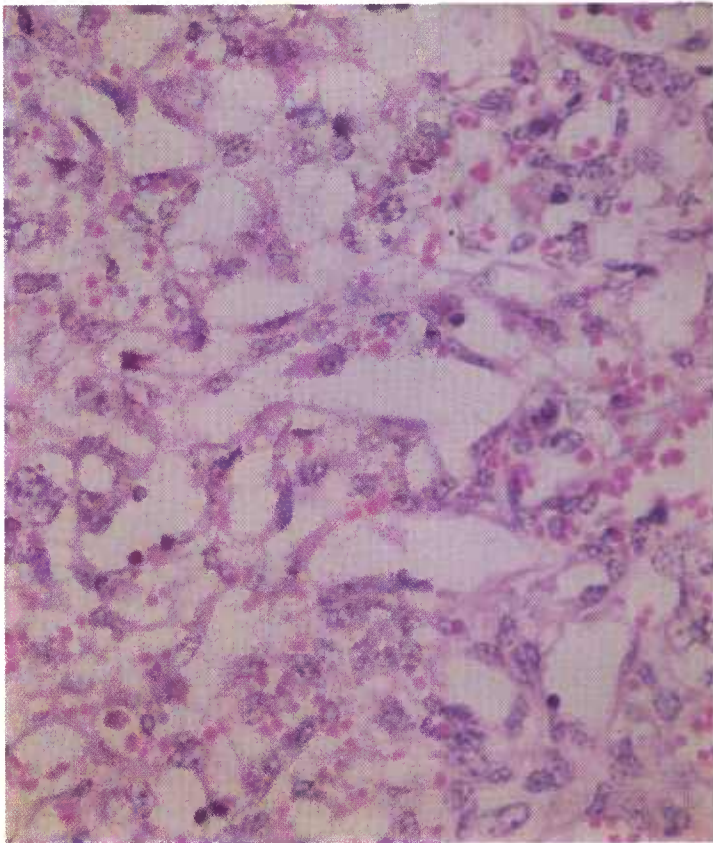


Figure 137.—A higher magnification of the histologic preparation of the hemangiosarcoma (D1922) shown in figure 136. Hematoxylin-eosin stain,  $\times 500$ .

greatly dilated. In contrast, the solid type consists of masses of endothelial cells with few or no vascular discernible lumens. If the growth of capillaries is associated with a proliferation of vascular pericytes just outside of the reticulin sheath, the tumor is designated as a hemangiopericytoma.

The nuclei of hemangiosarcomas are round, oval, or ellipsoidal, and have fine- to medium-sized chromatin granules. One or more nuclei may be present in a cell. Both normal and atypical mitotic figures are present. The cytoplasm is not conspicuously stained and the cell boundaries tend to fuse. Connective tissue fibrils make up the stroma.

Since the hemangiosarcoma is a malignant tumor of blood vessels, metastasis occurs early and with relative ease because the malignant cells are in contact with the blood stream. By the time a hemangiosarcoma is recognized, multiple metastases usually have already occurred.

### Leiomyoma and Leiomyosarcoma

**Definition.**—A leiomyoma is a benign tumor composed of smooth muscle. If malignant, it is known as a leiomyosarcoma.

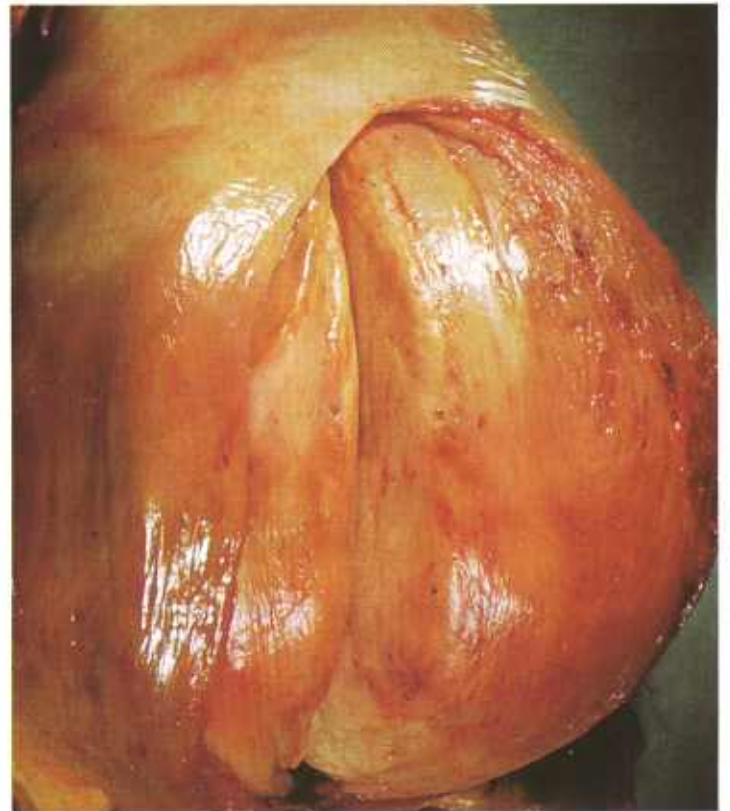


Figure 138.—Leiomyoma of the uterus in an old Hereford cow (A287-D2675). An incision has been made through the originally intact serosa into the main tumor mass. The gray tumor consists of a solid, oval, non-encapsulated mass (14 by 14 by 12 cm.) in the wall of the uterine body. Yellow areas of necrosis are present in the center of the tumor. The serosa and mucosa of the uterus are not penetrated by the neoplasm.

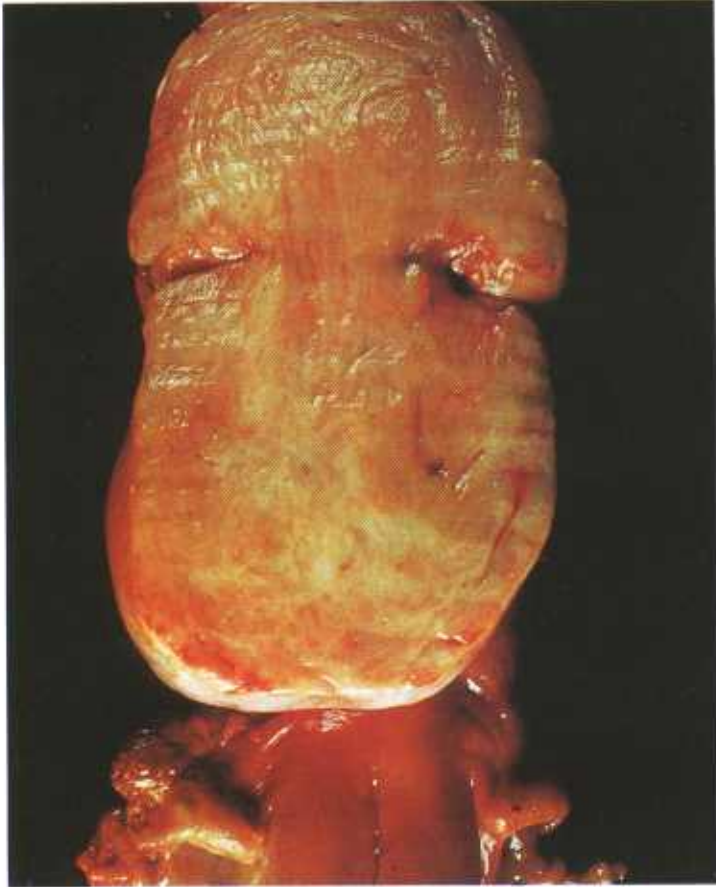


Figure 139.—Leiomyoma of the uterus of an aged ewe (A436-D3499). The body of the uterus is distended by a firm gray tumor. No degeneration or necrosis is present within the neoplasm and no invasion of other organs has occurred. The tumor is histologically benign but its great size probably interfered with the normal function of the uterus.

**Distribution and incidence.**—Leiomyomas and leiomyosarcomas are found in meat-producing animals throughout the United States. No breed or sex predominance has been determined. Although young animals may be involved, most of the tumors occur in cattle over 6 years of age or in old sheep. During the USDA's 2-year survey, mentioned on page 1, 0.9 percent of the cattle tumors and 1.5 percent of the sheep tumors collected were tumors of the smooth muscle. None were found in swine.

Tumors of the smooth muscle are most frequently encountered in the musculature of the tubular and hollow organs, such as the digestive, urinary, and genital tracts. Often they are not discovered until after the death of the animal, particularly when they are located in the wall of a hollow organ, such as the intestine, where their size causes an obstruction to the passage of secretion, excretion, or ingesta that proves fatal to the host. A few of the faster growing tumors expand and infiltrate into the walls of hollow organs. They are then classified as leiomyosarcomas and must be regarded as being locally malignant.

**Macroscopic appearance.**—Leiomyomas vary consid-

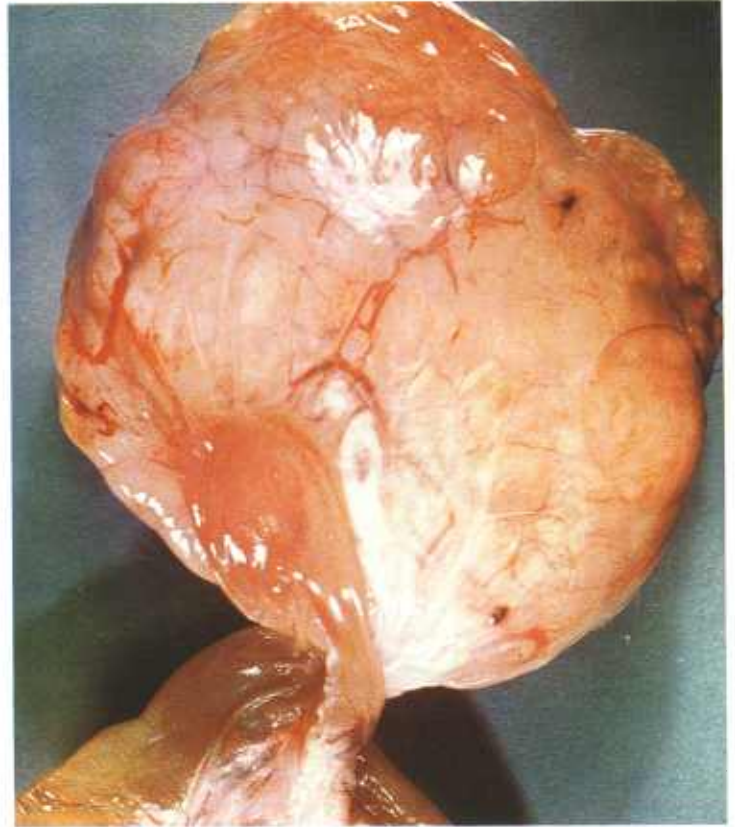


Figure 140.—Leiomyoma of the mesentery and intestine of an aged ram (A365-D2908). An oval, gray, thinly encapsulated growth (13 by 11 by 5 cm.) is firmly attached to the wall of the intestine at its mesenteric attachment. No metastatic tumors are present.



Figure 141.—Leiomyosarcoma of the wall of the intestine in an 8-year-old cow (A50-D1351). The growth consists of a large oval, yellow mass that measures 10 by 6 by 5 cm., weighs 5 pounds, and contains areas of hemorrhage and necrosis (arrows).

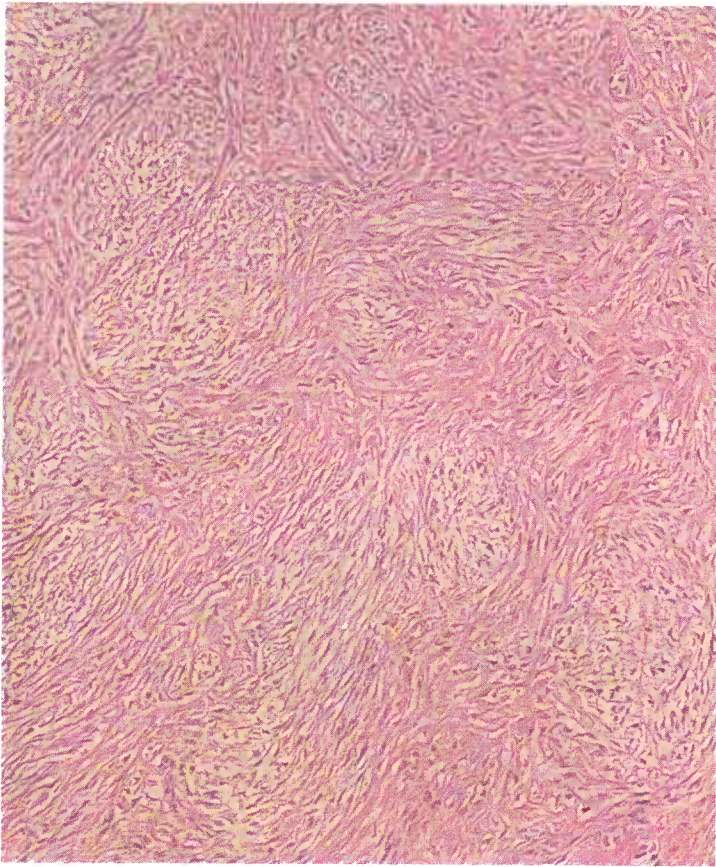


Figure 142.—A histologic preparation of the leiomyoma of the uterus (A287-D2675) shown in figure 138. Note the typical whorled structure of this type of neoplasm. Hematoxylin-eosin stain.  $\times 125$ .

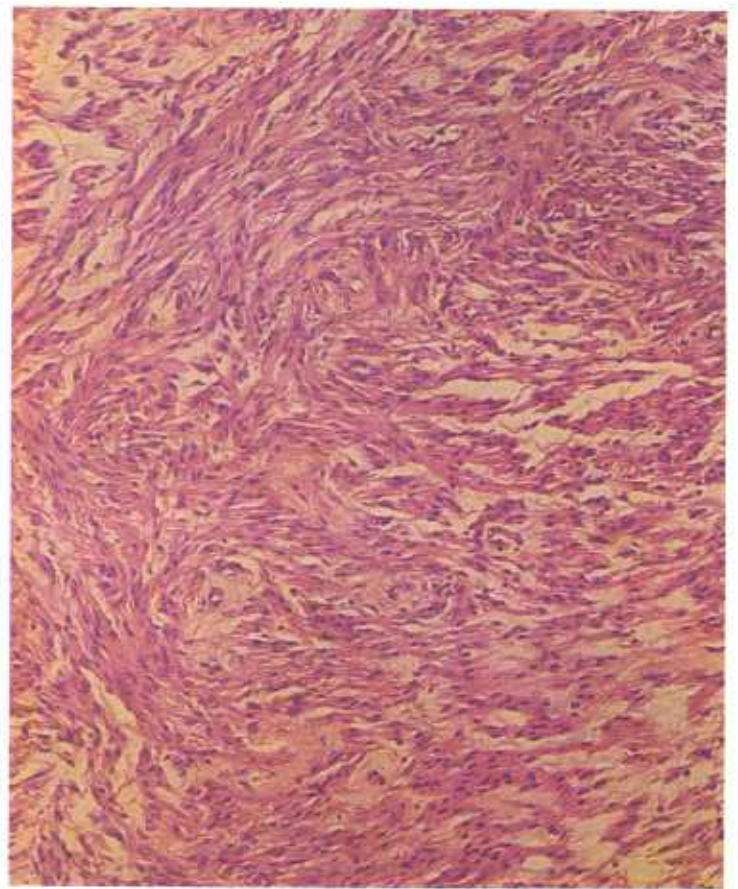


Figure 144.—A histologic preparation of a leiomyoma of the uterus in an old cow (D3206). Note that the muscle cells are larger and contain more cytoplasm than the tumor shown in figure 142, but the growth still has a whorled arrangement. Hematoxylin-eosin stain.  $\times 125$ .

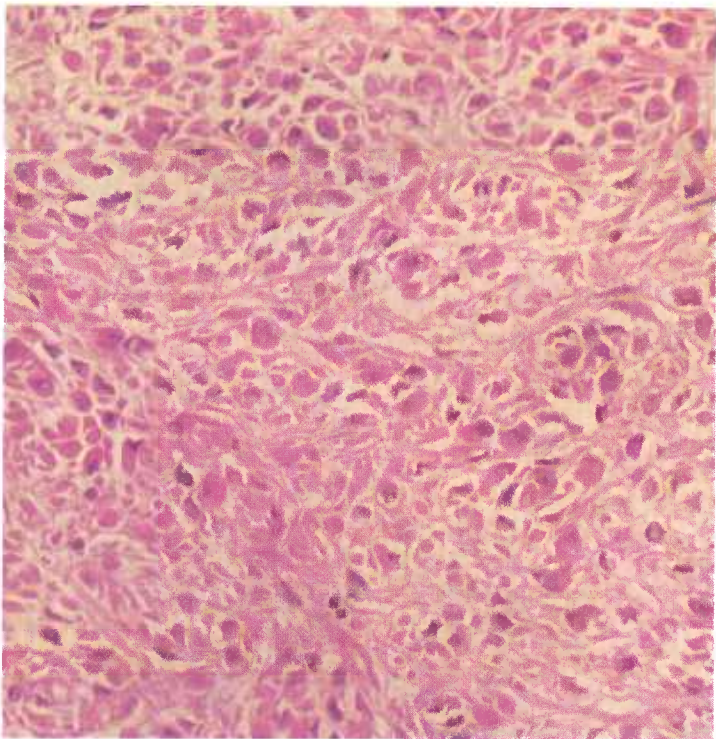


Figure 143.—A histologic preparation of the leiomyoma of the uterus (A287-D2675) shown in figure 138. An area of the tumor is presented in which the neoplastic cells are irregular in size and shape. Hematoxylin-eosin stain.  $\times 320$ .

erably in size, ranging in measurement from a few millimeters to as much as 18 centimeters in diameter. They are usually spherical or elliptical and tend to be rather distinctly demarcated from the surrounding tissue. These neoplasms are located in areas where smooth muscle is normally found and usually have the pink coloring of normal smooth muscle tissue. They tend to be rather firm in consistency and those with considerable deposits of connective tissue have an exceedingly dense and sclerotic consistency. Smooth muscle tumors usually do not contain areas of degeneration, necrosis, and hemorrhage. However, those neoplasms that protrude into the lumen of an organ, such as vaginal leiomyomas, often have ulcerated surfaces. Examination of the glassy, rather dry cut-surface reveals that the growth is composed of interlacing fibers and strands of tissue that tend to have a whorled appearance.

**Microscopic appearance.**—The basic cell type is a long spindle-shaped cell containing an elliptically shaped nucleus. The neoplastic nuclei are rather rich in chromatin, and the nucleoli are not prominent. At times the muscle cells are interspersed with white fibrous connective tissue cells and it is difficult to determine whether they are fibroblasts or myoblasts. For this reason, such stains as Van Gieson's stain or Gomori's connective tissue stain

should be used in identifying the specimen as either connective tissue or muscle tissue.

Histologic examination reveals the cells to be arranged in bundles, strands, and bands that interlace and form a whorled pattern. The muscle cells usually merge with the normal musculature of the organ and thus indicate their origin. The locally malignant invasive leiomyosarcomas have numerous mitotic figures; however, metastatic leiomyosarcomas are very infrequently observed in meat-producing animals.

### Lipoma and Liposarcoma

**Definition.**—A lipoma is a benign tumor composed of adipose tissue. The malignant form of the tumor is called a liposarcoma.

**Distribution and incidence.**—Lipomas and liposarcomas are found throughout the United States and in all genera of domesticated animals. Lipomas are rather common tumors in older animals. In the 2-year survey conducted by the USDA to determine the incidence of neoplasms in animals slaughtered for food in Denver abattoirs (see p. 1), 0.11 percent of the cattle tumors and 1.5 percent of the sheep tumors collected were lipomas. No liposarcomas were found in cattle, but 1.5 percent of the sheep tumors were of this type. None were found in swine. No sex, species, or breed predominance was established.

Lipomas occur in locations where fat is physiolog-

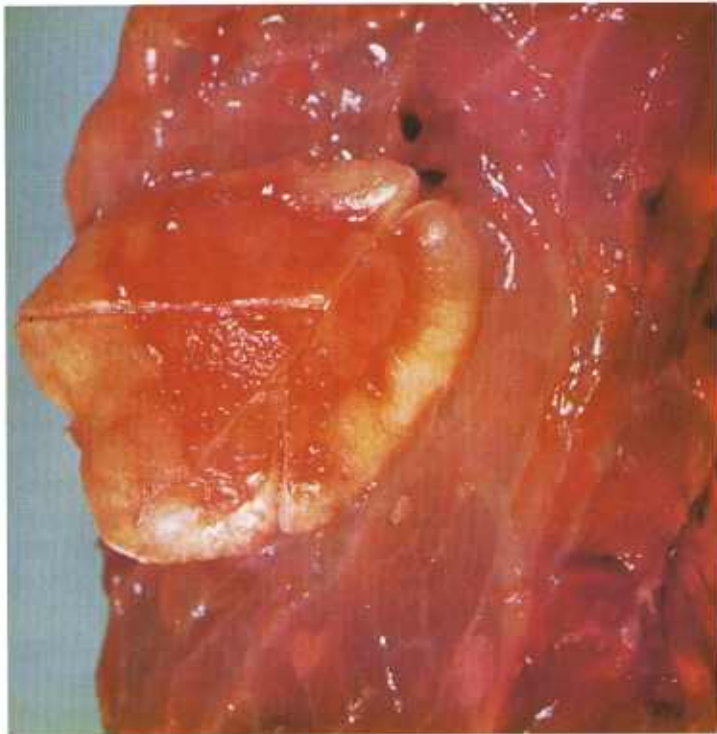


Figure 145.—Lipoma of the pleura of a 2-year-old Hereford cow (A366-D3001). A solid, flattened, yellow growth (35 by 30 by 10 mm.) is firmly attached to the pleural surface of the apical lobe of the lung. The tumor is composed of fat and has a distinct capsule.

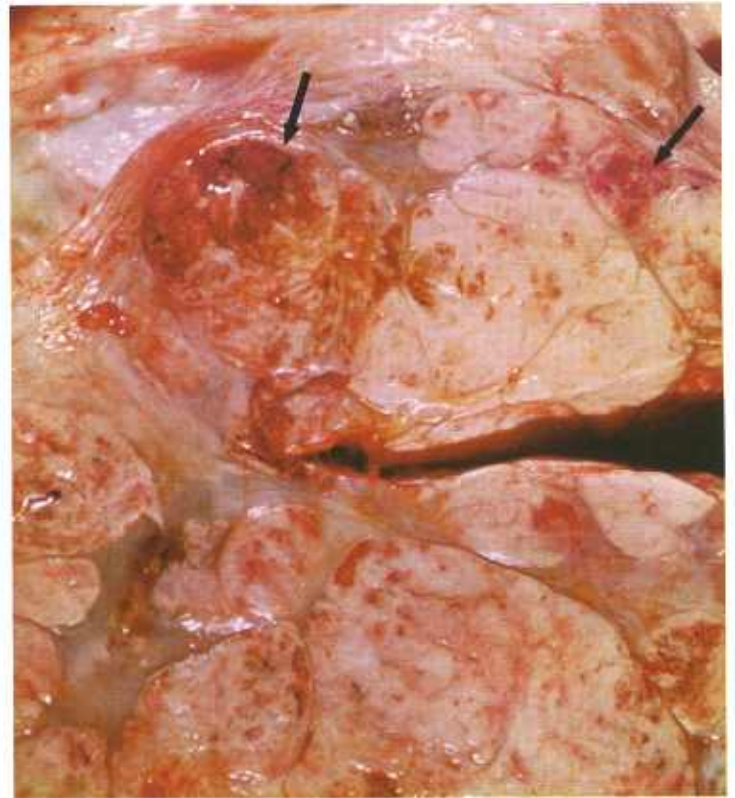

Figure 146.—Liposarcoma of the neck of a 4-year-old ram (A248-D2421). A lobulated, soft, gray tumor (16 by 13 by 10 cm.) is located in the musculature of the neck and extends from the angle of the jaw to the shoulder. Areas (arrows) of necrosis and hemorrhage are present within the mass.

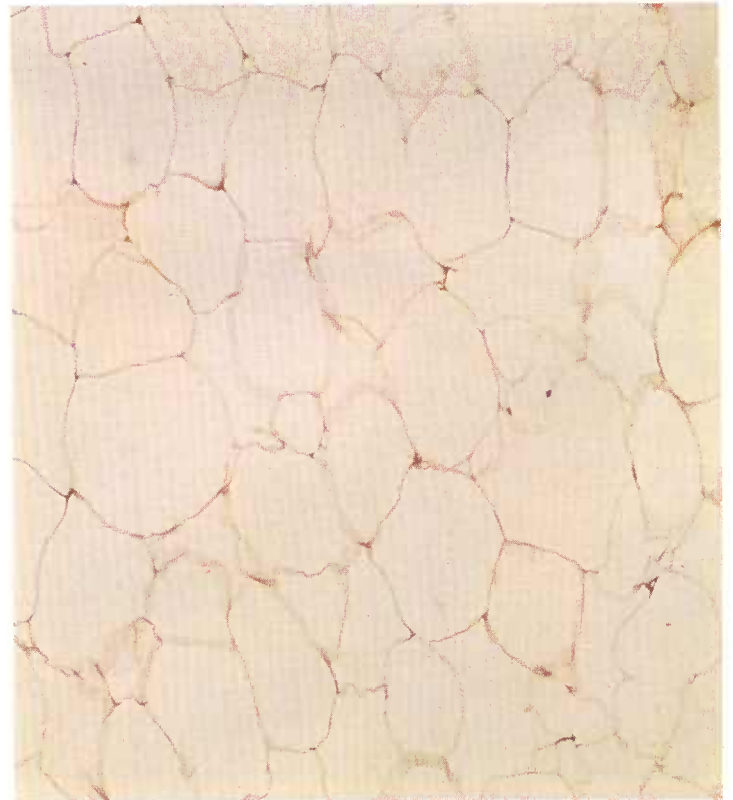


Figure 147.—A histologic preparation of a subcutaneous lipoma (M165) that contains large fat cells similar to normal adipose cells. Hematoxylin-eosin stain.  $\times 125$ .

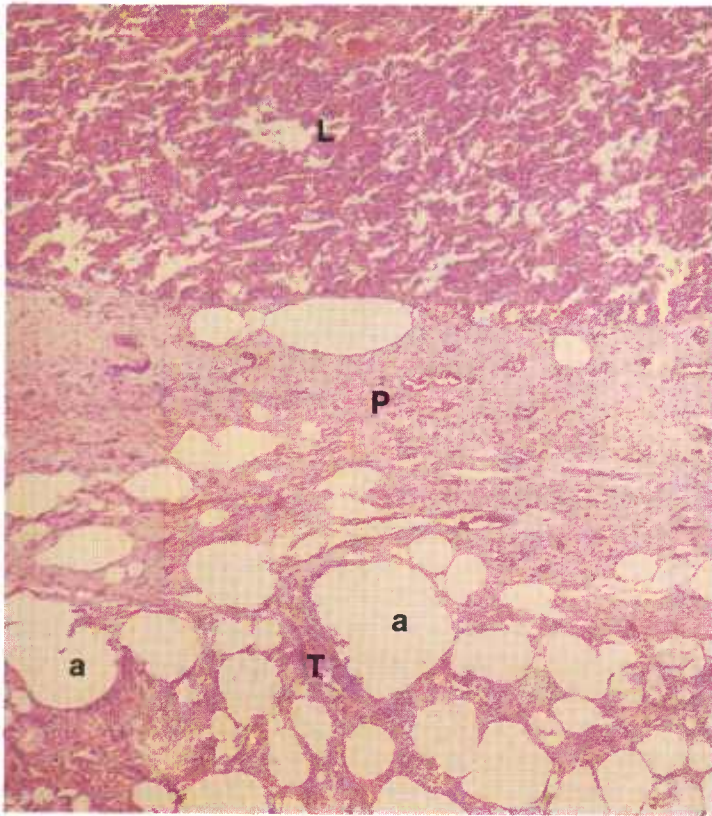


Figure 148.—A histologic preparation of the lipoma of the pleura (A366-D3001) shown in figure 145. The tumor (T), which contains adipose cells (a), is attached to the pleura (P) of the lung (L). Hematoxylin-eosin stain.  $\times 50$ .

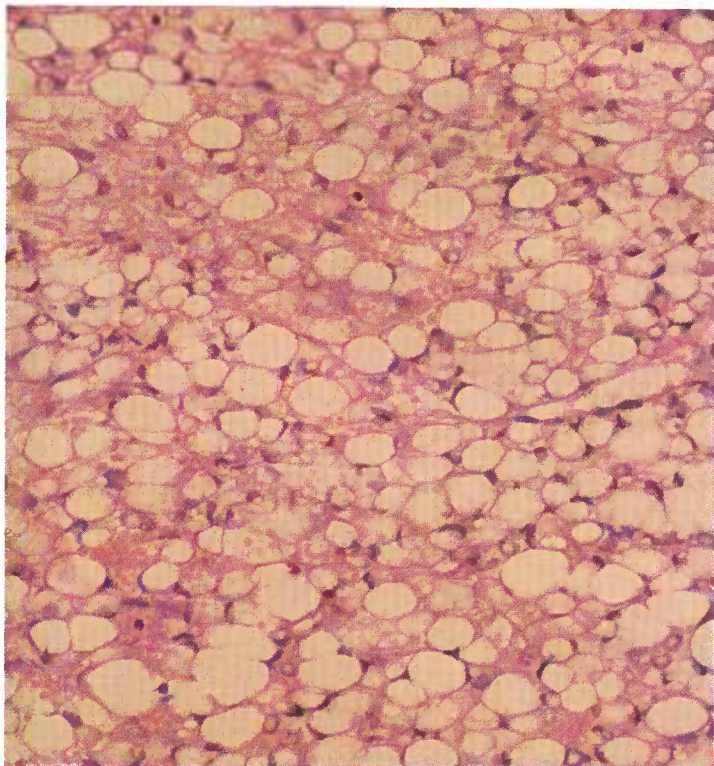


Figure 149.—Histologic preparation of the liposarcoma of the neck (A248-D2421) shown in figure 146. The adipose cells have large round nuclei and acidophilic cytoplasm, and they contain multiple fat droplets. Hematoxylin-eosin stain.  $\times 320$ .

ically abundant, as in the mesentery, peritoneum, subcutis, and submucosa. The most common sites are the subcutaneous tissues of the thorax and abdomen. (It should be noted that the fat of the lipoma and liposarcoma is not available to the body during periods of starvation. When normal body fat wastes away, these tumors may actually increase in size.) In all species of animals, adipose tissue tumors are frequently found in the subserosal fat of the abdominal cavity. These tumors are often pedunculated. Occasionally the pedunculated tumors of the peritoneum, which are reported to grow as long as 18 inches, become wrapped around a loop of intestine and produce strangulation. Pedunculated tumors of the peritoneum may become detached and may then be found as necrotic and partially mineralized masses in the peritoneal cavity.

Great care should be taken not to confuse the chronic inflammation associated with fat necrosis with the lipoma. Phagocytic cells containing an abundance of fat droplets resemble lipoblasts. The traumatic fat necrosis that occurs in the vagina of cattle is frequently diagnosed as a vaginal lipoma, when it actually represents the strangulation and necrosis of perivaginal fat that has protruded into the lumen of the vagina through rents or defects in the musculature of the vaginal wall.

**Macroscopic appearance.**—Lipomas usually occur as solitary growths, but many examples of multiple lipomas have been reported. Some of these are probably related to abnormalities in normal fat deposition. Lipomas are yellow or white tumors that vary in shape and size and may weigh more than 100 pounds. As has been mentioned, some of the growths are pedunculated. Most, however, are either lobulated or nodular. They may be encapsulated or they may be demarcated from adjacent tissues only by a change in the character of the fat. Lipomas are soft in consistency, and when they are incised, their cut surfaces have a greasy or oily translucent appearance. Mineralization of the tumors may occur and occasionally, when metaplasia takes place, bone will be found in the neoplasms.

Liposarcomas are much more varied in appearance than lipomas. They may be soft, moderately firm, or firm in consistency. Although often not distinctly encapsulated, they are frequently divided into definite lobules and present a distinct nodular appearance. Liposarcomas are often pink or mottled pink and may exhibit varying shades of gray and yellow. Mineralization and metaplasia with the formation of bone do not occur as frequently in the liposarcomas as in the lipomas.

**Microscopic appearance.**—Most lipomas have a simple structure and are made up of cells that contain one large fat globule or several smaller ones. The nuclei are pushed to the peripheries of the cells and may not be visible in histologic preparations. Interspersed between the fat cells are strands of collagenous fibers, and frequently thicker sheets of these fibers form an incomplete capsule at the periphery of the tumor.

Occasionally, lipomas of a more immature type are

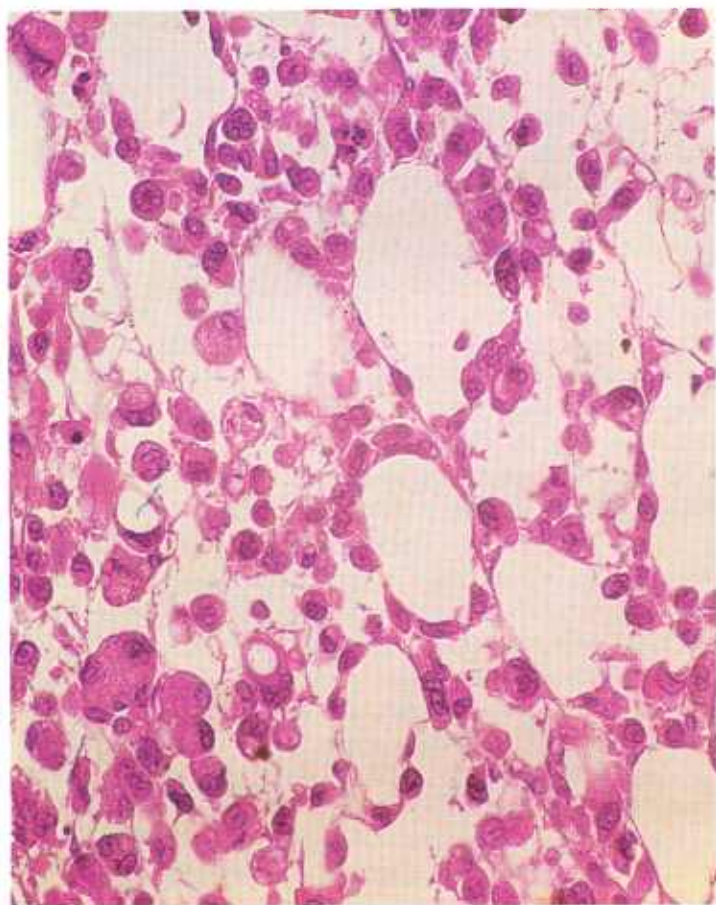


Figure 150.—Histologic preparation of a very malignant liposarcoma (DA16352). The cells are irregular in size and shape, their nuclei are hyperchromatic, and their cytoplasm is acidophilic and contains multiple fat droplets. Hematoxylin-eosin stain.  $\times 320$ .

found. These are characterized by the presence of numerous immature lipoblasts arranged in clumps or patches. These cells have spherical nuclei that stain intensely with hematoxylin and finely granular acidophilic cytoplasm. Their nuclei contain an abundance of fine chromatin granules and possess small eccentrically located nucleoli. When special fat stains (oil red "O," Nile blue sulfate, or scarlet red) are used to stain sections from formalin-fixed tissue prepared with a frozen-section technique, the presence of fat in these immature cells can be detected.

In liposarcomas, the resemblance of the neoplastic cells of the liposarcomas to normal fat cells is more difficult to recognize than in lipomas. Round, stellate, spindle-shaped, and multinucleated cells are found in these growths, as well as the characteristic polyhedral cells. The nuclei of liposarcomas are usually large. Giant cells and mitotic figures are occasionally observed. Neoplasms with loosely arranged spindle-shaped nuclei are frequently invasive and should not be confused with fibrosarcomas or myosarcomas. The identification of small droplets of fat in the cytoplasm requires the use of fat stains, and the diagnosis may be difficult to arrive at without this supporting information.

## Osteoma and Osteosarcoma

**Definition.**—Osteomas and osteosarcomas are tumors that have the ability to form osteoid tissue and, in most instances, identifiable bone.

**Distribution and incidence.**—Osteomas and osteosarcomas are found throughout the United States. No generic, species, breed, or sex predominance has been established for meat-producing animals. No tumors of this type were found during the USDA's 2-year survey, mentioned on page 1. However, several specimens were submitted to the Denver laboratory before and after the survey—an indication that these tumors do occur but are relatively uncommon.

Osteomas and osteosarcomas are most frequently found in the bones that form the noses and sinuses of horses and cattle. They are found less commonly in the long bones, and seldom appear in other osseous structures.

**Macroscopic appearance.**—Osteomas are generally small, slow-growing tumors that resemble normal bone and are attached to some part of the skeleton. They are hard, sharply circumscribed, and encapsulated. These round or elliptical growths generally involve the bones of the head, particularly those of the nasal passages and orbital regions.

Osteosarcomas cause extensive destruction of tissue and have an expanding and infiltrating mode of growth. Metastases are common and are most frequently located in the lungs. Bone in the vicinity of these neoplasms undergoes demineralization in an irregular pattern ac-

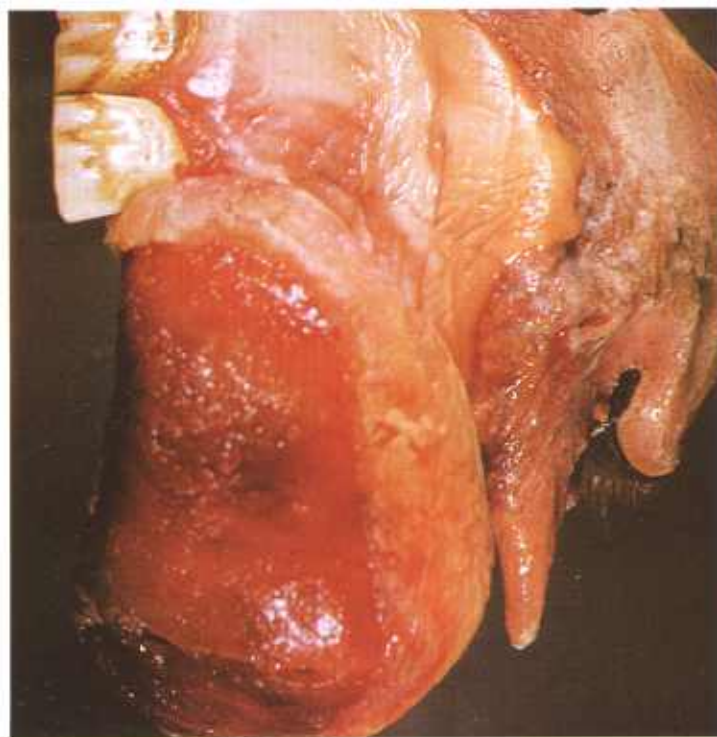


Figure 151.—Osteoma of the premaxilla of a 5-year-old male horse (A140-D1581). A hard, dense tumor with necrosis and ulceration of the surface.

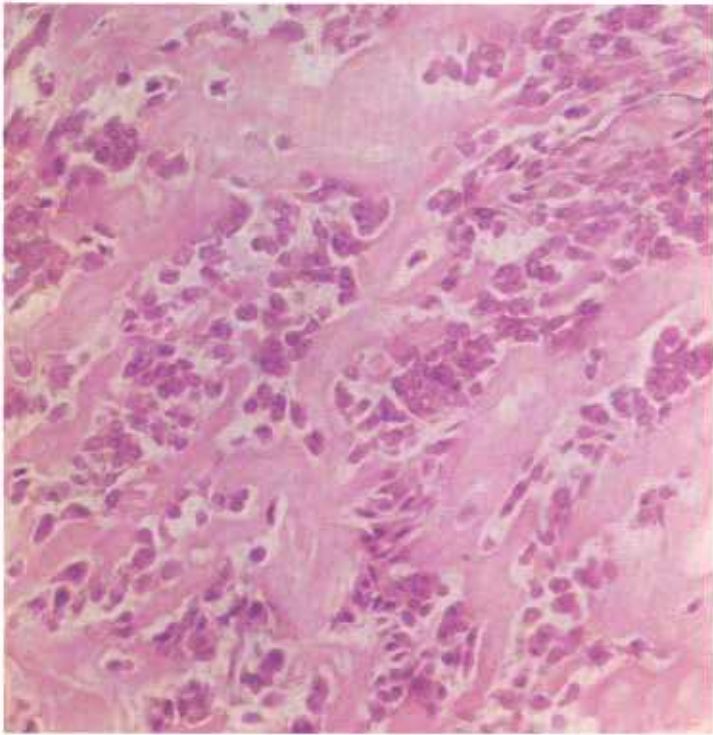


Figure 152.—Histologic preparation of an osteosarcoma of the femur (M4738). Nests of tumor cells are separated by an homogeneous, eosin-staining osteoid tissue. Hematoxylin-eosin stain.  $\times 320$ .

cording to the location of the neoplastic infiltration. Strands of partially mineralized neoplastic tissue growing in a radiating pattern from the center of the neoplasm give the growth a characteristic sunburst pattern when the cut surface of a cross section or when a roentgenogram is examined. Necrosis and hemorrhage may be present. Fracture of the long bones usually occurs because of traumatic injury of osseous structures that have been invaded and rarefied by neoplastic tissue.

**Microscopic appearance.**—The arrangement of lamellae in most osteomas is like that of normal bone. Haversian canals are not as uniformly arranged and often run at right angles to the bone axis. Marrow may be seen in the larger canals. The capsule of the tumor is similar to periosteum.

Identification of osteosarcomas is based on the ability to recognize neoplastic osteoblasts and to make the determination that these cells are producing osteoid tissue. Unless production of osteoid tissue can be demonstrated somewhere in the neoplasm, a diagnosis of osteosarcoma cannot be made. Osteoblasts may be very anaplastic, pleomorphic, and hyperchromatic, and they usually tend to produce spindle-shaped cells. Quite frequently osteosarcomas contain many tumor giant cells. The presence of giant cells can be misleading if too much importance is placed on their presence, for both the giant-cell tumor of tendon sheaths and the chronic inflammatory processes of tissues contain multinucleated cells with which osteoblastic giant cells may be confused.

## Rhabdomyoma and Rhabdomyosarcoma

**Definition.**—A rhabdomyoma is a benign tumor composed of cardiac or skeletal muscle. The malignant form of the tumor is known as a rhabdomyosarcoma.

**Distribution and incidence.**—Rhabdomyomas and rhabdomyosarcomas are found in meat-producing animals throughout the United States. No sex or breed incidence has been established. These neoplasms have been most frequently described in connection with cattle and pigs. They are probably more common in pigs, where they involve the heart and hind legs, and they are suspected of being congenital in origin.

Most of the rhabdomyomas that have been described have occurred in the lateral thoracic wall, in the muscles of the limbs, or, particularly, in the myocardium. They are usually found by meat inspectors who are incising hearts for the detection of tapeworm cysts. Although these tumors also occur in skeletal muscle, they are probably overlooked during routine meat inspection unless they become exceedingly large. Rhabdomyomas seldom become malignant and very few descriptions of their occurrence in animals are available. Apparently, they do not contribute to the death of the host animal and are found as incidental lesions during postmortem examinations.

**Macroscopic appearance.**—Rhabdomyomas are most easily observed in the myocardium, where they form firm globular masses measuring 1 to 3 cm. in diameter.

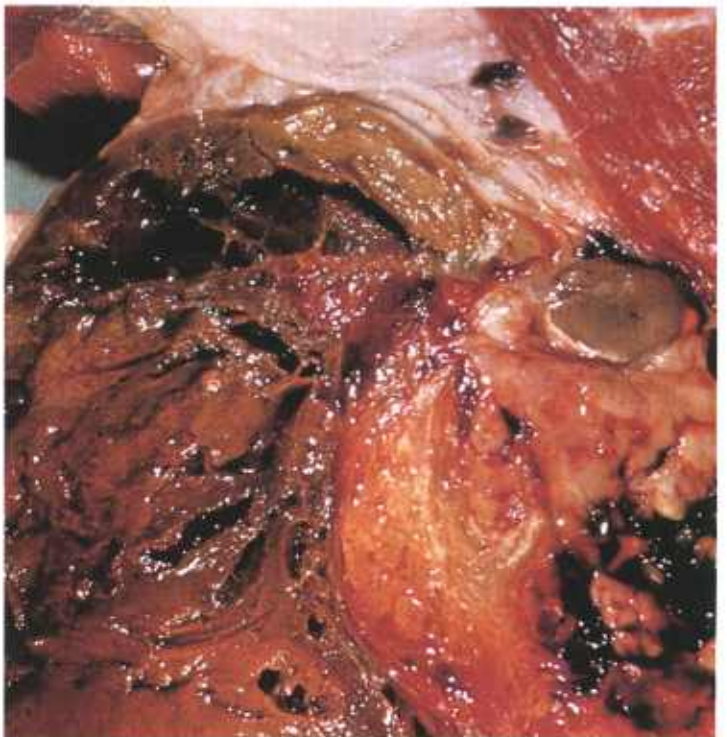


Figure 153.—Rhabdomyosarcoma of the left hind leg of an adult ewe (A101-D1448). The tumor, which measures 6 inches in diameter, is oval, gray, and vascular and contains extensive areas of necrosis. Metastatic tumors (not visible) are present in the popliteal lymph nodes.

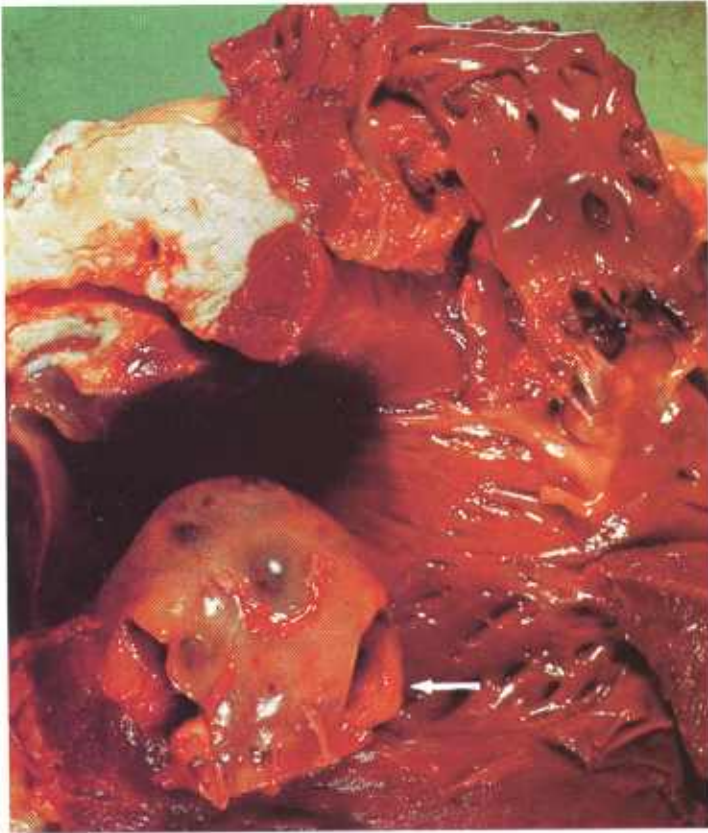

Figure 154.—Rhabdomyosarcoma (arrow) of the heart of an 18-month-old Hereford cow (A195-D2200). The tumor consists of a solid, red mass (5 by 5 by 3 cm.) in the wall of the left ventricle.

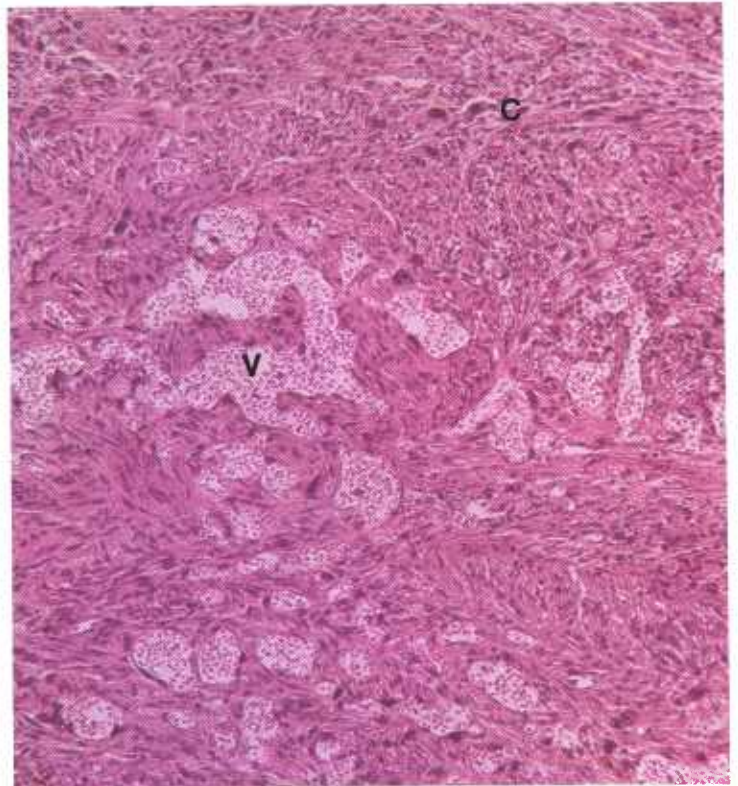


Figure 156.—A histologic preparation of the rhabdomyosarcoma (A195-D2200) shown in figure 154. The neoplasm is composed of a very vascular part (V) resembling an angiosarcoma and a more cellular part (C) containing many multinucleated cells that are irregular in size and shape. Hematoxylin-eosin stain.  $\times 50$ .

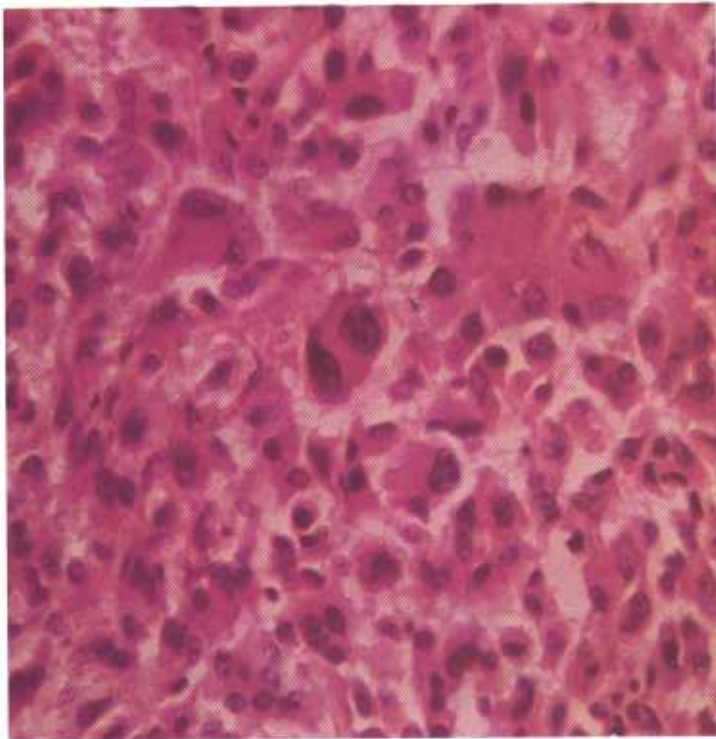


Figure 155.—A histologic preparation of the rhabdomyosarcoma (A101-D1448) shown in figure 153. The cells and their hyperchromatic nuclei are irregular in size and shape. A few of the cells are multinucleated. Very little supporting connective tissue stroma is present. Hematoxylin-eosin stain.  $\times 320$ .

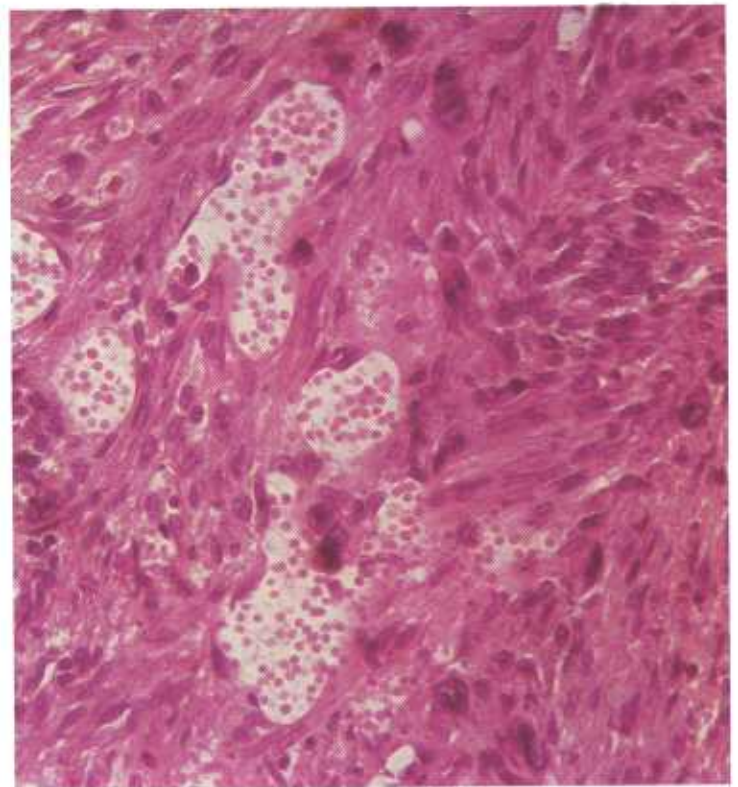


Figure 157.—A higher magnification of the vascular part (V) of the rhabdomyosarcoma (A195-D2200) shown in figure 156. Hematoxylin-eosin stain.  $\times 320$ .

Their characteristic of blending into the adjacent muscle, their consistency, and their iridescent sheen leave little doubt of their relationship to muscle.

Rhabdomyosarcomas are found in the same sites as

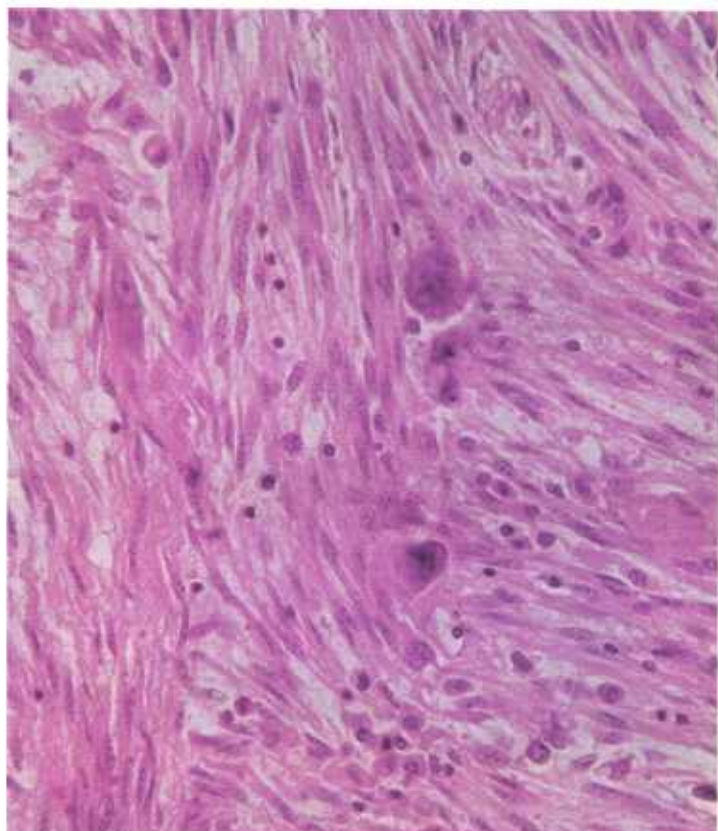


Figure 158.—A higher magnification of the cellular part (C) of the rhabdomyosarcoma (A195-D2200) shown in figure 156. Hematoxylin-eosin stain.  $\times 320$ .

those favored by rhabdomyomas—the lateral thoracic wall, the muscles of the limbs, or, most particularly, the myocardium. These sarcomas are difficult to recognize because they are not distinctly demarcated from adjacent muscle tissue and tend to lose their resemblance to it. Besides losing their continuity with the muscle, they occasionally become quite vascular and are frequently confused with angiosarcomas and fibrosarcomas. Rhabdomyosarcomas have a slow, local, insidious mode of growth and a few instances of metastasis have been reported.

**Microscopic appearance.**—Rhabdomyomas are composed of an interlacing network of spindle-shaped cells with elongated nuclei. Their histologic identification is based upon their resemblance to normal cardiac or skeletal muscle cells and their production of cross striations.

Rhabdomyosarcomas are difficult to recognize and the demonstration of striated neoplastic cells is not easy. Most of the tumor's cellular growth is without distinguishing characteristics and resembles the cellular growth of the fibroblast. Diagnosis is based on the tumor's anatomic location (heart, thoracic wall, or limbs), its characteristic of being enclosed within muscle, and its production of cross striations and cells with multiple and bizarrely shaped nuclei. It should be noted that errors in the detection of cross striations are easily made when the striations in the infiltrating myoblasts are confused with the striations found in nonneoplastic muscle cells.

The nuclei of the neoplastic cells may be round, elongated, or irregularly shaped and they have no definite location in the cells. One or several nuclei may be found in the same cell. Cells with multiple nuclei are usually large.

## Hematopoietic Tissue Tumors

### Lymphosarcoma

**Definition.**—A lymphosarcoma is a malignant neoplasm composed of immature lymphocytes.

**Distribution and incidence.**—Lymphosarcomas are found in domesticated animals throughout the United States. All genera, species, breeds, sexes, and ages of meat-producing animals are affected. During the USDA's survey, mentioned on page 1, 2.0 percent of the cattle tumors, 30 percent of the sheep tumors, and 32 percent of the swine tumors collected were lymphosarcomas.

Involvement of the superficial lymph nodes is one of the most characteristic features of this disease in all meat-producing animals except cattle. Thoracic and abdominal lymph nodes are more commonly affected than the nonvisceral lymph nodes in cattle. The high incidence of lymphosarcomas in certain areas, on individual farms, and even within specific families of animals suggests that a hereditary factor as well as an infectious agent may be involved in their appearance.

**Macroscopic appearance.**—Lymphosarcomas occur as focal tumors within organs or as diffuse infiltrations of organs and usually involve multiple tissues and organs throughout the body. These neoplasms are grayish white or pinkish white and tend to be rather soft and encephaloid in consistency. In all, they resemble lymphoid tissue in consistency and appearance.

Since the lymphosarcoma affects lymphoid tissue, all organs in the host animal that contain lymphoid tissue become greatly enlarged. The thymus, lymph nodes, tonsils, and Peyer's patches may become several times their normal size. The spleen enlarges and the bulging splenic pulp obscures the normal trabecular architecture. The marrow cavity of the bones becomes filled with grayish-red or brownish-red neoplastic tissue. The liver becomes greatly enlarged, and the lobular architecture becomes much more distinct than normal because of the accumulation of neoplastic cells in the interstitial tissue.

Lymphosarcomas in cattle are frequently observed to effect a diffuse infiltration of the abomasal wall that causes the wall to become as much as 4 inches thick.

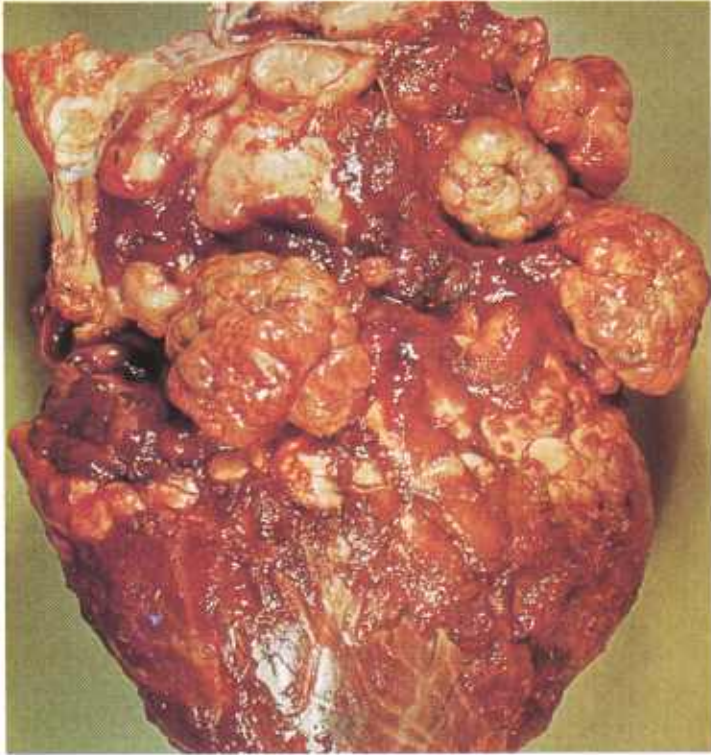


Figure 159.—Lymphosarcoma of the heart of a 5-year-old Holstein bull (A437-D3480). A gray, lobulated, encephaloid tumor is present at the base of the heart. It has invaded the atria and surrounds the large vessels leaving the heart.

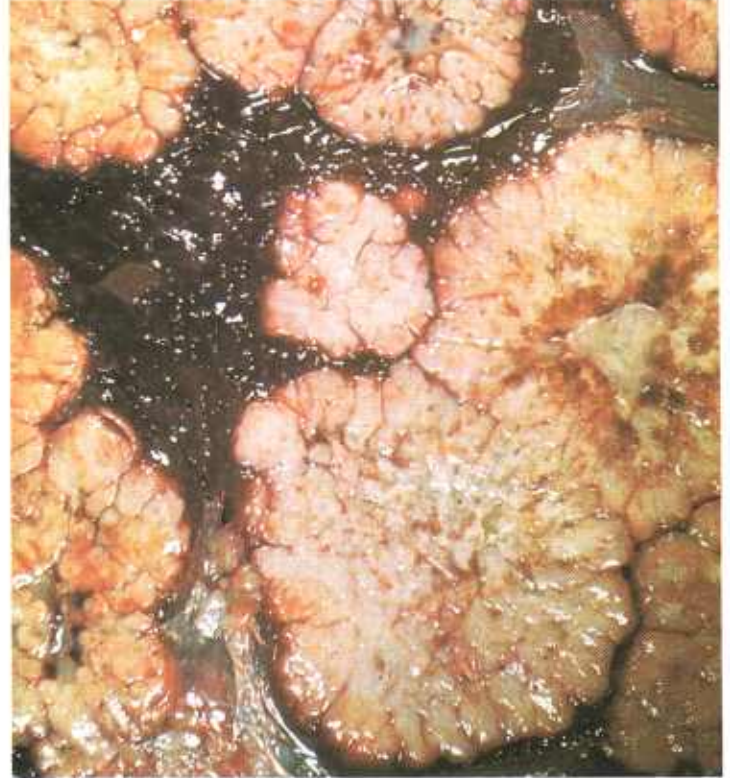

Figure 161.—Lymphosarcoma of the spleen of a 6-year-old ewe (A182-D2036). Multiple grayish-pink, lobulated tumors are scattered throughout the parenchyma of the spleen.

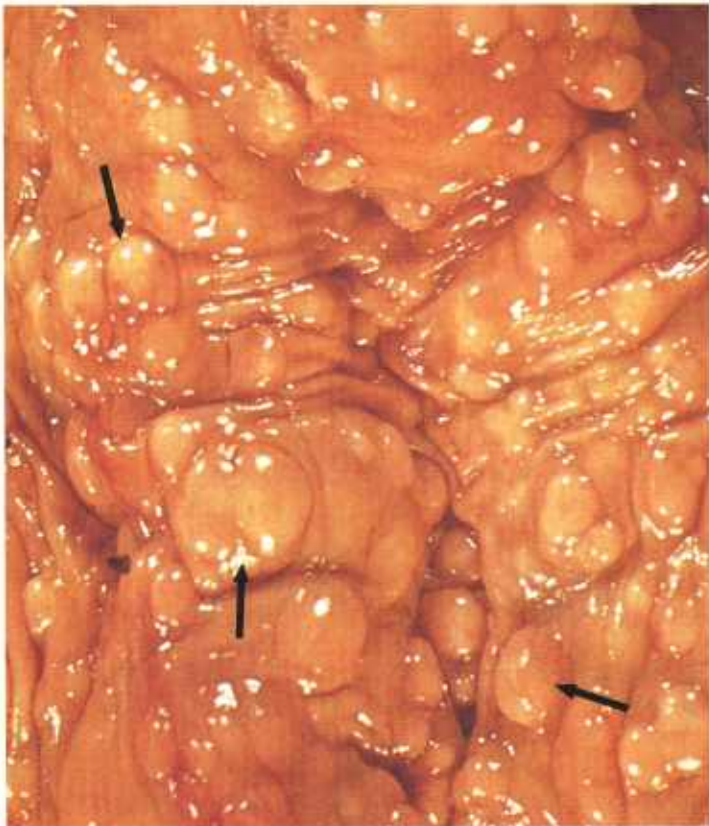

Figure 160.—Lymphosarcoma of the uterus of an old cow (A373-D3082). Solid, gray, nodular tumors measuring 3 to 15 mm. in diameter (arrows) are present in the wall of the uterus. No ulceration of the uterine mucosa has occurred.

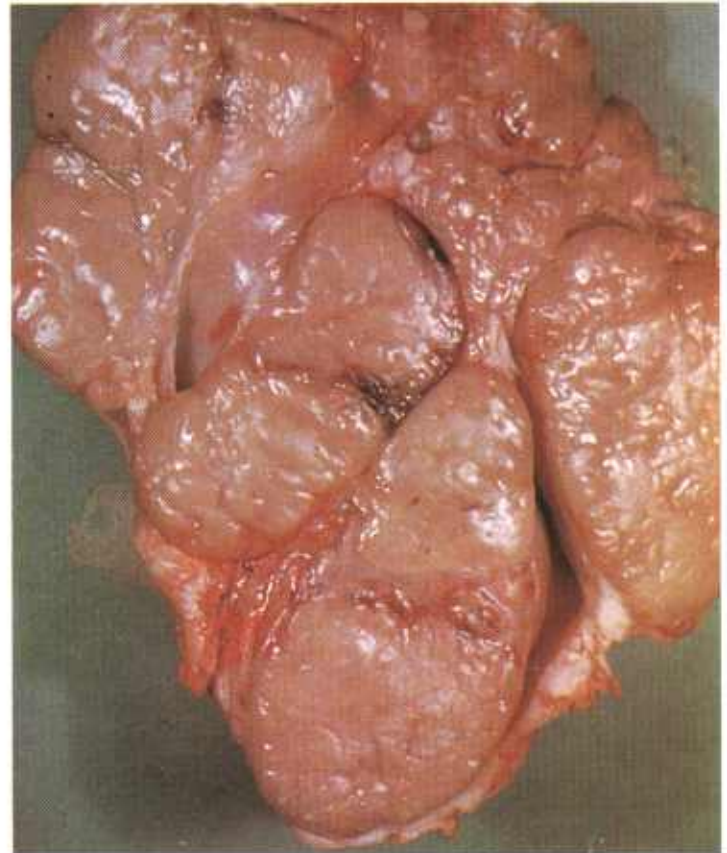


Figure 162.—Lymphosarcoma of a lymph node of an 8-month-old gilt (A9-D1235). The gross anatomical characteristics of the node have been obliterated.

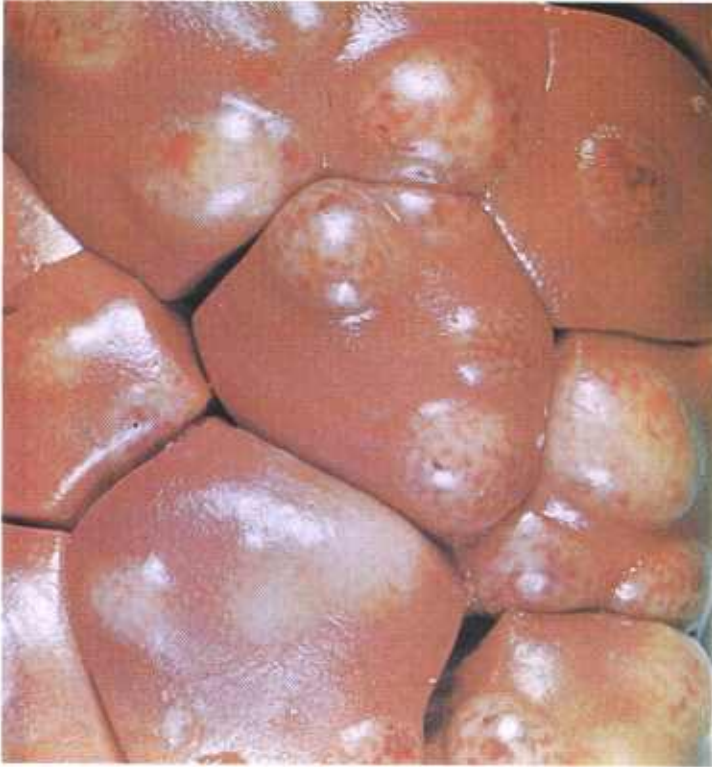

Figure 163.—Lymphosarcoma of the kidney of a 7-year-old cow (A77-D1404). Multiple white nodules that contain red focal areas of hyperemia and hemorrhage are scattered throughout the parenchyma of the kidney.

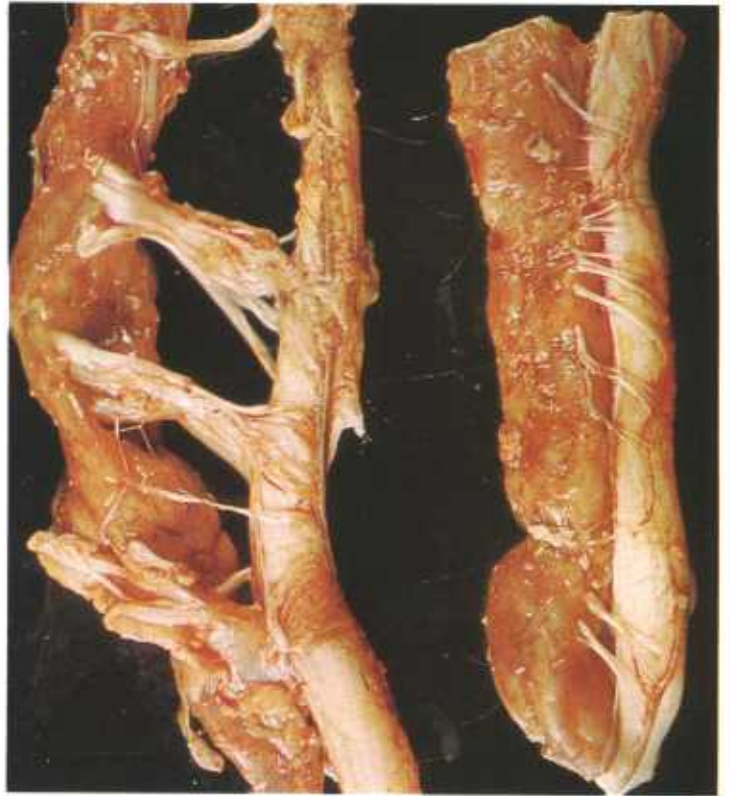

Figure 165.—Lymphosarcoma in the vertebral canal of a 5-year-old cow (A443-D3489). A grayish-yellow tumor has infiltrated around the spinal cord and nerves of the lumbo-sacral region.

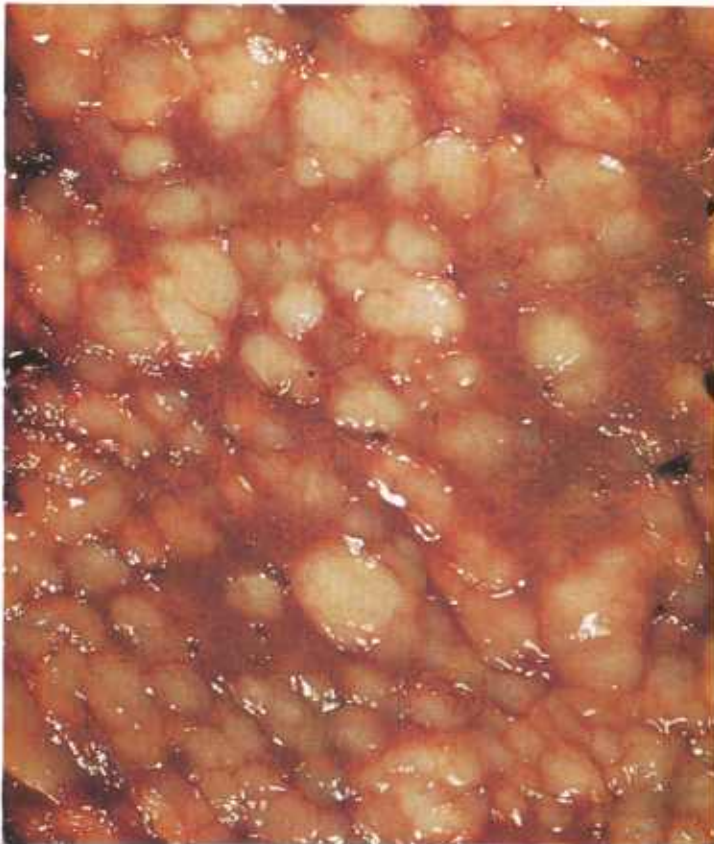


Figure 164.—Lymphosarcoma of the liver of an old ewe (A399-D3098). Firm gray nodules measuring 3 to 15 mm. in diameter are scattered throughout the parenchyma of the liver.

Although the sublumbar lymph nodes are the most consistently involved group of lymphoid tissues in cattle, affected sublumbar lymph nodes are not as striking in appearance as are affected tumefied mediastinal and anterior thoracic groups of lymphoid tissue. Occasionally, cattle have a cutaneous form of lymphosarcomas that is characterized by multiple nodules in the skin.

**Microscopic appearance.**—The normal architecture (follicles, germinal centers, cortex and medulla, sinuses, and cords) of the involved lymphoid tissue or organ disappears. Many normal lymphocytes are present but there are also myriads of embryonic cells. Focal areas of coagulative and liquefactive necrosis are frequently observed within the tumor.

Large numbers of immature lymphocytes may be found in the circulating blood stream in terminal stages of the disease. Total leukocyte counts are usually between 40,000 to 60,000 lymphocytes per cubic millimeter of blood, but much higher counts are observed. One of the confusing peculiarities of this disease is that cellular alterations in the blood are frequently not present or are slight. In cattle, the total number of leukocytes is usually only slightly elevated and lymphocytes and lymphoblasts are the predominating cells. There is a marked decrease in the total number of erythrocytes, granulocytes, and platelets because the infiltrating neoplastic cells cause atrophy of the erythropoietic tissue in the bone marrow. The red and white pulp and the sinusoids in the spleen are filled with neoplastic cells,

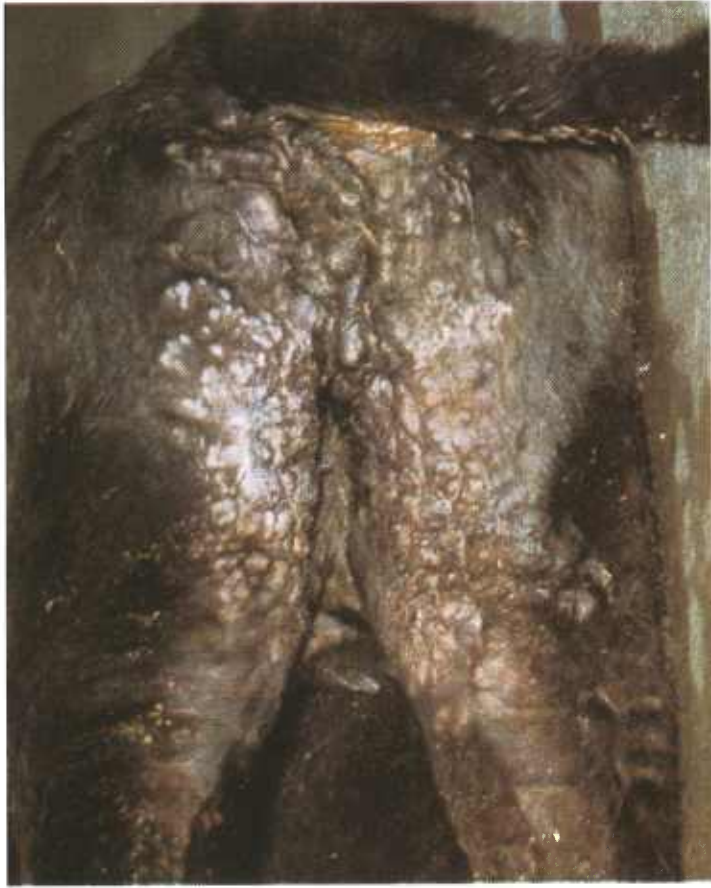

Figure 166.—Lymphosarcoma of the skin of an Angus cow (M103). Multiple tumor nodules, most abundant in the perineal region, are present in the skin.

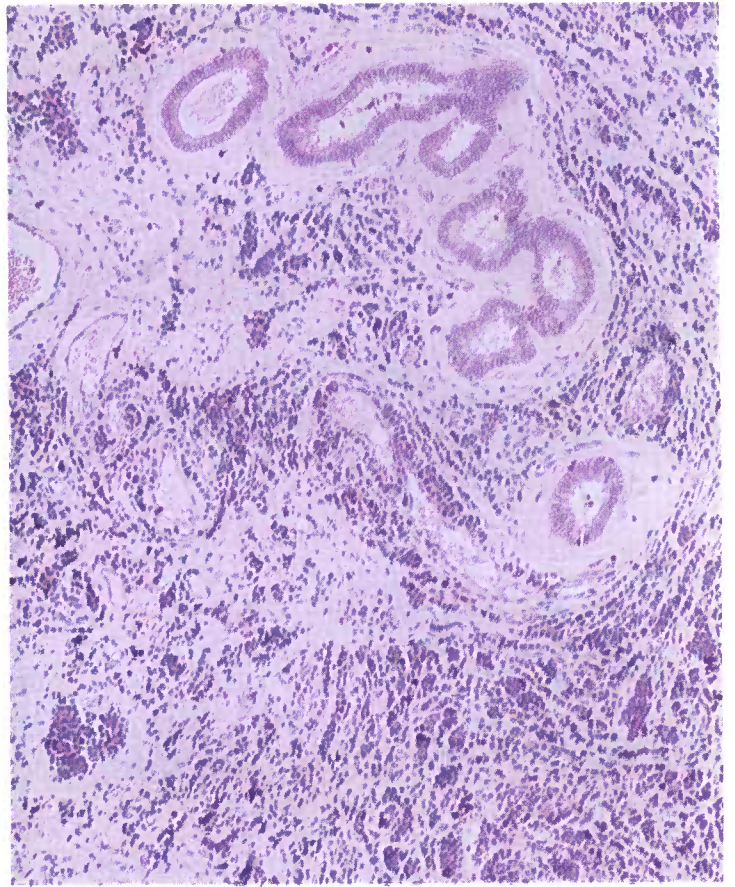


Figure 168.—Lymphosarcoma of the uterus of a 5-year-old cow (A443-D3489). There is a diffuse infiltration of the uterine wall with malignant lymphocytes. Hematoxylin-eosin stain.  $\times 125$ .

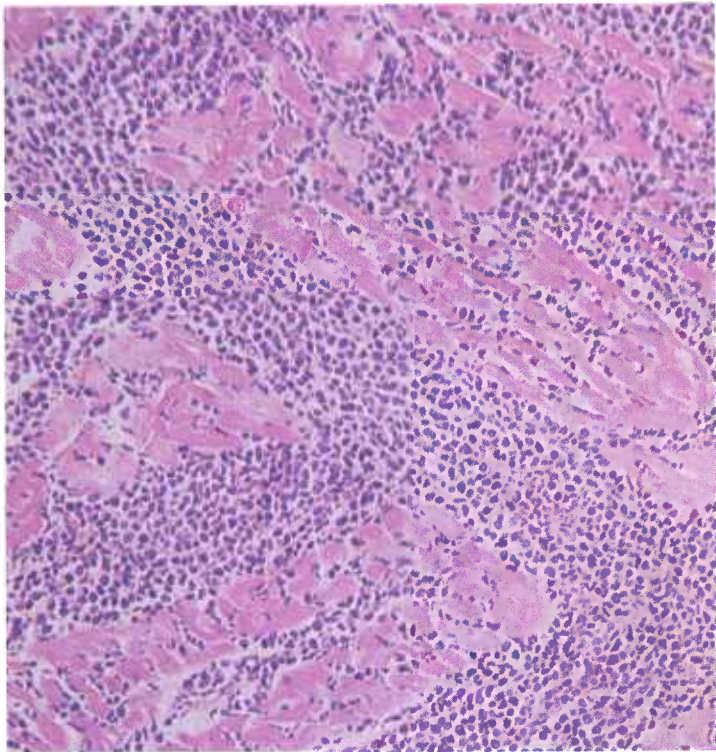


Figure 167.—Lymphosarcoma of the heart of a 9-year-old Hereford cow (D2550). The neoplastic cells have infiltrated between atrophic muscle cells. Hematoxylin-eosin stain.  $\times 125$ .

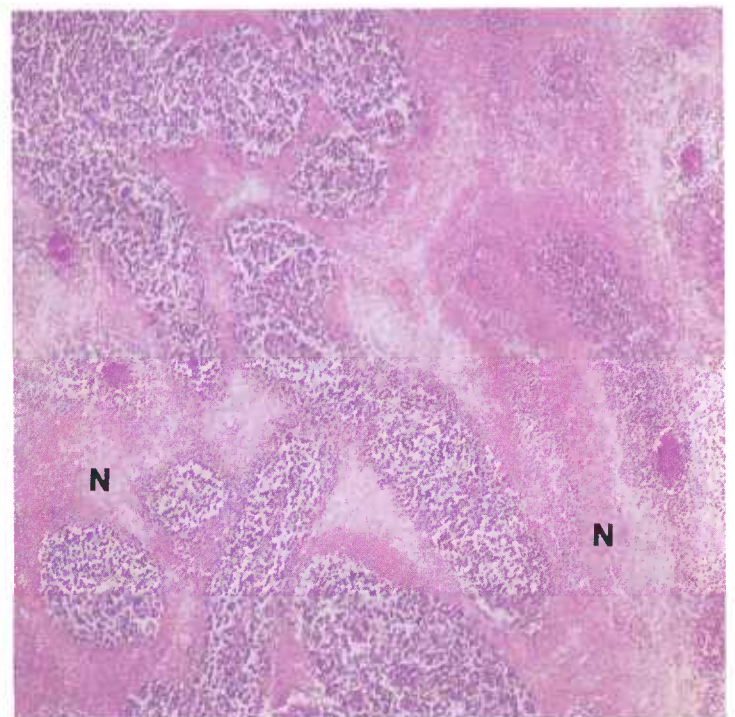


Figure 169.—Lymphosarcoma of a lymph node in a 5-year-old ewe (D2417). The general architecture of the node has been destroyed. Extensive areas of coagulative necrosis (N) are present. Hematoxylin-eosin stain.  $\times 50$ .

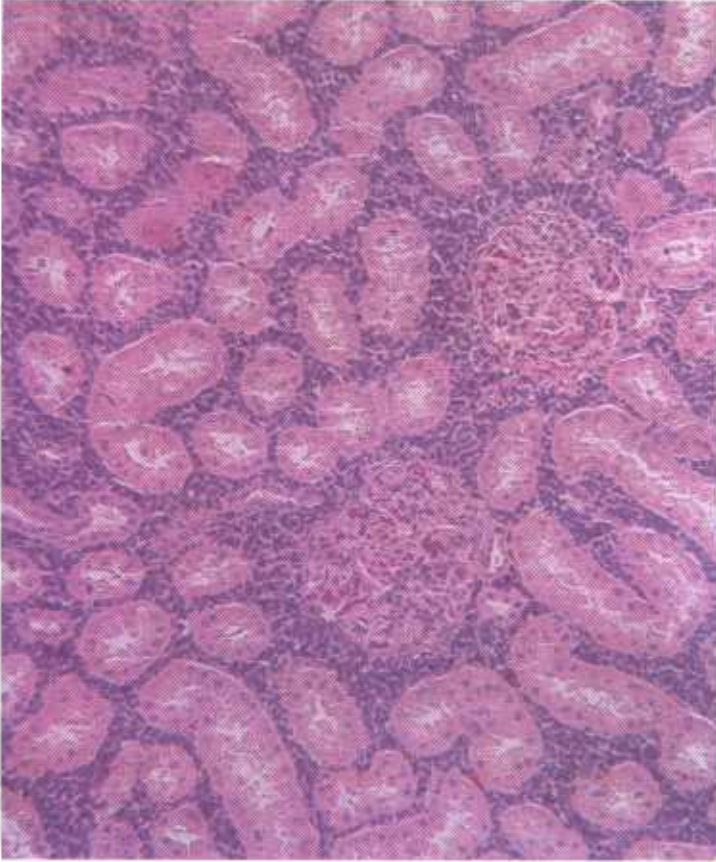


Figure 170.—Lymphosarcoma of the kidney of a 5-year-old cow (A443-D3489). Many malignant lymphocytes are infiltrating between the renal tubules and around the glomeruli. Hematoxylin-eosin stain.  $\times 125$ .

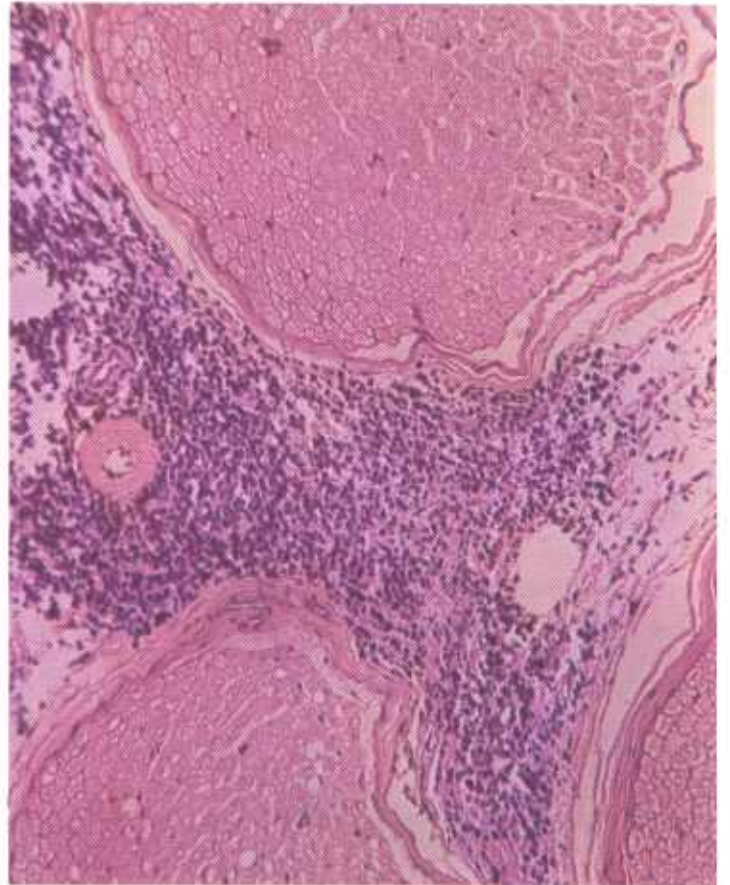


Figure 172.—Lymphosarcoma in the vertebral canal of a 4-year-old Holstein cow (D2898). Malignant lymphocytes are infiltrating between the spinal nerves. Hematoxylin-eosin stain.  $\times 125$ .

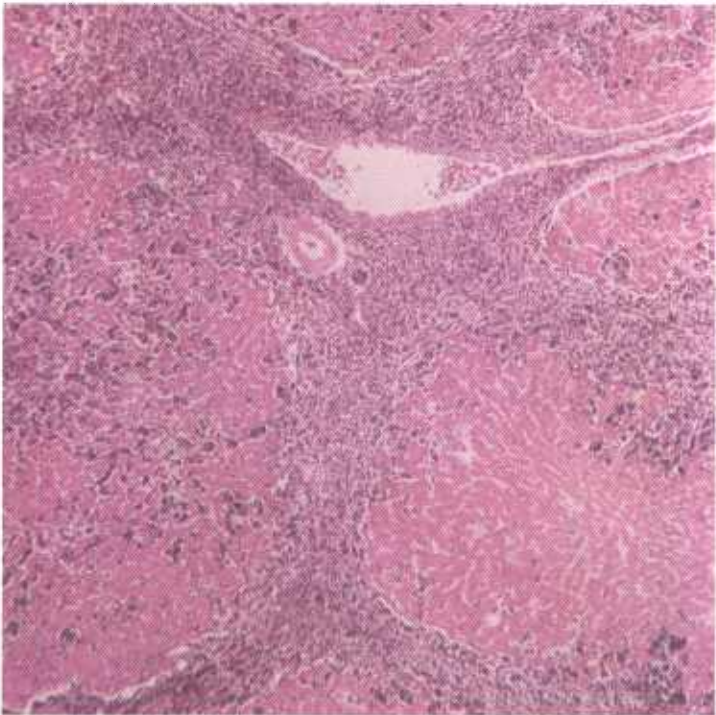


Figure 171.—Lymphosarcoma of the liver of a 9-month-old gilt (D3004). Malignant lymphocytes are infiltrating the hepatic lobules and the interstitial tissues of the liver. Hematoxylin-eosin stain.  $\times 50$ .

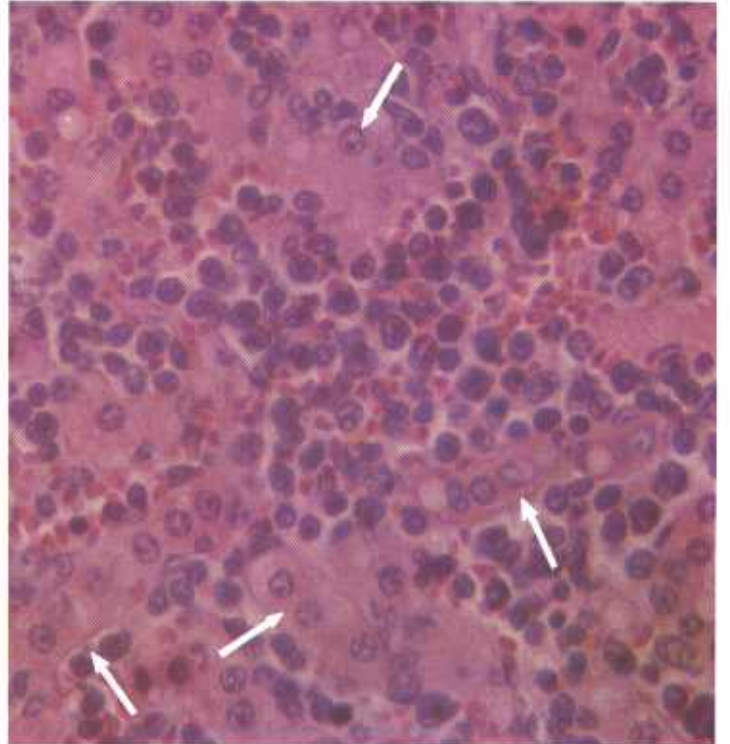


Figure 173.—Lymphosarcoma of the liver of an adult Hereford cow (C332). Malignant lymphocytes are infiltrating between the hepatic cells (arrows). Hematoxylin-eosin stain.  $\times 500$ .

and splenic corpuscles are difficult or impossible to find. The only remaining recognizable structures in an extensively involved spleen are the muscular trabeculae and capsule.

Kupffer's cells in the liver are hyperplastic and more numerous than normal. Large numbers of neoplastic cells are present in the interstitial tissue, especially in Glisson's triangle. As the neoplastic cells in the interstitial tissue increase in number, they invade the hepatic nodules from the periphery and cause pressure atrophy of the liver cells.

### Myeloma and Myelosarcoma

**Definition.**—A myeloma is a benign tumor composed of myeloid cells. The malignant type is known as a myelosarcoma.

**Distribution and incidence.**—Myelomas and myelosarcomas are found in meat-producing animals throughout the United States. During the USDA's survey, mentioned on page 1, 3 percent of the ovine tumors collected were found to be myelosarcomas. No tumors of this type were found in cattle or swine during the same period. Few myelomas have been reported in meat-producing animals and none were found in this survey. Information is not available concerning generic, species, breed, or sex incidence.

In general, it can be stated that all tumors of myeloid cells are myelosarcomas in varying stages of differentia-

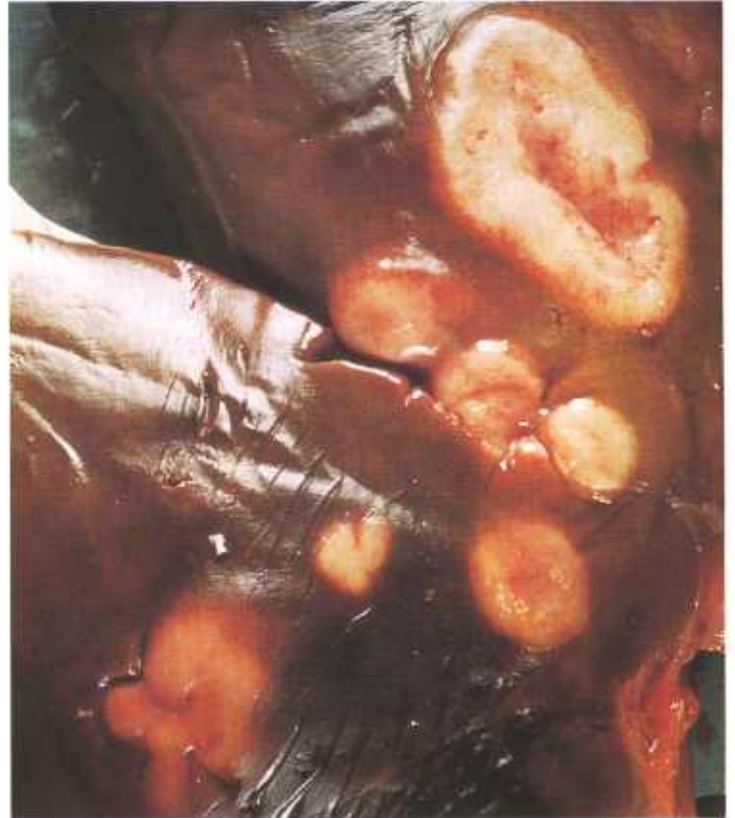

Figure 175.—Myelosarcoma of the liver of an old ewe (A415-D3179). Multiple firm, gray tumors measuring 5 mm. to 5 cm. in diameter and having slightly depressed centers are scattered throughout the parenchyma of the liver.

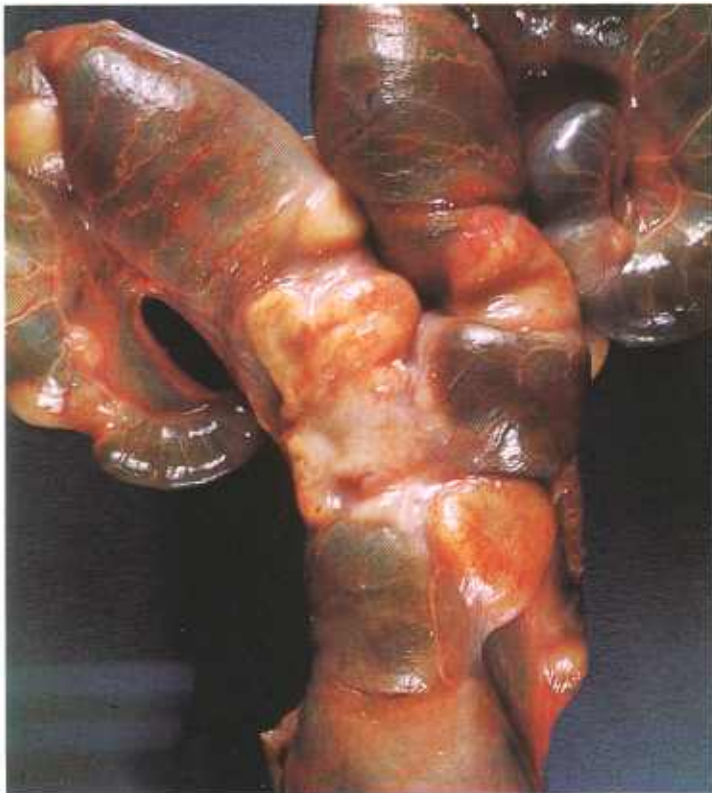

Figure 174.—Myelosarcoma of the uterus of an old ewe (A414-D3179). Firm, gray, rounded growths measuring 5 mm. to 3 cm. in diameter are present in the wall of the uterus.

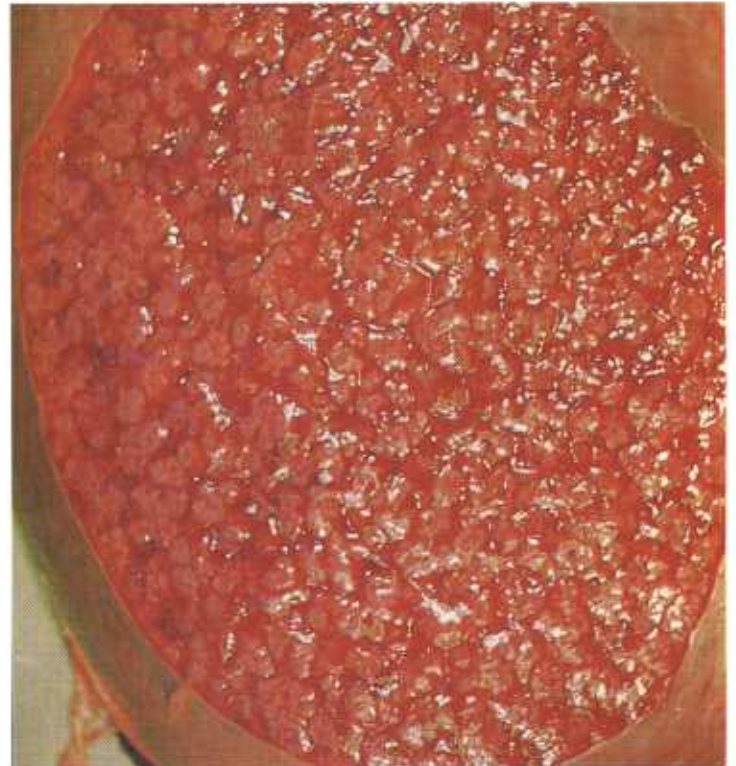


Figure 176.—Myelosarcoma of the spleen of a 5-year-old ewe (A36-D1296). The spleen, weighing 740 grams, is enlarged about eight times. On cross section, it reveals multiple gray, irregularly shaped foci of tumor tissue.

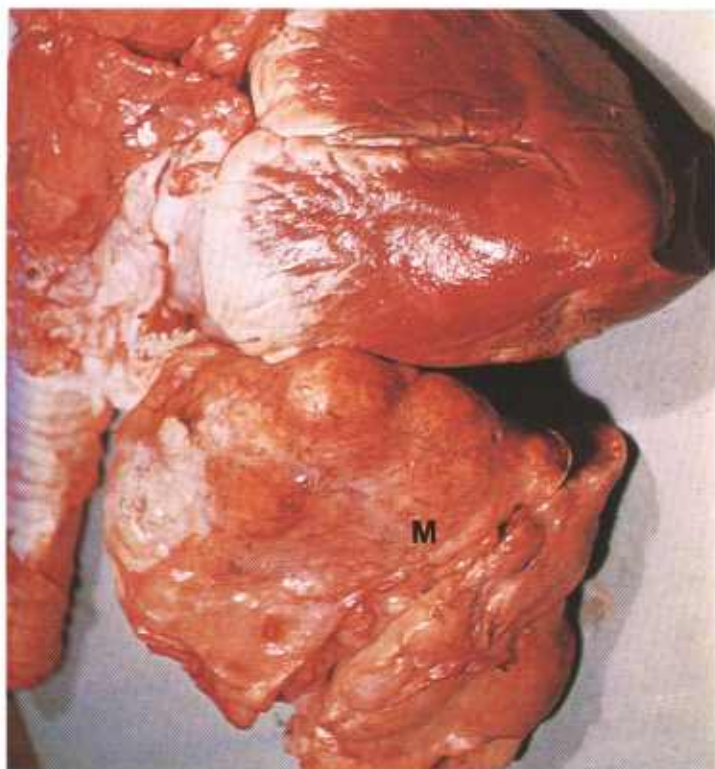


Figure 177.—Myelosarcoma (basophilic type) of the pericardium of a 3-year-old Hereford cow (A14-D1253). The mass (M) anterior to the heart is the reflected pericardium and contains multiple tumor nodules. No invasion of the heart has occurred but tumors are present in the visceral and parietal pleura, lung, liver, kidney, lymph nodes, and bone marrow.

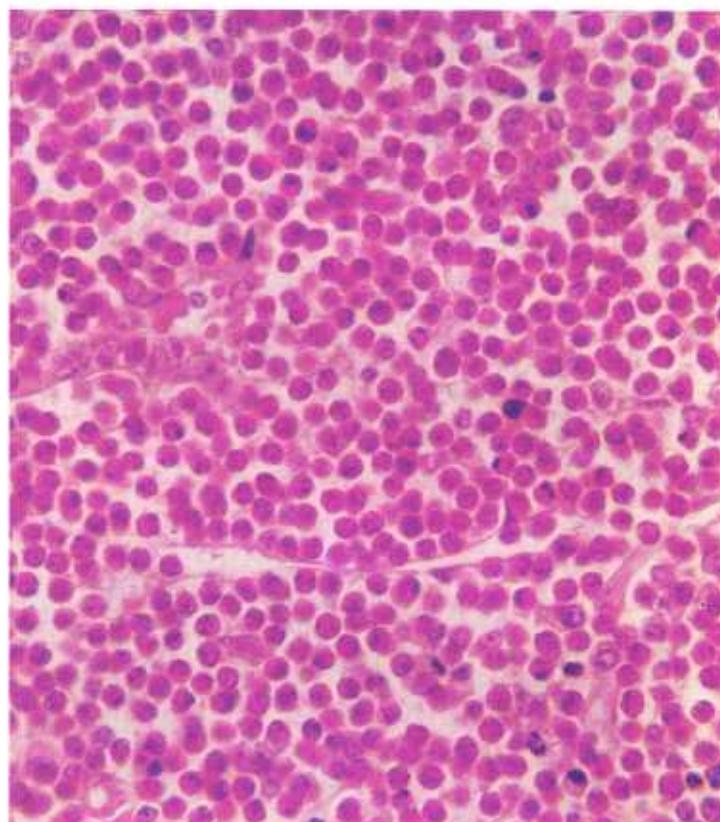
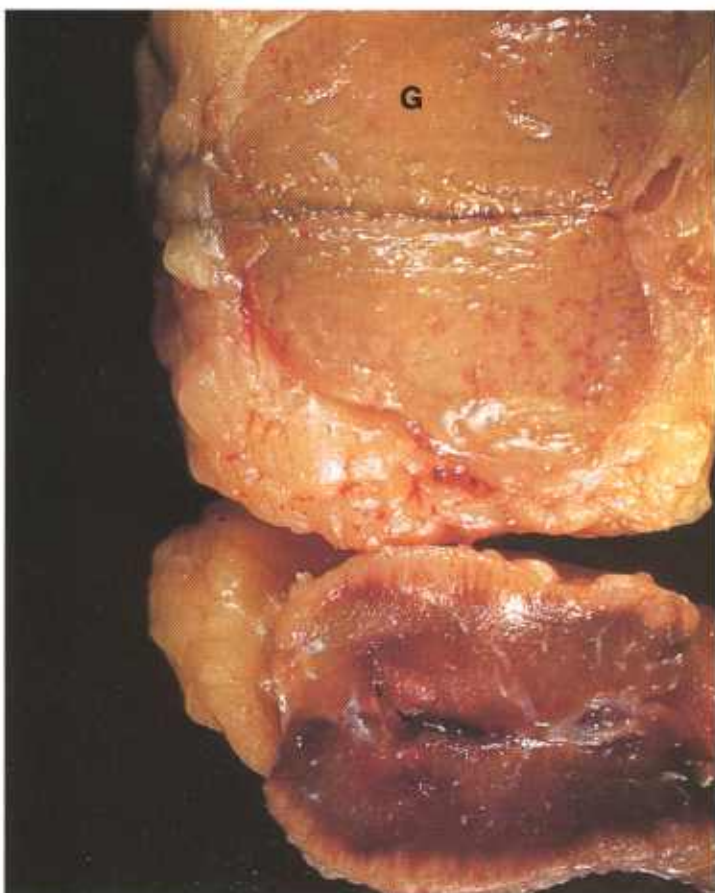


Figure 179.—A histologic preparation of the lymph node (A138-D1557) shown in figure 178. The tumor is composed of myeloid cells with acidophilic granular cytoplasm. Hematoxylin-eosin stain.  $\times 500$ .

tion. Myelosarcomas involve the hematopoietic tissues. As would be expected, these tumors are found most frequently in bone marrow and less commonly in lymph nodes, liver, spleen, and other organs. One uncommon type of myeloid tumor is composed of plasma cells. The multiple osteolytic foci described in the skeletons of man and dogs affected with plasma cell tumors have not been described in meat-producing animals. The granular-cell myeloid tumor can be confused with bacterial, mycotic, and parasitic lesions that contain mature myeloid cells.

**Macroscopic appearance.**—Tumors composed of neoplastic granulocytes are rather firm, are somewhat fibrous in texture, and are white, gray, or green. When the specimen is green, its color is always helpful in identifying the neoplasm. However, the green color gradually disappears when the tissue is exposed to air. Partial restoration of this color can be accomplished by flooding the neoplastic tissue with hydrogen peroxide. Tumors composed of neoplastic plasma cells are white or yellowish white.

Myeloid-cell tumors are irregular in both size and

←  
Figure 178.—Myelosarcoma of a lymph node in a 2-year-old steer (A138-D1557). Note that the growth (G) is green, a characteristic often associated with this type of neoplasm.

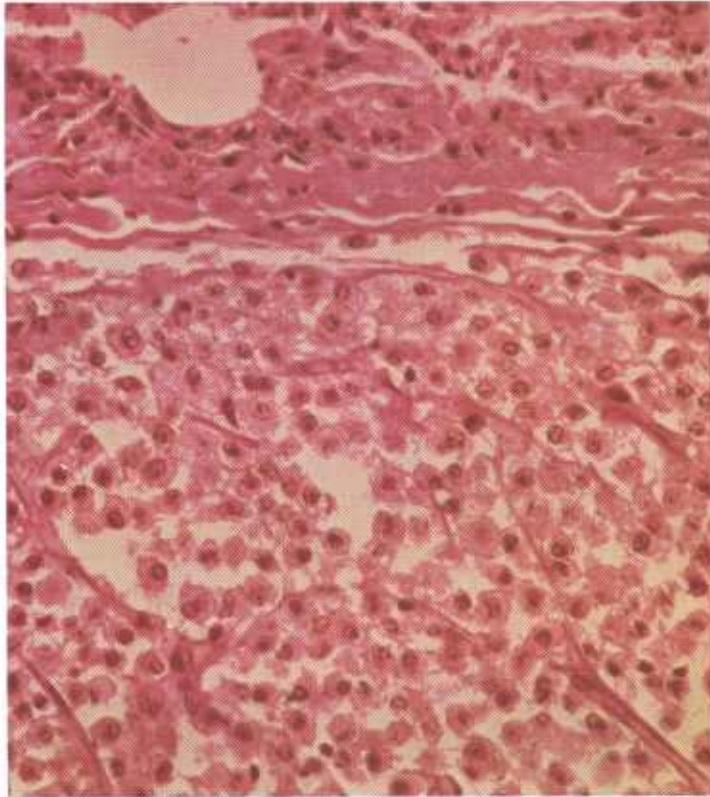


Figure 180.—Myelosarcoma (basophilic type) of the lung of a 3-year-old Hereford cow (A14-D1253). The granules in the cytoplasm of the neoplastic cells stain blue with the Giemsa stain. Hematoxylin-eosin stain.  $\times 320$ .

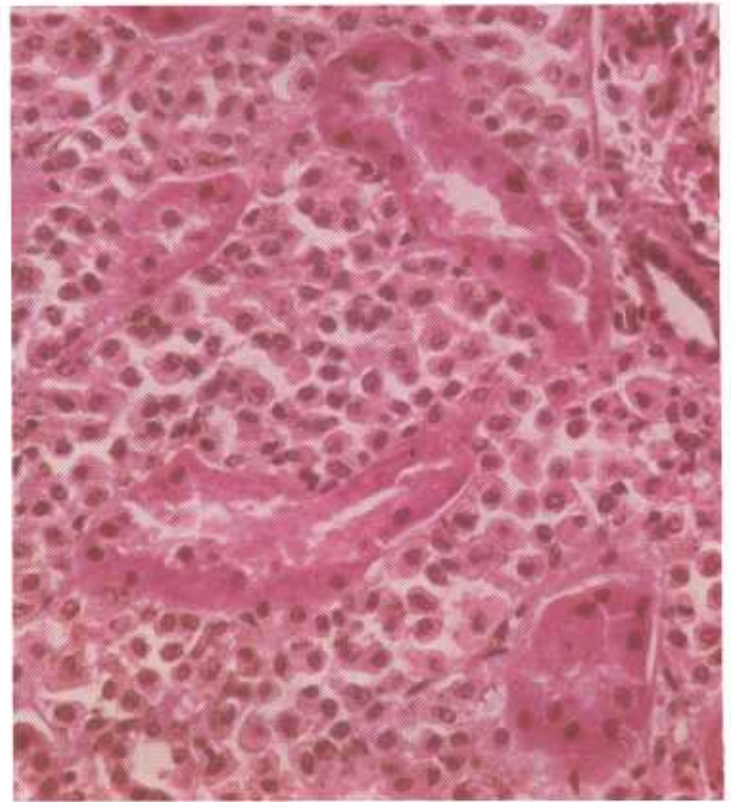

Figure 181.—Myelosarcoma (basophilic type) of the kidney of a 3-year-old Hereford cow (A14-D1253). Tumor cells containing granules that stain blue with Giemsa stain are infiltrating between the renal tubules. Hematoxylin-eosin stain.  $\times 320$ .

shape and are seldom over 8 cm. in diameter. Metastases are widely disseminated, even into the genital tract.

**Microscopic appearance.**—The basic cell constituent of the myeloma and myelosarcoma is the myelocyte in its various degrees of differentiation. According to the degree of differentiation, the more mature tumors may be further classified as plasmacytic, neutrophilic, eosinophilic, or basophilic. The basophilic type of myeloid tumor, popularly referred to as a mastosarcoma, is seldom observed in meat-producing animals.

Cells of the granular-cell type vary greatly in morphology. The primitive myelocytes are large cells with prominent nuclei and blue, nongranular cytoplasm,

whereas the more differentiated myelocytes have irregular, indented, or lobulated nuclei and cytoplasm that contain basophilic or eosinophilic granules. Mitotic figures are numerous. The typical myeloma or myelosarcoma of the granular-cell type usually contains granulocytes (neutrophils, eosinophils, and basophils) in various degrees of differentiation, primitive myelocytes, and even lymphocytes. The uncommon plasma-cell type of myeloid tumor consists predominantly of plasma cells. Before a diagnosis of myelosarcoma is made, involvement of the bone marrow, lymph nodes, spleen, liver, and other hematopoietic tissues and organs should be established.

## Neoplasms of the Nervous System

### Auditory (Acoustic) Nerve Tumor

**Definition.**—The auditory (acoustic) nerve tumor is an intracranial neoplasm that involves the acoustic nerve.

**Distribution and incidence.**—These tumors are so uncommon in domesticated animals that no information is available concerning generic, species, breed, or sex incidence. Three tumors associated with the auditory nerve have been found in animals slaughtered for food in Denver abattoirs. None were found during the USDA's 2-year survey mentioned on page 1. So few

tumors of this type have been found that their exact identity has not been established. They may originate from Schwann cells at the point where the auditory nerve leaves the internal auditory meatus. If they are derived from Schwann cells, they occur in much younger animals (6 to 12 months) than the peripheral nerve Schwannomas that occur in older animals (1 to 12 years). It is quite possible that they are atypical meningiomas of the fibrous type. The true identity of the auditory nerve tumor probably will not be resolved until additional cases have been studied.

**Macroscopic appearance.**—Auditory nerve tumors are

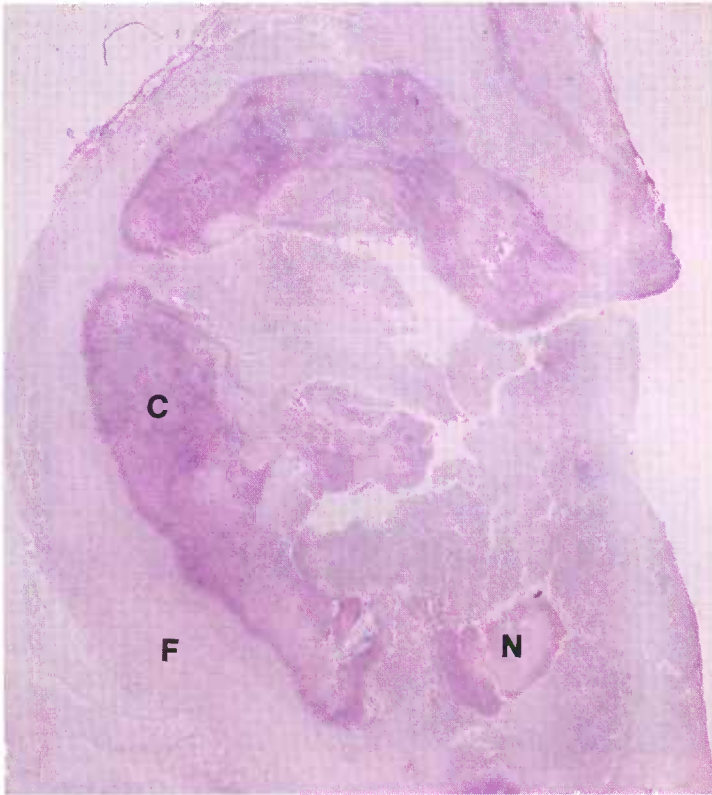


Figure 182.—Auditory nerve tumor in an 8-month-old hog (D2177). The tumor has a central cellular region (C) containing areas of necrosis (N) that is surrounded by a fibrous zone (F). Hematoxylin-eosin stain.  $\times 9$ .

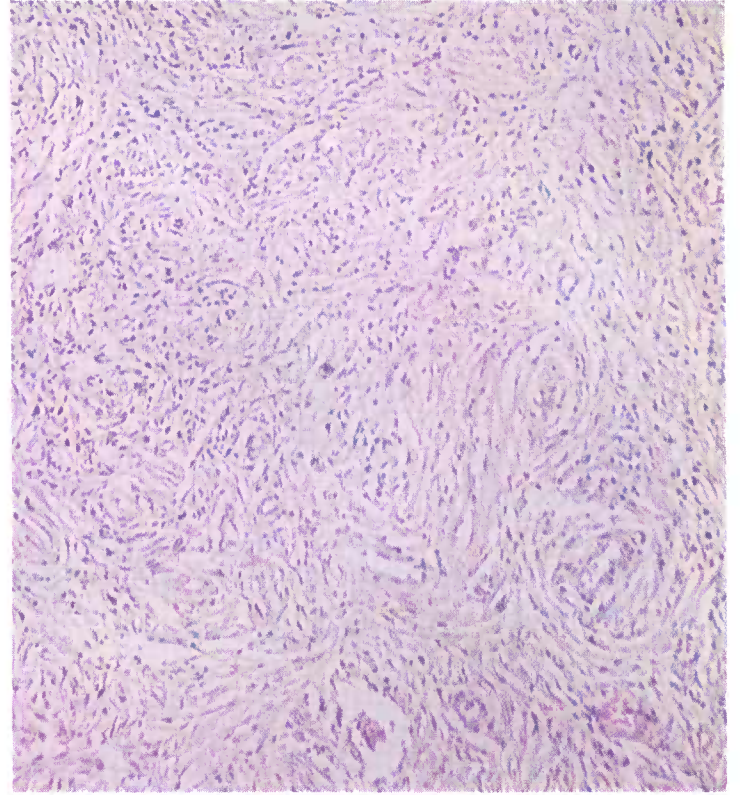


Figure 184.—A higher magnification of the fibrous zone of the auditory nerve tumor (D2177) shown in figure 182. This zone consists of spindle-shaped cells that resemble cells of a peripheral nerve Schwannoma. Hematoxylin-eosin stain.  $\times 125$ .

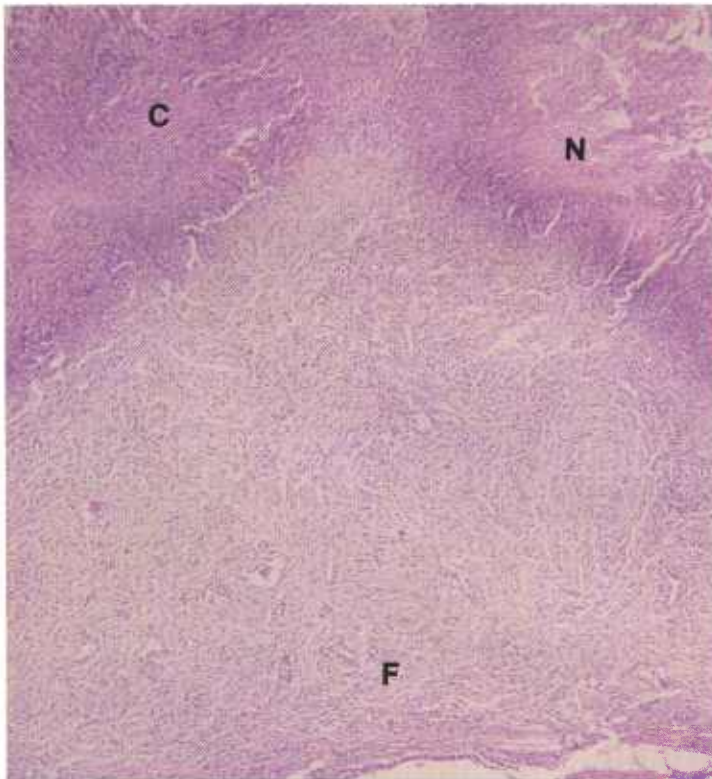


Figure 183.—A higher magnification of the auditory nerve tumor (D2177) shown in figure 182. The cellular region (C) containing areas of necrosis (N) is surrounded by a fibrous zone (F). Hematoxylin-eosin stain.  $\times 50$ .

located along the course of the auditory nerve. They are less than 5 cm. in diameter and conform to the shape of the adjacent brain and skull. These tumors are rather nodular in appearance, are usually white or yellowish orange, and may contain thin-walled cysts and hematogenous pigment. They do not invade the brain or the adjacent skull and do not metastasize to other organs. Animals affected with auditory nerve tumors have clinical signs resembling a middle ear infection or listeriosis.

**Microscopic appearance.**—The tumor consists of spindle-shaped cells resembling those of a peripheral nerve Schwannoma. Although there is a tendency toward the palisading and swirling seen in a peripheral nerve Schwannoma, the arrangement is usually not distinct enough to establish the presence of these cellular patterns. The concentric arrangement of cells with the formation of psammoma bodies seen in meningiomas is not observed in this tumor. Small cysts may be found throughout the neoplasm and hematogenous pigment may be present.

### Meningioma

**Definition.**—A meningioma is a tumor of the meninges and the type cell is the arachnoidal fibroblast.

**Distribution and incidence.**—Too few meningiomas have been described in meat-producing animals to indi-

cate geographic, generic, species, breed, or sex predominance. It is assumed that they are found in all parts of the United States and that all genera, species, breeds, and sexes are affected. Meningiomas occur most frequently in older animals. This probably explains why few tumors of this type have been found during meat inspection, since most animals slaughtered for food are young. As a group meningiomas are not as common as gliomas. Of the cattle neoplasms collected during the USDA's 2-year survey described on page 1, 0.1 percent were meningiomas. None were found in sheep, goats, and swine during the same period.

The meningioma is confined to the meninges and seldom, if ever, invades the brain, spinal cord, or adjacent skull. Metastases to other organs are rare if they occur at all. In those few instances where metastases have been reported, it is possible that the growths were other types of mesodermal tumors instead of metastases from a meningioma.

The intracranial and intraspinal location of these tumors is probably similar to their location in man. However, few have been reported in animals and no definite conclusion as to location can be made. Experience would indicate that most occur in the longitudinal and transverse fissures of the brain and in the vicinity of the olfactory lobes.

**Macroscopic appearance.**—This tumor enlarges slowly and may reach considerable size, causing pressure atrophy of the brain, spinal cord, and overlying osseous structures. Meningiomas observed in animals are usually less than 3 cm. in diameter. The meningioma is white, has an irregular or nodular surface, and is enclosed within a capsule. Its shape varies considerably in conformance with the shape of the brain, spinal cord, and osseous structures where it is located. At times the neoplasm is flattened to a thin sheet of tissue between the brain and the skull. When incised, the exposed surface has a granular appearance and may contain foci of calcification.

**Microscopic appearance.**—Three basic types of the tumor—psammomatous, meningotheliomatous, and fibroblastic—have been described. Of these, the psammomatous type is most frequently observed in animals. Its cells are arranged in whorls. In the older parts of the neoplasms, the centers of the whorls contain hyalinized bodies that enlarge concentrically in a lamellar manner and later become mineralized. These hyalinized masses are known as psammoma bodies and probably represent a cell or a group of cells undergoing degeneration.

The meningotheliomatous type of meningioma consists of large oval cells with large round nuclei and granular cytoplasm within a collagenous, partially hyalinized stroma. It has numerous blood vessels.

The fibroblastic type of meningioma consists of cells that resemble fibroblasts. A histologic examination of the entire mass usually reveals parts that are similar to the other two types—psammomatous and meningotheliomatous.

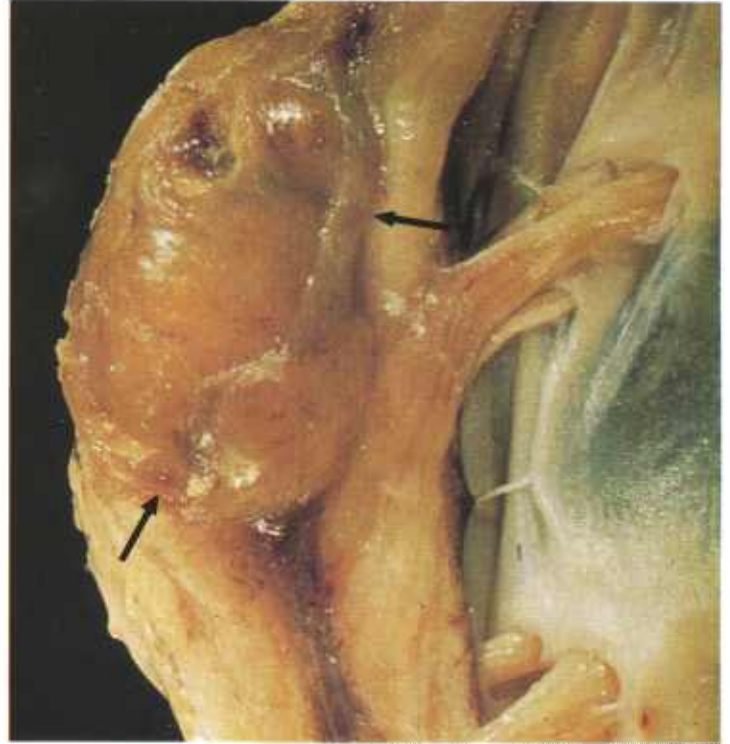


Figure 185.—Meningioma (arrows) of the spinal cord in a 6-year-old cow (A376-D3078). A soft, yellow, thinly encapsulated tumor measuring 30 by 20 by 15 mm. is attached to the meninges and is compressing the spinal cord.

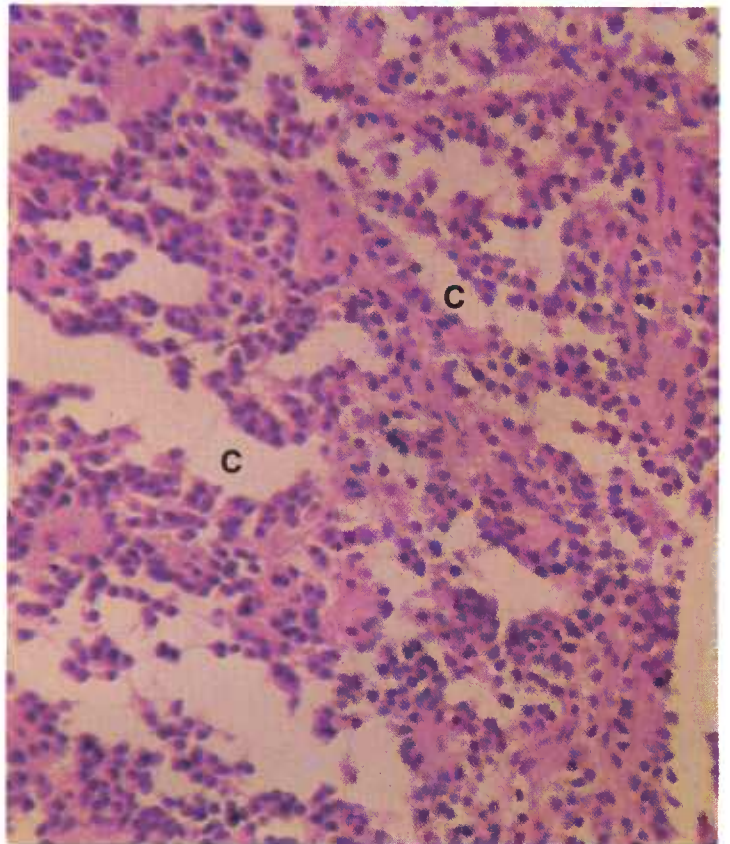


Figure 186.—A histologic preparation of the meningioma (A376-D3078) shown in figure 185. Channels (C), which often contain blood, are present. Hematoxylin-eosin stain.  $\times 320$ .

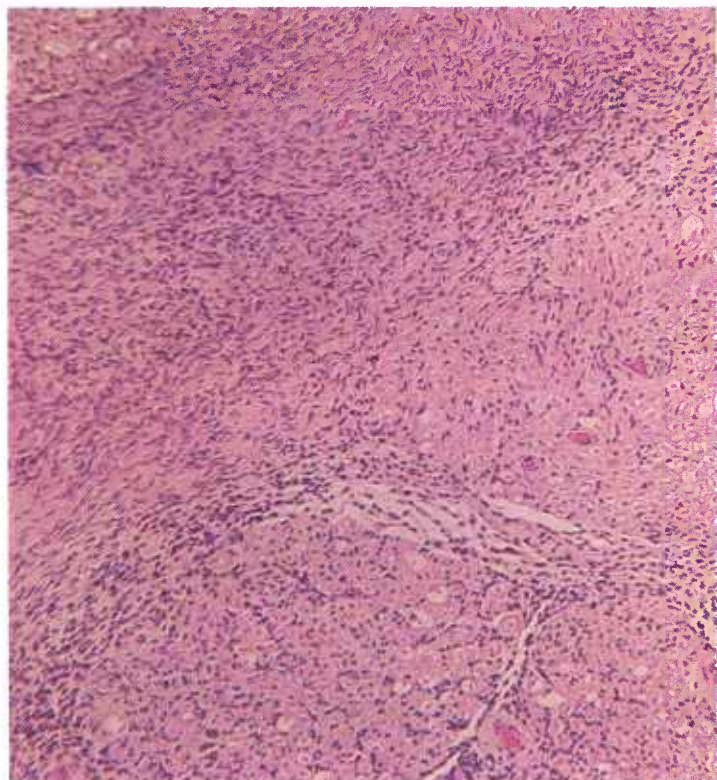


Figure 187.—A histologic preparation of the meningioma (A376-D3078) shown in figure 185. The growth is of the fibroblastic type. Hematoxylin-eosin stain.  $\times 125$ .

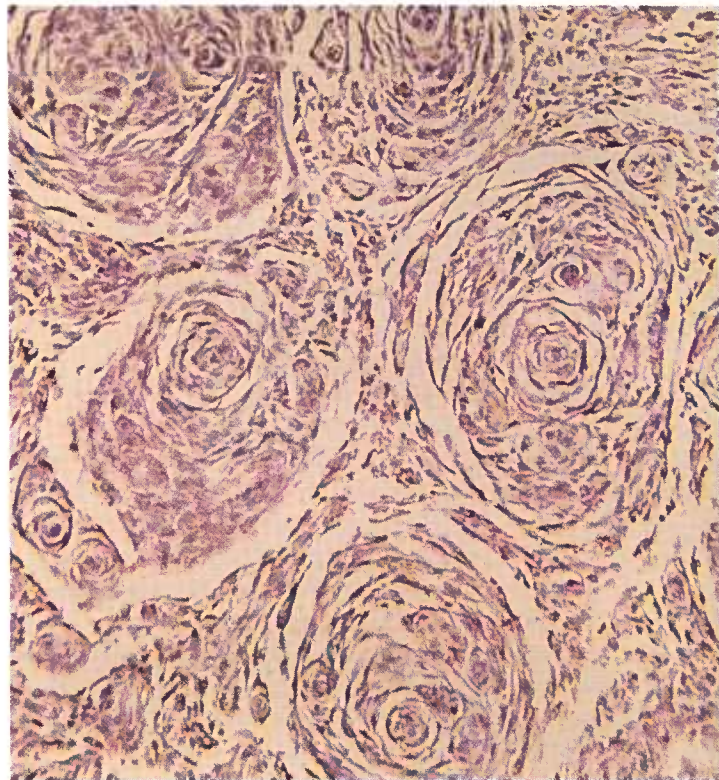


Figure 189.—A histologic preparation of a meningioma of the psammomatous type (M213) in which the neoplastic tissue is arranged in whorls. Hematoxylin-eosin stain.  $\times 125$ .

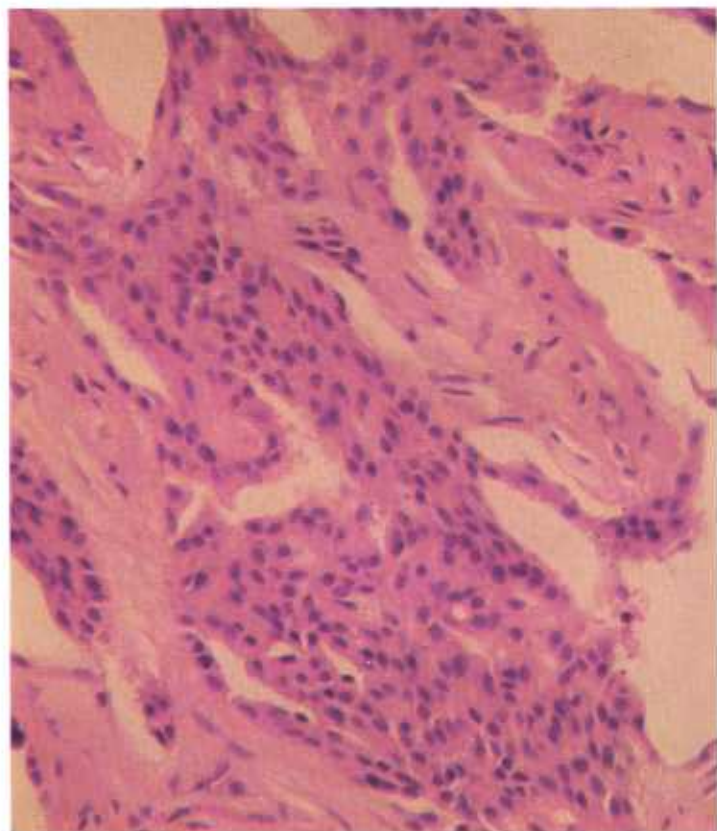


Figure 188.—A histologic preparation of the meningioma (A376-D3078) shown in figure 185. This photograph shows a part of the tumor that is composed of large oval cells of the meningotheomatous type. Hematoxylin-eosin stain.  $\times 320$ .

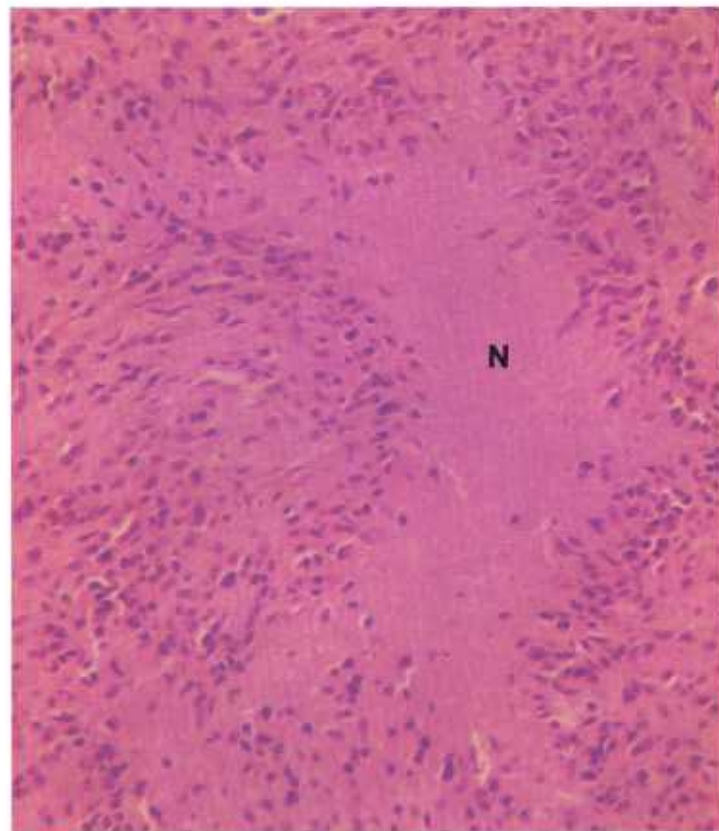


Figure 190.—A histological preparation of the meningioma (A376-D3078) shown in figure 185. An area of necrosis (N) is present in a dense cellular part of the neoplasm. Hematoxylin-eosin stain.  $\times 320$ .

## Nerve Sheath Tumor (Schwannoma)

**Definition.**—Nerve sheath tumors (Schwannomas) are composed of cells arising from the sheath of Schwann of the peripheral nerves.

**Distribution and incidence.**—Nerve sheath tumors are found in meat-producing animals throughout the United States and are most frequently observed in cattle. They are uncommon in other domesticated animals. No breed, age, or sex predominance has been established. During the USDA's 2-year survey mentioned on page 1, 4.8 percent of the bovine tumors collected were of this type but none were found in swine and sheep.

Nerve sheath tumors arise from the sheath of Schwann and are most frequently observed in the heart brachial plexus and coeliac plexus, and in the intercostal nerves. In most instances, except where the heart or the mediastinum is involved, the tumors are found adjacent to or incorporated in one or more nerves, ganglia, or plexuses. Careful dissection is necessary if the association of the neoplasms with nerves is to be demonstrated. Nerve sheath tumors are usually found in several locations within the animals, an indication that they are multicentric. They are usually benign and involve animals of all age groups. Because of their slow growth, small lesions in young animals are generally overlooked.

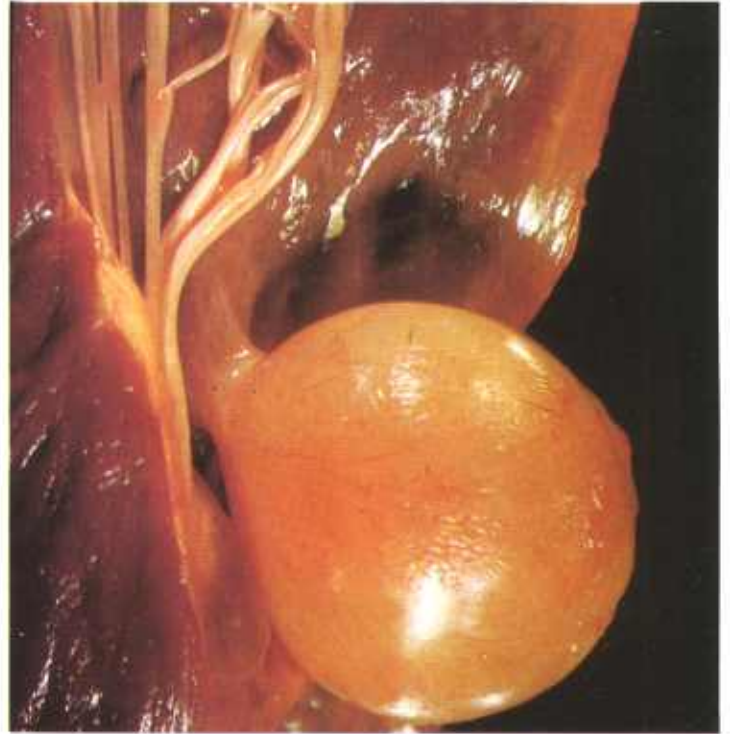


Figure 192.—A yellow, pedunculated nerve sheath tumor measuring 43 by 40 by 28 mm. A stalk measuring 7 mm. in diameter attached the growth to the endocardium and myocardium of the left ventricle in an old Hereford cow (A349-D2874).

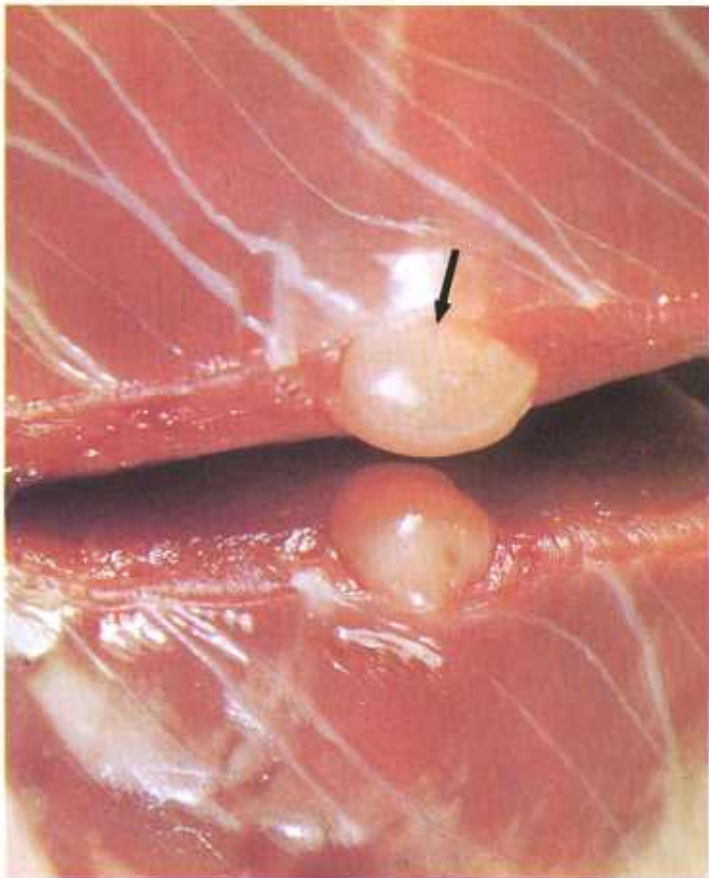


Figure 191.—Cross section of a nerve sheath tumor (arrow) in the heart of an 8-year-old cow (A75-D1394). A soft, yellow tumor that measures 2 cm. in diameter is present in the myocardium.

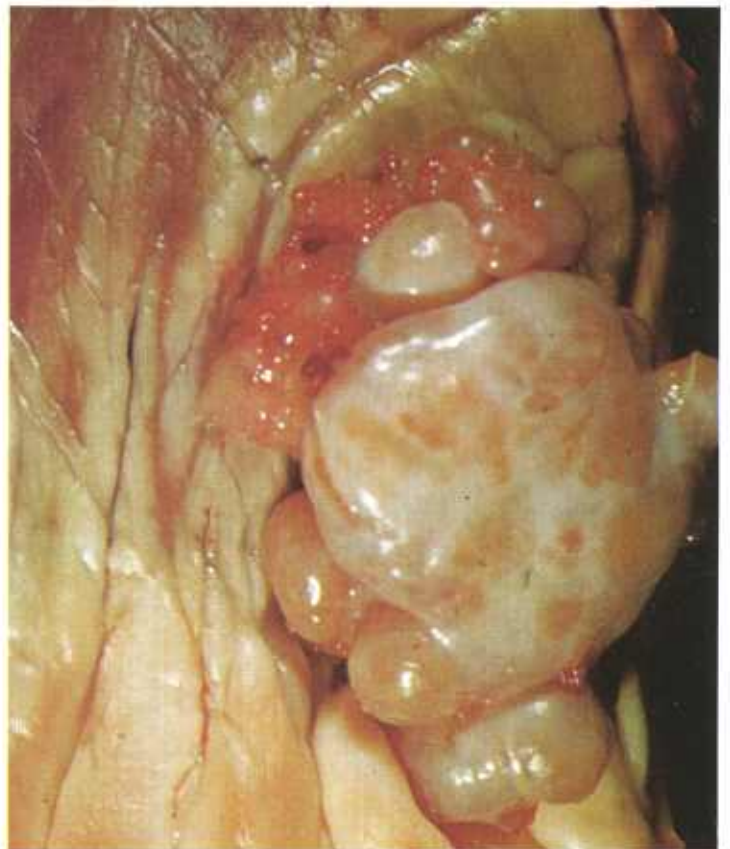


Figure 193.—A lobulated, encapsulated nerve sheath tumor measuring 50 by 35 by 12 mm. is protruding from the epicardium and myocardium of the right ventricle in a 6-year-old cow (D2700).

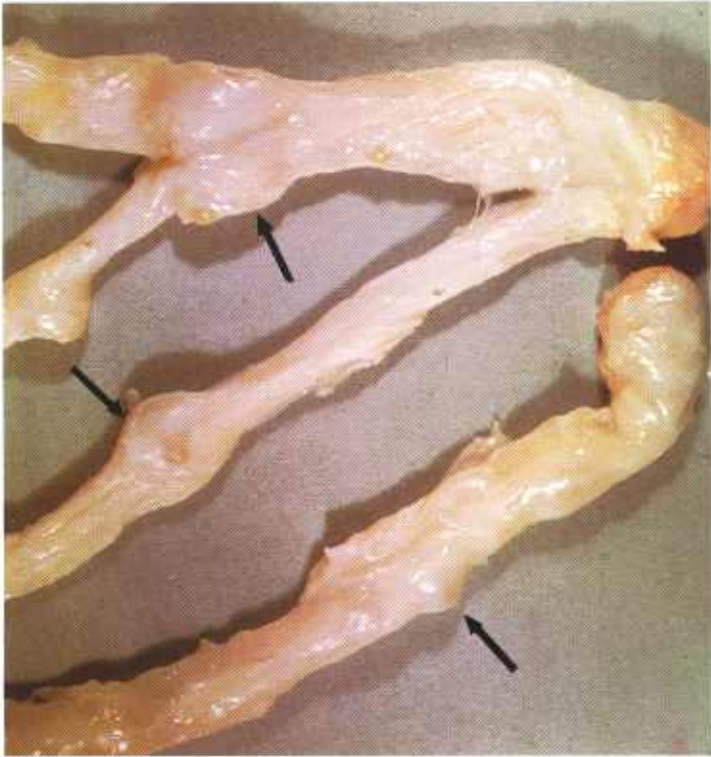


Figure 194.—Nerve sheath tumors involving the brachial plexus of an 8-year-old cow (A75-D1394). Multiple tumors (arrows) are present within the nerves.

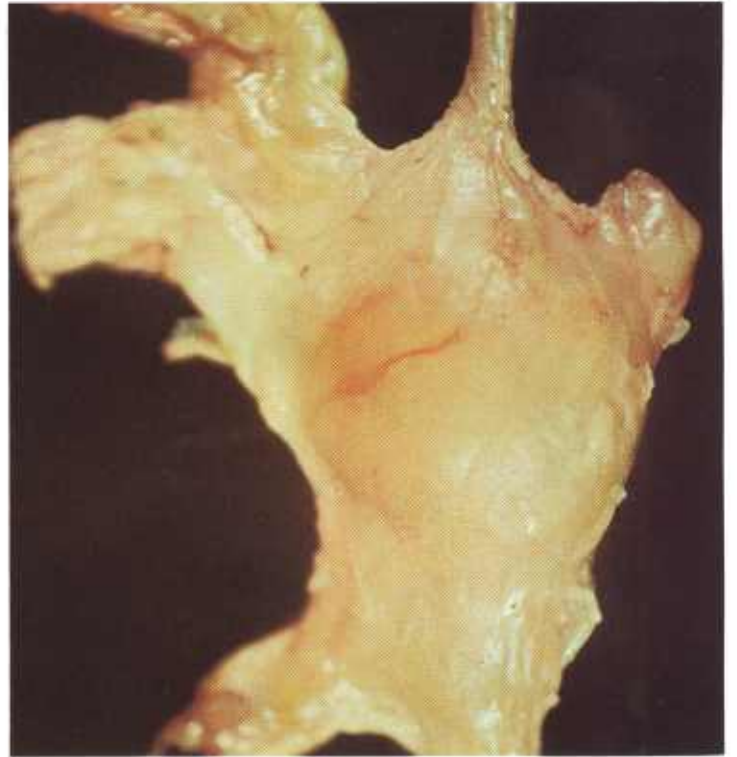

Figure 196.—A nerve sheath tumor of the first thoracic ganglion with plexiform tumefaction of the nerves communicating with the ganglion in an old Hereford cow (A308-D2731A).

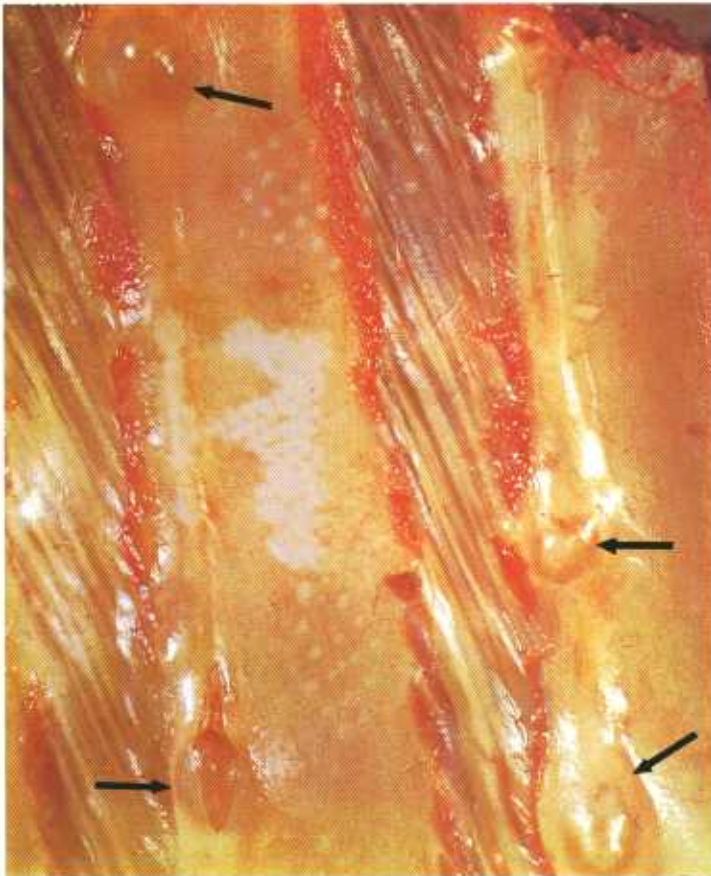


Figure 195.—Nerve sheath tumors involving the intercostal nerves of an 8-year-old cow (A75-D1394). Multiple tumors (arrows) are present within the intercostal nerves.

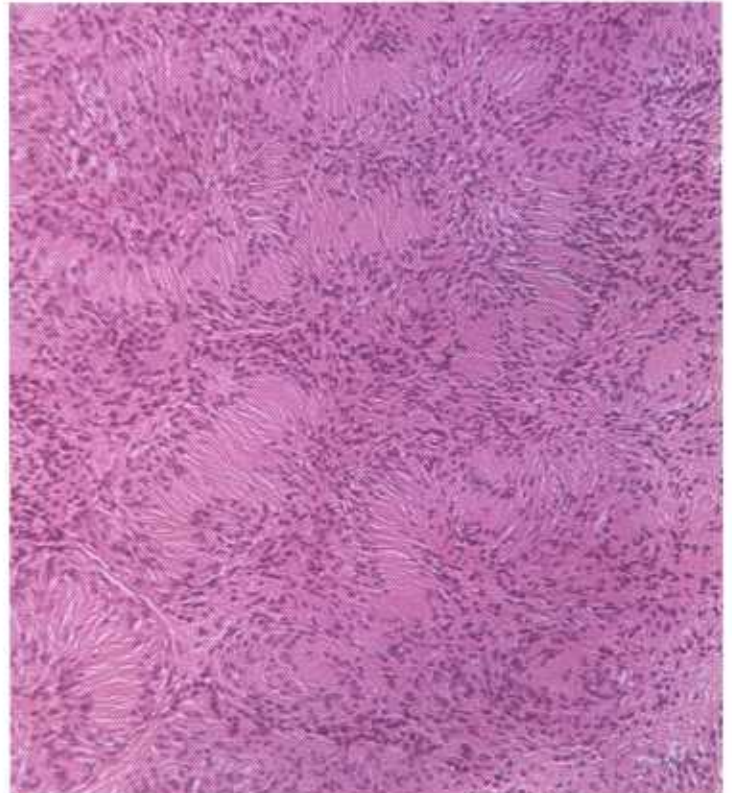


Figure 197.—Histologic preparation of a nerve sheath tumor of an intercostal nerve in a cow (14675). The Schwann's cells have the characteristic arrangement of this type of neoplasm with palisading nuclei and the whorled appearance of Antoni type-A tissue. Note the parallel arrangement of intercellular fibers between Schwann's cells. Hematoxylin-eosin stain.  $\times 125$ .

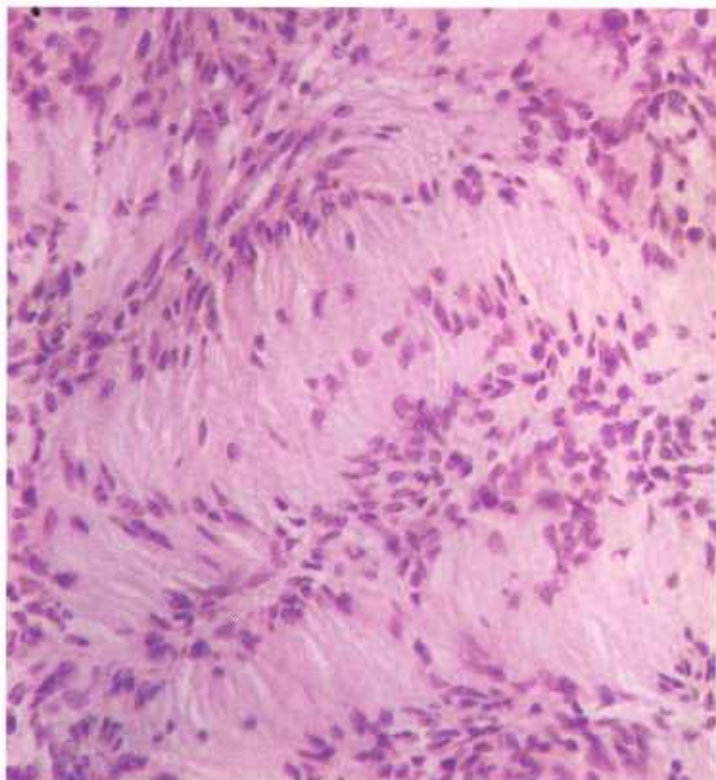


Figure 198.—A higher magnification of the nerve sheath tumor (14675) shown in figure 197. Hematoxylin-eosin stain.  $\times 320$ .

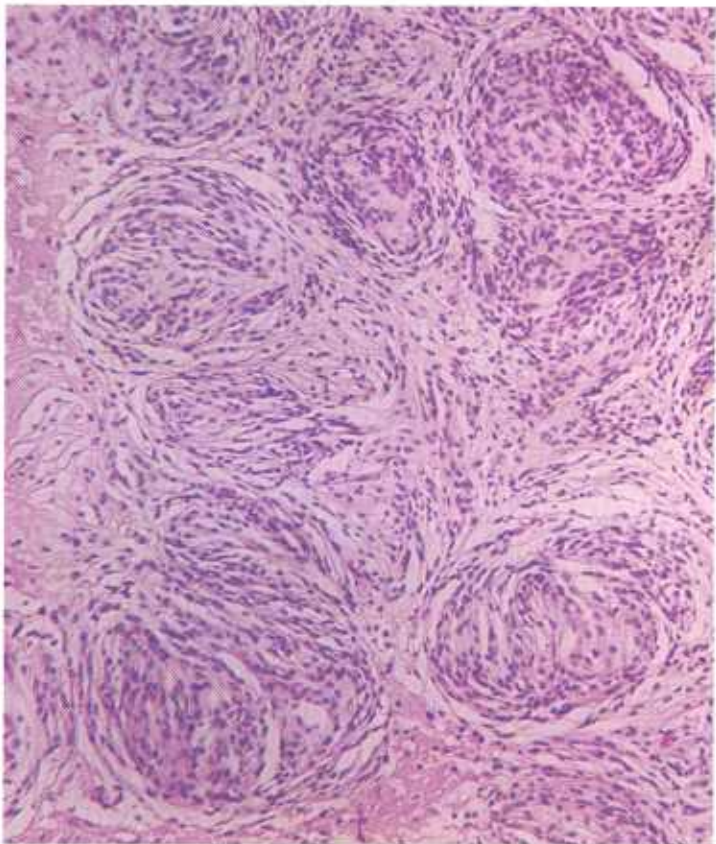


Figure 199.—Histologic preparation of the nerve sheath tumor (A75-D1394) shown in figure 195. The tumor has the characteristic palisading and whorled pattern shown in figure 197, but the arrangement is more focal in distribution. Hematoxylin-eosin stain.  $\times 125$ .

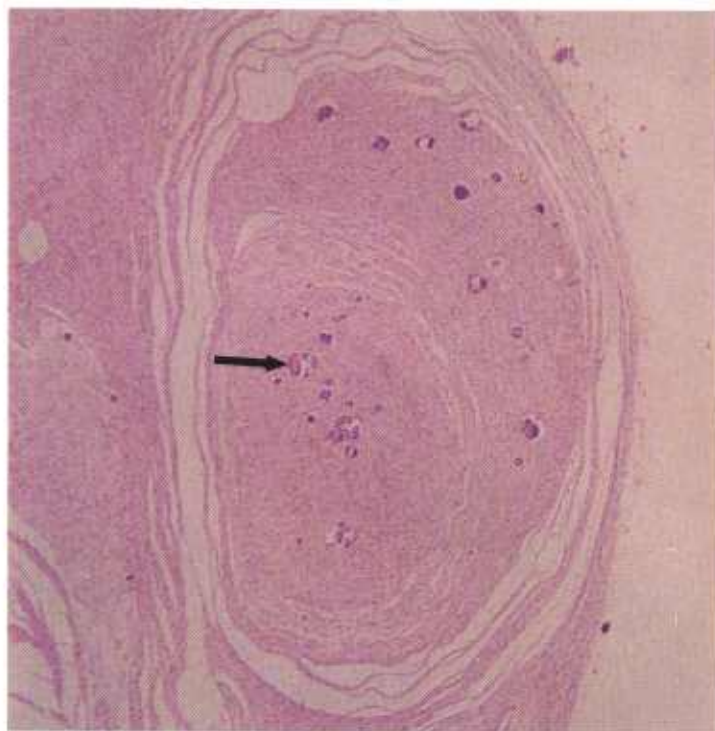


Figure 200.—Nerve sheath tumor of a spinal nerve in a cow (M1953). The tumor has a concentric arrangement and multiple foci of calcification (arrow) are present. Hematoxylin-eosin stain  $\times 30$ .

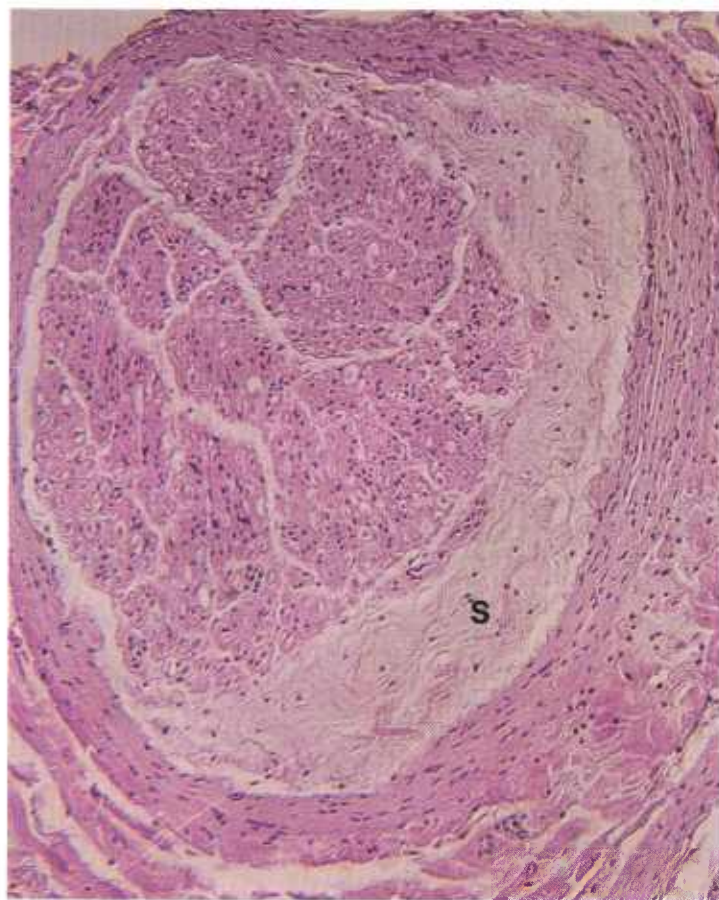


Figure 201.—Loosely arranged Schwann's cells (S) separate the perineurium from the epineurium of a nerve of the brachial plexus in a cow (17518). Hematoxylin-eosin stain.  $\times 125$ .

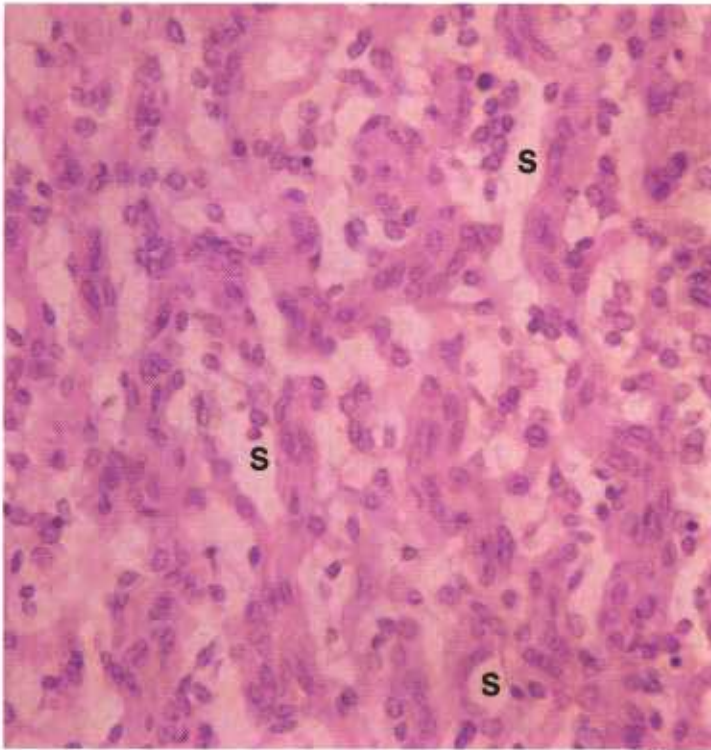


Figure 202.—Nerve sheath tumor in a 10-year-old Angus cow (D2863). Many small cystic spaces (S) are present between the Schwann's cells. Hematoxylin-eosin stain.  $\times 320$ .

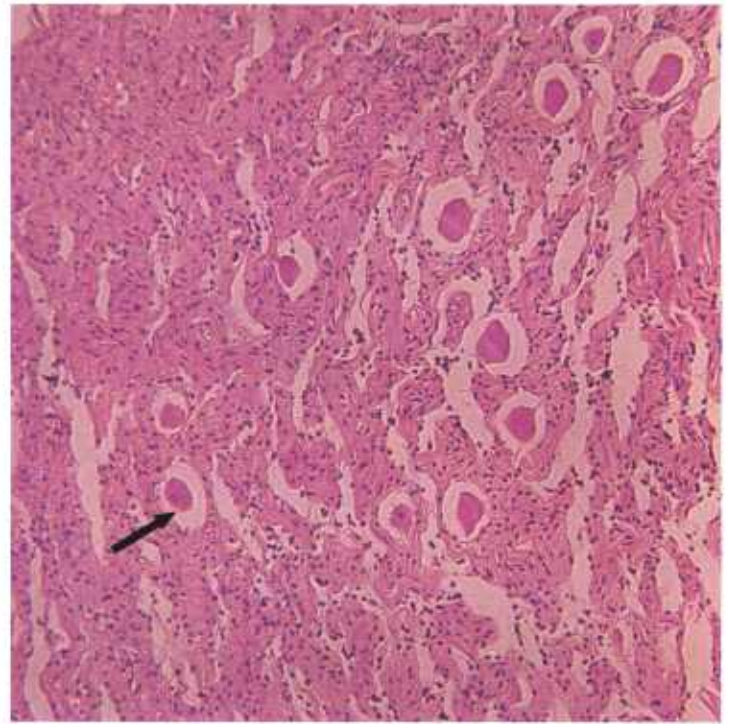


Figure 204.—Nerve sheath tumor of the cervicothoracic ganglion of a 6-year-old cow (D1829). Tumor tissue is infiltrating between the ganglion cells (arrow). Hematoxylin-eosin stain.  $\times 125$ .

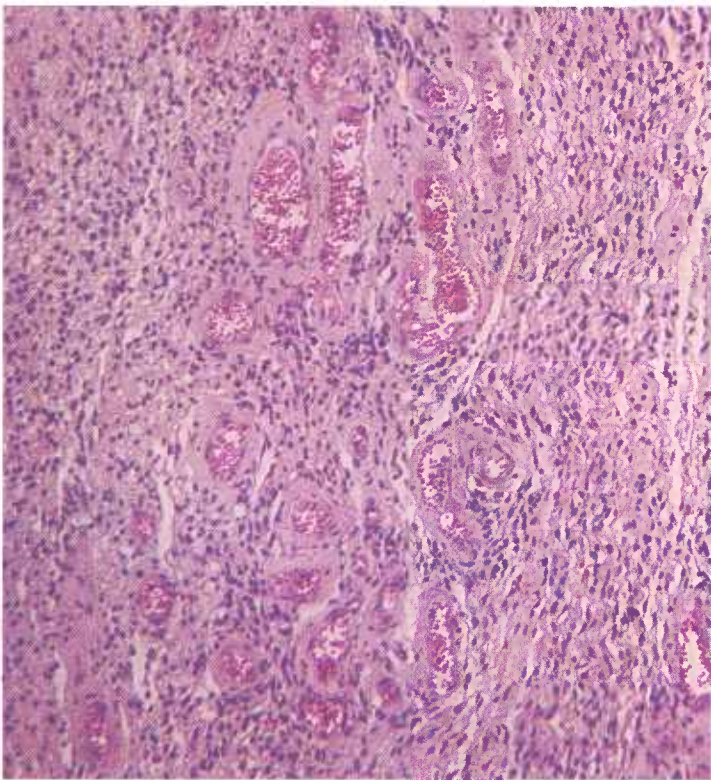


Figure 203.—Nerve sheath tumor in the heart of a 9-year-old cow (D345). The heart lesion is composed of loosely arranged Schwann's cells and blood vessels with thick collagen sheaths. Because the characteristic palisading and whorling of this tumor is lacking, the observer must rely on the morphology of individual cells in completing his diagnosis. Hematoxylin-eosin stain.  $\times 125$ .

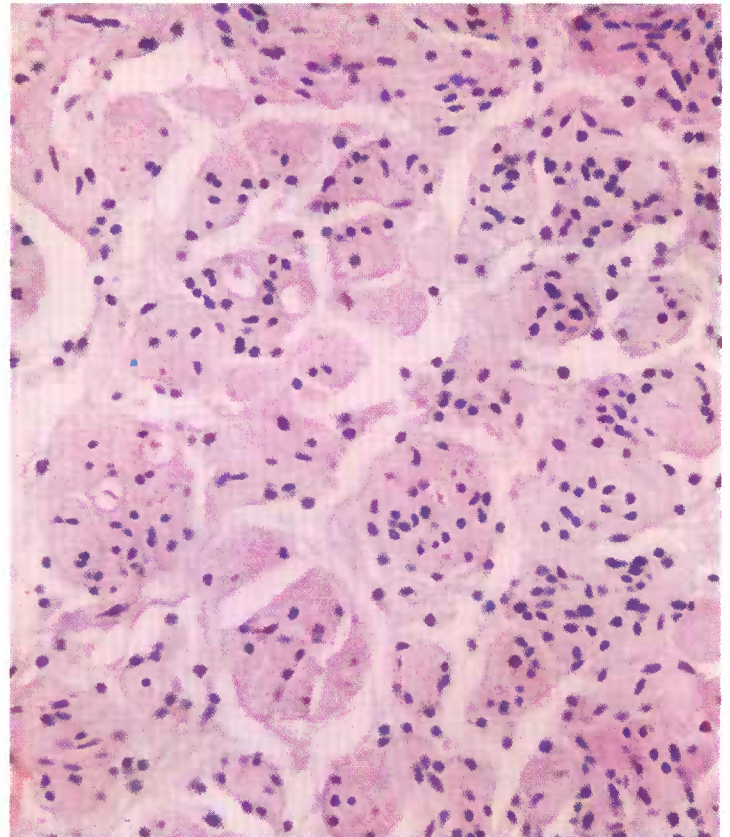


Figure 205.—Nerve sheath tumor of the brachial plexus of a cow (17518). Schwann's cells are proliferating within a nerve of the brachial plexus. Although the tumor cells are growing in clumps, the characteristic palisading and whorling are not present in this photograph. Hematoxylin-eosin stain.  $\times 320$ .

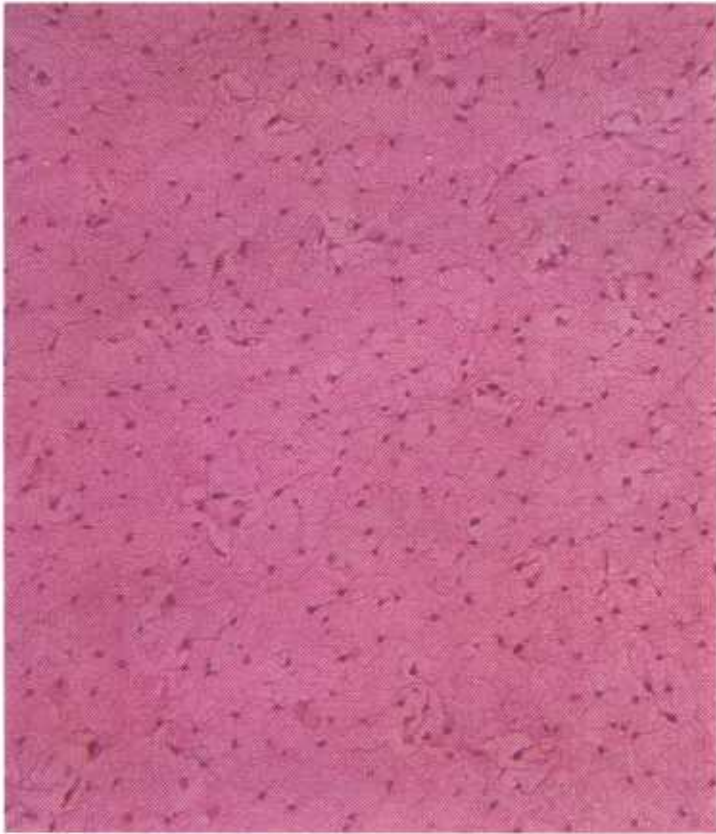

Figure 206.—Nerve sheath tumor in a 10-year-old Angus cow (D2863). The tumor has the appearance of brain tissue. The palisading and whorling, characteristic of this neoplasm, are not present in this photograph. Hematoxylin-eosin stain.  $\times 125$ .

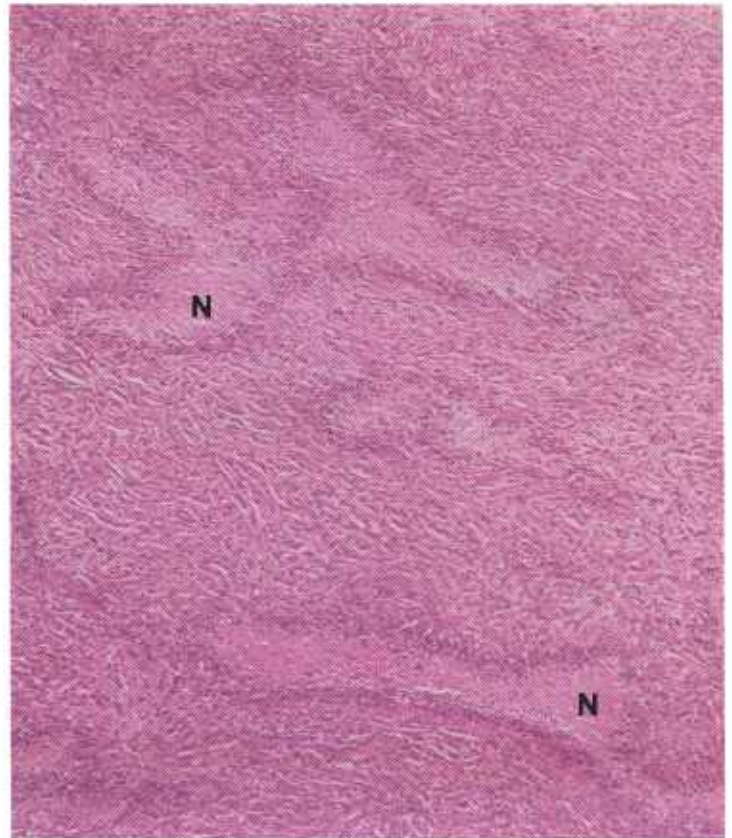


Figure 207.—Nerve sheath tumor in a spinal nerve of a cow (M1953). Multiple areas of coagulative necrosis (N) are frequently present in this type of neoplasm. Hematoxylin-eosin stain.  $\times 50$ .

By the time they are recognized, the tumors are large and the animal is in an older age group.

In abattoir specimens, the highest incidence of the neoplasm is found in the heart. However, in routine meat inspection a thorough examination of the heart for tapeworm cysts is made, and it is quite likely that a higher incidence in other organs would be found if they were subjected to a similar examination. The literature indicates the highest incidence in European cattle is found in the brachial plexus. It is assumed that a similar high incidence of Schwannomas occurs in the brachial plexuses of cattle in the United States, but the difficulty experienced in examining the brachial plexuses of dressed carcasses precludes the confirmation of this assumption.

Nerve sheath tumors seldom cause the death of the animal although they may impair the functional capacity of affected nerves. The debility seen in some cattle with involvement of several nerves is undoubtedly related to the disease. The involvement of a major nerve of the brachial plexus may interfere with locomotion. A protrusion of enlarged spinal nerves through intervertebral foramina will cause compression of the spinal cord and posterior paralysis. It is certain that many cases are never diagnosed and that affected animals either die from the disease or are sent to slaughter when they are observed to be in poor health.

**Macroscopic appearance.**—Nerve sheath tumors are frequently bilateral and are easily recognized by the extensive involvement of one or more nerves. The involved nerve is uniformly enlarged or has nodular masses within it. Affected areas are shiny or glistening and are either white or gray. They are often lobulated and slightly gelatinous, and at times they contain areas of degeneration, necrosis, and hemorrhage.

**Microscopic appearance.**—Tumor cells derived from the sheath of Schwann are elongated and spindle-shaped with oval or long cylindrical nuclei. Each cell tends to parallel itself with another, an arrangement that is called palisading. Distinct palisading is found in each tumor, and equally distinct is the alignment of cells in interlacing fasciculi and whorls. In loosely arranged tumors, the intercellular fibers resemble a fine reticulum. In the more solid or compactly organized tumors, connective tissue collagen is present. The orderly arrangement of the cells in parallel bundles, the interlacing fibers, and the whorling of cells and fibers into structures resembling Meissner's corpuscles is characteristic of nerve sheath tumors. Since palisading of cells also occurs in connective tissue tumors, nerve sheath tumors and connective tissue tumors are often mistaken for each other. Therefore, it is most important to consider the location of the neoplasm and its relation to a nerve before classifying it.

## Miscellaneous Tumors

### Embryonal Sarcoma of the Vagina of Swine

**Definition.**—Embryonal sarcoma of the vagina is a mesenchymal cell tumor of young female swine.

**Distribution and incidence.**—This condition is so infrequently encountered that no information is available as to its incidence and geographic distribution. It is assumed that it occurs throughout the United States. The disease has only been observed in swine under 1 year of age. No breed predominance has been established. The affected gilts are of normal market size and show no indication of an endocrinological disturbance.

These tumors bear some resemblance to the “grape-like” or “botryoid” sarcomas of the vagina of children and young adults. It is interesting to note that muscle cells with cross striations are sometimes described as being components of human sarcomas of the vagina. No striated muscle elements have been observed in the porcine tumors.

**Macroscopic appearance.**—The distal tubular part of the genital tract is greatly enlarged. The vulva is nor-

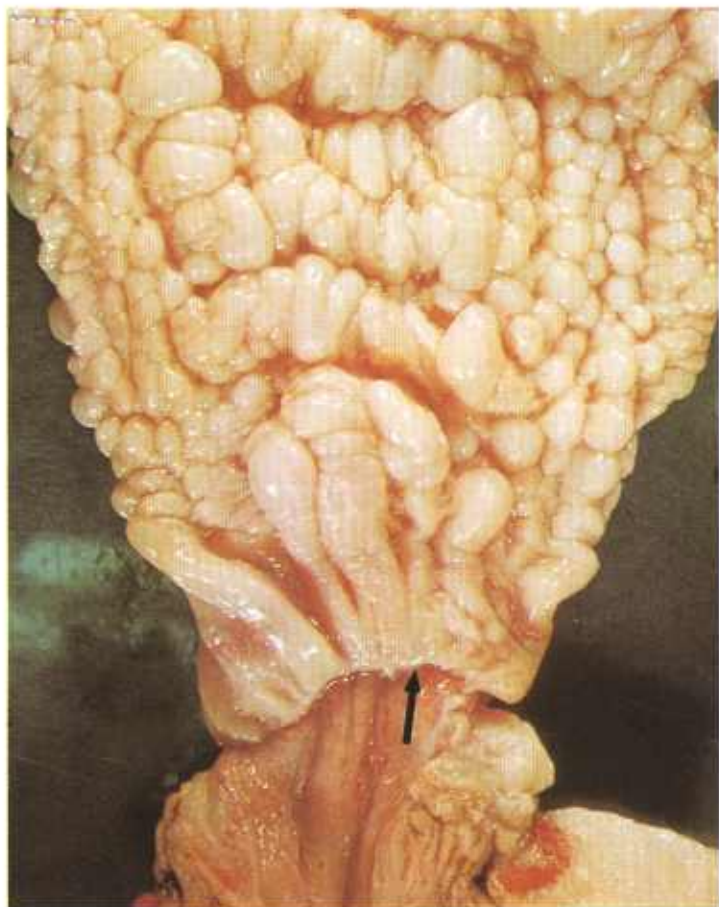


Figure 208.—Embryonal sarcoma of the vagina in a 6-month-old gilt (A409-D3094). Note the rounded protruberances that are present in the tumefied mucosa. The arrow indicates the junction between the tumefied vagina and the normal vulva.

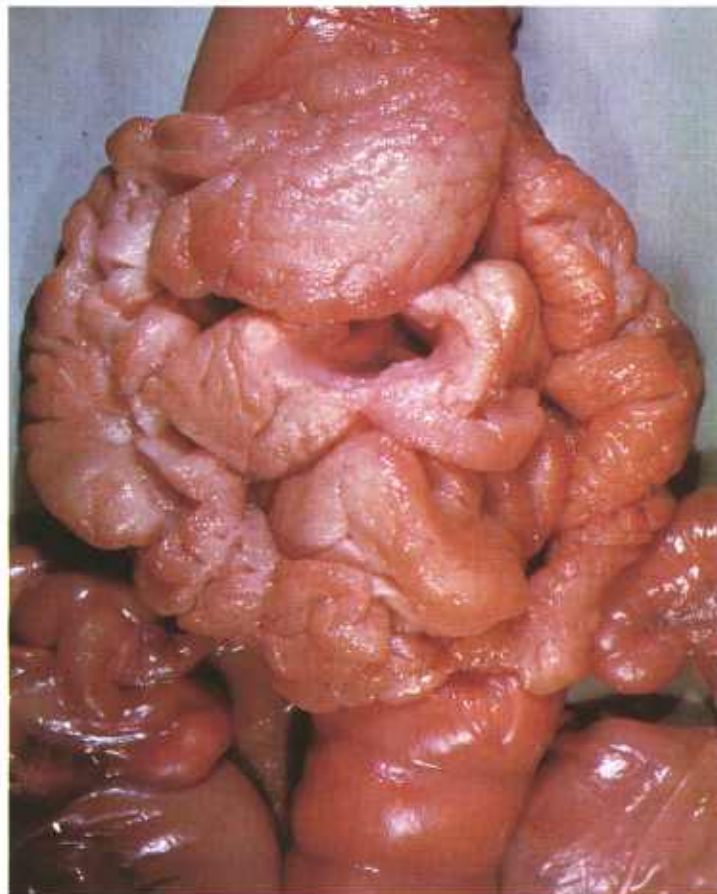


Figure 209.—Embryonal sarcoma of the body of the uterus of an adult sow (A113-D1468). Note the rounded protruberances that are present in the tumefied uterine mucosa.

mal but the vagina, cervix, and body of the uterus are merged into a continuous single, enlarged, hyperplastic structure measuring about 45 cm. in length and 15 cm. around the greatest circumference of the vagina.

The mucosa is arranged externally into rounded or annular folds that often project 2 or 3 cm. but retain some resemblance to the normal linear and annular folds of the porcine vagina. Submucosal and muscular layers are noticeably increased in thickness with either prominent firm, gray, and fibrous tissue or soft and mucinoid tissue replacing the normally loose submucosal tissues. The uterine horns and ovaries are normal.

**Microscopic appearance.**—The bulky folds of the tumefied vagina are produced by a proliferation of mesenchymal cells in an edematous, vascular, and fibrous connective tissue stroma. The overlying epithelium is intact and shows no neoplastic alterations. The growth involves the vagina, cervix, and body of the uterus but not the vulva or uterine horns.

Hyperplastic changes are seen in the internal iliac, sublumbar, and rectal lymph nodes. No metastases have occurred in the regional lymph nodes or other organs.

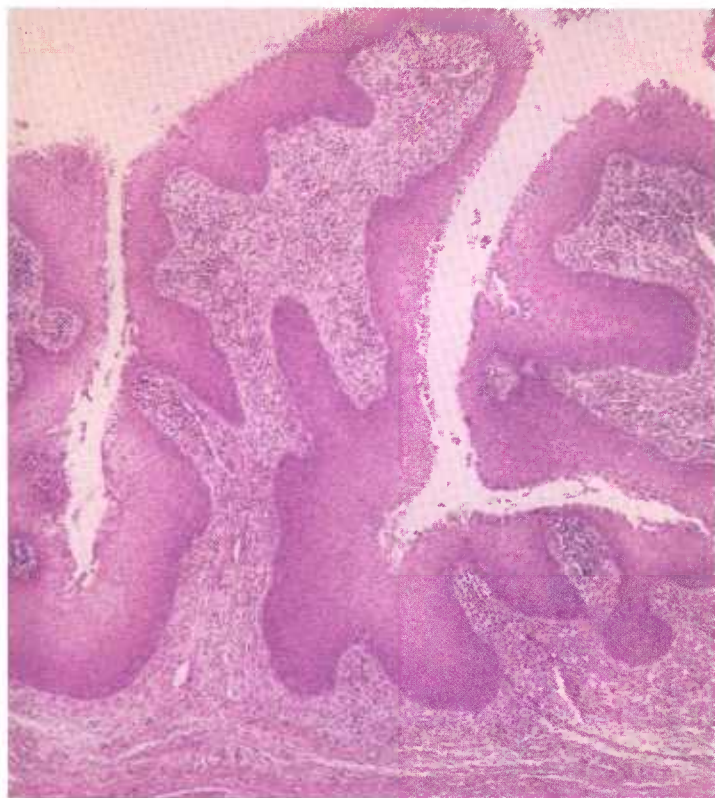

Figure 210.—Embryonal sarcoma of the vagina of an adult sow (113-D1468). The protuberances projecting into the lumen of the vagina consist of proliferating connective tissue covered by hyperplastic epithelium. Hematoxylin-eosin stain.  $\times 50$ .

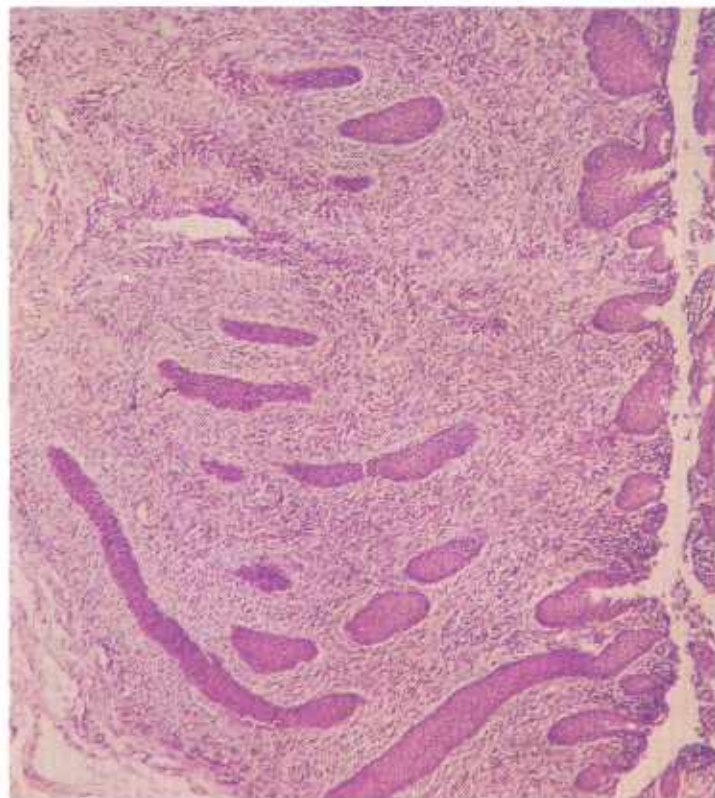


Figure 211.—Histologic preparation of the embryonal sarcoma (A409-D3094) shown in figure 208. The tumefied epithelium consists of proliferating connective tissue and hyperplastic epithelium. Hematoxylin-eosin stain.  $\times 50$ .

## Melanoma and Malignant Melanoma

**Definition.**—A melanoma is a benign tumor composed of melanoblasts. A malignant melanoma is composed of anaplastic melanoblasts.

**Distribution and incidence.**—Melanomas and malignant melanomas are found in meat-producing animals throughout the United States. Melanotic tumors are most frequently observed in swine between 6 and 12 months of age; in cattle and horses they occur in older animals. During the USDA's 2-year survey of neoplasms found in Denver abattoirs (see p. 1), 0.2 percent (0.1 percent melanomas and 0.1 percent malignant melanomas) of the cattle tumors and 11 percent (all melanomas) of the porcine tumors collected were identified as melanotic types. None were found in sheep. Only five malignant melanomas of swine have been collected at the Denver laboratory over a period of 22 years; therefore, malignant porcine melanomas are evidently uncommon.

Melanotic tumors in cattle are not confined to any particular tissue or organ. There is reason to believe that they are more common in cattle with lightly pigmented skin. White or gray horses are more frequently

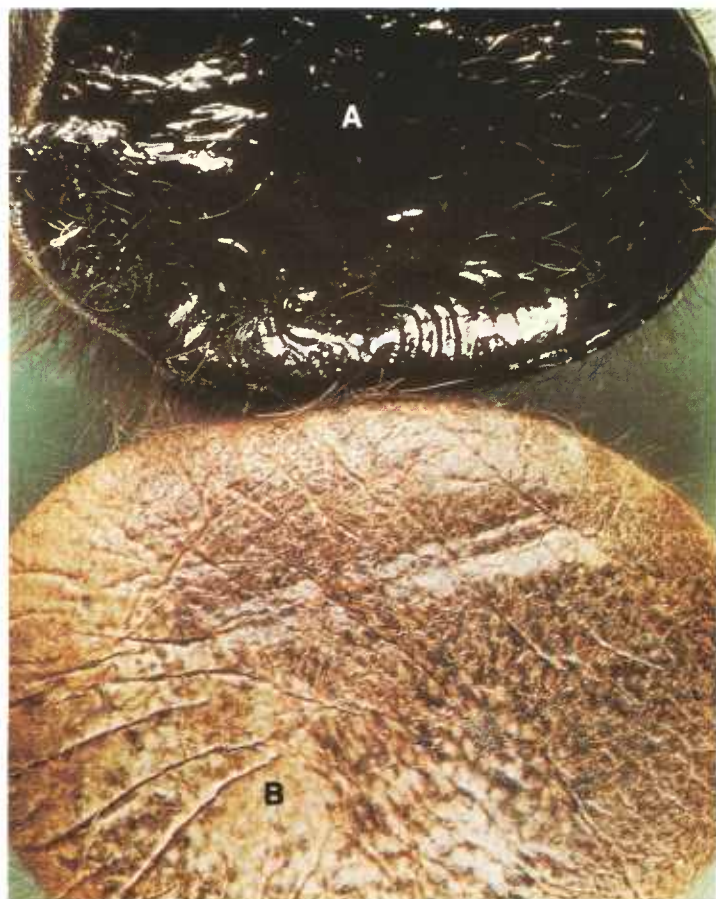

Figure 212.—A melanoma of the skin of the right forearm in a 2-year-old Hereford cow (A413-D3162). The tumor has been incised to reveal the black internal structure (A) and the skin surface (B).

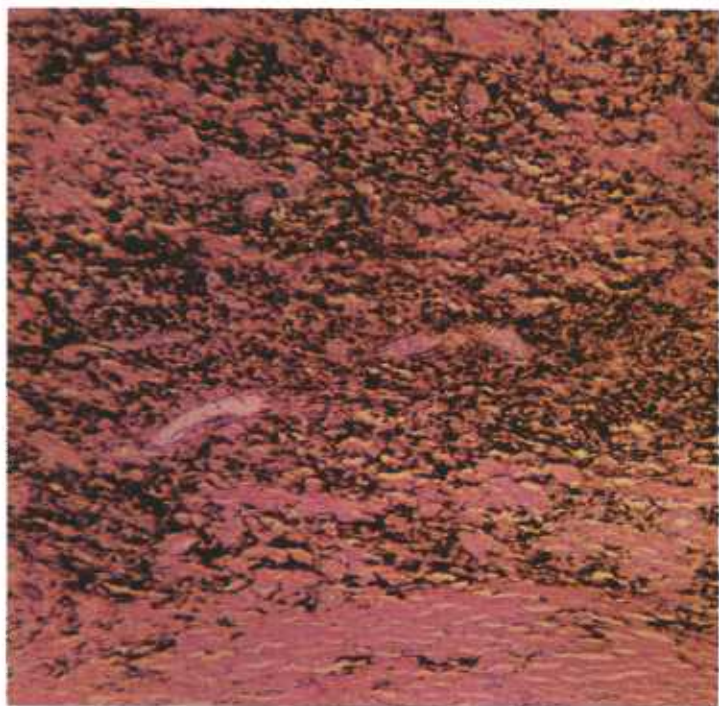

Figure 213.—Histologic preparation of the melanoma (A413-D3162) shown in figure 212. The dark-brown infiltration consists of pigmented tumor cells. Hematoxylin-eosin stain.  $\times 50$ .

affected than black or brown ones, and in older horses, the common primary sites are the ventral surface of the tail, the rectoanal area, the perineum, and the external genitalia. In swine, the tumors are usually solitary and involve the skin of the jowls and the flanks, and the anterolateral surface of the hind legs.

Melanomas and malignant melanomas are a problem in the packing industry because the pigment melanin contained within the tumor stains any tissue with which it comes in contact. This necessitates much trimming of affected carcasses or other carcasses on the line that have been contaminated by the neoplasm.

**Macroscopic appearance.**—The most prominent gross characteristic of melanotic tumors is their brown, black, or gray color. The intensity of pigmentation depends on the amount of melanin contained within the tumor. Occasional tumors, particularly those that are exceedingly malignant, will contain little—and at times no—pigment. In size they may be scarcely visible or they may measure as much as 60 centimeters in diameter. These tumors may vary in weight from a few milligrams to as much as 20 kilograms and even more. The shape of melanotic tumors also varies. Most equine and bovine tumors are roughly globular and, when located in the skin, protrude as nodules. In swine, tumors of the skin are more flattened and irregular and have a wart-like appearance, even though they are usually distinctly raised. Thus they contrast with the frequently encountered areas of melanosis that are nonelevated but that may expand the epithelium. Melanotic tumors may be extremely soft or encephaloid, or they may be dense and firm in accordance with the amount of connective

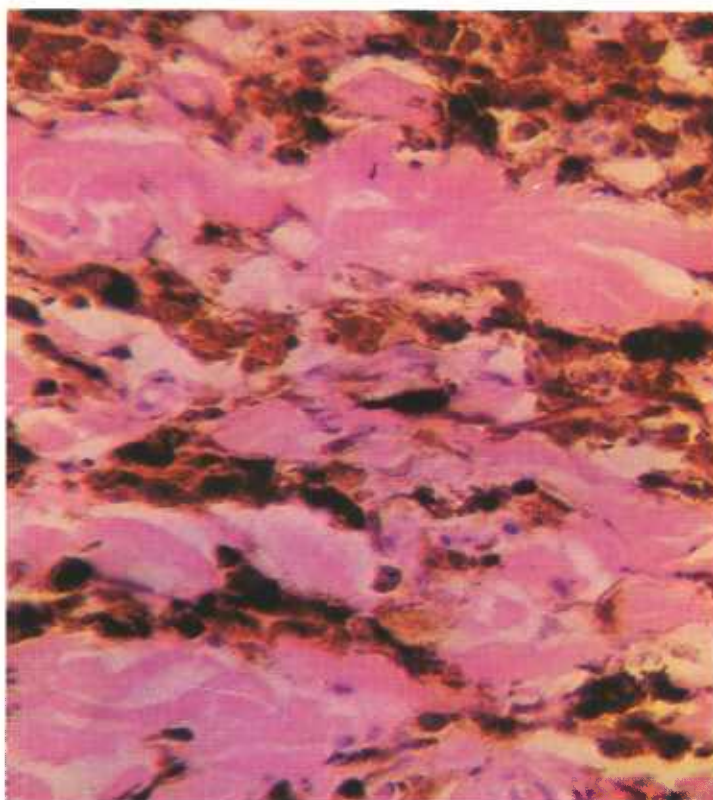


Figure 214.—A higher magnification of the histologic preparation of the melanoma (A413-D3162) shown in figure 213. Note the individual granules of pigment, which are dark brown and regular in size and shape, mask the histologic appearance of the tumor cells. Hematoxylin-eosin stain.  $\times 320$ .

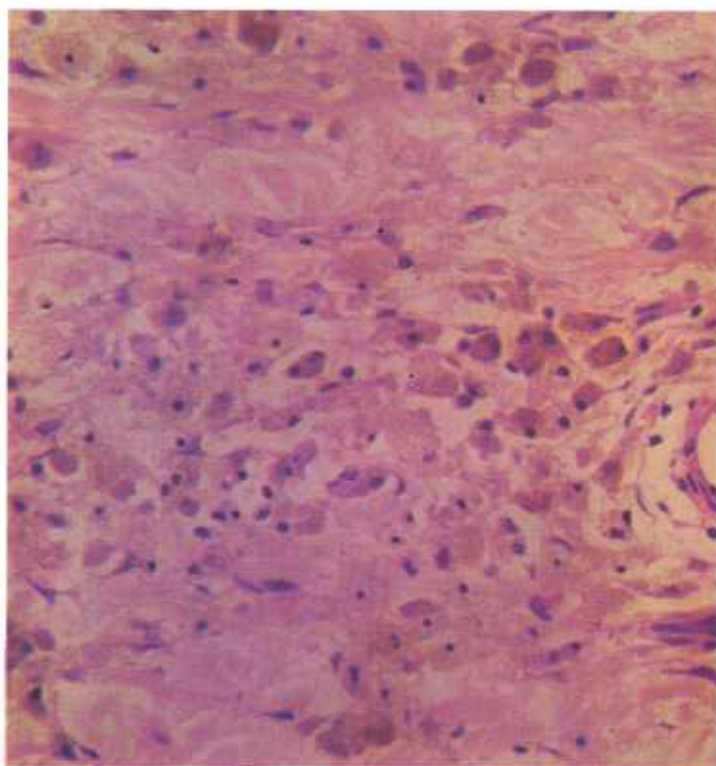


Figure 215.—A bleached histologic preparation of the melanoma (A413-D3162) shown in figures 213 and 214. The cytologic structure of the tumor cells becomes visible when the pigment is removed by bleaching. Hematoxylin-eosin stain.  $\times 320$ .

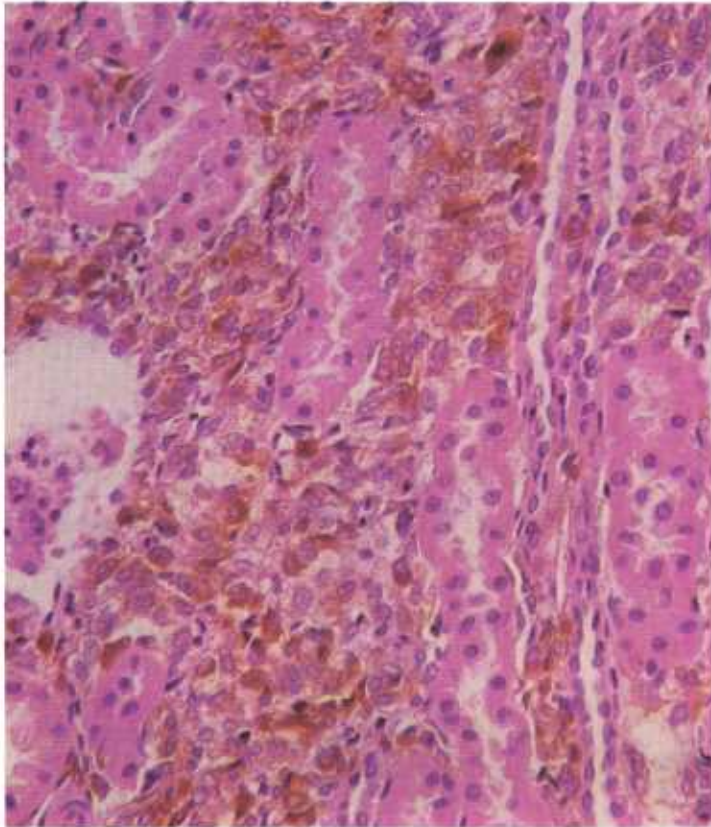


Figure 216.—Melanosarcoma of the kidney of a 6-month-old Shropshire female lamb (D2404). The tumor cells have larger nuclei and their cytoplasm contains less pigment than the cells in the melanoma shown in figure 214. Hematoxylin-eosin stain.  $\times 320$ .

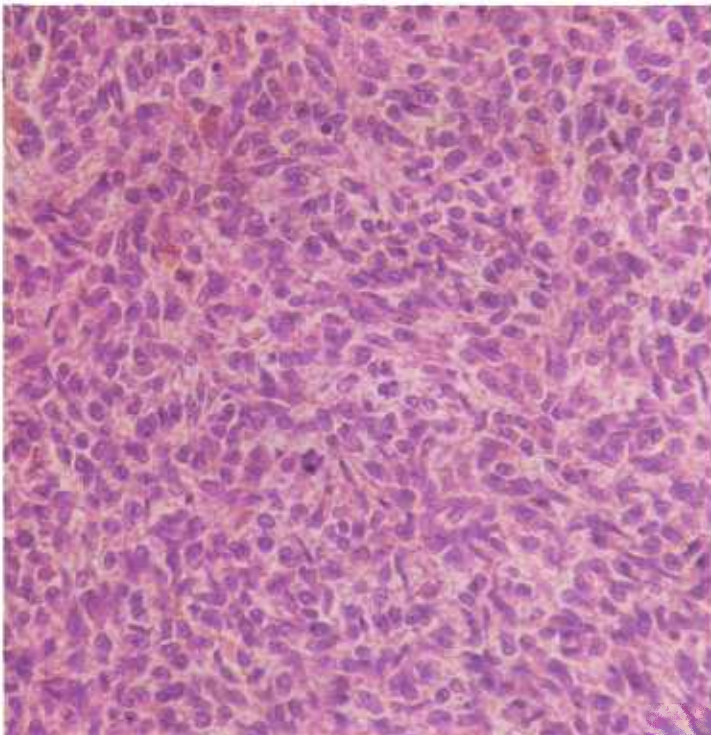


Figure 217.—Melanosarcoma of the liver of a 6-month-old Shropshire female lamb (D2404). Very little melanin is present in the rapidly growing neoplastic cells. Hematoxylin-eosin stain.  $\times 320$ .

tissue and necrosis present. Tumors involving the skin frequently contain cutaneous ulcers. Malignant melanomas tend to metastasize throughout the animal.

**Microscopic appearance.**—The tumors consist of masses of melanoblasts filled with the brown pigment melanin. These melanoblasts are irregularly round, spindle-shaped, or stellate cells. If the cells are filled with pigment, their internal structure cannot be determined. The focal accumulation of pigment within a tissue or organ does, however, indicate that the pigment is enclosed within a cell. If it becomes necessary to determine the morphology of the pigment-containing cell, the melanin may be removed by bleaching.

Neoplastic cells of malignant melanomas have large nuclei and nucleoli, contain many mitotic figures, and stain more intensely with hematoxylin than normal. Pigment within the cells consists of multiple small, dirty-brown granules that are regular in both size and shape. The degree of invasiveness and the varying amount of connective tissue and necrosis help to explain the great variation in the appearance of the tumors when they are examined macroscopically.

Macrophages within lymph nodes that drain areas where melanosis or melanomas are present frequently contain melanotic pigment. These pigment-laden macrophages may be confused with metastatic melanoblasts unless the cytologic characteristics of the cell are determined. The presence of melanin alone in a regional lymph node does not indicate metastasis from a melanotic tumor.

## Mesothelioma

**Definition.**—A mesothelioma is a tumor arising from the serosal cells of the pleura, pericardium, and peritoneum.

**Distribution and incidence.**—Mesotheliomas apparently occur throughout the United States but are so uncommon that little information concerning generic, species, breed, or sex incidence is available. During USDA's 2-year survey, mentioned on page 1, 0.22 percent of the cattle tumors collected were mesotheliomas. None were found in sheep, goats, or swine during the survey.

Most pathologists hesitate in making a diagnosis of primary mesothelioma of the pleura, pericardium, or peritoneum for two reasons. One is that the anaplastic mesothelial cells in mesotheliomas have a morphologic similarity to the malignant cells of other neoplasms that may invade the body cavities (pulmonary, uterine, ovarian, bile duct, intestinal carcinomas). The second is that the anaplastic mesothelial cells in mesotheliomas resemble the hyperplastic serosal cells associated with inflammatory processes of the pleura, pericardium, and peritoneum.

Mesotheliomas have certain characteristic features that differentiate them from other neoplasms. These

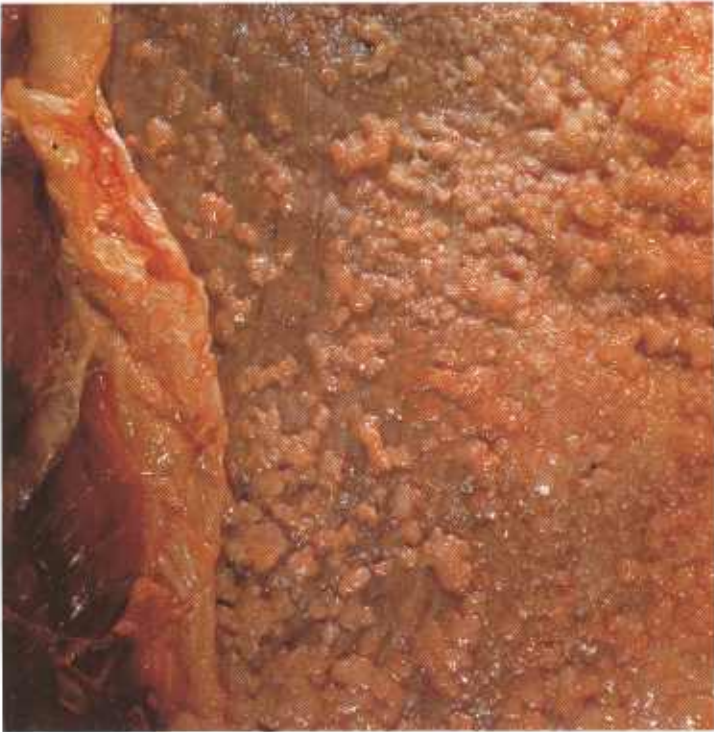

Figure 218.—Mesothelioma of the peritoneum of a 5-year-old cow (A378-D2922). Multiple gray, firm, flattened or papillary growths that measure 1 mm. to 6 cm. in diameter are scattered over the peritoneal surface. The lesions could be confused with those found in tuberculous peritonitis.

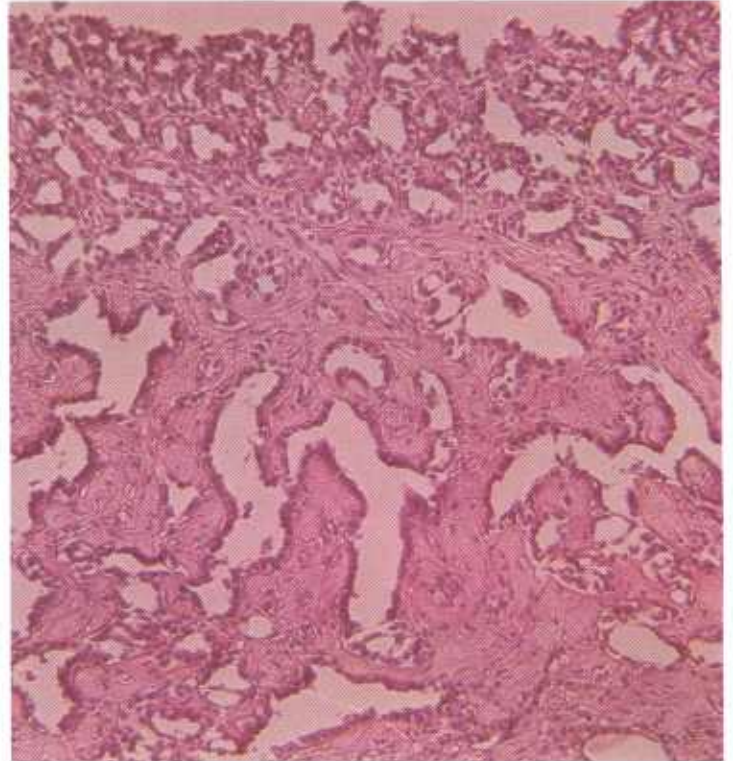


Figure 220.—A histologic preparation of a mesothelioma of the peritoneum of an old cow (126200). The tumor consists of spaces lined with low columnar epithelium and supported by a connective tissue stroma. Hematoxylin-eosin stain.  $\times 125$ .

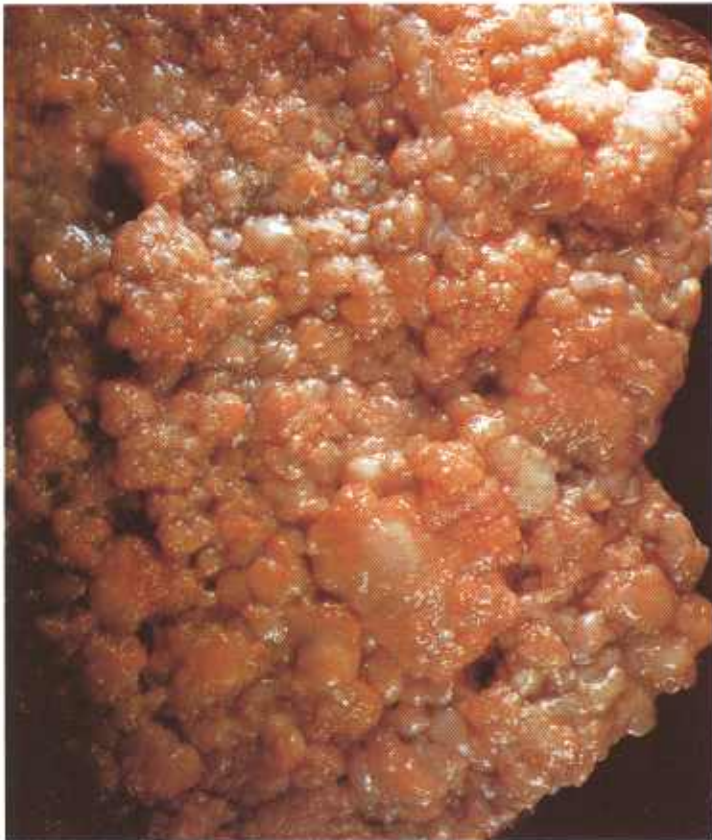

Figure 219.—Mesothelioma of the peritoneum of a 4-year-old cow (A444-D3511). The entire peritoneal surface is covered with soft papillary growths.

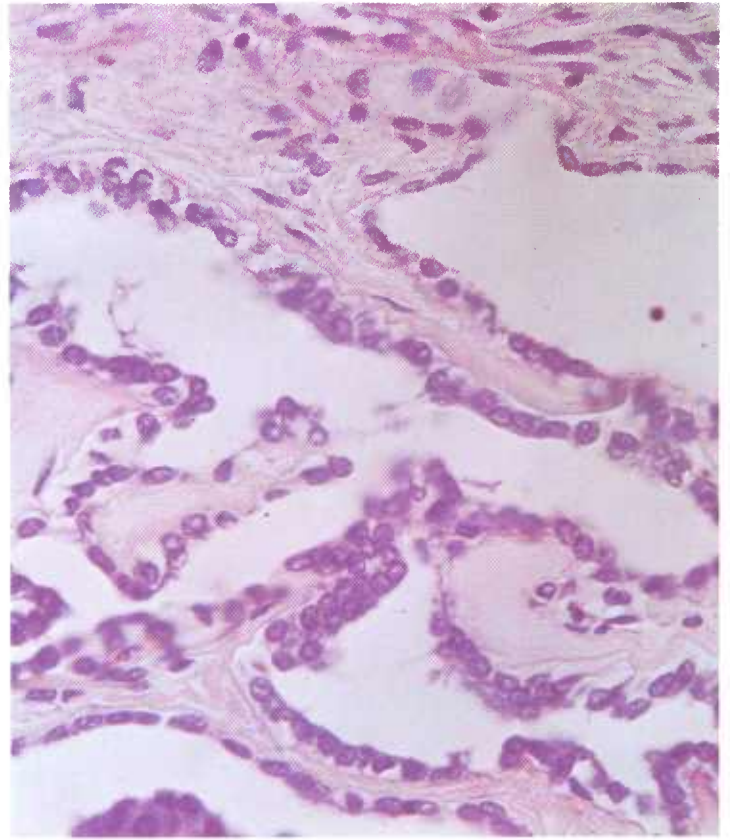


Figure 221.—A higher magnification of the mesothelioma (126200) shown in figure 220. The spaces are lined with low columnar epithelium. Hematoxylin-eosin stain.  $\times 320$ .

tumors spread over affected serous surfaces in the form of sheets or nodules. They produce an abundance of secretion having a high hyaluronic acid content. The fact that mesotheliomas produce hyaluronic acid differentiates them from other epithelial and endothelial tumors that apparently are unable to produce this substance. Although neoplastic tissue may be abundant on the serosal surfaces involved, and although a slight invasion of the underlying tissues may occur, mesotheliomas seldom metastasize to other organs. If metastases do occur, they are usually confined to the regional lymph nodes.

**Macroscopic appearance.**—Multiple white or tan nodules measuring 1 mm. to 1 cm. in diameter are scattered over the serosal surface of the peritoneum, pleura, or pericardium. At times, the nodules are so numerous that they become confluent and form sheets of neoplastic

tissue over the serosal surface. Small cysts are usually visible in the neoplastic nodules. The underlying connective tissue and muscle are not invaded by the neoplasm. Varying amounts of fluid containing desquamated neoplastic cells are usually present in the affected body cavity.

**Microscopic appearance.**—The mesothelioma is composed of squamous, cuboidal, columnar, or stratified epithelial anaplastic mesothelial cells. The most consistent feature of most bovine tumors is the subserous and usually irregularly arranged papillary proliferations of connective tissue and collagen. Nests of neoplastic mesenchymal cells are frequently found within masses of this fibrous tissue but they always appear as trapped groups of cells, as if connective tissue had grown over and around them.

## CHRONIC INFECTIOUS BACTERIAL DISEASES THAT RESEMBLE NEOPLASTIC ALTERATIONS

### Actinobacillosis

**Definition.**—Actinobacillosis is a chronic focal suppurative inflammation of the soft tissues of cattle and occasionally of swine, sheep, and other animals. It is caused by *Actinobacillus lignieresii*.

**Distribution and incidence.**—The disease is found throughout the United States and is especially common in areas where dense cattle populations are present.

The lymph nodes of the head and neck are the most common sites of infection in cattle. In a series of 82 cases, the incidence of specific organ involvement was the lymph nodes of the head and neck, 50; the peritoneum, 10; the tongue, 10; the pharynx, 2; the larynx, 2; the external nares, 1; the thoracic lymph nodes, 4; the lung, 4; the pleura, 3; the subcutaneous tissues, 2; the

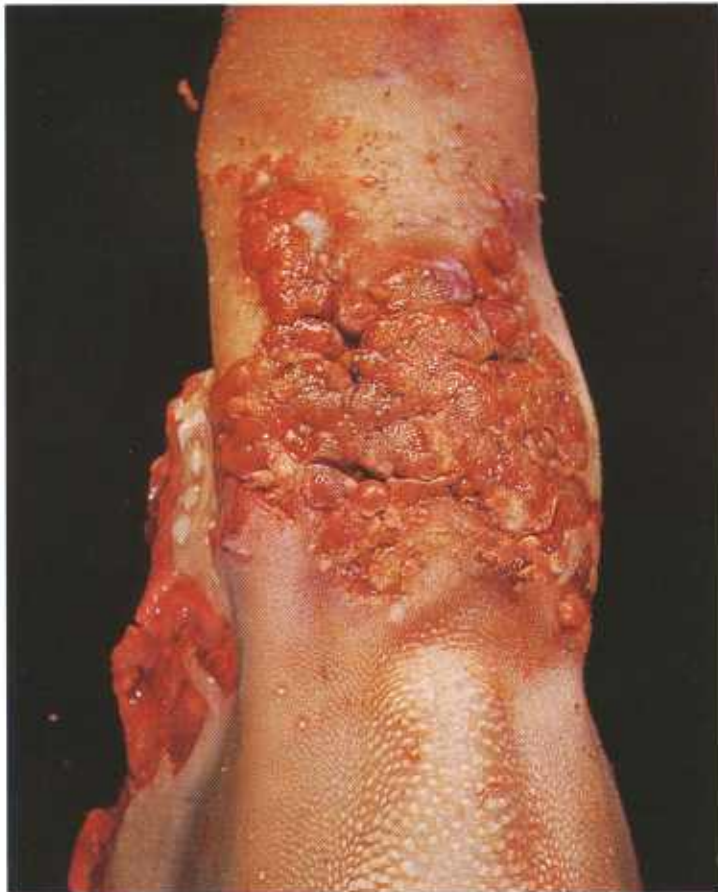

Figure 222.—Actinobacillosis of the tongue of a 2-year-old steer (B161-D2956). Confluent flattened, papillary growths appearing on the dorsal surface of the tongue.

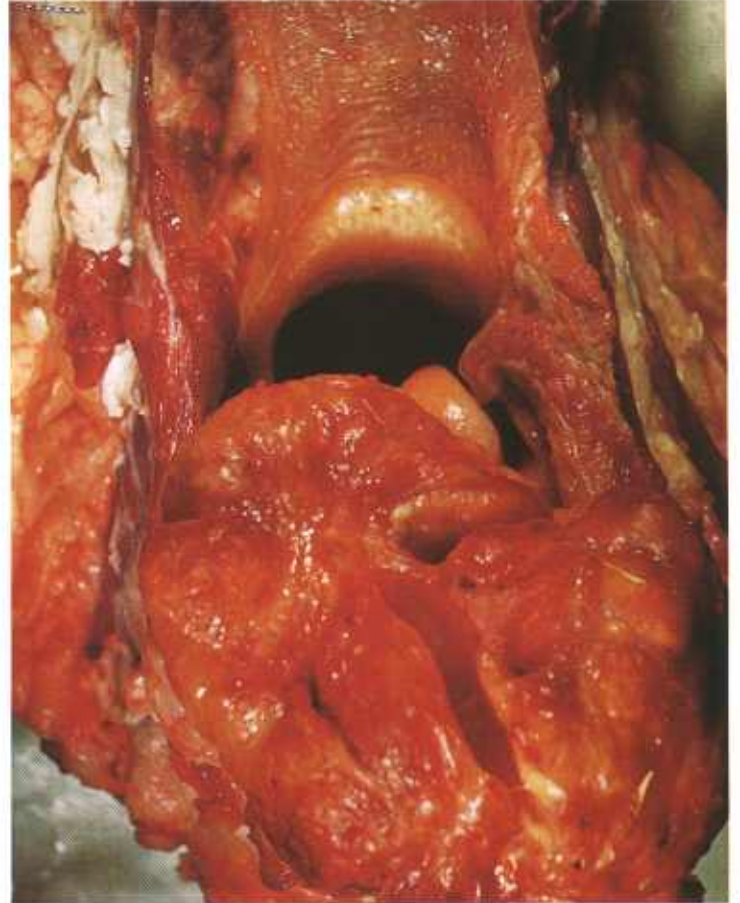


Figure 223.—Actinobacillosis of the tongue of a steer (B41-128565). A large mass in the wall of the pharynx that is interfering with the passage of air, food, and water and the eructation of rumen gases.

heart, 1; the gluteal muscle, 1. Lesions in swine and sheep usually occur in the subcutaneous tissue.

The most frequent site of entry of the organism is in the tongue just anterior to the dorsal eminence where sharp plant beards and other objects become inserted. The lesions in the regional lymph nodes of the head are probably the result of tonsillar and glossal infections. Entrance of the organisms into the lungs is probably accomplished through the inhalation of dust or the aspiration of pus from lesions in the upper respiratory tract.

**Macroscopic appearance.**—The lesion begins as an

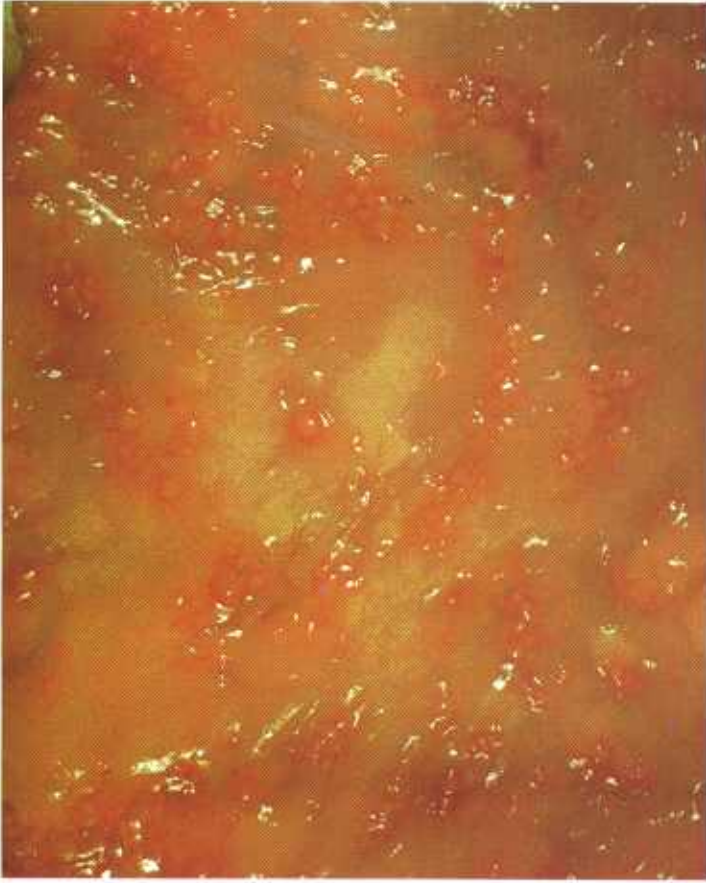

Figure 224.—Actinobacillosis of the omentum of a 3-year-old cow (B100-D2058). Multiple yellow nodules measuring 1 to 3 mm. in diameter and surrounded by a zone of hyperemia, are scattered over the surface of the omentum.

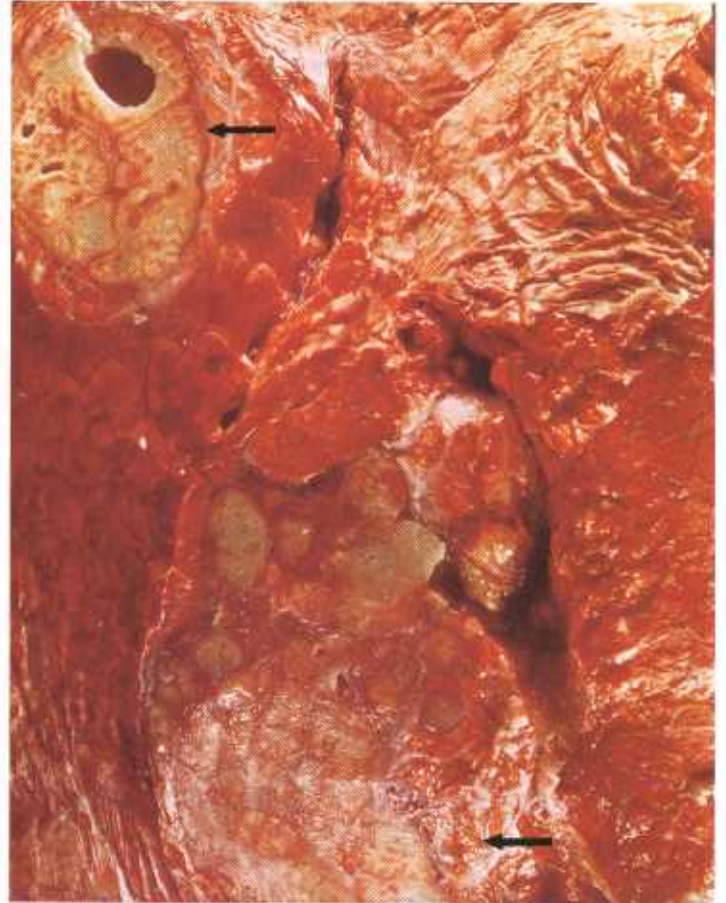

Figure 226.—Actinobacillosis of the lung of a cow (B172-132380). Areas (arrows) of chronic inflammation that resemble tuberculosis are present in the parenchyma of the lung.

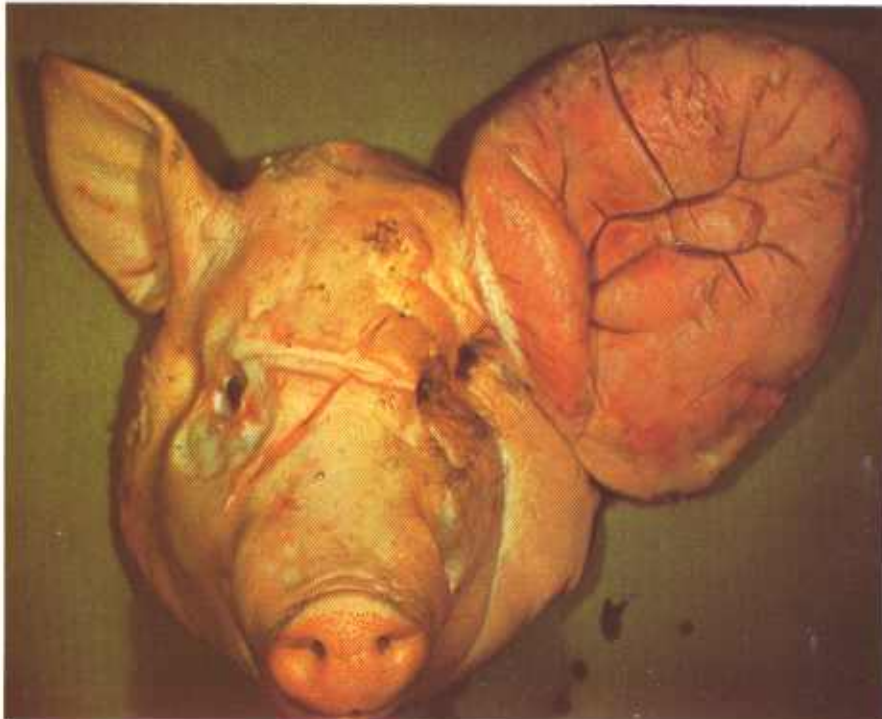


Figure 225.—Actinobacillosis of the ear of a pig (B116-D2230). The ear to the right is greatly enlarged as the result of a chronic productive suppurative inflammation.

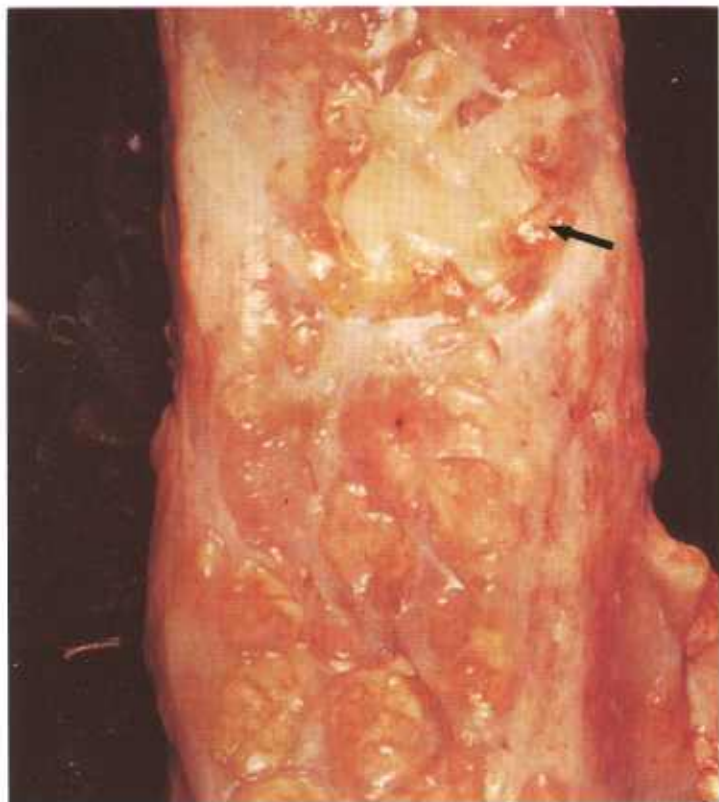


Figure 227.—Actinobacillosis of a prescapular lymph node in a cow (B193-132925). The lesion consists of a chronic suppurative inflammation that has destroyed most of the lymph node. The arrow indicates a large mass of pus.

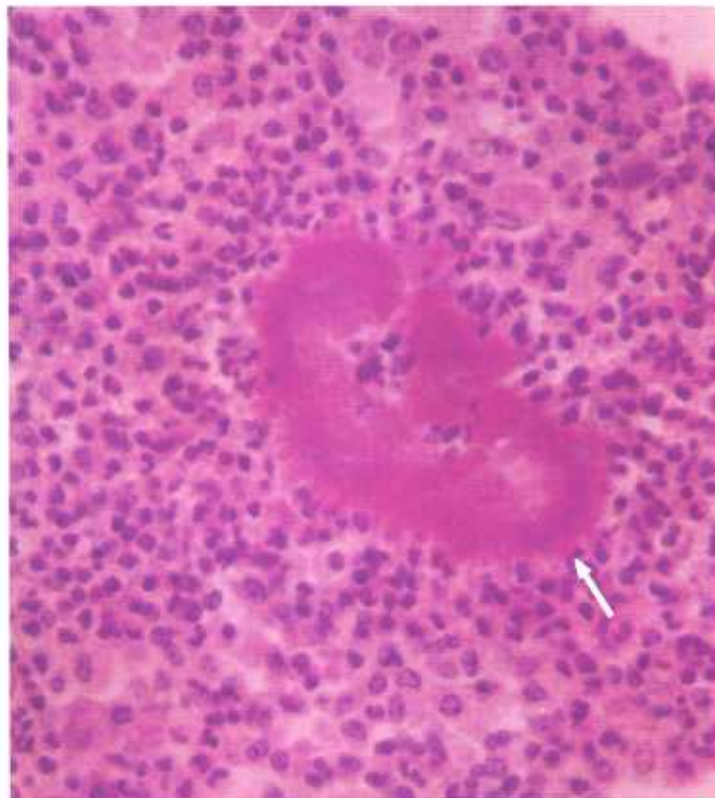


Figure 229.—A histologic preparation of the pharyngeal mass B41-128565) shown in figure 223. The photograph shows an eosin-staining "sulfur granule" (arrow) surrounded by many neutrophils. Hematoxylin-eosin stain.  $\times 500$ .

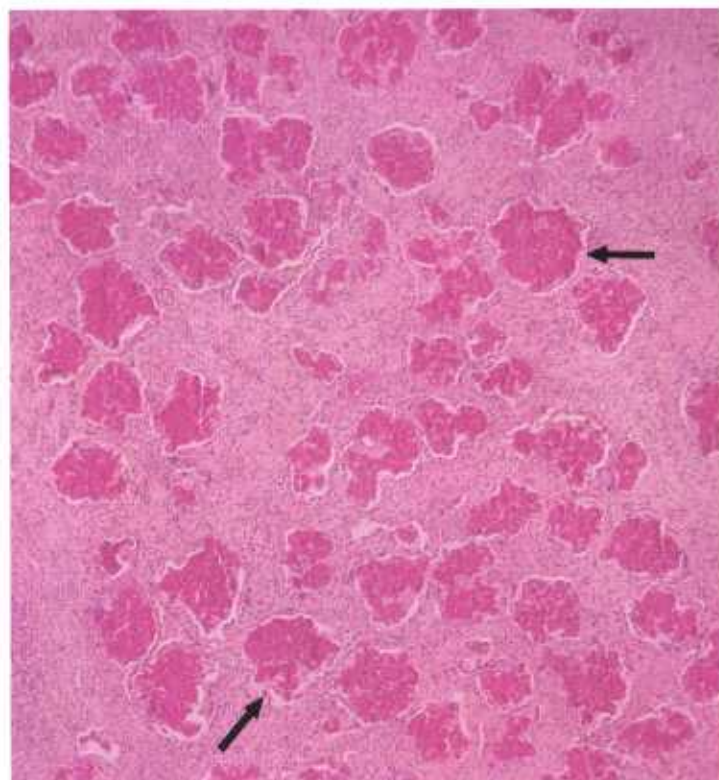


Figure 228.—A histologic preparation of the omentum (B100-D2058) shown in figure 224. Multiple eosin-staining "sulfur granules" (arrows) are enclosed by chronic inflammatory tissue. Hematoxylin-eosin stain.  $\times 50$ .

area of acute suppurative inflammation that soon becomes surrounded by a zone of proliferating connective tissue. The center of the abscess consists of a mass of thick, tenacious pus in which are suspended small yellowish-gray granules ("sulfur granules") measuring 1 mm. in diameter. The abscess may point and rupture and, according to its location, its contents may then discharge onto the surface of the skin, mucous membrane, or serous membrane. Discharge onto a skin or mucous membrane through a sinus or several sinus tracts may continue for months or years until healing occurs or the lesion is removed surgically.

When the tongue is involved it becomes greatly enlarged and partially immobilized, and is often permeated with abscesses. The enlarged stiff tongue is frequently referred to as "wooden tongue."

**Microscopic appearance.**—After the initial invasion of the tissue by the organisms, an acute suppurative inflammation is produced. The organisms become surrounded with a mass of neutrophils. After 3 or 4 days, macrophages, lymphocytes, a few giant cells, and fibroblasts appear in the area. With the appearance of these cells, the type of reaction becomes chronic in nature. The organisms soon become surrounded with a fringe of radiating club-shaped structures that probably represent a precipitation of protein on the bacteria as the result of an antigen-antibody reaction between the organisms and the body fluids of the host. These aggre-

gates of club-shaped structures, stained pink with eosin, are called rosettes, and are the "sulfur granules" observed grossly in the pus. When the lesions are stained with the Gram's method, small Gram-negative bacteria are found within the rosettes.

The rosettes of actinobacillosis are frequently confused with similar structures observed in actinomycosis, staphylococcosis, and other chronic suppurative diseases. The rosettes of actinobacillosis are usually softer and smaller than those observed in actinomycosis.

## Actinomycosis

**Definition.**—Actinomycosis is a chronic focal suppurative inflammation of the mandible and maxillae of cattle and the mammary glands of swine that is caused by *Actinomyces bovis*.

**Distribution and incidence.**—The disease is found throughout the United States. In cattle, invasion of the bones of the head is brought about by the introduction of organisms into the peridental tissues, where they cause an alveolar periostitis. The organisms are conveyed into the host animals on splinters of wood, plant thorns, barbs, and awns. In swine, *A. bovis* causes a chronic suppurative inflammation of the mammary glands and tonsils and castration wounds. *Staphylococcus aureus*, as a secondary invader, is commonly associated with actinomycosis of the mammary gland.

**Macroscopic appearance.**—Lesions of actinomycosis consist of a chronic, focal or diffuse, suppurative inflammation. Bone in the more severe areas of inflammation

undergoes atrophy and in the less severe areas of inflammation undergoes hyperplasia and forms irregular masses of osseous tissue that cause distortion and disfiguration of the mandible and maxillae. White fibrous connective tissue in the area, especially in the periphery of the lesion, undergoes hyperplasia, and dense masses of it are deposited in the affected site.

Abscesses rupture frequently and thick, tenacious, light-green pus, containing yellowish-gray granules ("sulfur granules"), flows from one or several sinus tracts that drain on the lateral or ventral skin surface of the head or drain on the mucous membrane of the mouth, pharynx, or nasal cavity. The maxillary sinuses are frequently filled and distended with exudate that may drain into the nasal cavity through the naso-maxillary fissure.

**Microscopic appearance.**—Soon after the organisms enter the tissues, there is an acute suppurative inflam-

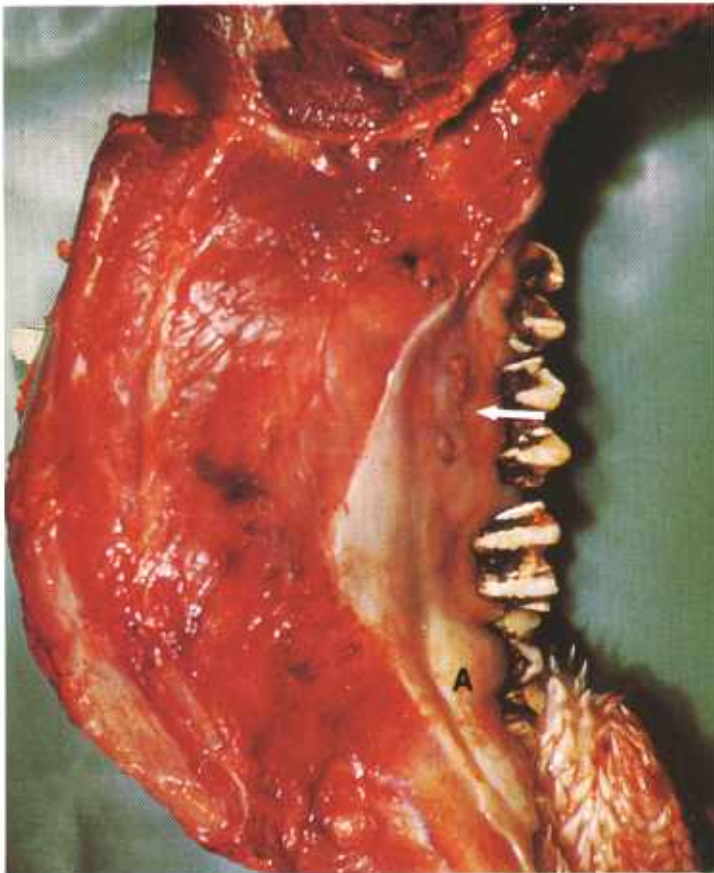


Figure 230.—Actinomycosis of the mandible of a cow (C8-128712). Note the increased diameter of the mandible, the protruding abscesses (A), and the ulcers (arrow).

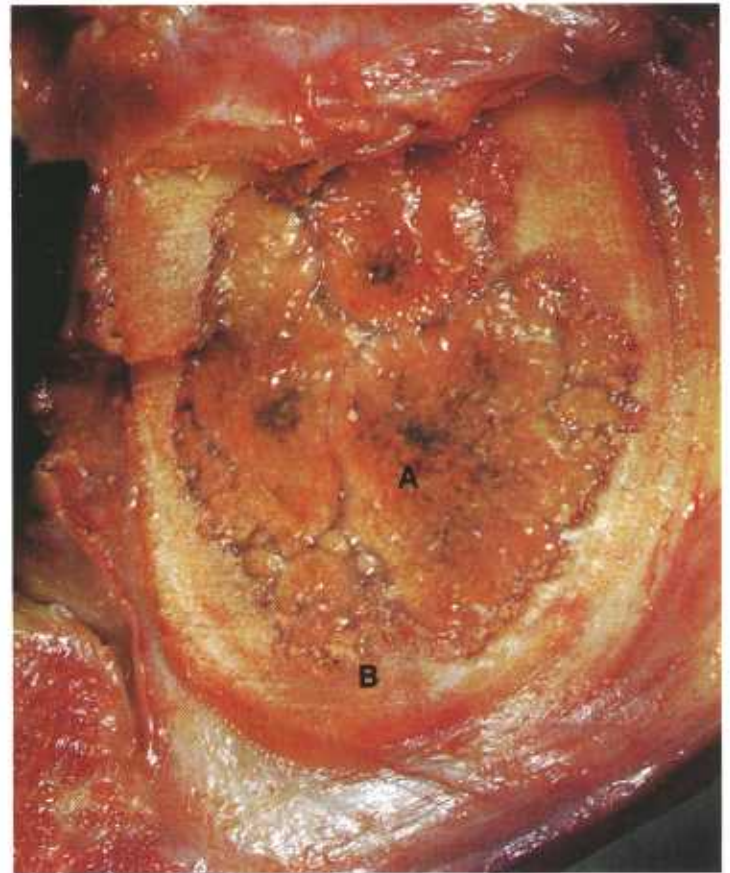


Figure 231.—Actinomycosis of the mandible of a cow (C8-128712). The marrow cavity is filled with a yellow mass of chronic inflammatory tissue (A) that is invading the bone (B).

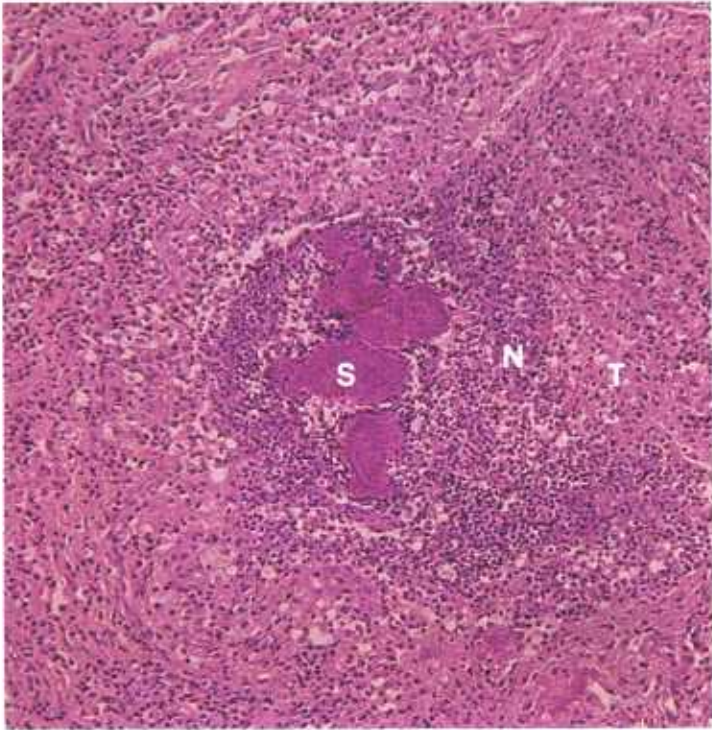


Figure 232.—Actinomycosis of the bones of the orbital region of a 6-year-old Hereford cow (D2711). A group of “sulfur granules” (S) is surrounded by a zone of neutrophils (N) and all are enclosed by chronic productive inflammatory tissue (T) in which the macrophage is the predominating cell. Hematoxylin-eosin stain.  $\times 125$ .

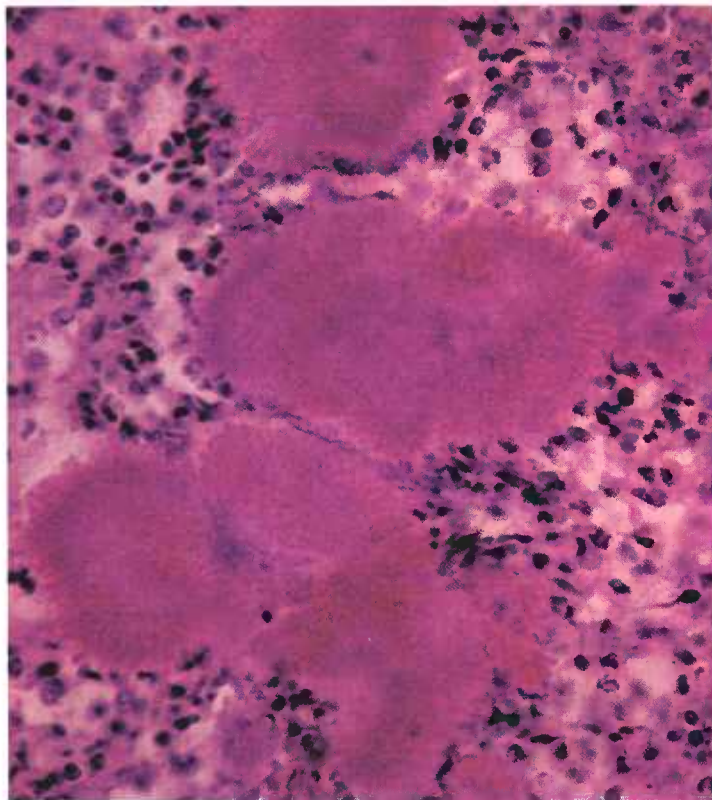


Figure 233.—A higher magnification of the actinomycotic “sulfur granules” (D2711) shown in figure 232. The radiating club-shaped structure of the granules is revealed. Hematoxylin-eosin stain.  $\times 500$ .

mation with the accumulation of neutrophils in the tissues in the vicinity of the organism. After several days, macrophages, lymphocytes, fibroblasts, and (later) giant cells appear in the area. With the appearance of these cells, the lesion is classified as chronic. Thick, dense, zones of these cells and mature collagen are deposited in the periphery of the lesion. Even though the lesion is chronic, large numbers of neutrophils persist in the immediate vicinity of the organisms.

Osseous structures in the immediate vicinity of the inflammatory process undergo demineralization, disintegration, and atrophy. Periosteum, endosteum, and osteoblasts in the periphery of the lesion, stimulated by the irritant and the inflammatory process, undergo hyperplasia and form osteoid and osseous tissue.

When the lesions are stained with the Gram's method, radiating, filamentous, Gram-positive bacteria are found in the rosettes (“sulfur granules”) and occasionally in the tissues. The organisms are surrounded by radiating, club-shaped masses of precipitated protein that represent an antigen-antibody reaction between the organism and the host. The presence of rosettes is not a pathognomonic lesion of any specific disease but represents a tissue alteration common to several chronic diseases (actinobacillosis and staphylococcosis). However, rosettes of actinomycosis are firmer and larger than those of other chronic diseases, and their radiating club-shaped structures are larger and more distinct.

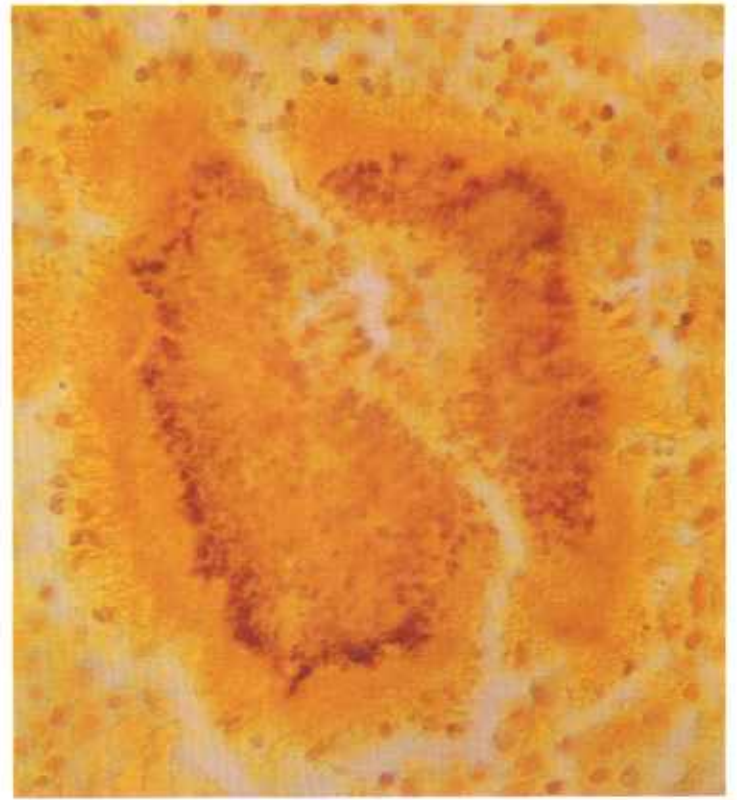

Figure 234.—A Gram stain of a “sulfur granule” (D2711) similar to those shown in figures 222 and 223. *Actinomyces bovis* appears as small Gram-positive (purple) rods against a yellow background. Gram-Weigert stain.  $\times 500$ .

## Brucellosis

**Definition.**—Brucellosis is a chronic infectious disease of cattle, swine, sheep, and goats caused by *Brucella abortus*, *B. suis*, and *B. melitensis*.

**Distribution and incidence.**—The disease is found throughout the United States. Its incidence varies with animal populations and the effectiveness of eradication programs in specific areas.

Although the infection has a preference for certain organs, it can be found in any organ or tissue throughout the body. It is commonly found in the articulations of swine, where it produces a suppurative arthritis. Suppurative spondylitis, especially of the lumbar region, is a common lesion in affected swine. The organism is often isolated from fistulous withers of horses, but proof is lacking that it is the actual cause of this shoulder abscess.

The most important lesions in cattle and swine, because of the loss of offspring, are found in the genital organs. The chronic suppurative inflammation produces marked distortion of the genital organs and causes sterility. The lesions may be focal, multiple focal, or diffuse. Occasionally, an entire genital organ, such as a testicle, is converted into one large abscess.

**Macroscopic appearance.**—The basic alteration is a chronic suppurative inflammation. The amount of sup-

uration varies considerably. In some areas the lesion consists principally of an abscess but in others, gross pus cannot be seen. The amount of connective tissue present depends upon the age of the lesion. In recent infections, connective tissue is not grossly visible, but in those 1 or 2 years of age or older, there is often an abundance of scar tissue with considerable distortion of the organ in which the lesion occurs.

In swine, splenic lesions consist of circular hyperplastic areas with depressed centers that measure as much as 5 cm. in diameter. In other species of animals, the hyperplasia of splenic tissue is not as prominent, and the focus of infection is manifested as a yellow, gray, or white abscess that usually measures less than 1 cm. in diameter. Abscesses measuring 1 cm. or less in diameter are occasionally observed in the liver and other organs. Involved lymph nodes are hyperplastic and are infiltrated with connective tissue. Occasionally, they contain abscesses that can be observed grossly.

Alterations in the placentae of animals possessing resistance to brucellosis are more productive in type than those affected with brucellosis for the first time. The process begins in the uterus and then extends from the maternal caruncles to the fetal cotyledons and continues to spread to the intercotyledonary epithelium.

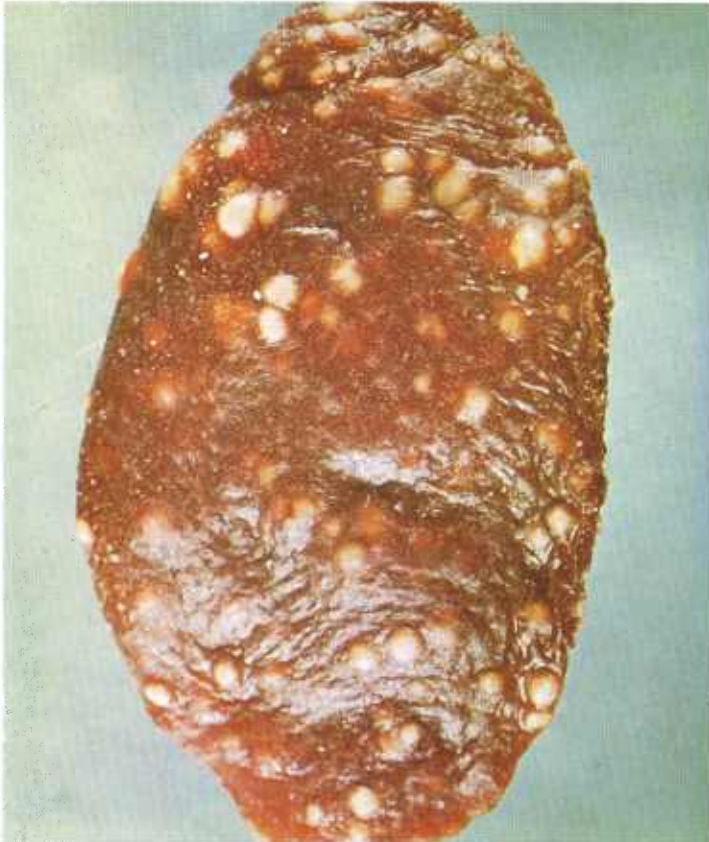

Figure 235.—Brucellosis of the spleen of a 6-month-old gilt (B188-D3301). The spleen contains multiple white, caseous foci of chronic inflammation.

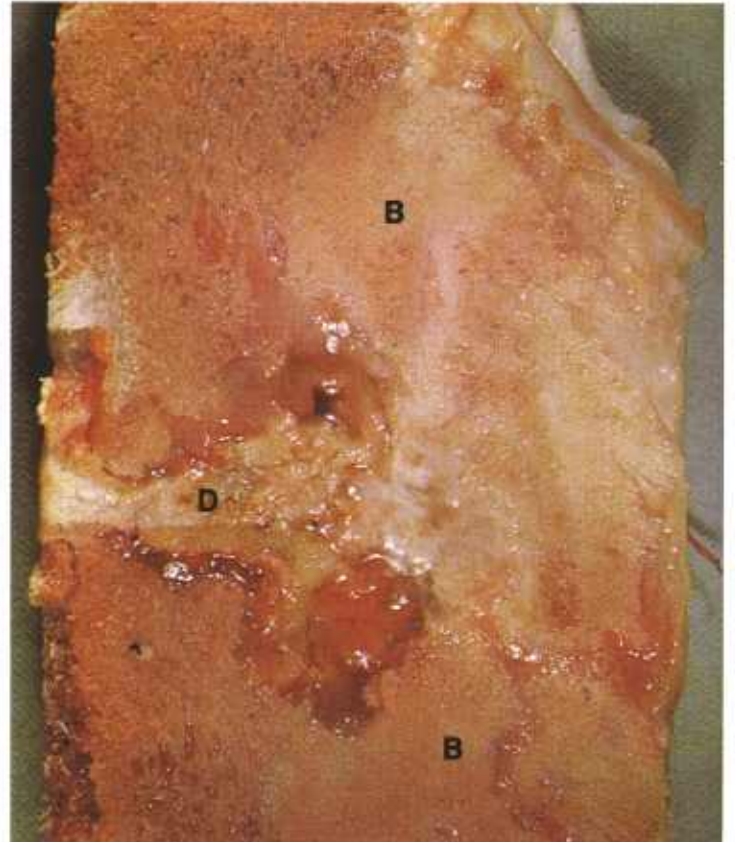


Figure 236.—Brucellosis of two lumbar vertebrae of a hog (B47-D1497). There is a chronic suppurative inflammation of the bodies (B) of two vertebrae and an intervertebral disc (D).

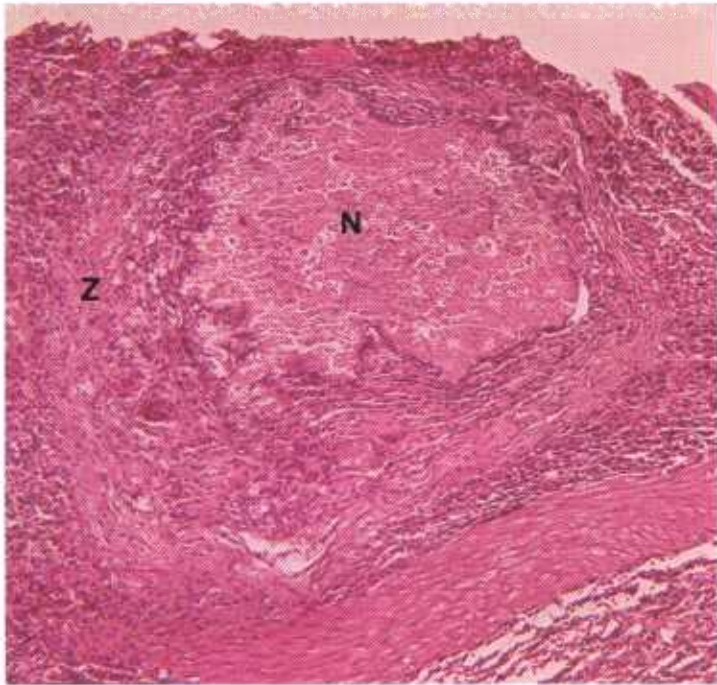


Figure 237.—A histologic preparation of the spleen (B188-D3301) shown in figure 235. A focus of caseous necrosis (N) is surrounded by a zone of chronic productive inflammation (Z). Hematoxylin-eosin stain.  $\times 125$ .

As it spreads into the intercotyledonous epithelium, the membranes lose their moist transparent appearance and become cloudy and dry. Later, the membranes become brown, opaque, thickened, wrinkled, and leather-like in consistency. The appearance of the fetal membranes at the time of abortion indicates the condition of the uterine mucosa.

Lesions in the mammary gland consist of a chronic focal suppurative mastitis. Occasionally, small abscesses are visible.

**Microscopic appearance.**—The basic lesion is a chronic suppurative inflammation in which the neutrophil is the principal constituent of the exudate. The number of neutrophils varies considerably from lesion to lesion. In some, few cells other than neutrophils are present and in others relatively few neutrophils are found. Because of the chronicity of the lesion, many lymphocytes and macrophages and a few giant cells are present. The organisms cause a productive type of inflammation. As the condition progresses, connective tissue continues to be deposited in the affected area. The lesion cannot be differentiated with certainty from other chronic suppurative alterations (tuberculosis and nocardiosis). Therefore, a definite diagnosis depends upon the isolation and identification of the etiologic agent.

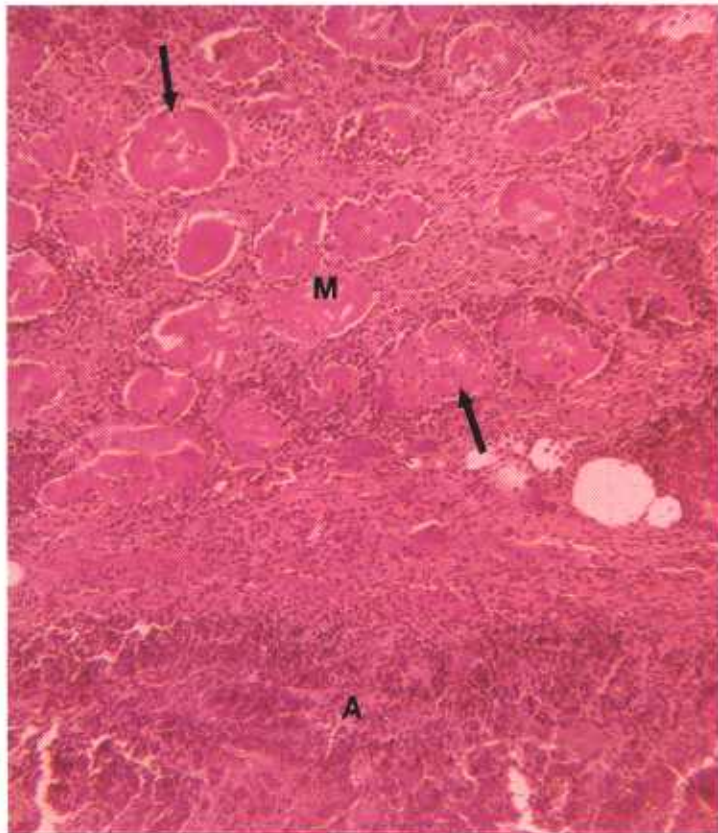


Figure 238.—Brucellosis of the loin of a hog (128637). The inflammatory process has extended from an abscess (A) in the vicinity of a lumbar vertebra into the adjacent loin muscles (M). The necrotic muscle cells (arrows) are separated from each other by chronic inflammatory tissue. Hematoxylin-eosin stain.  $\times 125$ .

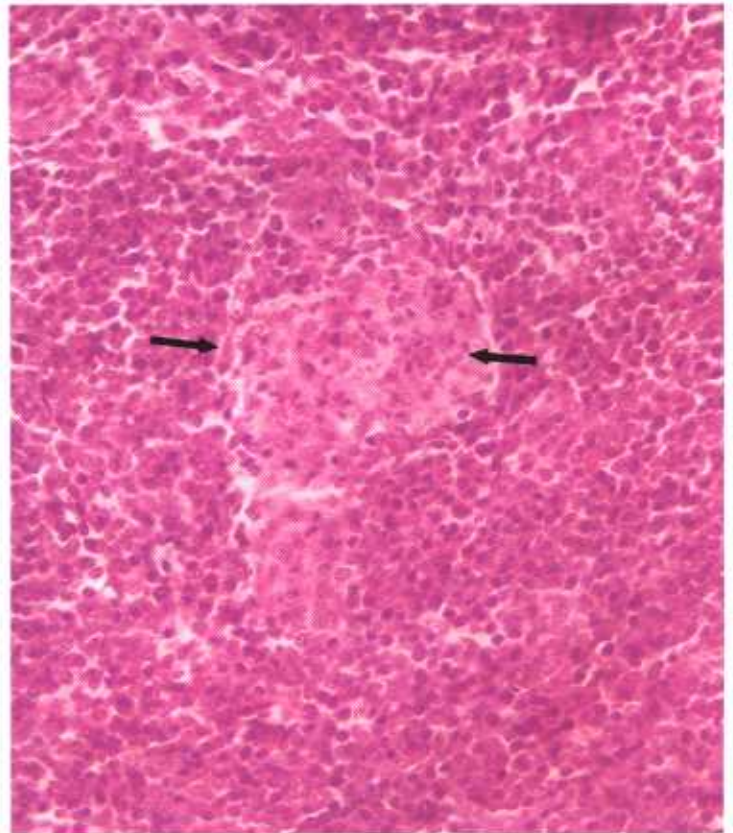


Figure 239.—A histologic preparation of the spleen (B188-D3301) shown in figure 235. A focal area (arrows) of macrophage hyperplasia and neutrophil infiltration is found in the parenchyma of the spleen. This type of reaction occurs soon after *Brucella* organisms have localized in the spleen. Hematoxylin-eosin stain.  $\times 320$ .

## Cervical Anthrax in Swine

**Definition.**—Cervical anthrax in swine is an acute, subacute, or chronic infectious disease of the throat region caused by *Bacillus anthracis*.

**Distribution and incidence.**—Anthrax in swine is an endemic disease occurring principally in those areas where anthrax in cattle is prevalent. Swine become infected by consuming dead animals, improperly sterilized bonemeal, tankage, or vegetation that contains *B. anthracis*. Several animals in the herd are usually affected at the same time. Cervical anthrax is most frequently observed in swine living in slashes and cane breaks of the flood plains along rivers in the southern United States. Lesions are usually confined to the throat region.

**Macroscopic appearance.**—The type of tissue reaction observed in cervical anthrax depends upon the stage of the disease and the resistance of the pig. An occasional pig will develop an acute fatal septicemic form of the disease, a few may die as the result of suffocation from the cervical swelling, and some may also have intestinal involvement; most, however, will recover and show no further clinical signs of the disease.

The most prominent lesion is an acute inflammatory swelling of the ventral and lateral cervical regions. Dissection of the throat and neck reveals a lymphadenitis that involves the submaxillary, parotid, and prescapular lymph nodes. Affected nodes are greatly enlarged and, in the more acute infections, are moist and engorged with blood, and are cherry red or brick red. Chronic

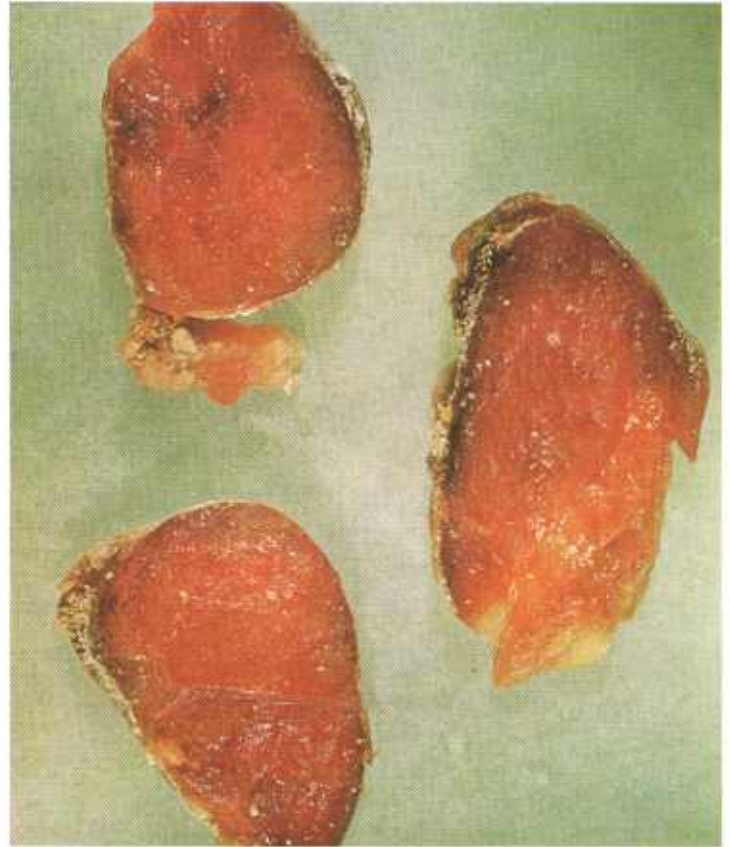

Figure 241.—Anthrax of cervical lymph nodes in a hog (B99-129764). The lymph nodes have undergone coagulative necrosis and are red—alterations typical of cervical anthrax.

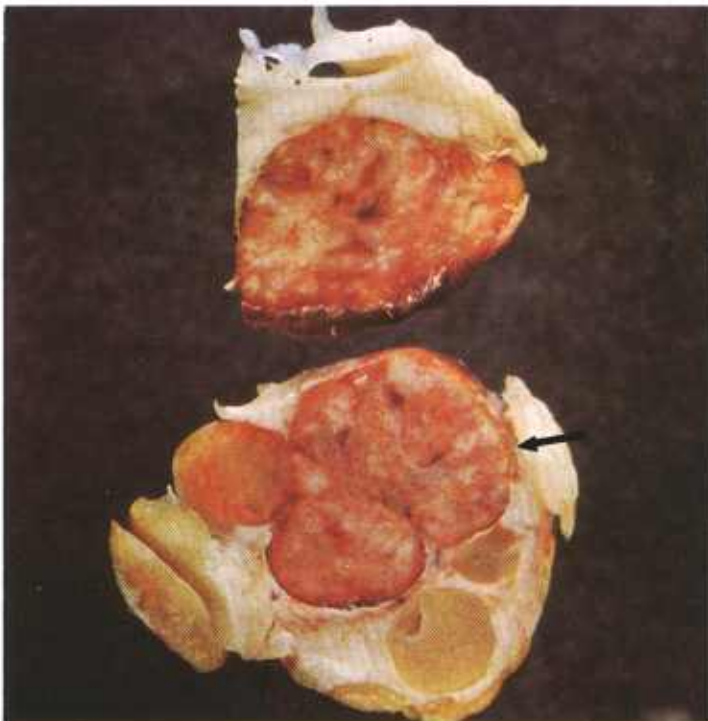


Figure 240.—Anthrax of a cervical lymph node in a 10-month-old sow (B78-D1811). One part (arrow) of the lymph node aggregate has the red necrotic appearance of cervical anthrax. Adjacent areas of the lymph node are not affected.

lesions are salmon pink and dry. Usually the entire node is involved but occasionally only parts are affected. Tonsillitis is commonly observed and is an indication of the portal of entry of the bacilli.

**Microscopic appearance.**—According to the course of the disease, there is an acute diffuse hemorrhagic, fibrinous, suppurative, or necrotic lymphadenitis, or a chronic diffuse necrotic lymphadenitis. Focal suppurative lesions usually indicate that a concurrent streptococcal infection is also present. Chronic tuberculous lymphadenitis and lymphosarcomas are occasionally observed as concomitant diseases in nodes affected with anthrax.

The typical lesion in a cervical lymph node affected with anthrax consists of a central area of coagulative necrosis surrounded by a zone of acute, subacute, or chronic inflammation. The general architecture of the node is almost completely destroyed and only a few damaged lymph follicles remain. Perinodal fat and connective tissue are edematous and are infiltrated with leukocytes, and they often contain areas of fat necrosis. In chronic infections, the involved nodes are enclosed in a connective tissue capsule.

Bacterial stains reveal large, square-ended, Gram-positive rods that occur singly or in short chains. When

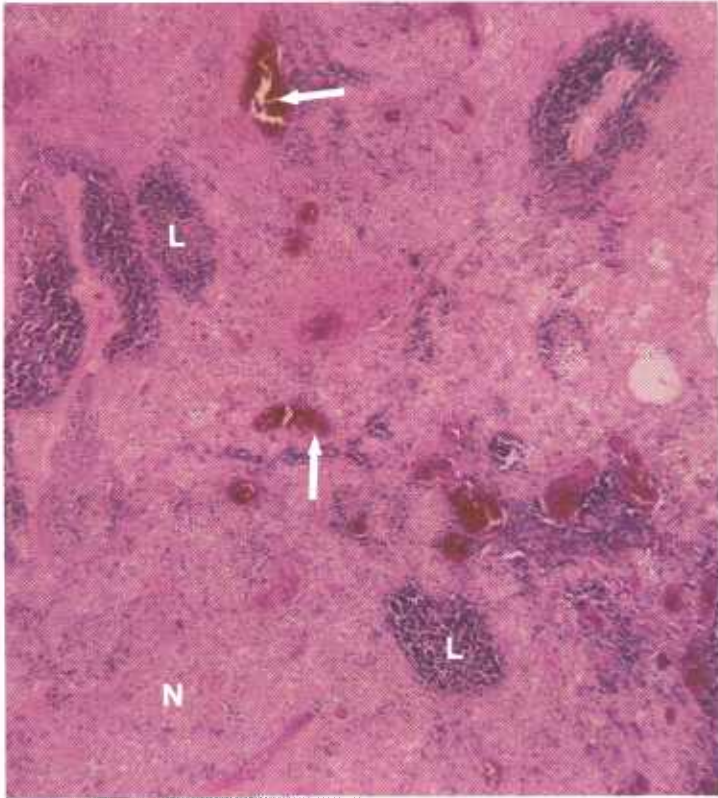


Figure 242.—A histologic preparation of the lymph node (B78-D1811) shown in figure 240. Extensive coagulative necrosis (N) is revealed. A small amount of recognizable lymphoid tissue (L) and a few distended blood vessels (arrows) are still visible. Hematoxylin-eosin stain.  $\times 50$ .

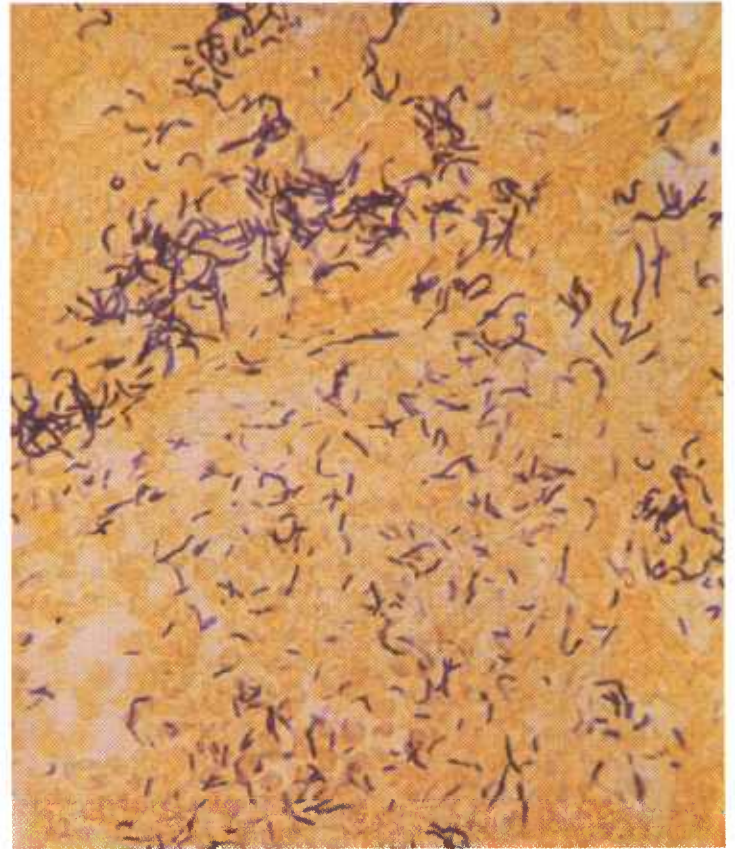


Figure 244.—Anthrax of a cervical lymph node in a 7-month-old gilt (D2276). Numerous Gram-positive organisms are present. Brown and Bren stain.  $\times 500$ .

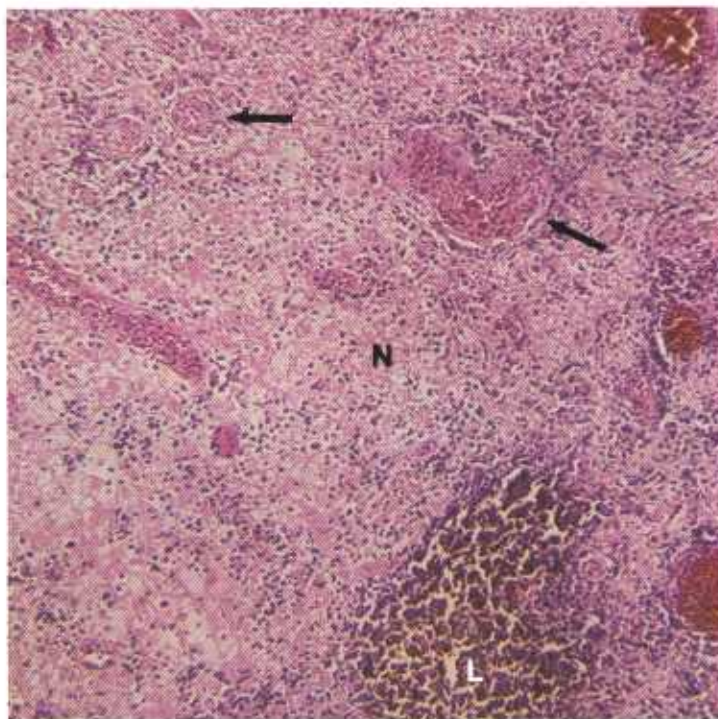


Figure 243.—A higher magnification of the histologic preparation of the lymph node (B78-D1811) shown in figure 242. Most of the tissue has undergone coagulative necrosis (N), a small amount of lymphoid tissue (L) is still recognizable, and a few distended blood vessels (arrows), several containing thrombi, are still discernible. Hematoxylin-eosin stain.  $\times 125$ .

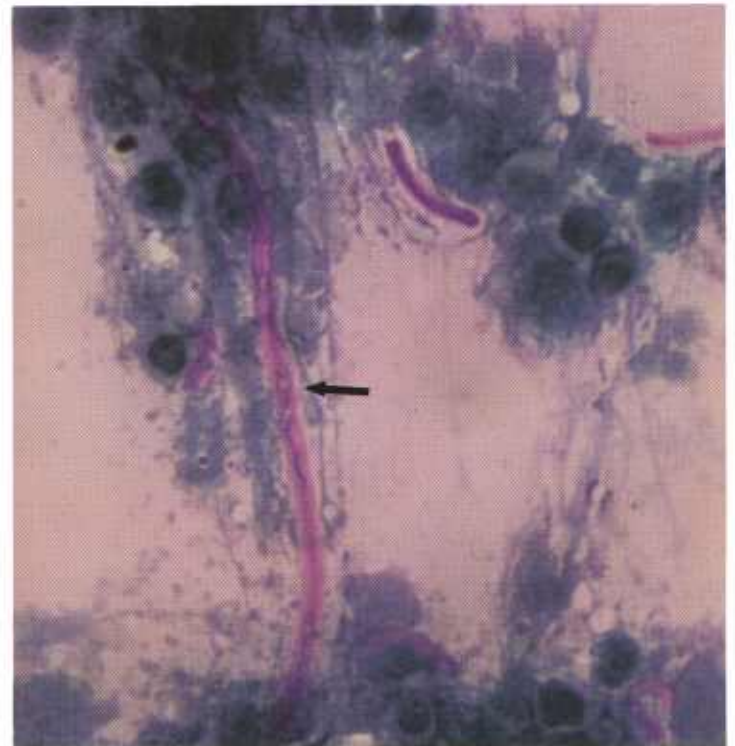


Figure 245.—Anthrax of a cervical lymph node in a 7-month-old gilt (D2276). Pink capsule (MacFayden reaction) of *Bacillus anthracis* (arrow) that has been stained with freshly prepared, slightly basic Loeffler's methylene blue after fixation in absolute methyl alcohol. Loeffler's methylene blue stain.  $\times 1000$ .

smears made of the lesion are fixed in absolute methyl alcohol and stained with freshly prepared, slightly basic, Loeffler's methylene blue, a pink capsule known as the MacFayden reaction is observed around the organisms. This capsule can also be demonstrated when smears fixed in absolute methyl alcohol are stained with the Giemsa technique.

*B. anthracis* loses its morphologic and staining characteristics and becomes avirulent quite soon after the

death of the animal, especially if putrefaction of the carcass occurs. Organisms become increasingly more difficult to stain as putrefaction progresses, soon appear as barely visible rods, and finally cannot be demonstrated at all. When tissue containing these morphologically altered bacilli is placed on artificial media, no growth occurs. If similar material is inoculated into laboratory animals, clinical signs of illness and death do not occur.

## Coccidioidomycosis

**Definition.**—Coccidioidomycosis of cattle and other animals is a chronic infectious disease caused by *Coccidioides immitis*.

**Distribution and incidence.**—The disease is primarily observed in the feed lots of Southwestern United States among cattle 2 to 4 years of age. This age represents the largest group of animals slaughtered. However, on a percentage basis, the incidence is higher in older animals. Affected animals are occasionally observed in other geographic locations but usually are found to have had their origins in the Southwest.

Coccidioidomycosis usually occurs as a chronic suppurative inflammation of the bronchial and mediastinal lymph nodes. Affected animals are usually in good condition and show no clinical signs of the disease.

**Macroscopic appearance.**—Coccidioidomycosis is primarily a disease of lymph nodes and may involve the

entire node or only part of it. Affected nodes contain encapsulated areas of chronic suppurative inflammation that exist as a large single abscess measuring as much as 3 cm. in diameter or as multiple smaller abscesses. The pus is thick, creamy, or tenacious in early lesions but in older lesions it becomes dry and caseous in consistency and may contain granules of calcium. Older lesions resemble those of tuberculosis and can be differentiated only by demonstration of the etiologic agent.

Lung lesions are less frequently encountered than lymph node alterations because the primary lung lesions heal and leave only the secondary lymph node alterations. Pulmonary lesions are usually small, single, and well encapsulated. When the lungs are involved, the thoracic lymph nodes are usually involved also. Involvement of other organs and their contiguous lymph nodes is uncommon.

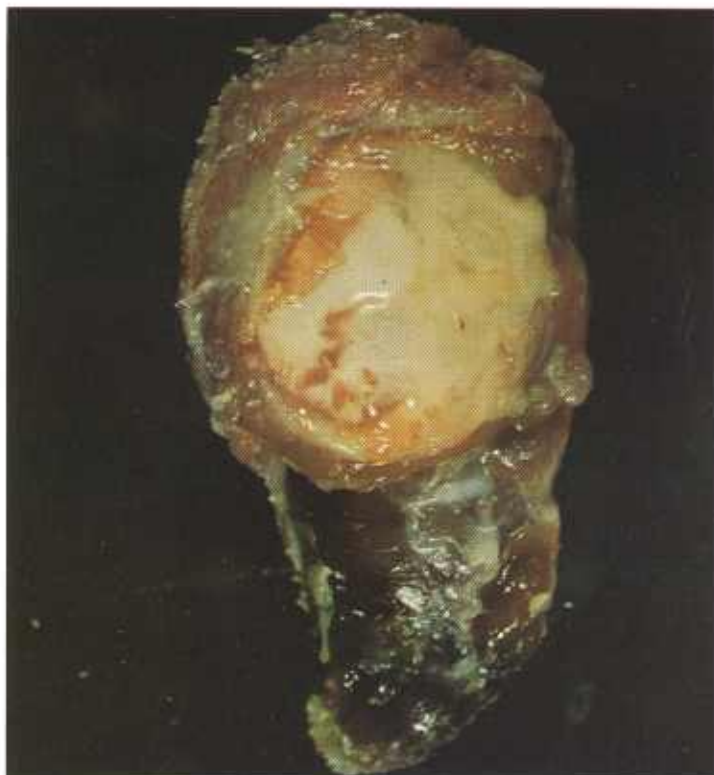

Figure 246.—Coccidioidomycosis of a submaxillary lymph node in a 3-year-old Hereford steer (C28-131070). There is a chronic suppurative lymphadenitis with an abundance of creamy white exudate.

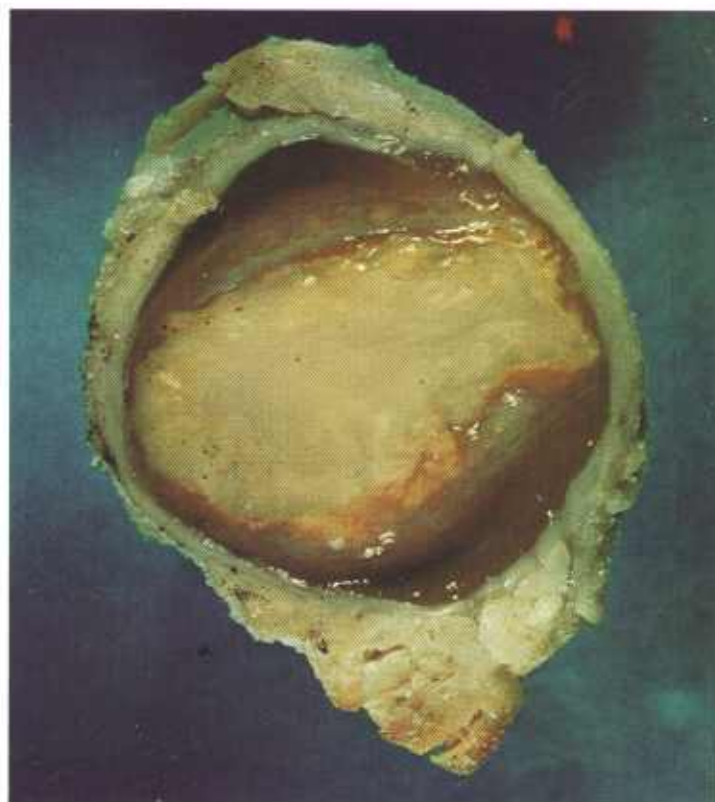


Figure 247.—Coccidioidomycosis of a mediastinal lymph node in an 18-month-old steer (C31-D2541). There is a chronic suppurative lymphadenitis with only a small amount of exudate.

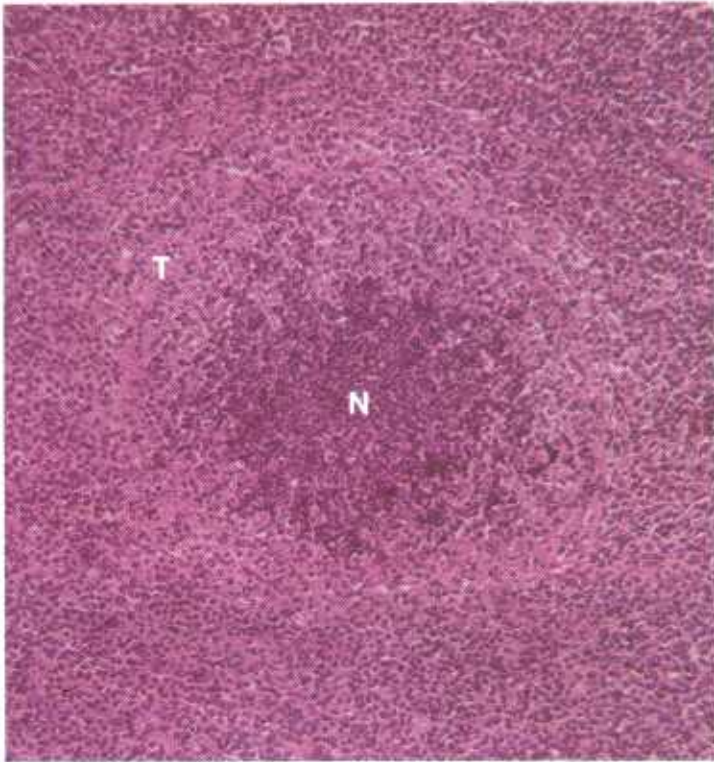


Figure 248.—Coccidioidomycosis of the lung of a steer (D2413). The lesion consists of a chronic suppurative inflammation with a central focus of neutrophils (N) surrounded by chronic inflammatory tissue (T) in which the macrophage is the predominant leukocyte. Hematoxylin-eosin stain.  $\times 125$ .

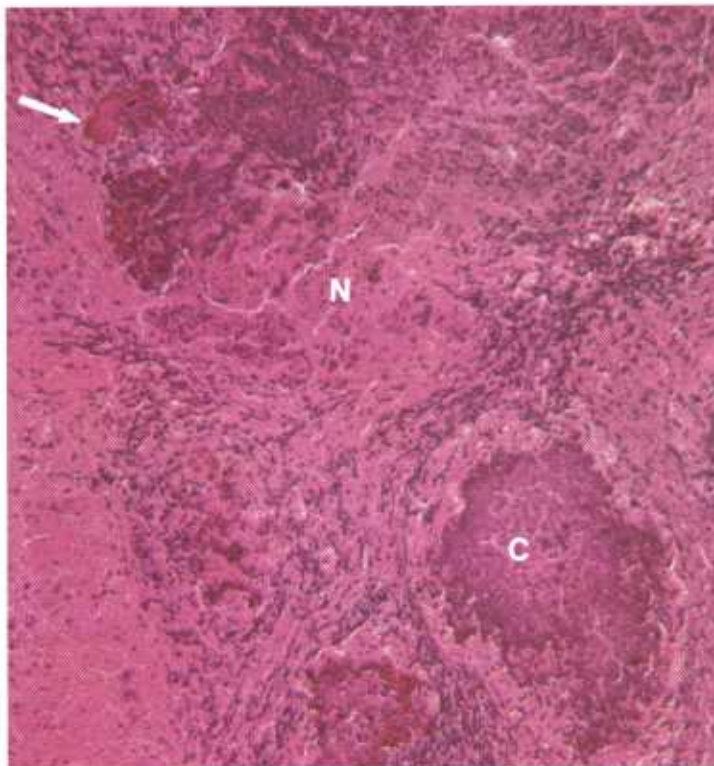


Figure 249.—Coccidioidomycosis of a bronchial lymph node in a 3-year-old steer (D2533). There is a chronic suppurative inflammation with areas of necrosis (N) and calcification (C). A few sulfur granules (arrow) are present. Hematoxylin-eosin stain.  $\times 125$ .

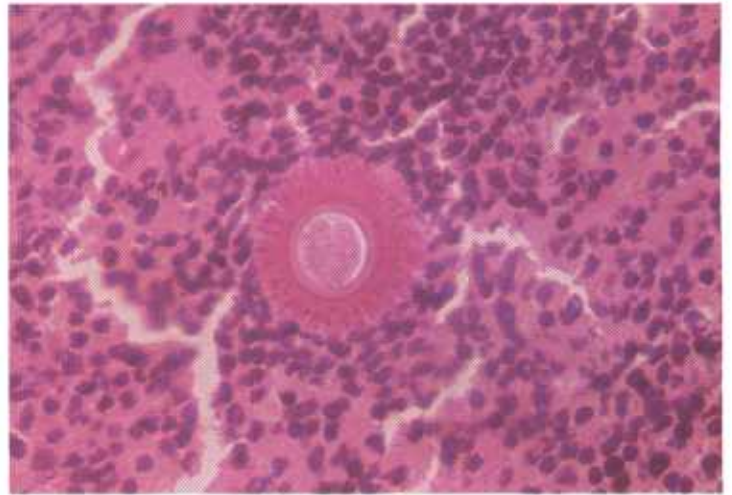


Figure 250.—Coccidioidomycosis of a bronchial lymph node in a 3-year-old steer (D2510). A spherule of *Coccidioides immitis* surrounded by radiating clublike structures is present. Hematoxylin-eosin stain.  $\times 500$ .

**Microscopic appearance.**—The basic lesion consists of a chronic focal suppurative inflammatory reaction. The cellular exudate is composed of lymphocytes, plasma cells, neutrophils, macrophages, and many giant cells. This exudate is enclosed within a heavy connective tissue capsule that is most prominent in pulmonary lesions. Organisms (spherules), many of which have been engulfed by giant cells, are found throughout the area of inflammation. Those organisms not enclosed within giant cells are usually found within a mass of neutrophils. Occasionally, the spherule is surrounded by radiating clublike structures resembling the rosettes of actinobacillosis.

The sporangia of *Coccidioides immitis* are spherical

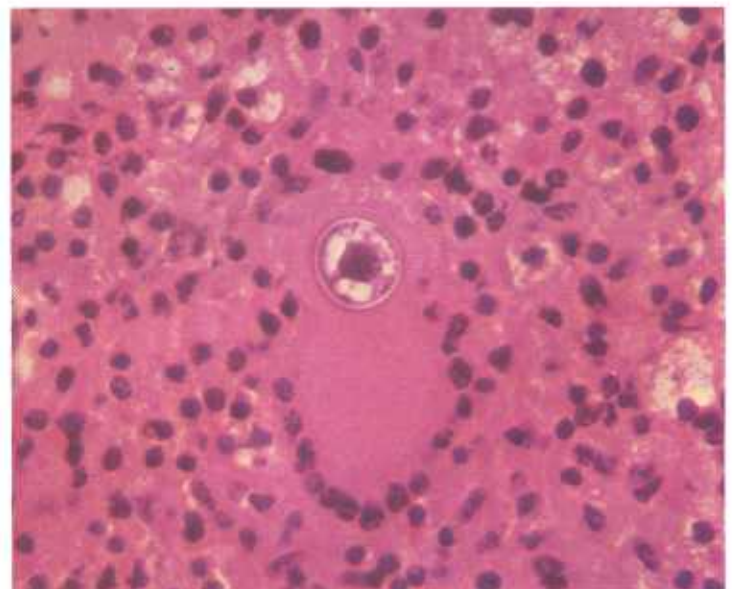


Figure 251.—Coccidioidomycosis of a bronchial lymph node in a 3-year-old steer (D2510). A spherule of *Coccidioides immitis* is present within a giant cell. Hematoxylin-eosin stain.  $\times 500$ .

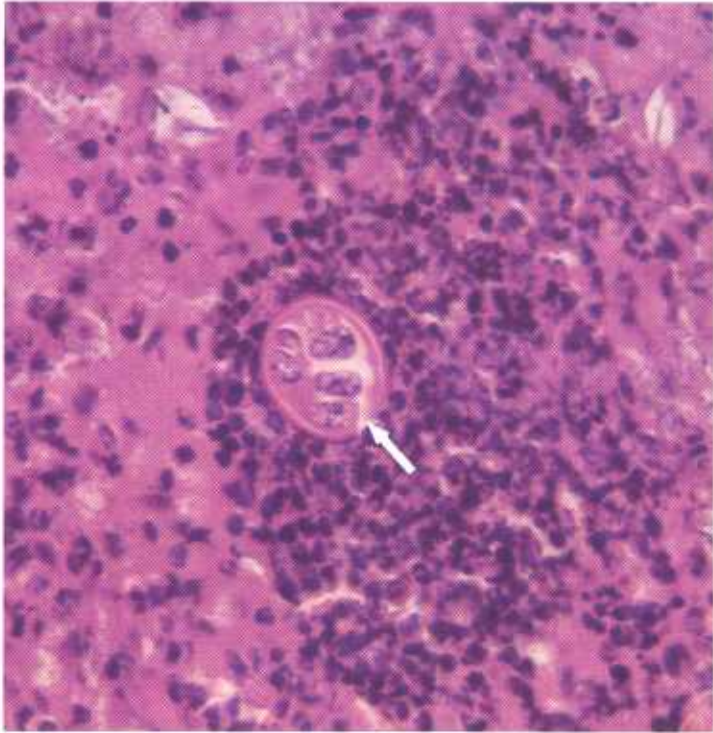

Figure 252.—Coccidioidomycosis of a bronchial lymph node in a 3-year-old steer (D2510). A spherule of *Coccidioides immitis* that contains endospores is present. A micropore (arrow) is also present. Hematoxylin-eosin stain.  $\times 500$ .

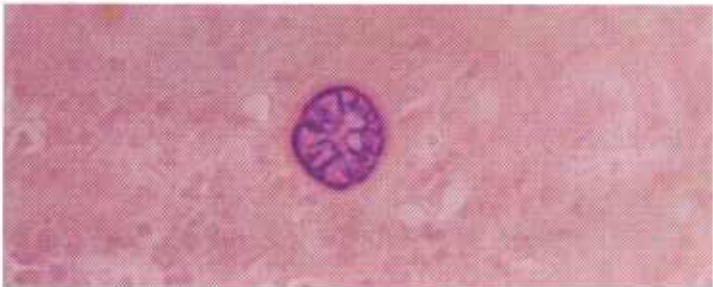


Figure 253.—Coccidioidomycosis of a bronchial lymph node in a 3-year-old steer (D2510). A spherule of *Coccidioides immitis* that contains endospores is present. Gridley fungus stain.  $\times 500$ .

and range from 5 to 50 microns in diameter. They have double-contoured walls and can be demonstrated in unstained cover slip preparations of the pus. They do not reproduce by budding and do not produce mycelia in the tissues of the host. Endospores are visible within the

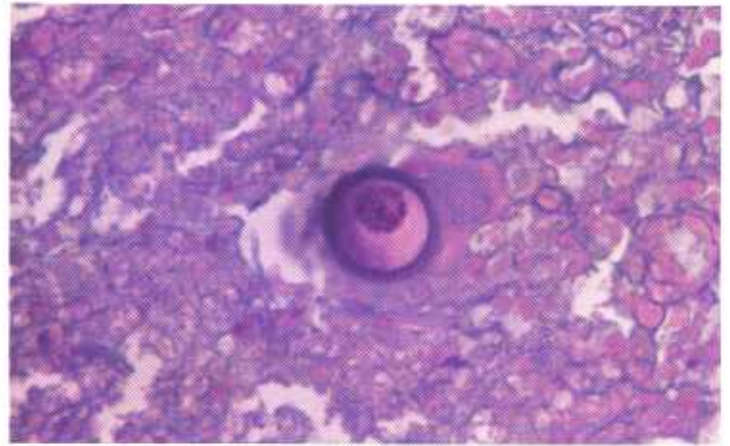


Figure 254.—Coccidioidomycosis of a bronchial lymph node in a 3-year-old steer (D2510). A spherule of *Coccidioides immitis* is present. Periodic acid-Schiff reaction.  $\times 500$ .

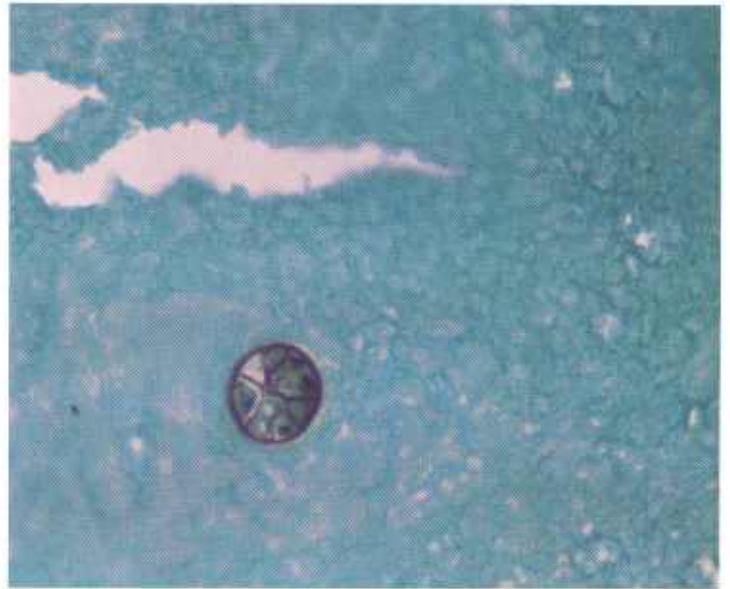


Figure 255.—Coccidioidomycosis of a bronchial lymph node in a 3-year-old steer (D2510). A spherule of *Coccidioides immitis* that contains endospores is present. Gomori's methanamine silver stain.  $\times 500$ .

spherules. The organisms (spherules) are stained with Gridley's fungus stain, periodic acid-Schiff staining reaction, Bauer-Feulgen technic, methanamine-silver staining technic, and they sometimes show a strong affinity for eosin.

## Contagious Ecthyma in Sheep and Goats

**Definition.**—Contagious ecthyma, also called infectious pustular dermatitis and soremouth, is an acute viral disease of sheep and goats that is characterized by proliferative lesions on the lips.

**Distribution and incidence.**—Contagious ecthyma occurs throughout the United States but is especially common in the Rocky Mountain region. The virus is so prevalent in most sheep- and goat-raising areas that all

lambs and kids must be vaccinated or serious losses will occur. The disease is frequently confused with sheep pox and blue tongue. As a matter of differentiation, sheep pox does not occur in the United States. Blue tongue differs from contagious ecthyma in that ulcerative lesions on the lips are not present and hyperplasia of epithelium does not occur.

The most typical lesions are found on the woolless or

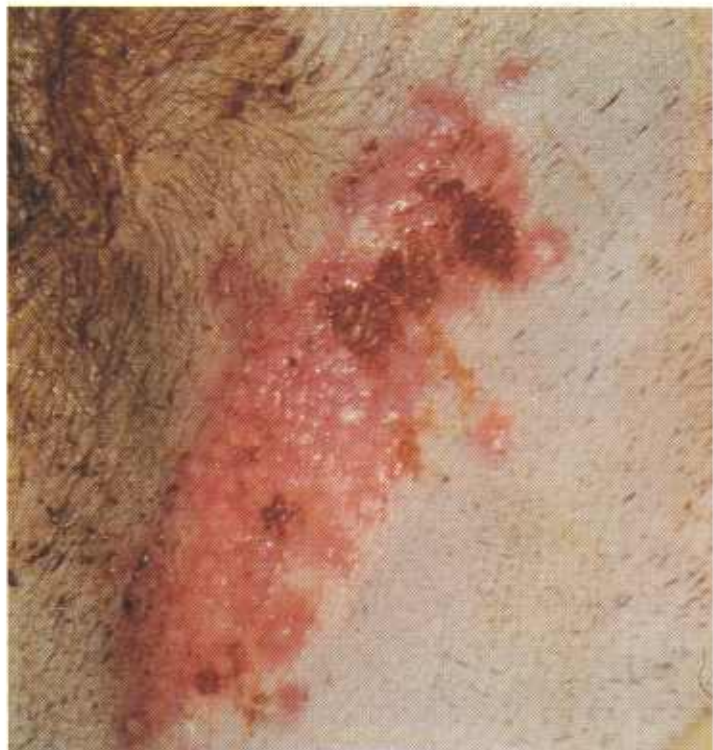

Figure 256.—Contagious ecthyma in a lamb 2 days after inoculation of the skin of the thigh (JPK100). Hyperemia and vesicular dermatitis are present.

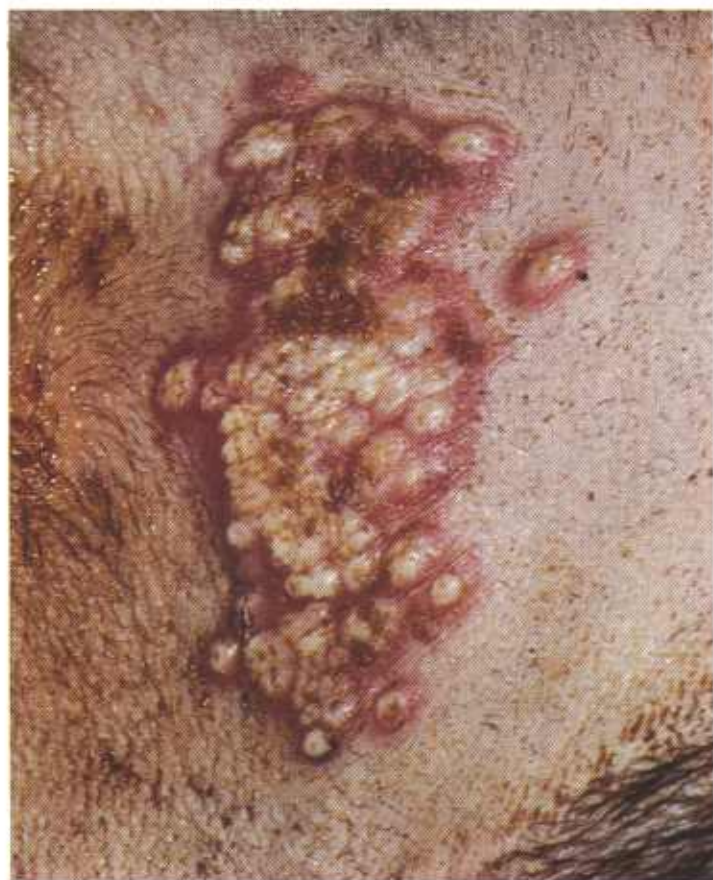

Figure 257.—Contagious ecthyma in a lamb 3 days after inoculation of the skin of the thigh (JPK100). Hyperemia and pustule formation are present.

hairless parts of the skin, such as the face, muzzle, lips, eyelids, internal surface of the ears, perianal and perivulvar regions, mammary gland, and medial surface of the thighs. Lesions involving the vulva, sheath, penis, coronet, and the soles of the feet are less commonly observed.

Oral lesions involve the cheeks, tongue, palate, and pharynx. Occasionally, when oral involvement occurs, the larynx, esophagus, rumen, reticulum, omasum, and abomasum are also involved. Inhalation pneumonia occurs when laryngeal lesions are present. When the mucosal surface is constantly bathed with saliva or fluids, diffuse necrotic inflammation of the epithelium may occur.

When contagious ecthyma involves nursing lambs, it can be transmitted to the udders of the ewes. Affected udders become so painful that the ewes will not allow their lambs to nurse. Bacteria associated with the viral lesions can invade the mammary gland and cause mastitis.

The disease usually has a duration of 3 to 4 weeks unless complications arise from bacterial or screw-worm infections. *Spherophorus necrophorus*, *Staphylococcus aureus*, and *Corynebacterium pyogenes* are common bacterial invaders of the sites of epithelial injury. Contagious ecthyma has a high morbidity but a

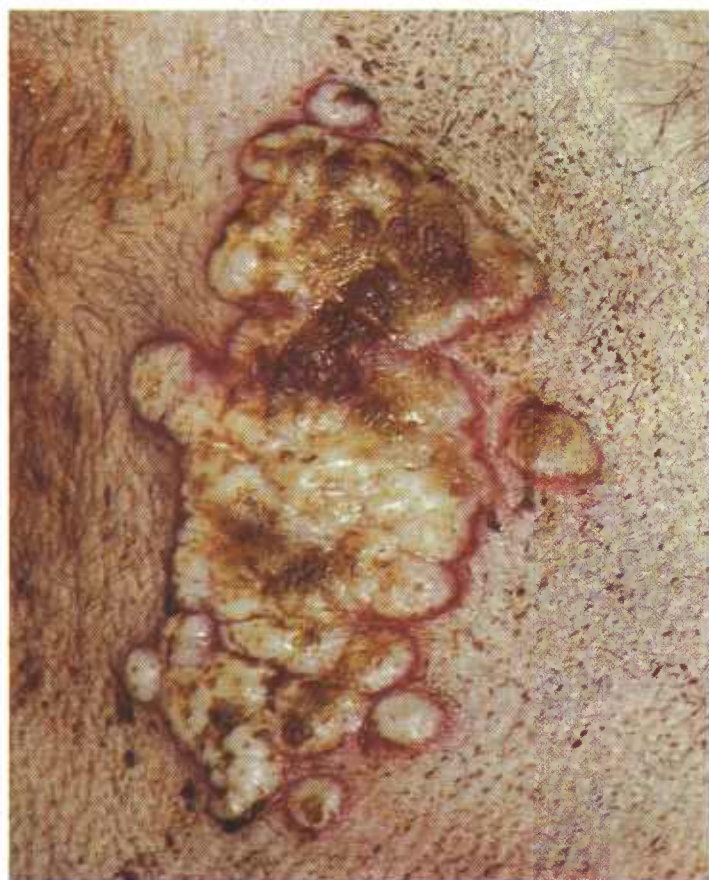

Figure 258.—Contagious ecthyma in a lamb 5 days after inoculation of the skin of the thigh (JPK100). Extensive pustule formation and beginning development of a scab are evidenced.

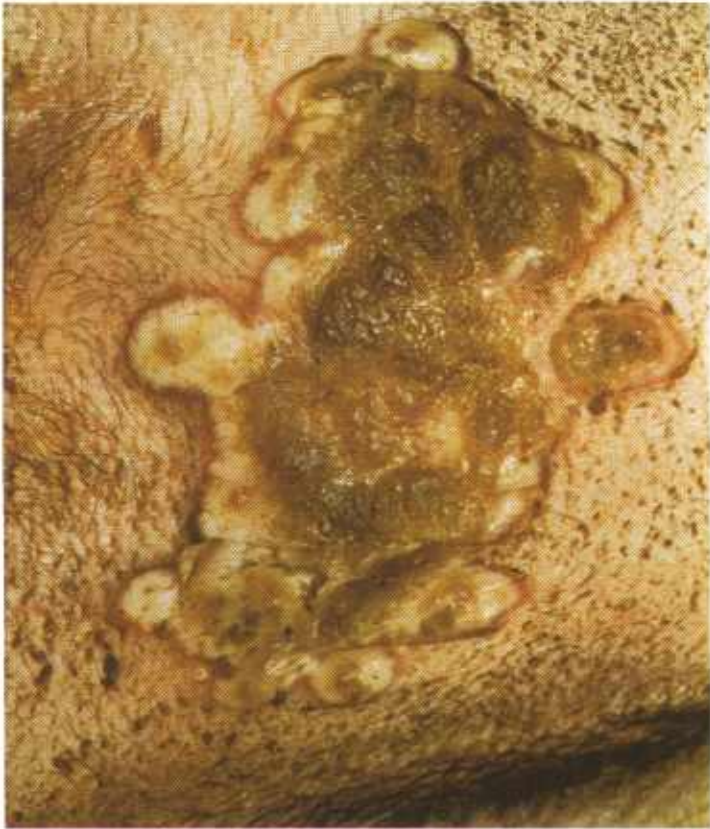

Figure 259.—Contagious ecthyma in a lamb 6 days after inoculation of the skin of the thigh (JPK100). A scab is forming in the area.

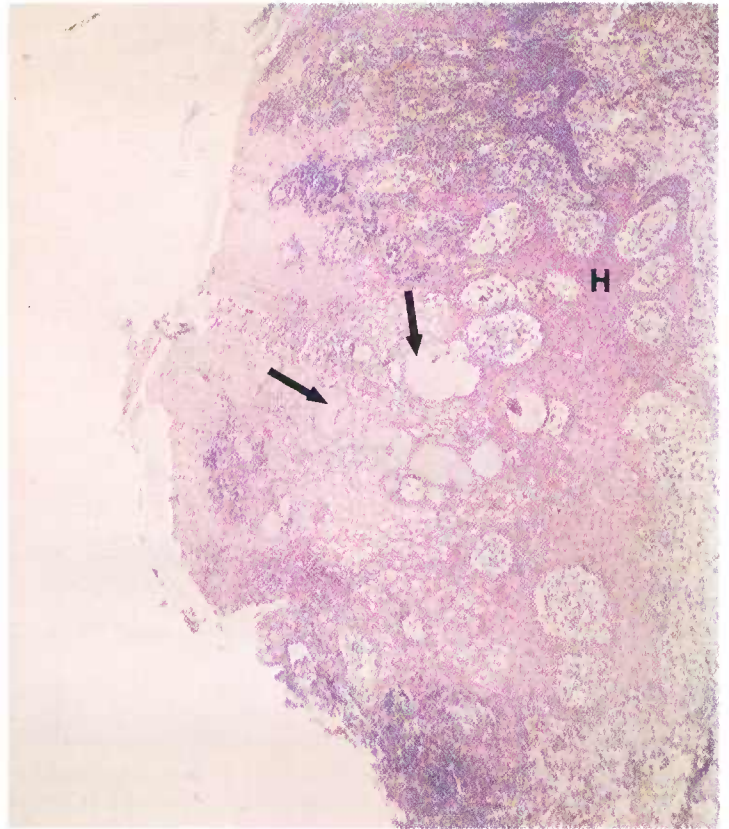


Figure 261.—Contagious ecthyma in a lamb (D424). Note the hyperplasia (H) of the epithelium and the formation of vesicles (arrows). Hematoxylin-eosin stain,  $\times 50$ .

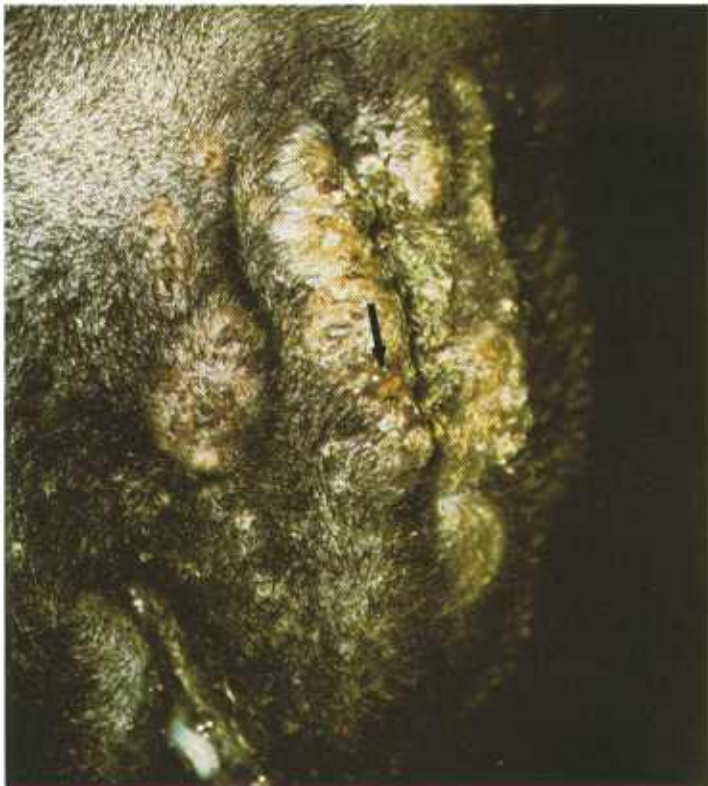

Figure 260.—Contagious ecthyma in a lamb 6 days after inoculation (JPK100). A hyperplastic and a pustular dermatitis of the lips are seen. A vesicle (arrow) can be seen protruding from the skin surface.

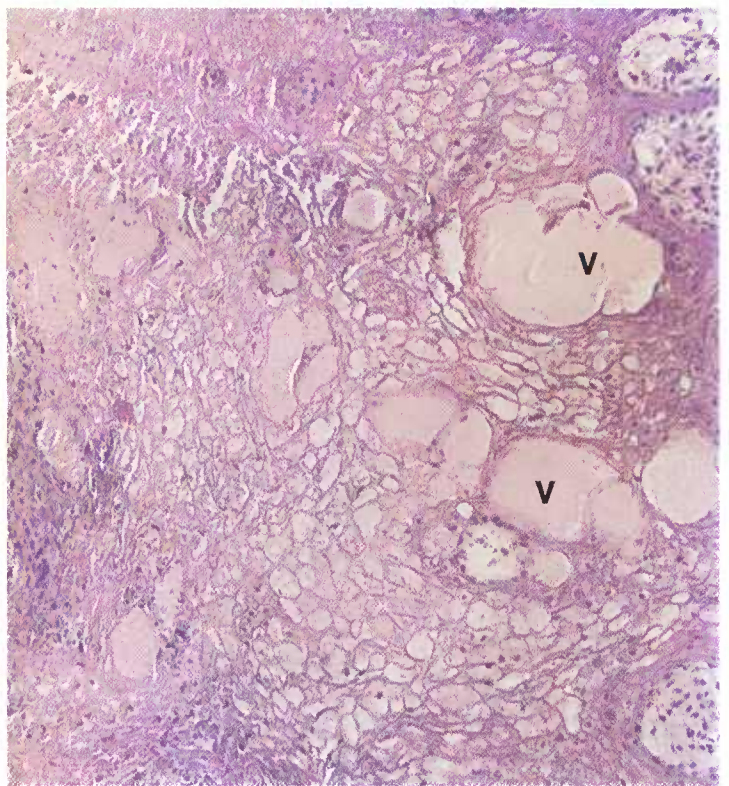


Figure 262.—A higher magnification of the histologic preparation (D424) shown in figure 261. The epithelial cells have undergone hydropic degeneration and vesicles (V) are being formed. Hematoxylin-eosin stain,  $\times 125$ .

low mortality, unless complications arise. Invasion of lesions by highly virulent organisms, infections in young lambs, adverse climatic conditions, and poor nutrition may cause severe losses. Affected animals, especially kids and lambs, lose weight and may starve to death because of their inability to eat or nurse.

**Macroscopic appearance.**—Lesions consist of focal areas of vesicle formation and epithelial hyperplasia on any squamous epithelial surface. Alterations begin with the formation of vesicles that rupture and produce ulcers. Vesicular fluid and exudate from the ulcer dries on the skin surface, forming a scab. If the scab is dislodged mechanically during feeding, bleeding of the exposed ulcer occurs. The associated epithelial hyperplasia results in the formation of large, protruding, wartlike masses.

Lesions involving stratified squamous mucous surfaces are subjected to constant mechanical injury by the passage of feed, secretions, or excretions that remove the surface exudate and delay healing. The exudate is

soft, moist, and yellowish white. The dry scab formation seen on external cutaneous surfaces does not occur since the exudate is constantly moist from mucus, secretions, and excretions.

**Microscopic appearance.**—There are two basic lesions: hydropic degeneration and epithelial hyperplasia. Hydropic degeneration involves the prickle-cell layer of the epithelium. Cells in the area swell and burst, and the escaping fluids coalesce and produce a vesicle. The vesicle eventually ruptures, producing an erosion or ulcer. Bacterial invasion of the vesicle, erosion, or ulcer results in a focal suppurative inflammation.

Epithelium in the vicinity of the vesicle is stimulated by the virus and undergoes hyperplasia, resulting in the formation of large protruding masses of tissue covered with crusts of exudate. The stratum germinativum projects long tongues of squamous cells into the underlying connective tissue. Healing occurs with no permanent alteration in the epithelium unless a severe bacterial or screw-worm infection has been present.

## Mucormycosis

**Definition.**—Mucormycosis, which is caused by *Absidia corymbifera*, is a chronic inflammatory disease that occurs most frequently in cattle and swine.

**Distribution and incidence.**—Mucormycosis occurs as a sporadic disease throughout the United States. It is observed most frequently in beef cattle in the Midwest. Dairy cattle are occasionally involved. The disease is usually found in cattle that are 6 months to 5 years of age, with the highest incidence in 1- to 2-year old feedlot cattle. Swine are not affected as frequently as cattle.

Lesions in beef cattle are found in the lungs and in the bronchial, mediastinal, and mesenteric lymph nodes. When lung lesions are present, alterations are usually found also in the bronchial and mediastinal lymph nodes. Animals with pulmonary infections tend to be in poor condition. Lesions in swine most commonly involve the intestine and the mesenteric lymph nodes. The involvement of the bronchial, mediastinal, and mesenteric lymph nodes indicates that the portals of entry are the respiratory and digestive tracts.

The disease has been observed in dairy cattle as a mycotic infection of the placenta and as a cause of abortion.

**Macroscopic appearance.**—The basic lesion is a chronic focal caseous inflammation. Individual lesions are yellow; they contain a granular caseous type of exudate and are partly calcified. Fibrosis of the area is minimal and the lesion is usually enclosed within a rather thin connective tissue capsule. Gross lesions cannot be distinguished from the alterations associated with tuberculosis, and they also closely resemble some neoplastic processes.

The most characteristic alterations of mucormycosis occur in the placentome (caruncles and cotyledons of the placenta and the uterus). The caruncles and cotyle-

dons are greatly enlarged, edematous, and necrotic, and they are separated with great difficulty because of the inflammatory reaction that is present. Necrosis begins in the periphery of the placentome and gradually invades the structure. The area where active invasion is occurring is very hyperemic and contains areas of hemorrhage. The necrotic part of the placentome has a grayish-red appearance. When the entire placentome is ne-

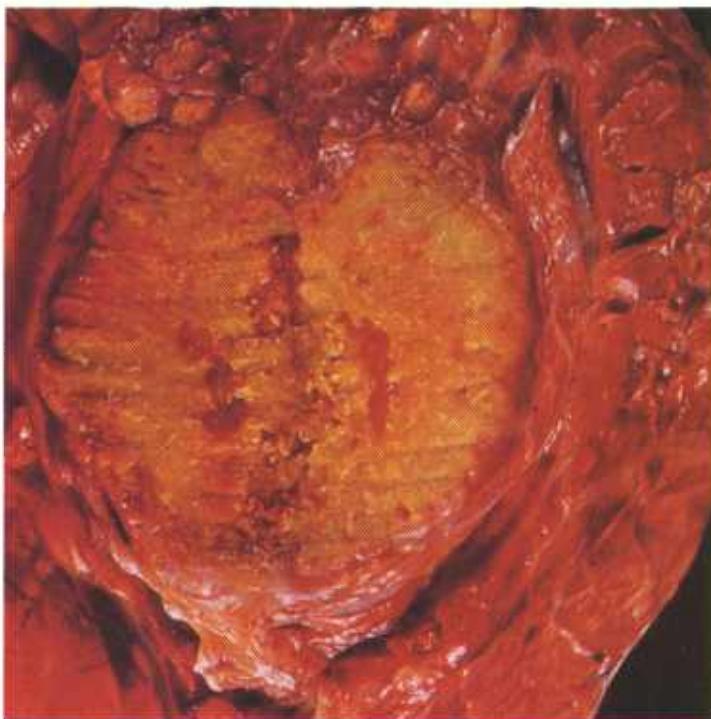


Figure 263.—Mucormycosis of the lung of a 2-year-old Hereford heifer (C49-D3555). Multiple yellow, necrotic, partially calcified foci are present in the lung.

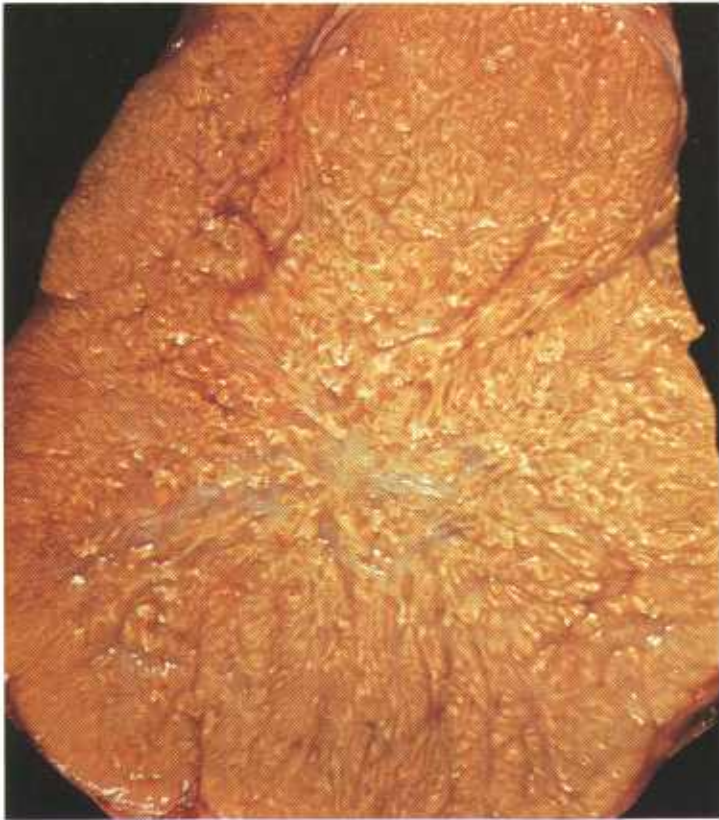

Figure 264.—Mucormycosis of a lymph node in the thoracic cavity of an old cow (C60-D3612). The node consists of a firm yellow mass of necrotic tissue that is partially calcified.

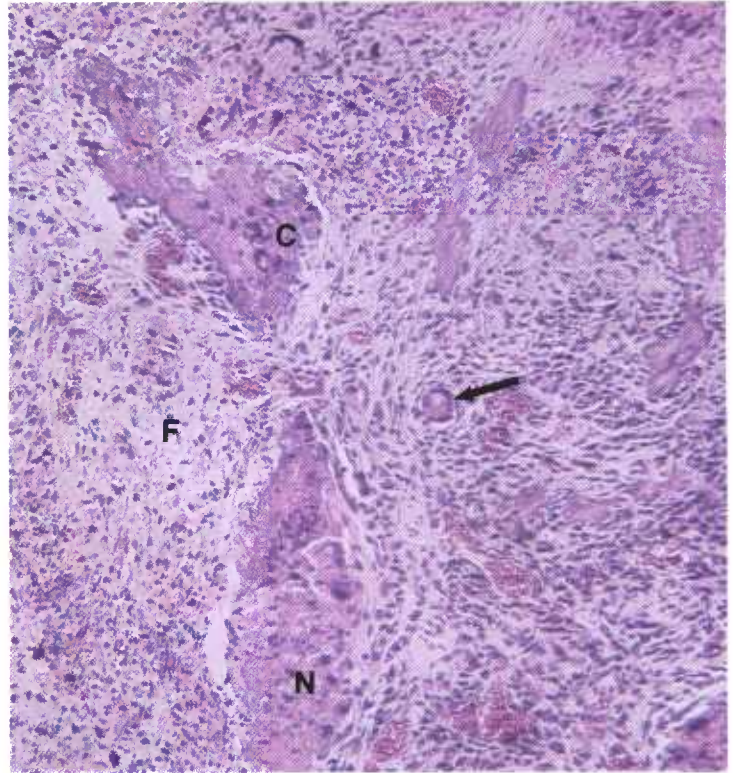


Figure 266.—A histologic preparation of the lung (C49-D3555) shown in figure 263. The typical histologic alterations—necrosis (N), calcification (C), fibrosis (F), and giant cell formation (arrow)—associated with mucormycosis are present. Hematoxylin-eosin stain.  $\times 125$ .

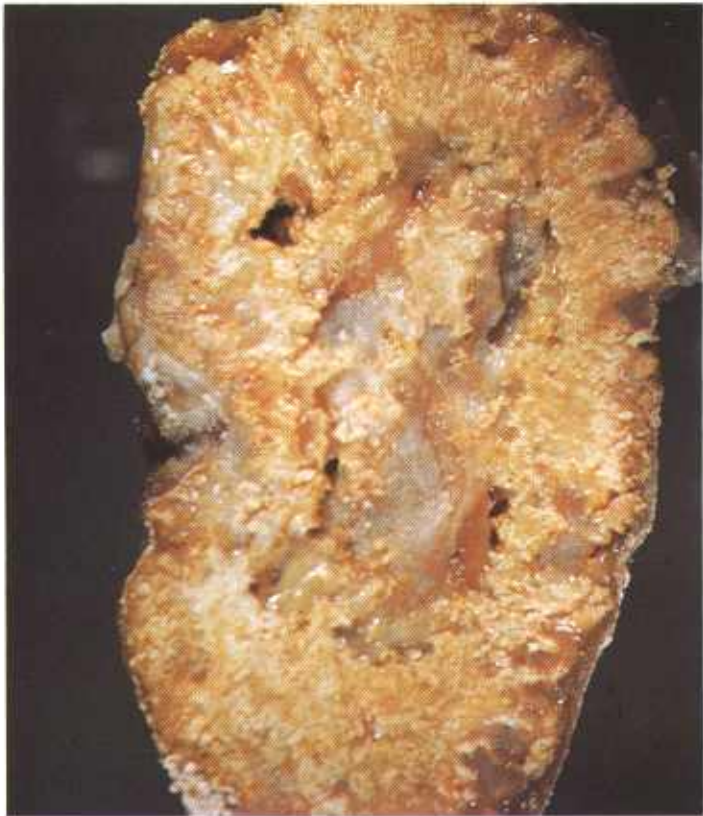

Figure 265.—Mucormycosis of a mediastinal lymph node in a 3-year-old steer (C14-D1660). The lymph node consists of a grayish-yellow necrotic mass that is extensively calcified.

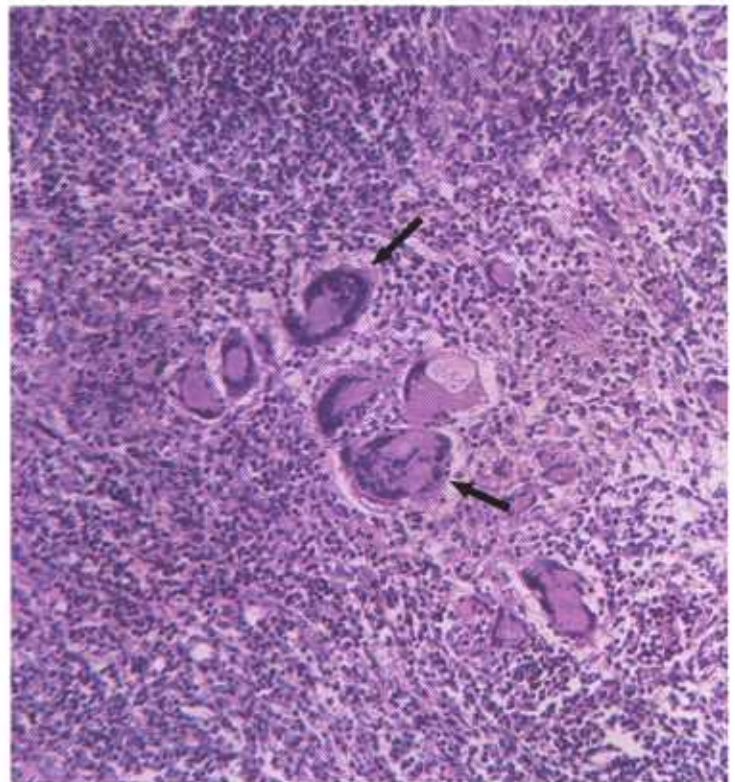


Figure 267.—A histologic preparation of mucormycosis of the mesentery in an 18-month-old steer (D2812). Several giant cells (arrows) are present in the chronic inflammatory tissue. Hematoxylin-eosin stain.  $\times 125$ .

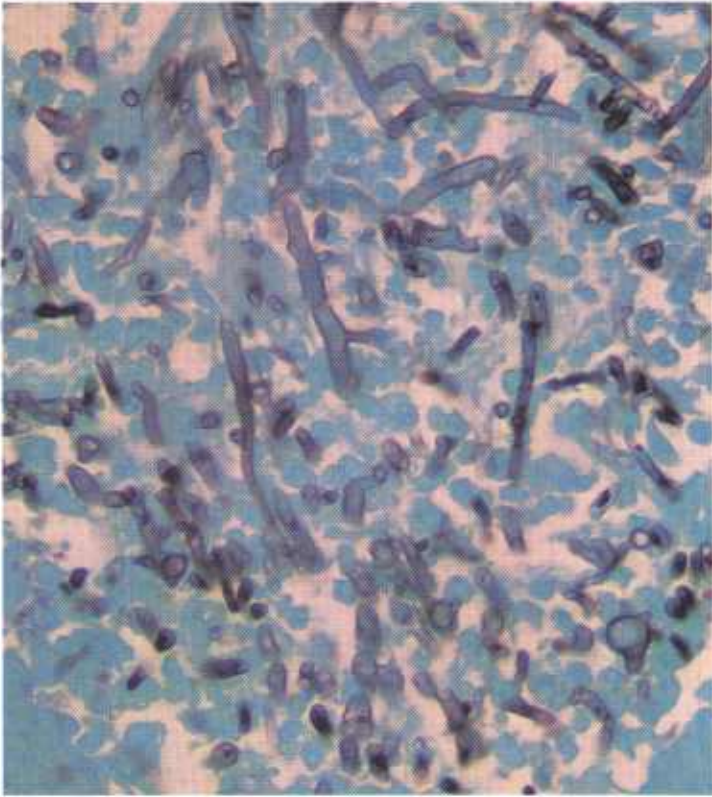


Figure 268.—A histologic preparation of the mucormycosis specimen (D2812) shown in figure 267. The black-staining structures are the mycelium of the fungus. Gomori's methanamine silver stain.  $\times 500$ .

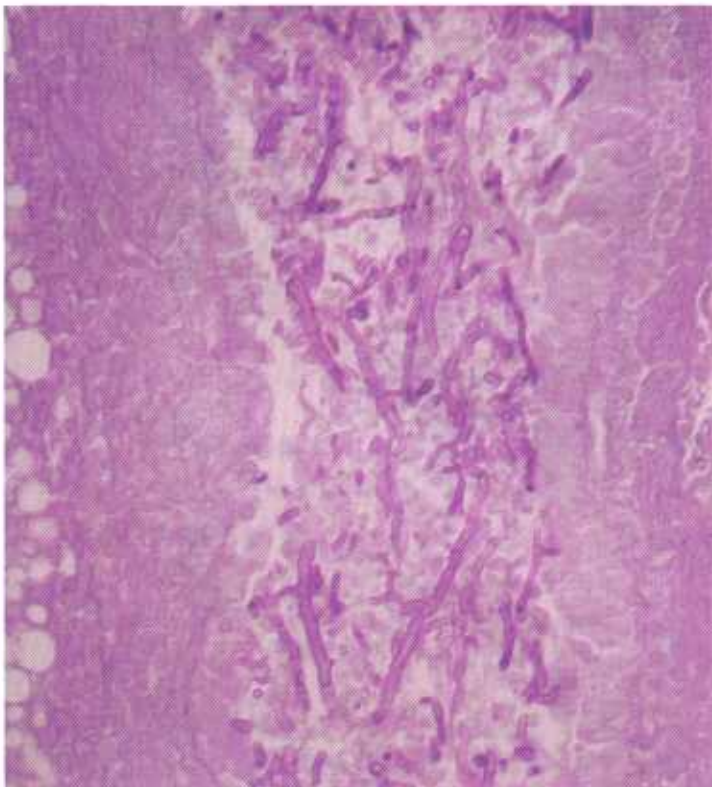


Figure 269.—A histologic preparation of the mucormycosis specimen (D2812) shown in figures 267 and 268. The red-staining structures are the mycelium of the fungus. Periodic acid-Schiff reaction.  $\times 320$ .

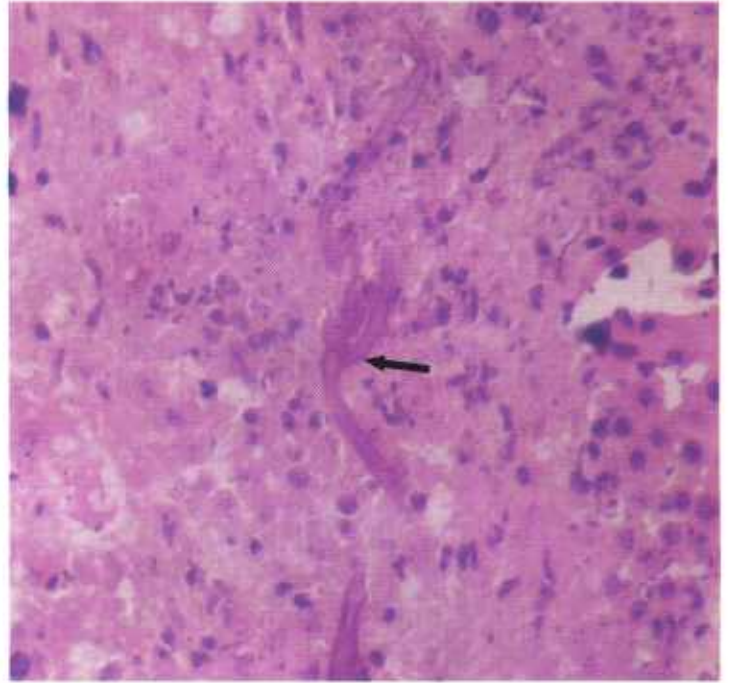


Figure 270.—A histologic preparation of the placenta of a cow (02839). The red-staining structures (arrow) are the mycelium of the fungus. Hematoxylin-eosin stain.  $\times 500$ .

crotic, it detaches easily from the uterine wall. The swollen margins of the placentome surrounding the stump of the caruncle gives the placentome a craterlike appearance. A reddish-gray exudate containing flakes of pus is found in the interplacentome space.

**Microscopic appearance.**—The principal alteration in the lungs and lymph nodes is a chronic caseous type of inflammation with the macrophage being the main cellular constituent of the exudate. Giant cells are numerous, lymphocytes, neutrophils, and plasma cells are present, and occasionally, numerous eosinophils are found. Calcification of the caseous exudate is usually present. Proliferation of connective tissue is usually not as great as in tuberculosis.

Alterations in the placentome are more acute than those found in other organs, such as the lungs and lymph nodes. Abortion occurs before the lesions can develop into the same state of chronicity that they reach in the lungs or lymph nodes. Macrophages are the principal cells of the exudate. The necrotic alteration is coagulative rather than caseous.

Throughout the lesion, in both the necrotic and non-necrotic areas, thick, branching, nonseptate hyphae of *A. corymbifera* can be found. Many of the giant cells contain such hyphae.

A diagnosis of mucormycosis should not be made unless the presence of the organism can be demonstrated histologically in typical lesions and its presence confirmed by isolation and identification of the organism in pure culture. The reason for this is that the organism is commonly found in nature and in laboratory surroundings and may contaminate culture media.

## Nasal Granuloma of Cattle

**Definition.**—Nasal granuloma of cattle is a chronic infectious disease of the nasal passages caused by one or several fungi. A *Helminthosporium* is one of the organisms that has etiologic significance.

**Distribution and incidence.**—The disease is found in Southwestern and Gulf States and is most frequently observed in Louisiana and Texas. It appears in cattle that are 18 months of age or older. Clinical signs of the disease are most severe during warm weather. The disease is not fatal and does not produce debility, and affected animals often recover spontaneously.

**Macroscopic appearance.**—Lesions consist of proliferative growths in the subepithelial tissues of the nasal passages. The alterations first appear as nodules that measure 1 to 2 mm. in diameter and protrude from the nasal mucosa. Individual nodules may enlarge and become as much as 1 to 6 cm. in diameter. If many nodules are present, they may become confluent and then appear as a diffuse infiltration of the nasal mucosa.

The alterations first appear in the anterior part of the nasal passages; later, the most severe lesions are found in this region. As the disease progresses, the more

posterior parts of the nasal cavity become involved until about two-thirds of the total mucosal surface is affected. Both nasal passages are usually affected, but one side may show greater involvement than the other. The septal mucosa is usually more extensively involved than the turbinate part. Lesions are not observed in the nasal sinuses or in other parts of the respiratory tract. The mass of proliferating tissue protruding into the lumen of the nasal passages seriously interferes with the tidal air flow. Because of this respiratory obstruction, cattle (especially when exercised) become dyspneic and produce snoring sounds. Affected cattle rub their noses on objects in their vicinity, sneeze, and eliminate a yellow nasal discharge.

The growths are rather soft in consistency and are quite vascular. They occur in the subepithelial region and do not invade the underlying tissues, nasal septum, and turbinate bones. Their surfaces are usually covered with epithelium, but occasionally the surfaces of the larger lesions are ulcerated. These growths are frequently confused with nasal neoplasms and amyloidosis.

Nasal growths are a mottled red and green. The red

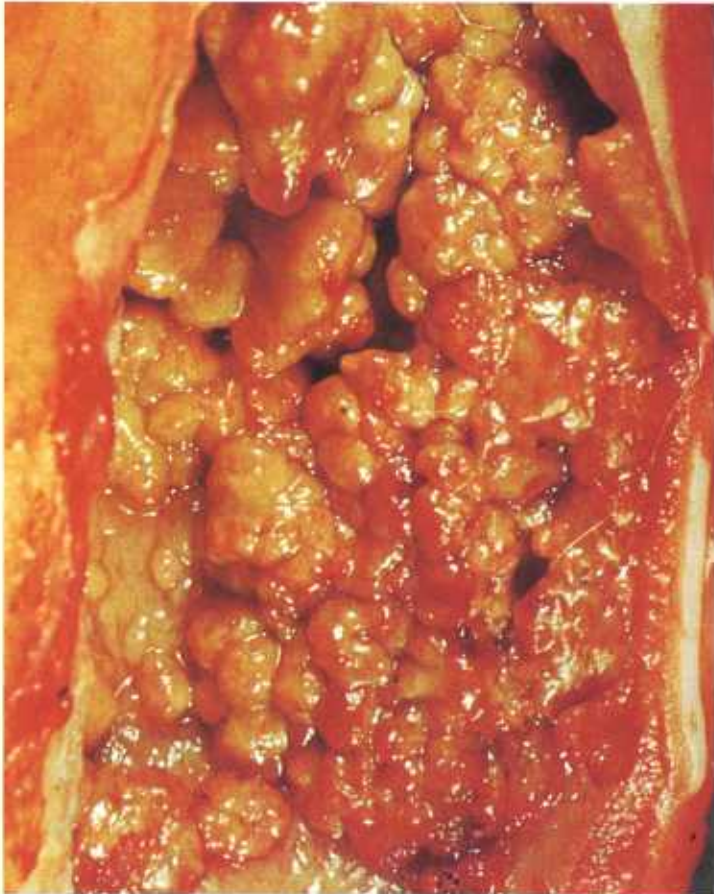

Figure 271.—Nasal granuloma of a 5-year-old cow (C10-D1544). Multiple yellowish-green nodules that contain focal areas of hyperemia and hemorrhage are protruding from the mucosa of the nasal passages.

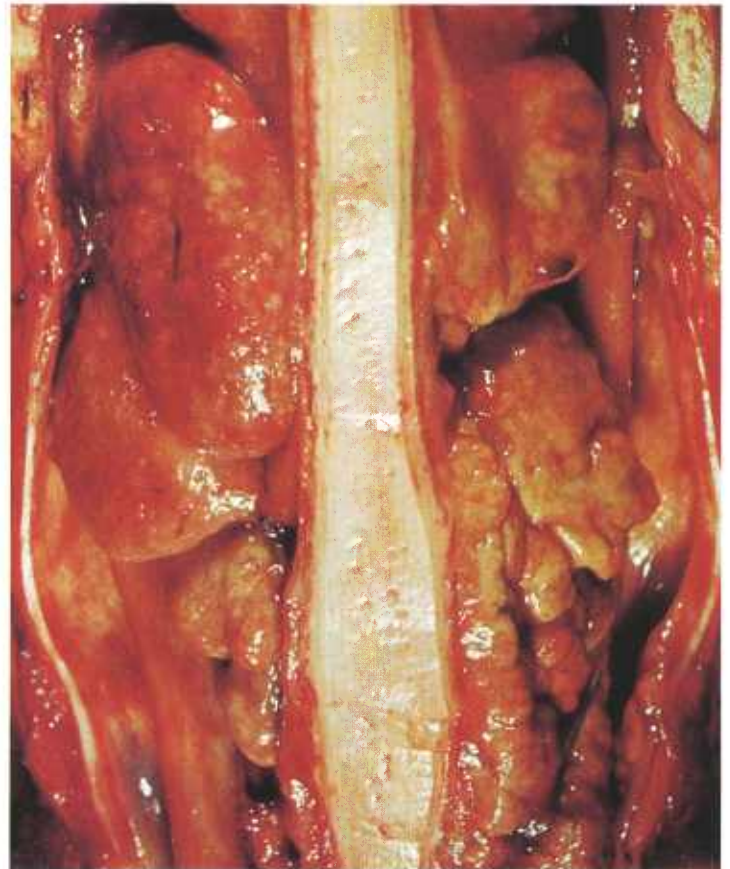


Figure 272.—Nasal granuloma of a 10-year-old cow (C21-D2413). Multiple yellowish-green nodules that contain focal areas of hyperemia and hemorrhage are protruding from the mucosa of the nasal passages. Most of the nodules are attached to the nasal septal mucosa.

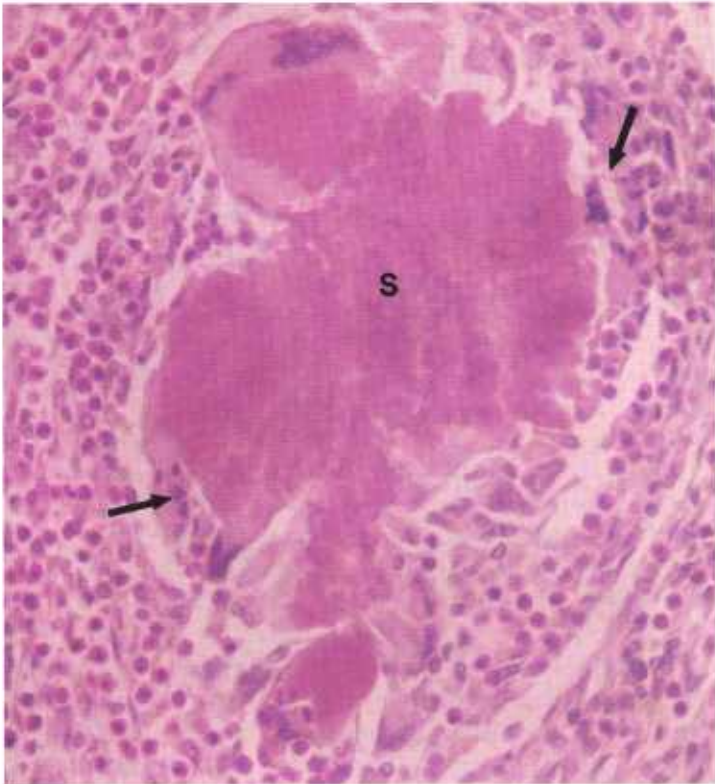


Figure 273.—A histologic preparation of the nasal granuloma (C21-D2413) shown in figure 272. A “sulfur granule” (S), similar to that seen in actinobacillosis, is bordered by giant cells (arrows), and all are surrounded by chronic inflammatory tissue that contains many eosinophils. Hematoxylin-eosin stain.  $\times 320$ .

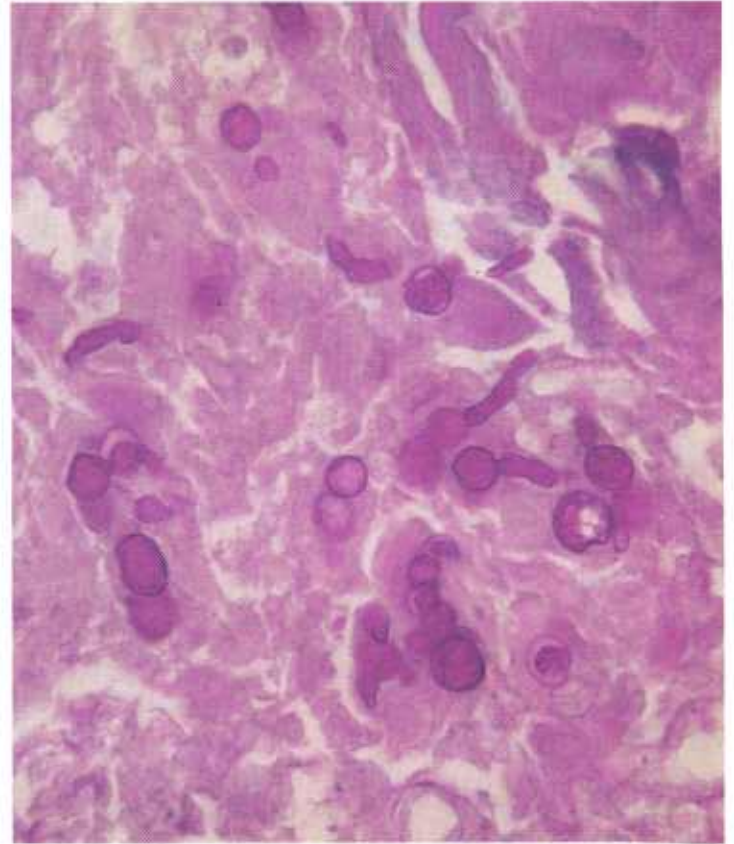


Figure 275.—A histologic preparation of the nasal granuloma (C21-D2413) shown in figure 272. The photograph shows various forms of the organism that are found in affected tissues. Periodic acid-Schiff reaction.  $\times 500$ .

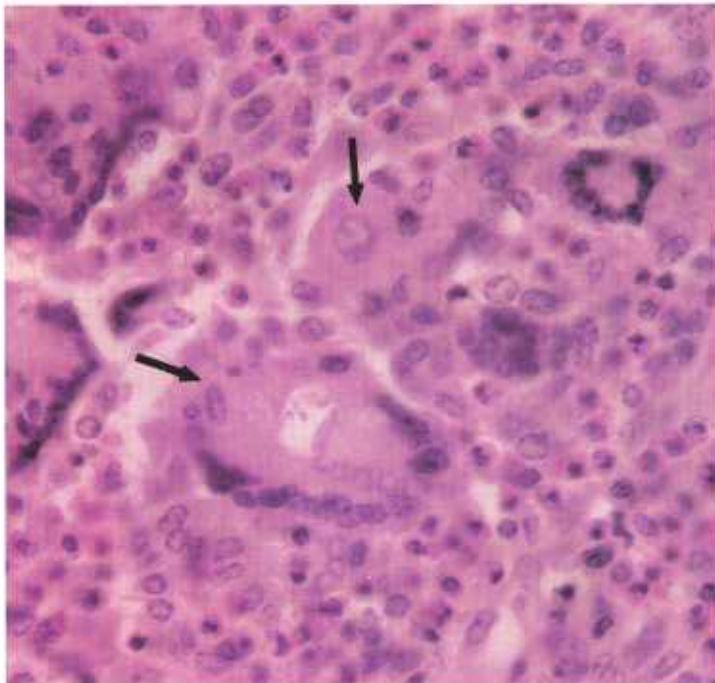


Figure 274.—A histologic preparation of the nasal granuloma (C21-D2413) shown in figure 272. The photograph shows a chronic inflammatory type of tissue reaction in which macrophages, giant cells, and eosinophils are the principal cellular constituents of the exudate. Several of the giant cells contain organisms (arrows). Hematoxylin-eosin stain.  $\times 500$ .

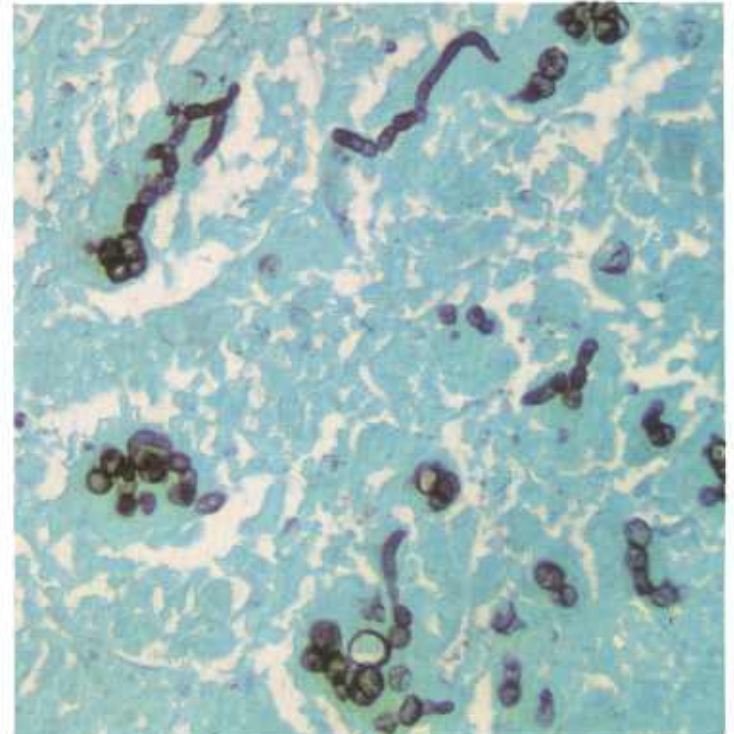


Figure 276.—A histologic preparation of the nasal granuloma (C21-D2413) shown in figure 272. The photograph shows various forms of the organism that are found in affected tissues. Gomori's methanamine silver stain.  $\times 320$ .

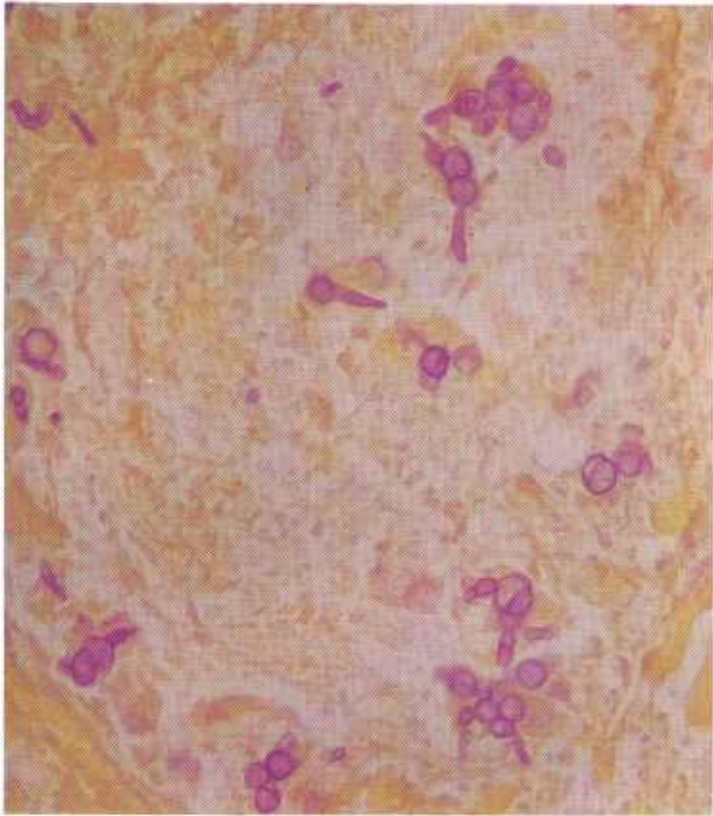


Figure 277.—A histologic preparation of the nasal granuloma (C21-D2413) shown in figure 272. The photograph shows various forms of the organism that are found in affected tissues. Gridley fungus stain.  $\times 320$ .

is due to hyperemia, and the green is the result of the disintegration of hemoglobin and the presence of many eosinophils.

**Microscopic appearance.**—The basic microscopic alteration is a chronic suppurative inflammation. Cellular exudate consists of macrophages, giant cells, lymphocytes, neutrophils, and many eosinophils. The entire lesion is diffusely infiltrated with hyperplastic white fibrous connective tissue.

Most of the growth is covered with hyperplastic epithelium. A few ulcers are found in the surface epithelium, and the tissues in the vicinity of the ulcers are infiltrated with neutrophils in response to the presence of bacteria.

Spherical chlamydospores of varying sizes, which may contain brown pigment, and a few septate hyphae are found throughout the lesion. The chlamydospores measure about 15 microns in diameter and the hyphae measure approximately 4 microns. They are usually found in giant cells or clumps of macrophages. One or several chlamydospores, together with hyphae, may be contained within a single giant cell. A few rosettes containing chlamydospores and hyphae, similar to those of actinobacillosis, are found in an occasional animal.

The organism has difficulty in producing hyphae in tissues. Budlike structures, pointed projections, and various bizarre objects are found attached to the chlamydospores. These represent an abortive attempt by the organism to produce mycelium.

## Necrobacillosis

**Definition.**—Necrobacillosis is a coagulative necrosis of tissue caused by *Spherophorus necrophorus*.

**Distribution and incidence.**—Necrobacillosis is found throughout the United States but is most frequently observed in the Rocky Mountain area. All meat-producing animals are affected. The role of *S. necrophorus* as the primary cause of the lesion in which it is found has never been established. The organism is considered to be a wound contaminant that grows in the necrotic tissue of the injury and produces a potent toxin causing coagulative necrosis of the surrounding tissue. Regional lymph nodes are seldom involved.

*S. necrophorus* is a common complication of necrotic enteritis, castration-wound infections, and rhinohyperplasia (bull nose) in swine. In lambs, it is associated with foot rot, contagious ecthyma, hepatic necrobacillosis, and umbilical infections. The organism is associated with a variety of diseases in cattle, including foot rot, calf diphtheria, hepatic abscesses, necrotic pneumonia, virus diarrhea, and vesicular stomatitis.

In the Rocky Mountain States, hepatic necrobacillosis is a common cause of liver condemnations in cattle. Eight percent of the livers of cattle inspected by the USDA are condemned because of this disease. These hepatic lesions apparently arise as metastases from pri-

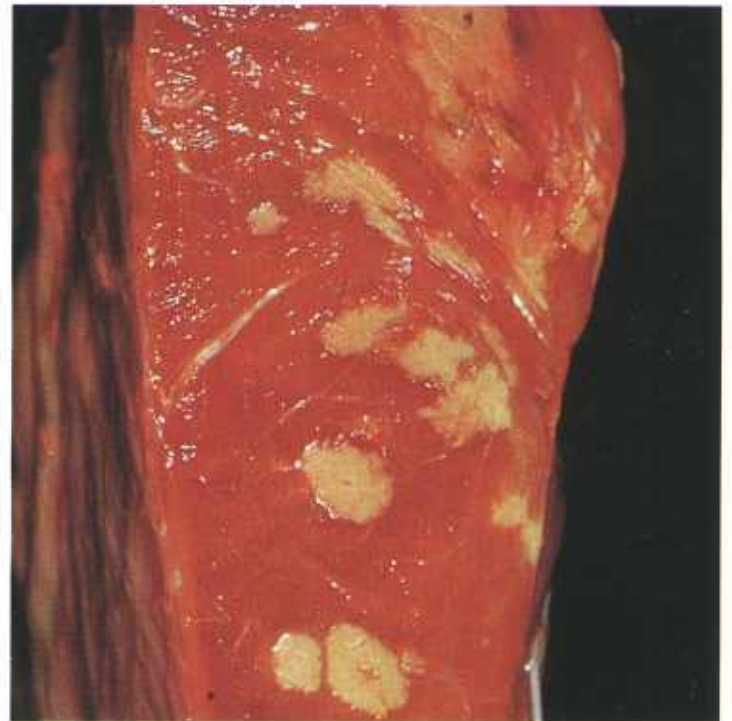

Figure 278.—Necrobacillosis of the heart of an 8-year-old Hereford cow (B155-D2827). Multiple buff-colored foci of coagulative necrosis are present in the myocardium.

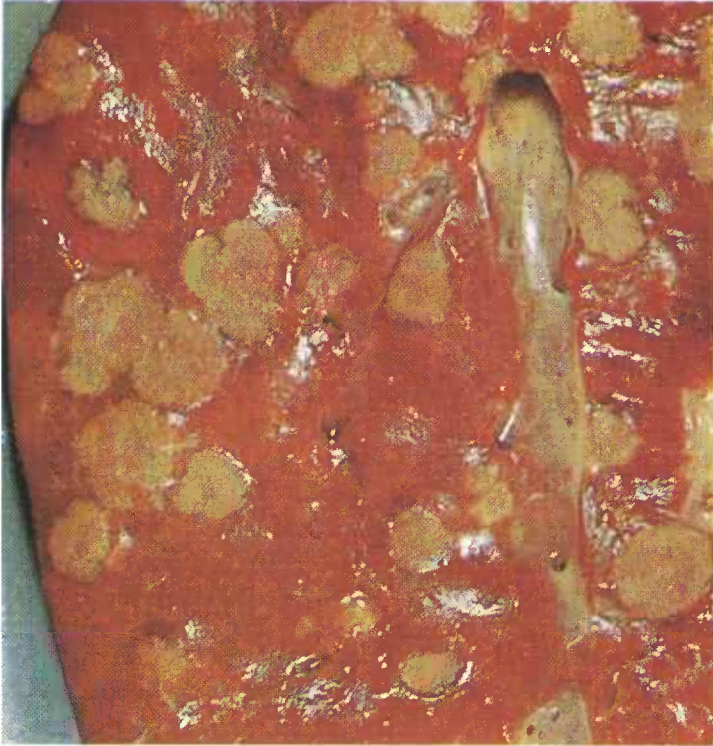

Figure 279.—Necrobacillosis of the liver of a 2-year-old steer (B8-127054). Multiple yellowish-gray areas of coagulative necrosis are present in the liver. Note that no zone of inflammation is visible around the necrotic areas.

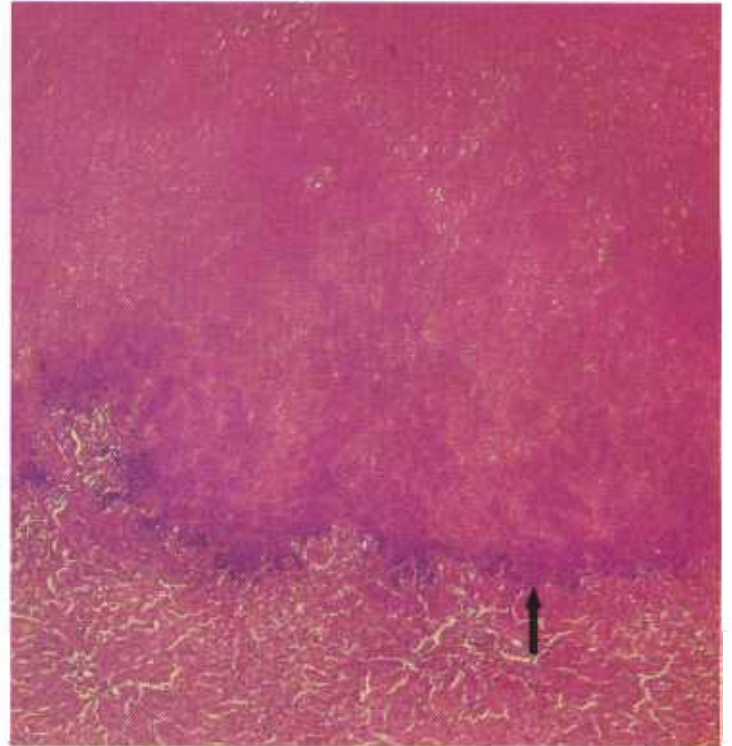


Figure 281.—Necrobacillosis of the liver of an old ewe (D2244). A narrow zone (arrow) of inflammation separates an area of coagulative necrosis from the normal liver parenchyma. Hematoxylin-eosin stain,  $\times 50$ .

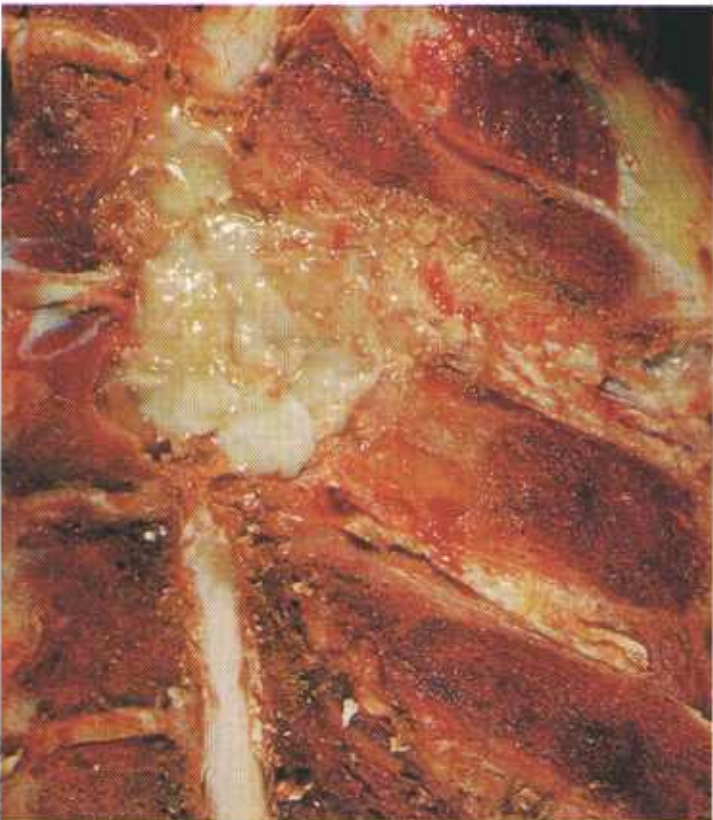

Figure 280.—Necrobacillosis of the first and second thoracic vertebrae in a 6-month-old calf (B138-130413). The abscess has invaded the bodies and spinal processes of the vertebrae and the vertebral canal.

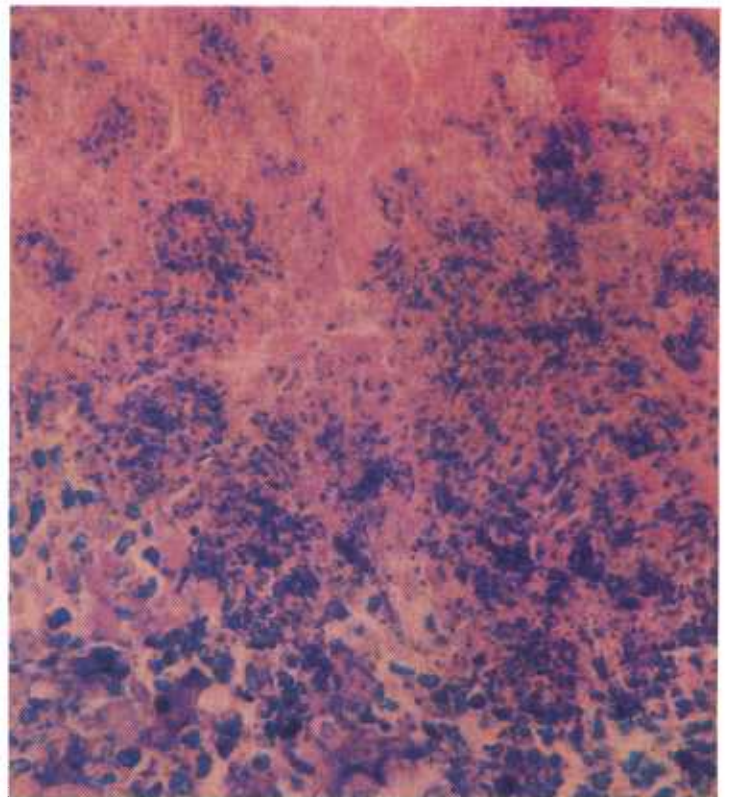


Figure 282.—Necrobacillosis of the liver of an old ewe (D2244). Many blue-staining organisms can be seen in the photograph. The preparation is from the periphery of a necrotic area adjacent to a zone of inflammation between the living and dead liver tissue. Giemsa stain,  $\times 500$ .

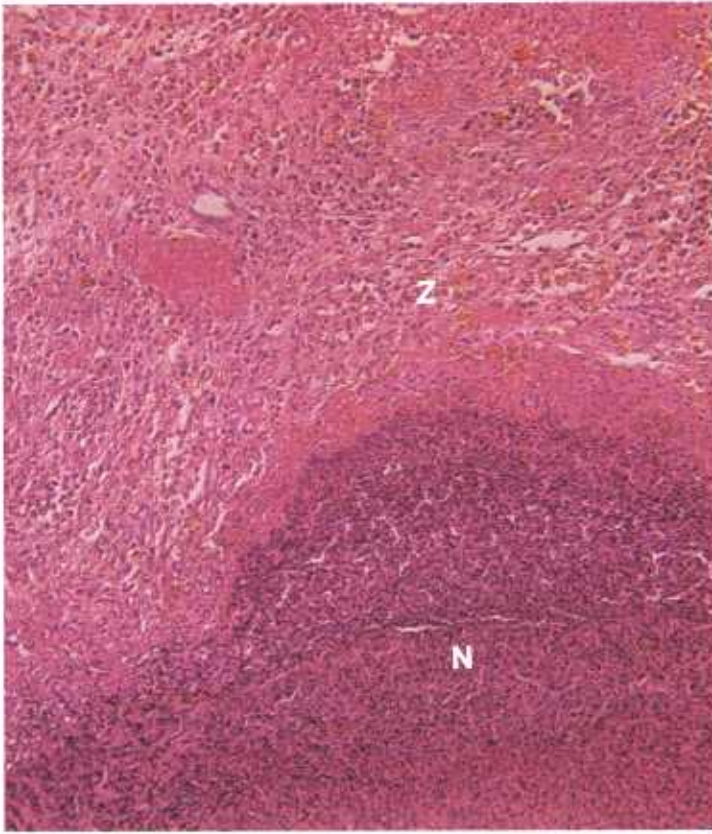


Figure 283.—Necrobacillosis of the spleen of an 8-year-old Hereford cow (D2827). The necrotic tissue (N) is undergoing liquefaction and has been infiltrated with lymphocytes, macrophages, and neutrophils. A zone (Z) of chronic inflammatory tissue composed of connective tissue, capillaries, and leukocytes is adjacent to the mass of necrotic tissue. Hematoxylin-eosin stain.  $\times 125$ .

mary lesions in the stomach, intestine, or umbilicus.

**Macroscopic appearance.**—The basic lesion in necrobacillosis consists of a white or buff area of coagulative necrosis separated from the living tissue by a narrow zone of inflammation. In older lesions, the area of necrosis becomes enclosed within a zone of connective tissue. Eventually, the necrotic tissue undergoes liquefaction that begins in the periphery of the lesion and progresses towards the center. As liquefaction occurs, the necrotic tissue becomes slightly green and tenacious in consistency.

**Microscopic appearance.**—When the organisms first enter the tissue, neutrophils collect around them. Soon the toxin produced by the bacteria causes necrosis of leukocytes and other cells or tissues in their immediate vicinity. As the organisms multiply and produce additional toxin, the area of necrosis gradually enlarges in a peripheral direction. The inflammatory reaction of the host to the presence of *S. necrophorus* is slight in comparison with the extent of damage produced. As the lesion ages, the acute inflammatory reaction in the periphery of the necrotic tissue becomes chronic. Connective tissue and capillaries develop in the zone of inflammation, and the zone becomes infiltrated with lymphocytes, macrophages, and a few neutrophils. Giant cells are seldom observed, but calcification of the necrotic tissue is occasionally present.

*S. necrophorus* is most abundant in the periphery of the necrotic tissue adjacent to the zone of inflammation. The organism is Gram-negative, nonspore forming, and has a beaded filamentous appearance. It is readily demonstrated in the lesions.

## Nocardiosis

**Definition.**—Nocardiosis is a chronic infectious disease that is caused by *Nocardia asteroides*.

**Distribution and incidence.**—The disease occurs as a sporadic infection throughout the United States. All meat-producing animals are affected.

Nocardiosis occurs as a chronic suppurative inflammation that involves the mammary gland, lungs, lymph nodes, skin, and occasionally other organs. Although the disease is infectious, it is not contagious and is usually the result of the contamination of wounds with soil or the use of dirty equipment in the treatment of wounds or mastitis.

The mammary gland is the most frequently affected organ because the organism is introduced into the gland by dirty teat tubes or contaminated intramammary infusion fluids and equipment. The infection involves all ages of lactating animals. Nearly all of the mammary infections occur between the last month of gestation and the second month of lactation, with the greatest incidence occurring 2 to 10 days after parturition.

**Macroscopic appearance.**—There is an acute multiple-focal suppurative mastitis in the early stages of the dis-

ease. Lesions in the mammary gland vary in size from those that are just visible to others that measure 5 cm. in diameter. As the disease progresses, a chronic multiple-focal suppurative type of inflammation develops. The mammary exudate is white and viscous, and it often contains blood clots and small white granules that measure 1 mm. in diameter. Microscopically, these granules are composed of masses of organisms.

The inflammatory reaction often penetrates the skin of the mammary gland and forms sinus tracts that drain onto the skin surface of the udder. The mucous membrane of the teat sinus, gland cystem, and collecting ducts is greatly thickened and granular in appearance. The lesions are most severe in the ventral part of the mammary gland, an indication that the infection is of an ascending type and enters the udder through the teat.

Metastatic lesions are present in other organs. The supramammary and internal inguinal lymph nodes are enlarged and contain multiple-focal areas of chronic suppurative inflammation. Multiple-focal lesions, measuring 1 to 2 mm. in diameter, are found in the lungs. Multiple

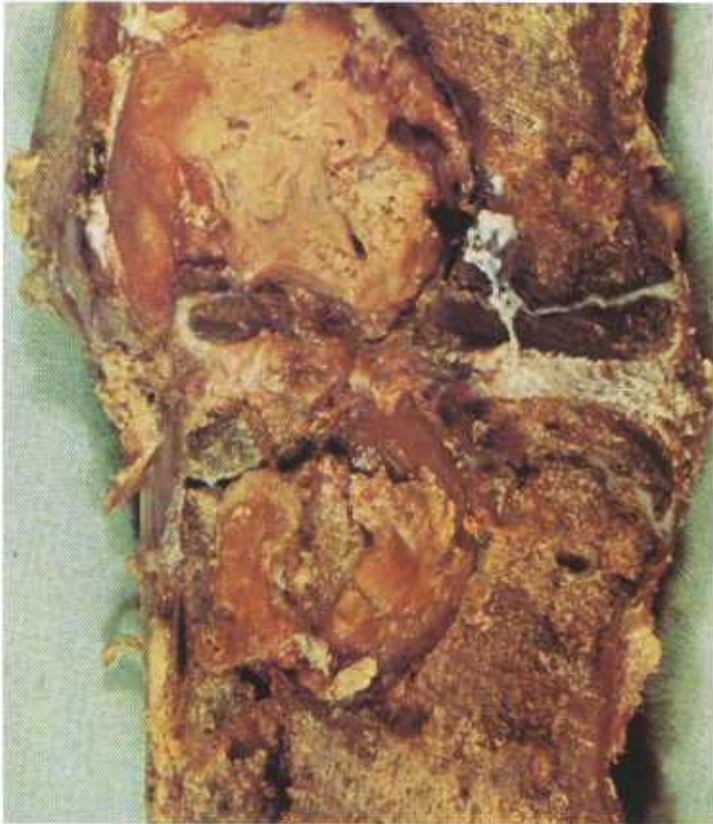

Figure 284.—Nocardial spondylitis of the third and fourth lumbar vertebrae of a 2-year-old steer (C2-D1077).

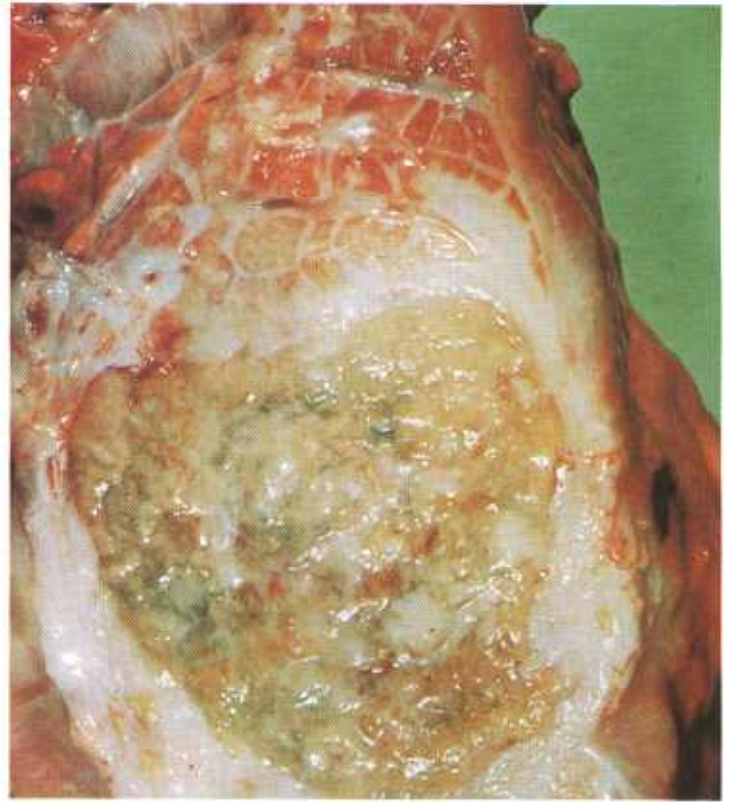


Figure 286.—Nocardial abscess in the lung of a 7-year-old bull (C19-D1916). Note the green pus and the thick connective tissue capsule that encloses the abscess.

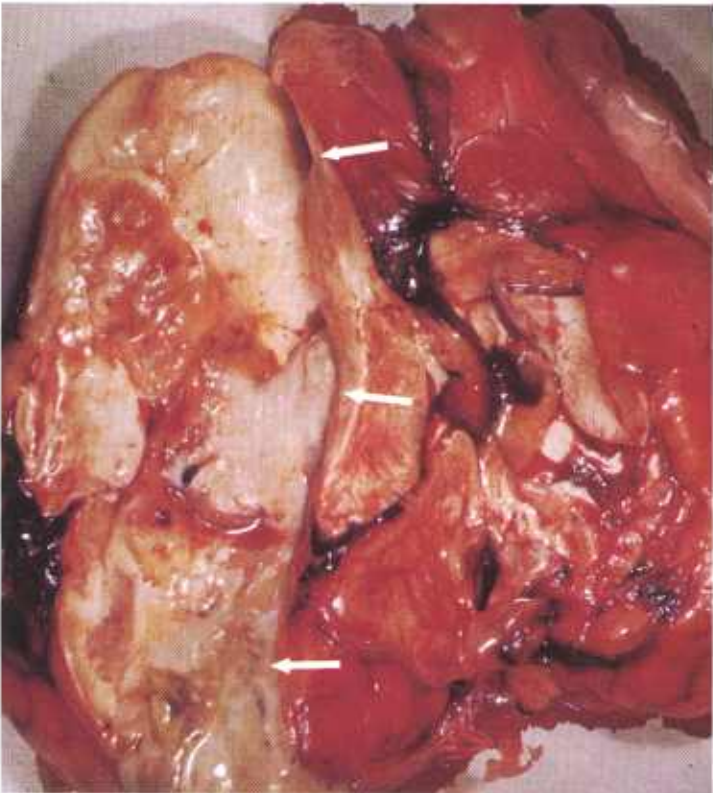


Figure 285.—Nocardial abscess (arrows) in the brain of a cow (C5-128479). Abscesses are present in the lungs and the brain abscess presumably represents a metastasis from the pulmonary lesions.

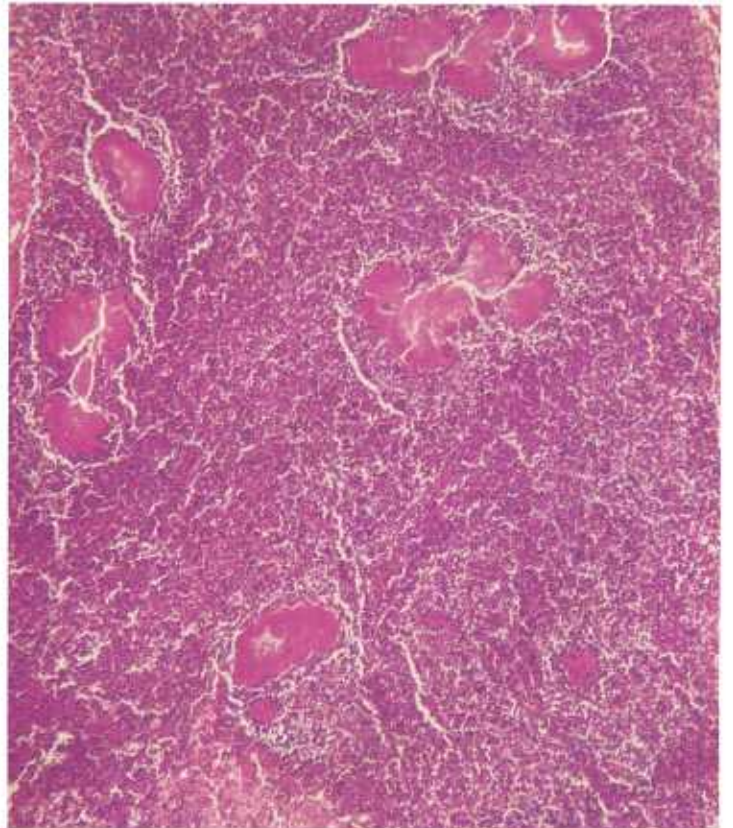


Figure 287.—Histologic preparation of a mediastinal lymph node from a 7-year-old bull (C19-D1916). Large "sulfur granules" are present in the neutrophilic exudate. Giemsa stain.  $\times 50$ .

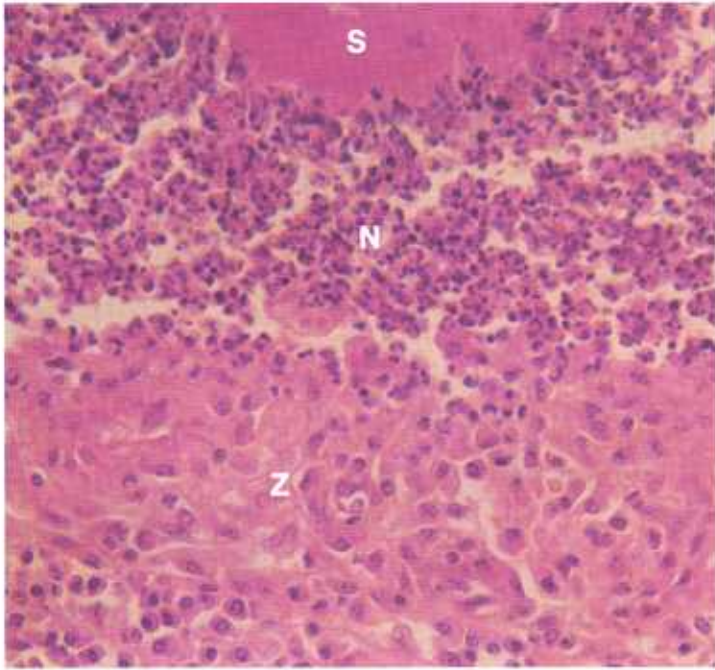


Figure 288.—Histologic preparation of a mediastinal lymph node from a 7-year-old bull (C19-D1916). The photograph shows the structure of a nocardial abscess in which there is a central "sulfur granule" (S), an adjacent mass of neutrophils (N), and an enclosing zone (Z) of chronic inflammatory tissue. Hematoxylin-eosin stain.  $\times 320$ .

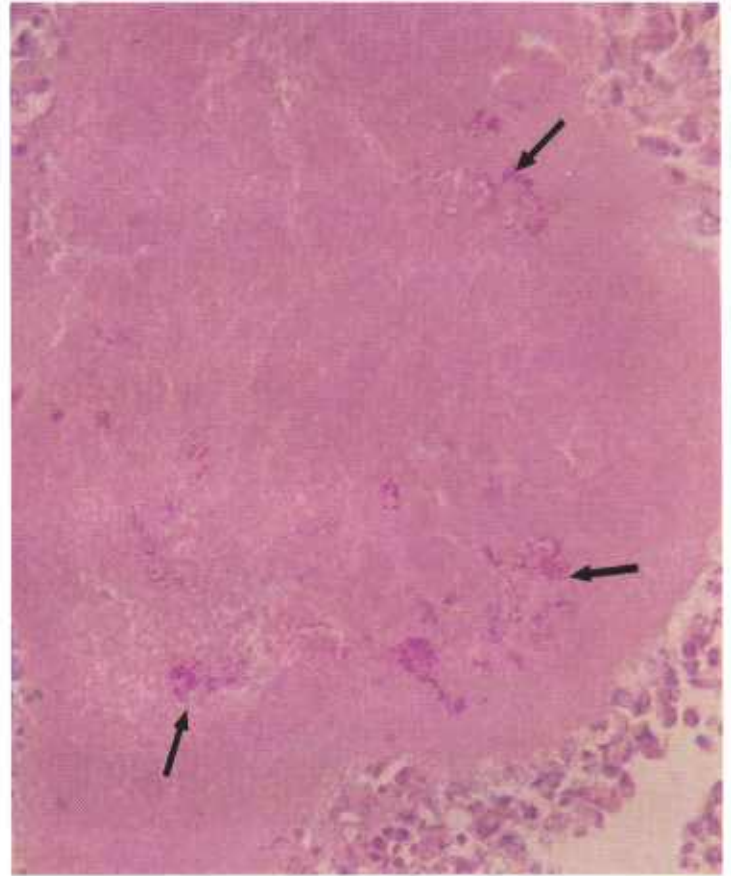


Figure 290.—Histologic preparation of a nocardial pulmonary lesion from a 7-year-old bull (C19-D1916). Red-staining organisms (arrows) can be seen within a "sulfur granule." Periodic acid-Schiff stain.  $\times 500$ .

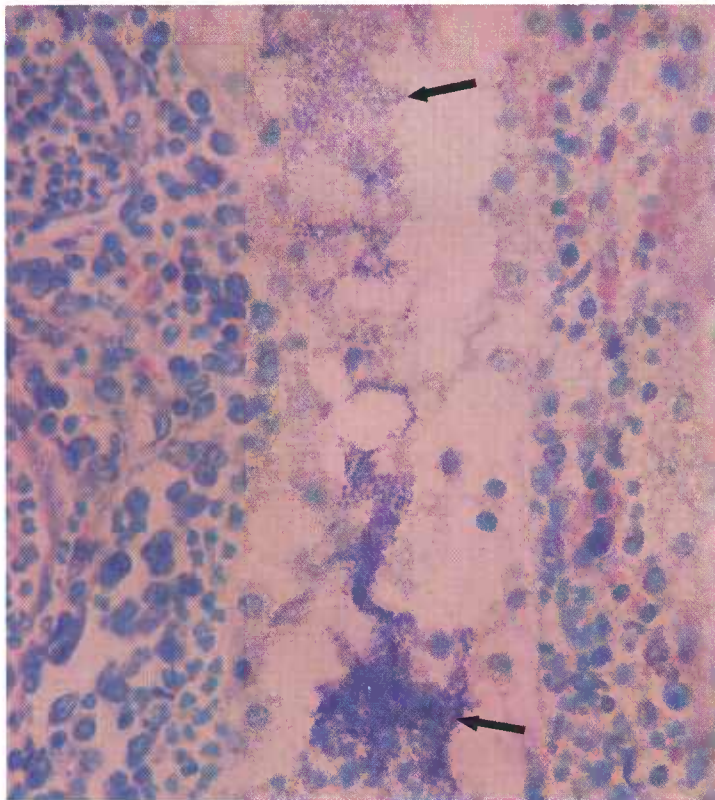


Figure 289.—Histologic preparation of a pulmonary lesion from a 7-year-old bull (C19-D1916). Blue-staining *Nocardia* (arrows) can be seen in the preparation. Giemsa stain.  $\times 500$ .

septic emboli are located in the pulmonary arteries, an indication of a hematogenous extension of the mammary infection into the lungs.

Lesions are occasionally observed in the lungs and in the bronchial and mediastinal lymph nodes of cattle when mastitis is not present. These pulmonary infections are thought to occur as the result of the inhalation of contaminated air. The alterations are easily confused with those of tuberculosis.

**Microscopic appearance.**—When the organism first enters the tissues, the lesion formed consists of an area of acute suppurative inflammation with an exudate principally composed of neutrophils. Later, the lesion becomes chronic and the central focus of neutrophils becomes surrounded by a zone of newly formed granulation tissue that is composed of connective tissue, capillaries, lymphocytes, macrophages, and a few giant cells. Calcification of the necrotic exudate is occasionally observed. The causative agent is found in the purulent exudate and is observed to consist of Gram-positive, branching, filamentous organisms that are acid-fast or slightly acid-fast. Diagnosis is based upon the cultural isolation and identification of these organisms.

## Paratuberculosis (Johne's Disease)

**Definition.**—Paratuberculosis is a chronic infectious enteric disease of cattle and sheep caused by *Mycobacterium paratuberculosis*.

**Distribution and incidence.**—This enteric disease is found throughout the United States and is particularly common in dairy communities. The prevalence of the disease in sheep has not been established but may prove to be just as common in sheep as in cattle. Current information indicates that the ovine disease is most frequently observed in the northern Rocky Mountain region.

Paratuberculosis is primarily a disease of cattle that are 2 or more years of age. Infection in both calves and sheep occurs at an early age. Animals over 4 months of age seldom become infected, even though they have been exposed to the disease. After a long incubation period (2 or more years), the first indication of the disease appears as a gradual loss of condition. When a persisting diarrhea is present, loss of weight is rapid and progressive. Many animals that react to the Johnin test are in good flesh, show no lesions, and do not contain demonstrable organisms.

**Macroscopic appearance.**—The entire intestinal tract

from the duodenum to the rectum is involved, but the lesions are usually most severe in the terminal portion of the ileum and in the region of the ileo-cecal valve. Affected parts of the intestine have greater diameters than normal and firmer consistencies, and their serosas are often edematous along their mesenteric attachments. The mucous membrane is yellowish white and is covered with adhesive, viscid, cloudy, grayish-yellow mucus. It is arranged in numerous folds that usually measure 5 to 8 mm. in diameter. When tension is applied to the mucous membrane, the folds cannot be flattened. No necrotic or ulcerative alterations are observed in the mucosa. The crests of the mucosal folds contain red streaks that correspond to the slightly hyperemic capillaries in the tips of the villi.

Lymph vessels in the serosa of the intestine and in the mesentery are readily visible. Mesenteric lymph nodes are enlarged and contain yellowish-white foci.

**Microscopic appearance.**—The basic lesion is a chronic diffuse catarrhal enteritis characterized by hyperplasia of macrophages wherever the causative organisms are found. In affected parts of the intestine, macrophages are most numerous in the tunica propria of the intesti-

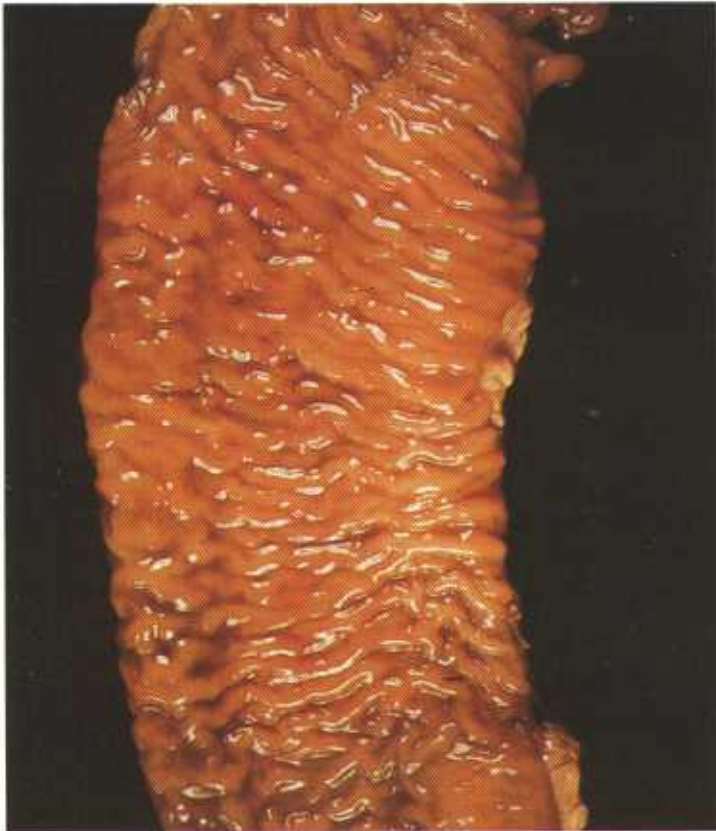

Figure 291.—Paratuberculosis of the small intestine of a cow (B180-D3238). The mucous membrane is thickened and corrugated.

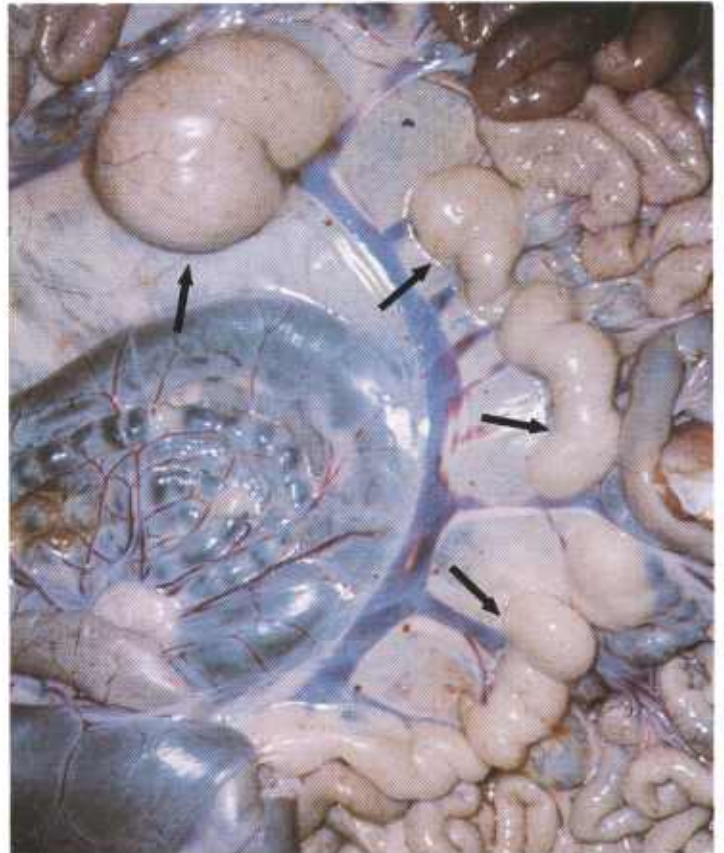


Figure 292.—Paratuberculosis of the mesenteric lymph nodes (arrows) of a lamb (JPK201).

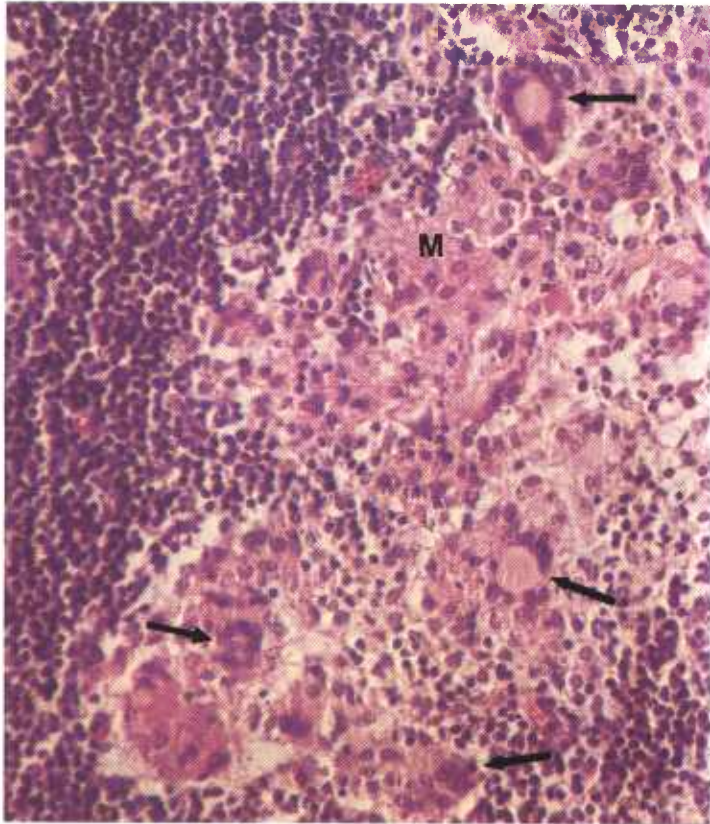


Figure 293.—A histologic preparation of a mesenteric lymph node in a lamb (JPK201). A focus of chronic inflammation with proliferation of macrophages (M) and formation of giant cells (arrows) is present. Hematoxylin-eosin stain.  $\times 320$ .

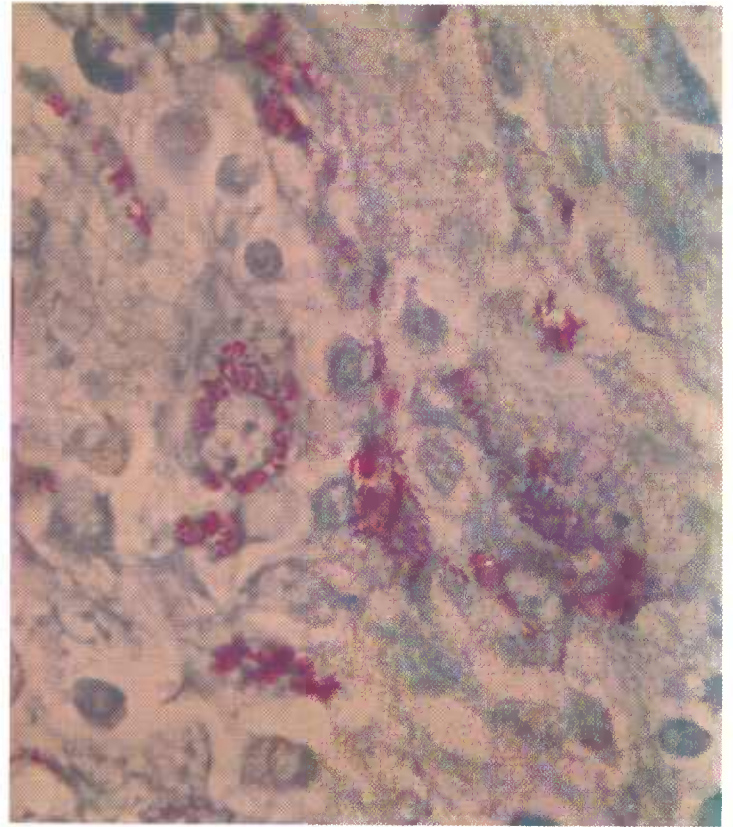


Figure 295.—A higher magnification of the acid-fast bacilli shown in figure 294. The red-staining, rod-shaped bacilli are *Mycobacterium paratuberculosis*. Ziehl-Neelsen acid-fast stain.  $\times 1250$ .

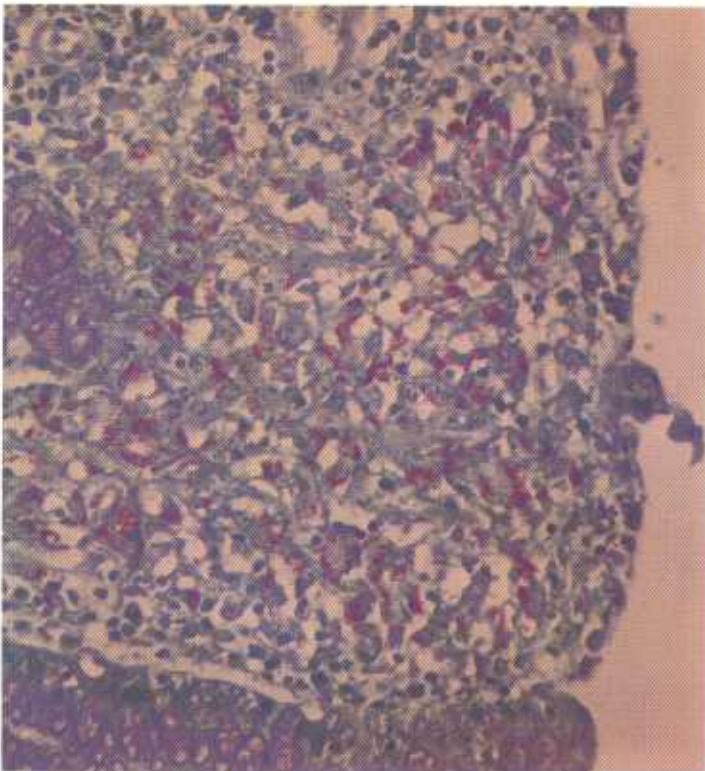


Figure 294.—Paratuberculosis of the intestine of a cow (B5122). The red-staining, rod-shaped bacilli are *Mycobacterium paratuberculosis*. Ziehl-Neelsen acid-fast stain.  $\times 320$ .

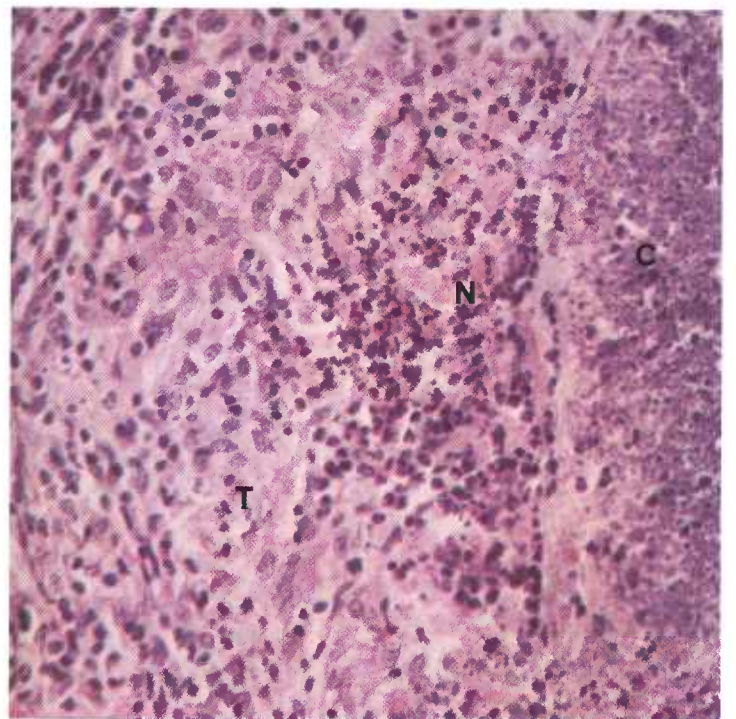


Figure 296.—Paratuberculosis of the intestine of a sheep (JPK201). The lesion consists of an area of caseous necrosis that has been calcified (C), a zone of liquefactive necrosis (N), and an enclosing zone of chronic inflammatory tissue (T). Hematoxylin-eosin stain.  $\times 320$ .

nal tract, are fewer in number in Peyer's patches, and are still fewer in the submucosa. Some of the macrophages form giant cells. Most of the acid-fast bacteria are contained within the macrophages or the giant cells. Thickening of the intestinal wall is caused mainly by the large number of macrophages that are present. Because of the accumulation of these cells in the tunica propria, the mucous membrane requires more space. The only available space is in the direction of the lumen of the intestine and expansion in this direction causes the mucous membrane to become arranged in folds. Masses of macrophages accumulating in the tunica propria interfere with the nutrition of epithelium and often cause scattered epithelial segments to atrophy. Atrophy of the epithelium is most prominent on the tips of the villi because there the epithelium is farthest removed from

the blood supply. When the epithelium over the tips of the villi disappears, macrophages loaded with acid-fast bacteria are exposed to the intestinal contents and are carried away by it. In some instances, the epithelium becomes hyperplastic and effectively covers the underlying tissues.

Lymph vessels in the intestine and mesentery contain masses of macrophages that have engulfed acid-fast bacteria. Subcapsular and peritrabecular cortical sinuses and the adjacent lymphoid tissues of the lymph nodes contain many similar macrophages. Medullary parts of the node are only slightly involved. Obstructing macrophages in the subcapsular and cortical trabecular sinuses and in the afferent lymph vessels impair the flow of lymph from the intestine so that a distention of the mesenteric lymph vessels occurs.

## Ovine Caseous Lymphadenitis

**Definition.**—Ovine caseous lymphadenitis is a chronic infectious disease of sheep caused by *Corynebacterium pseudotuberculosis*.

**Distribution and incidence.**—Caseous lymphadenitis is commonly found in sheep-raising areas (Rocky Mountain States) where mature sheep are retained in breeding flocks. The disease occurs infrequently in animals that are less than 1 year of age and therefore is seldom observed in those areas (Corn Belt) where lambs are fattened.

Affected sheep are usually in fair to good condition when slaughtered. Those that are emaciated are usually old, and their poor condition is caused, in part, by diseases other than caseous lymphadenitis. Although the disease is certainly debilitating and will sometimes cause death, affected sheep will often have a very extensive involvement of internal organs before clinical signs of the disease are observed.

Caseous lymphadenitis is principally a disease of lymph nodes. Abscesses in the lymph nodes are usually

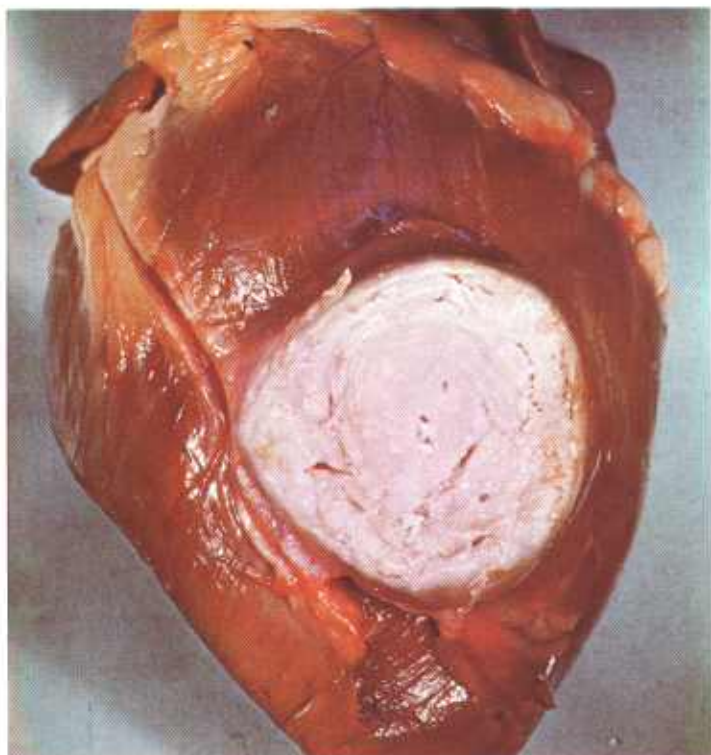


Figure 297.—Caseous lymphadenitis of the heart of a sheep (B40-128429). A white, encapsulated, concentrically laminated, partially calcified area of caseous necrosis is present in the wall of a ventricle.

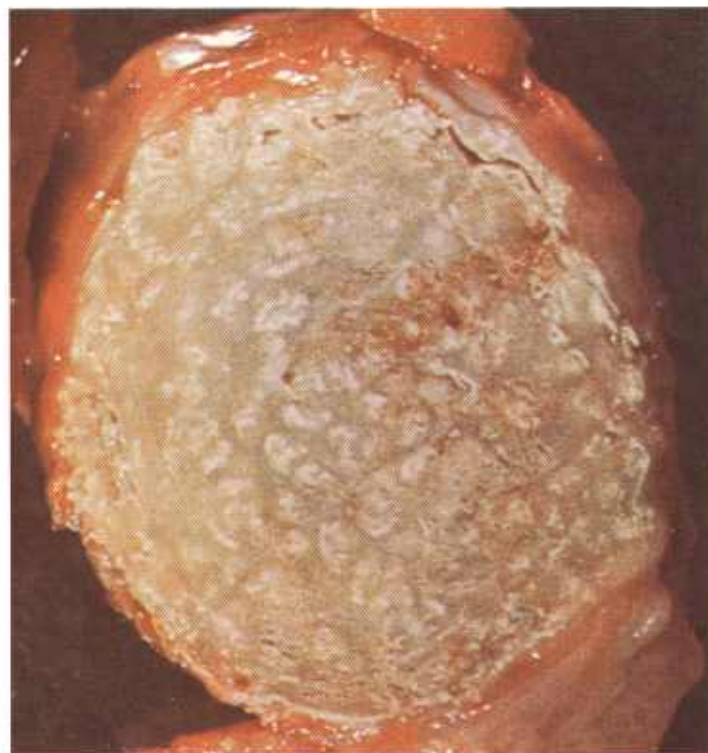

Figure 298.—Caseous lymphadenitis of a lymph node of a sheep (B85-129579). Most of the lymph node has been converted into a white, encapsulated, concentrically laminated, partially calcified mass of caseous necrosis.

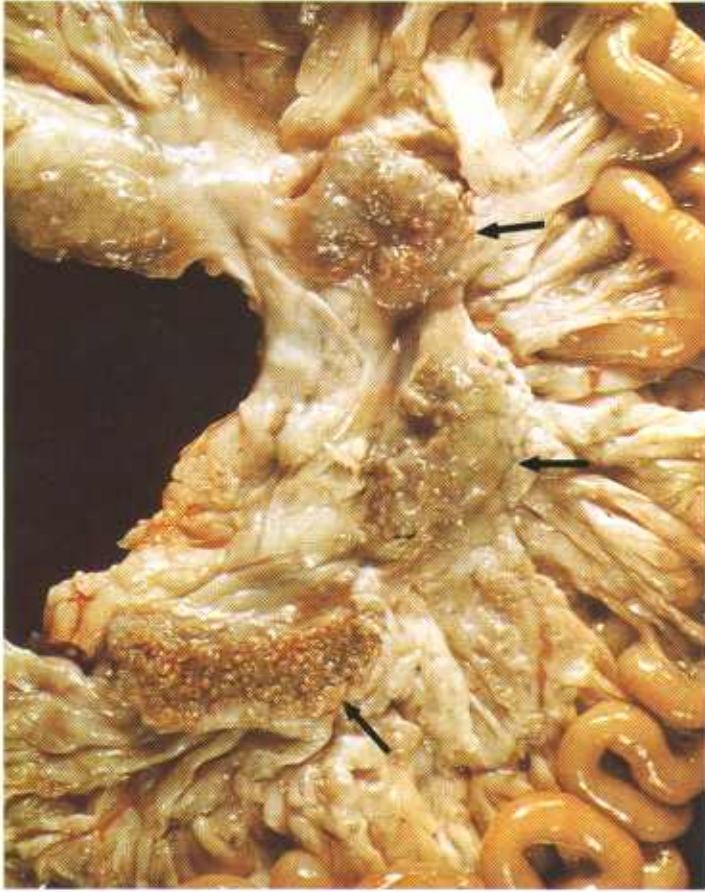

Figure 299.—Caseous lymphadenitis of the mesenteric lymph nodes (arrows) of a sheep (B196-D3548). The lymph nodes contain multiple white, partially calcified foci of caseous necrosis.

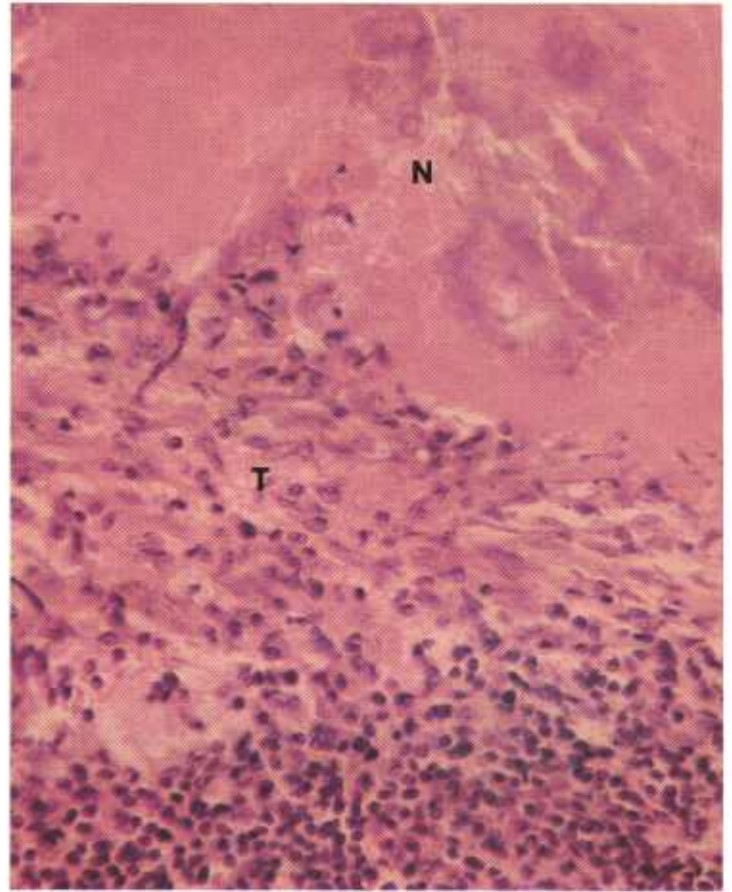


Figure 301.—A histologic preparation of the mesenteric lymph nodes (B196-D3548) shown in figure 299. The lesion consists of caseous necrosis (N) bordered by chronic inflammatory tissue (T). Hematoxylin-eosin stain.  $\times 320$ .

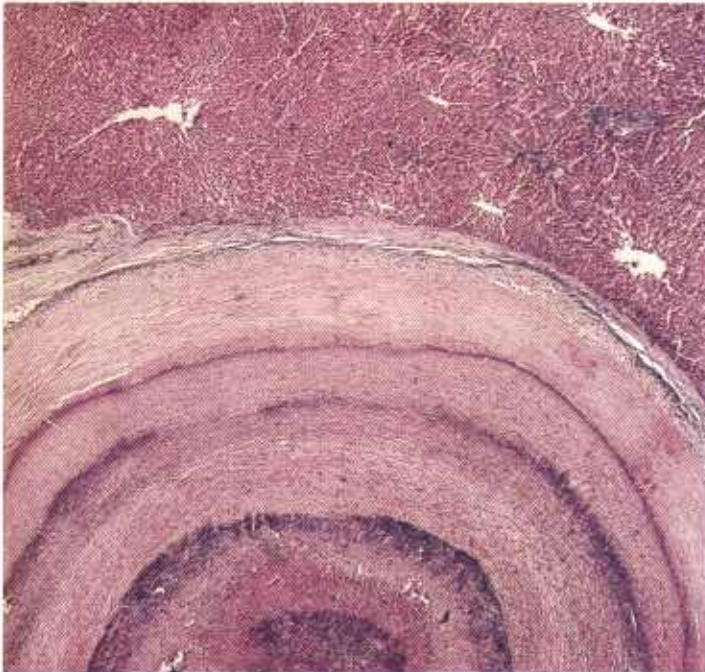


Figure 300.—Caseous lymphadenitis of the liver of an old ewe (D552). The necrotic tissue has a concentric arrangement. Giemsa stain.  $\times 25$ .

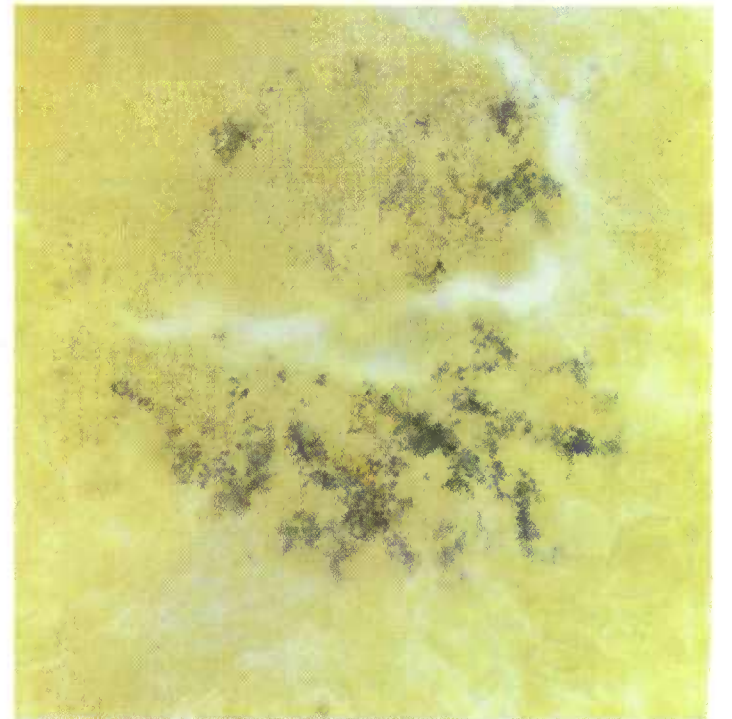


Figure 302.—A histologic preparation of the affected liver (D552) shown in figure 300. *Corynebacterium pseudotuberculosis* can be seen as short Gram-positive rods. Gram-Weigert stain.  $\times 750$ .

large and frequently involve the entire node. Prescapular lymph nodes are the most frequently involved peripheral lymph nodes and bronchial and mediastinal lymph nodes are the most commonly affected visceral nodes. Abdominal lymph nodes, especially the mesenteric, are also involved, but not as frequently as the thoracic lymph nodes.

The lung is the most commonly affected organ but the spleen, liver, kidney, and heart are occasionally involved. When an organ is involved, the regional lymph nodes are usually affected also. Lesions may be present in the visceral lymph nodes, even though no alterations are found in the visceral organs.

**Macroscopic appearance.**—Lesions begin as acute focal areas of suppurative inflammation that later become chronic and finally become enclosed in heavy connective tissue capsules. With age, the mass of pus within the abscesses becomes dry and granular and acquires a caseous appearance. The exudate is usually light green but may become white or grayish white when calcification occurs. As the lesions enlarge peripherally they develop a concentrically arranged lamination that is probably associated with the inability of the body to confine the infection and the resulting secondary exacerbations of the disease.

Older encapsulated caseocalcareous alterations resemble lesions of tuberculosis. This similarity is responsible for the name of the disease—"pseudotuberculosis." It should be remembered, however, that tuberculosis in sheep is relatively uncommon in this country and that when it does occur, its lesions show a greater tendency to calcify than those of pseudotuberculosis.

Pulmonary lesions occur as miliary foci, multiple abscesses of varying size, or as one large single abscess. A complicating bronchopneumonia is often present.

**Microscopic appearance.**—Shortly after *C. pseudotuberculosis* enters the tissues, an acute inflammatory reaction occurs and an abscess is formed. After a period of time, the mass of exudate in the abscess loses its architectural and cellular detail, becomes homogeneous in appearance, and stains with eosin. It then has the characteristic appearance of caseous necrosis. Calcium salts are frequently deposited in the necrotic tissue. The exudate is arranged in concentric rings around the original focus of infection, and the entire mass of exudate is surrounded with a zone of macrophages and an encapsulating border of connective tissue. Gram-positive organisms can be easily demonstrated in recent lesions but may be difficult to find in older alterations.

## Staphylococcosis

**Definition.**—Staphylococcosis is an infectious suppurative disease that is caused by *Staphylococcus aureus*.

**Distribution and incidence.**—The disease is found in

all species of meat-producing animals throughout the United States and is commonly observed in horses and cattle. It occurs as the result of wound infections in



Figure 303.—Staphylococcosis of part of the mammary gland of a 6-year-old cow (B179-D3233). The lobules of the gland are surrounded by chronic inflammatory tissue and multiple yellowish-white necrotic foci are present within the lobules.

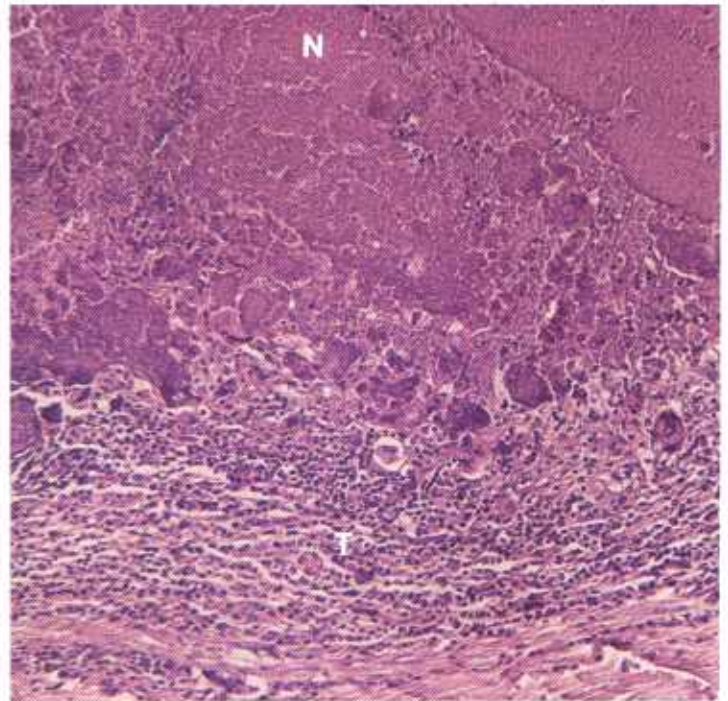


Figure 304.—Staphylococcal metritis in a cow (127529). The lesion consists of a central area of partially calcified, caseous necrosis (N), surrounded by a zone of chronic inflammatory tissue (T). Hematoxylin-eosin stain.  $\times 125$ .

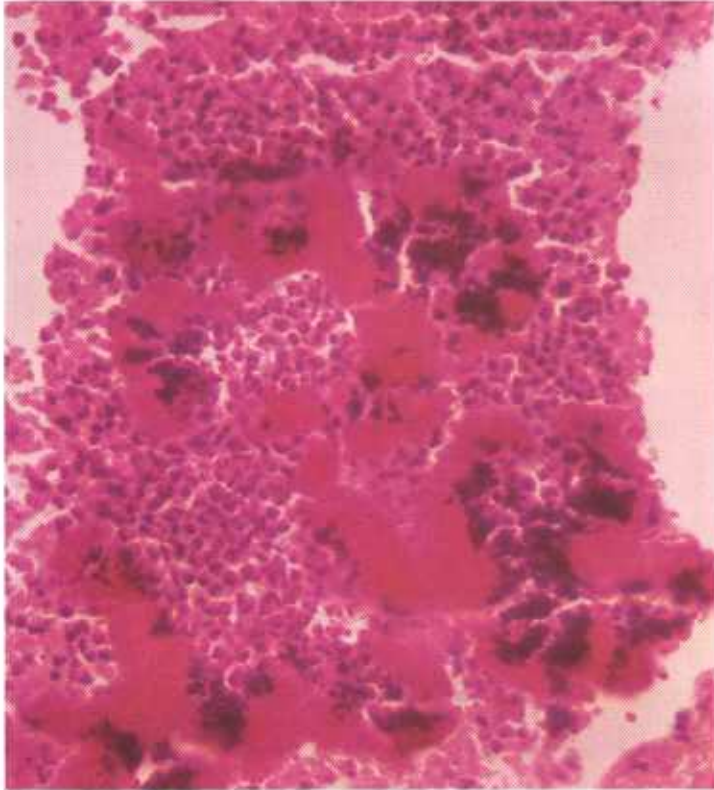


Figure 305.—Staphylococcal mastitis in a 5-year-old cow (D1355). Several eosin-staining sulfur granules are present in a focus of neutrophils. Hematoxylin-eosin stain,  $\times 320$ .

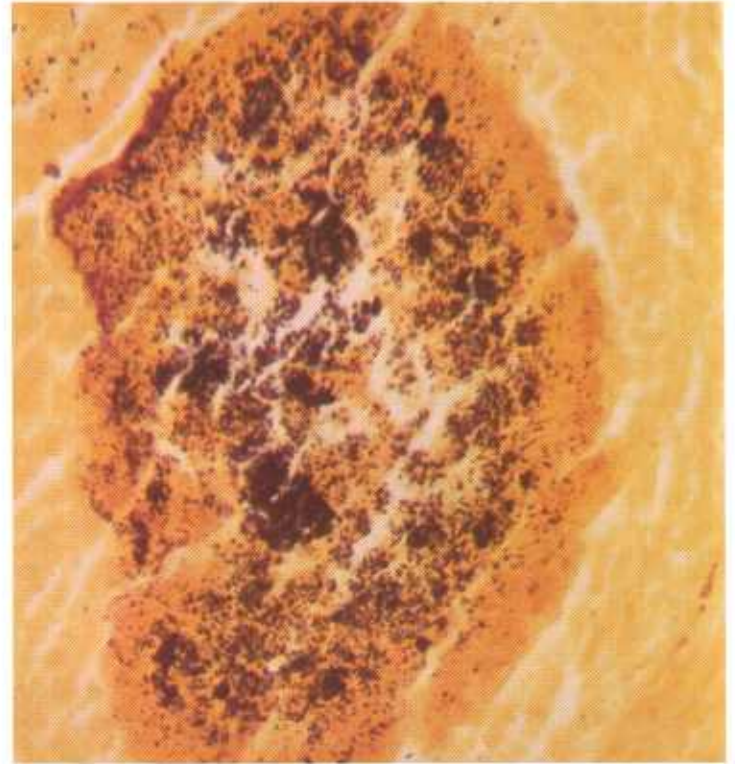

Figure 306.—A histologic preparation of the mammary gland specimen (B179-D3233) shown in figure 303. Numerous Gram-positive cocci are present in a "sulfur granule." Gram-Weigert stain,  $\times 320$ .

horses and is often observed as an infection of the spermatic cord in geldings (scirrhous cord). Staphylococcosis in cattle is commonly observed as a chronic mastitis. Animals with acute staphylococcosis are seldom slaughtered.

**Macroscopic appearance.**—Staphylococcosis usually occurs as a chronic productive type of inflammation. The chronicity of staphylococcal lesions is indicated by the abundance of connective tissue in and around the area. Alterations are diffuse or focal in distribution and are sharply demarcated from the surrounding tissue by a connective tissue capsule.

The exudate is usually yellow and is fluid, semisolid, or granular. Calcification usually is not present. Yellowish granules resembling grains of sulfur ("sulfur granules") are found within the exudate. The lesions and exudate of staphylococcosis resemble those of actinomycosis or actinobacillosis except that the exudate of staphylococcosis is not tenacious and is not often green like the exudates of the other two diseases.

Regional lymph nodes draining an area affected with

staphylococcosis are usually involved. Extensive lesions are usually found in the supramammary and prefemoral lymph nodes when the mammary gland is affected.

**Microscopic appearance.**—The lesions are those of a chronic suppurative inflammation. The centers of the lesions contain a mass of neutrophils, one or more rosettes, and a few calcospheres. With hematoxylin and eosin staining, the rosette (the yellow granule seen on gross examination) is red and has the same appearance as the rosettes observed in actinomycosis and actinobacillosis. Each rosette consists of a cluster of club-shaped structures that radiate from a central mass. Gram-positive cocci can be demonstrated within the rosette when the lesion is stained with the Gram's method.

A zone of granulation tissue is found peripheral to the central focus of neutrophils and rosettes. It is infiltrated with macrophages, lymphocytes, plasma cells, and neutrophils, and an occasional giant cell is present. The entire lesion is surrounded with a zone of connective tissue.

## Tuberculoid Dermatitis of Cattle

**Definition.**—Tuberculoid dermatitis is a chronic infectious skin disease caused by acid-fast organisms that sensitize cattle to tuberculin.

**Distribution and incidence.**—Tuberculoid dermatitis

is found throughout the United States. The disease is of primary concern in the tuberculosis eradication program since acid-fast organisms in the skin sensitize cattle to tuberculin. When no lesions of tuberculosis are

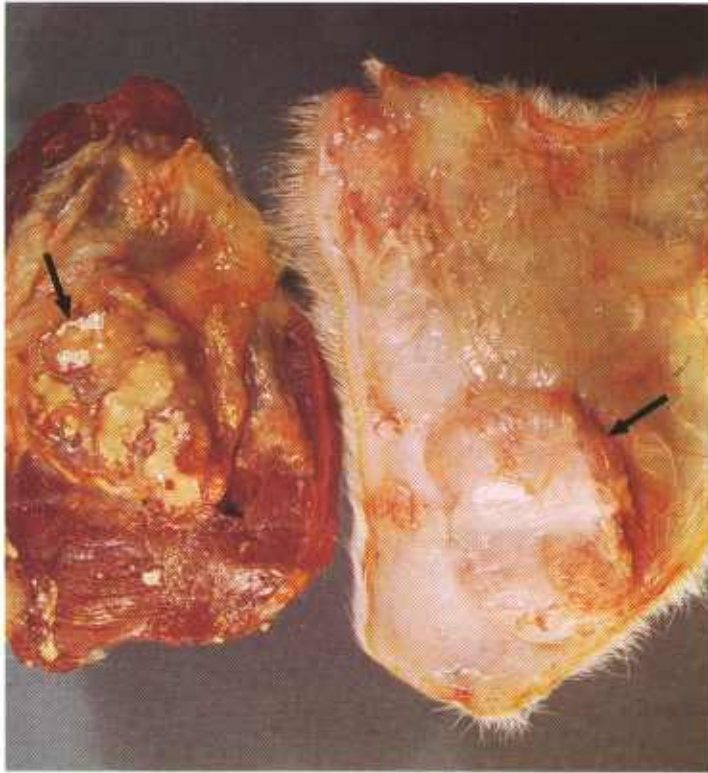


Figure 307.—Tuberculoid dermatitis of the skin of the right shoulder and forearm of an 8-year-old Holstein cow (B168-132231). The lesions (arrows) consist of yellow, encapsulated, caseocalcific masses that involve the skin, subcutaneous tissue, and underlying muscle.

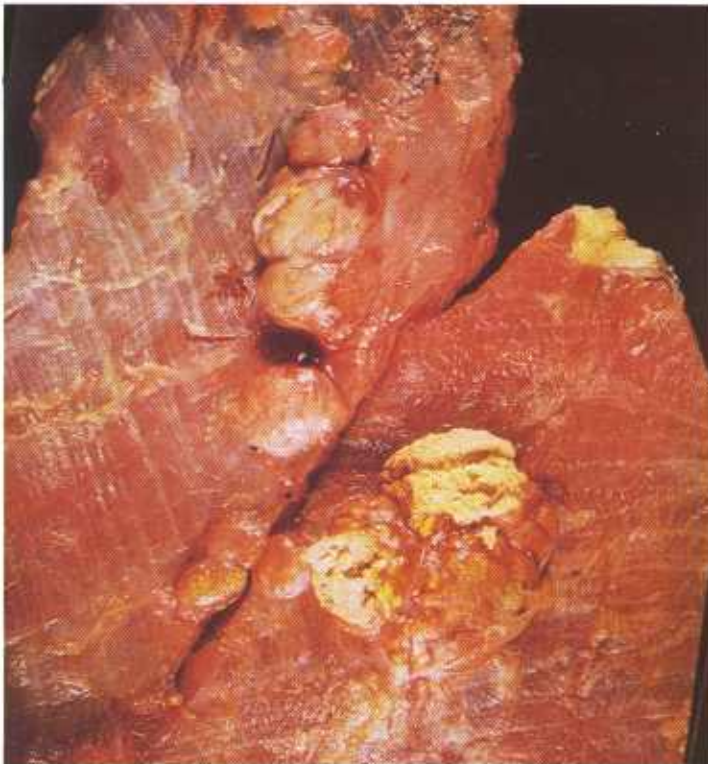

Figure 308.—Multiple yellowish-white, encapsulated tuberculoid lesions are present in the external oblique muscle of the abdominal wall of a 6-year-old cow (B217-133159). The nodules are arranged in chains, an arrangement that indicates the bacteria are invading along the course of the lymphatics.

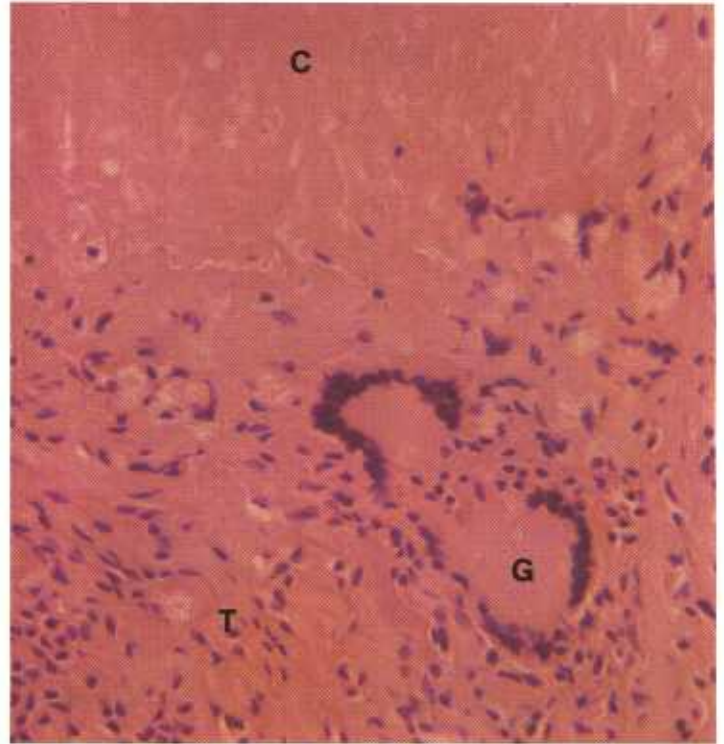


Figure 309.—Tuberculoid dermatitis of the skin of the leg of a 7-year-old cow (132312). The tissue has been decalcified. The histologic preparation is from the edge of the caseonecrotic center (C) where the calcium was located. A giant cell (G) is present in the chronic inflammatory tissue (T) that encloses the necrotic center (C). Hematoxylin-eosin stain.  $\times 320$ .

found in cattle reacting to the tuberculin test, their skin should be carefully examined for lesions of tuberculoid dermatitis.

Cattle with tuberculoid skin lesions do not always react to tuberculin. The presence or absence of skin sensitivity in tuberculoid dermatitis may depend upon the species of organism involved. If lesions of tuberculoid dermatitis are removed surgically, cattle will gradually lose their sensitivity.

Cultural examination of the skin lesions is only partially successful in isolating acid-fast organisms. It is difficult to transmit tuberculoid dermatitis to cattle or laboratory animals by inoculating them with lesion material or with bacteria isolated from the alterations.

**Macroscopic appearance.**—Lesions are most frequently observed in the skin of the fetlock, pastern, shoulder, and knee, and in the skin of the ventral abdominal wall. Acid-fast organisms are apparently introduced into the skin by mechanical injury. At the entrance site, they produce a chronic focal inflammation in the dermis or subcutaneous tissue.

The basic lesion consists of a tubercle that may occur as a single mass, as multiple tubercles enclosed within connective tissue, or as a primary mass with multiple tubercles scattered along the course of the lymphatics leaving the primary lesion. Regional lymph nodes are seldom affected even though their afferent lymphatics are involved. Individual skin lesions may be scarcely

visible. Spreading lesions consist of a mass of tubercles that may measure as much as 20 cm. by 6 cm. by 3 cm. The lesions tend to be elongated because they spread laterally along the course of lymphatics and are compressed between the skin and the underlying tissues. Daughter tubercles are often present along the course of the lymphatics leaving the primary lesion. A few of the lesions ulcerate and their exudate is discharged onto the skin surface. The protruding skin surface may be partly or completely devoid of hair.

**Microscopic appearance.**—When organisms are first introduced into the tissues, an acute suppurative inflammatory response occurs. This response quickly changes to a chronic suppurative type of inflammation that later becomes a chronic productive caseous alteration. At the time the lesion is examined by a meat inspector, it is usually composed of a group of tubercles. Each tubercle

contains a central, partially calcified, caseous mass of exudate enclosed within granulation tissue composed of macrophages, lymphocytes, a few neutrophils, an occasional giant cell, and fibroblasts. As the disease progresses, the connective tissue capsule surrounding the mass increases in thickness and the quantity of exudate within the lesion diminishes. If healing occurs, a mass of connective tissue persists in the area. Lesions resemble the alterations produced by *Mycobacterium tuberculosis* and cannot be differentiated from them with certainty.

Staining of the lesion with Ziehl-Neelsen and auramine-rhodamine methods usually reveals the presence of acid-fast organisms that cannot be differentiated morphologically from *Mycobacterium tuberculosis*. These organisms are abundant in early lesions but decrease in number as the alterations age.

## Tuberculosis

**Definition.**—Tuberculosis is a chronic infectious disease of all domesticated animals caused by *Mycobacterium tuberculosis*.

**Distribution and incidence.**—This disease is found throughout the United States. Its incidence varies from one community to another, but in general is less commonly observed today than it was a few years ago.

The location of the lesions in tuberculosis varies with the genus of the animal involved. In cattle, the lesions are most frequently located in the lungs and their re-

gional lymph nodes and less commonly found in the pleura, liver, spleen, and peritoneum. In swine, cervical lymph nodes are most frequently involved followed by the bronchial, hepatic, and mesenteric lymph nodes, and the liver, lungs, spleen, and kidney.

**Macroscopic appearance.**—The basic lesion of tuberculosis is the tubercle, which usually consists of a central area of caseous necrosis enclosed within a connective tissue capsule. Since the causative organisms usually invade the body through the alimentary tract or

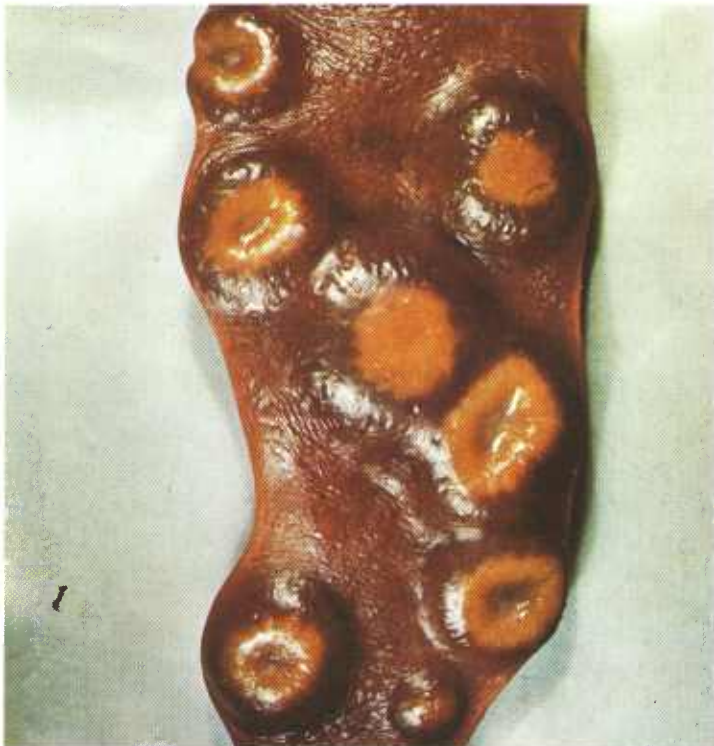

Figure 310.—Tuberculosis of the spleen of a 1-year-old sow (B62-128719). Firm, circular yellow lesions with raised borders and depressed centers are present.

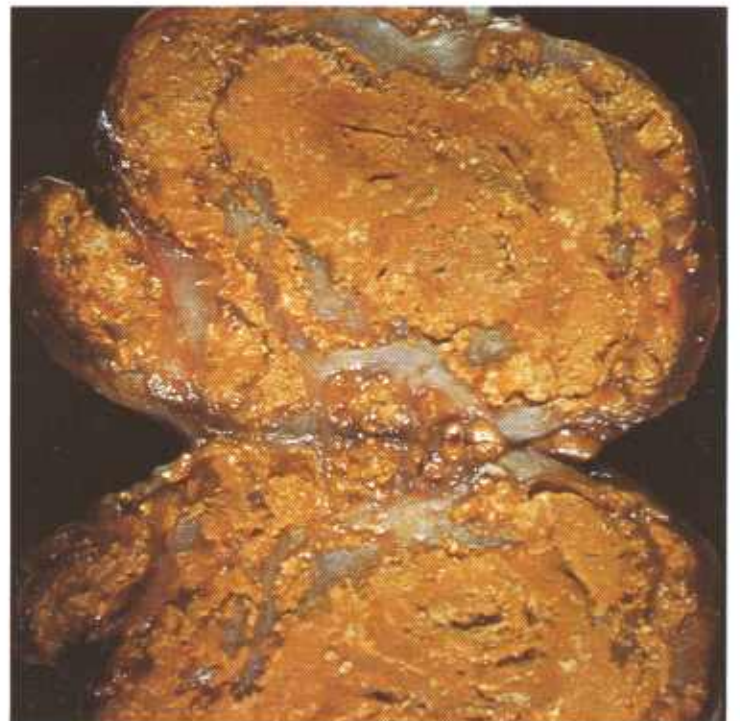

Figure 311.—Tuberculosis of a cervical lymph node in a 4-year-old cow (B74-128961). The node consists of a dry, yellow, partly calcified necrotic mass of tuberculous tissue interspersed with gray lymphoid and chronic inflammatory tissues.

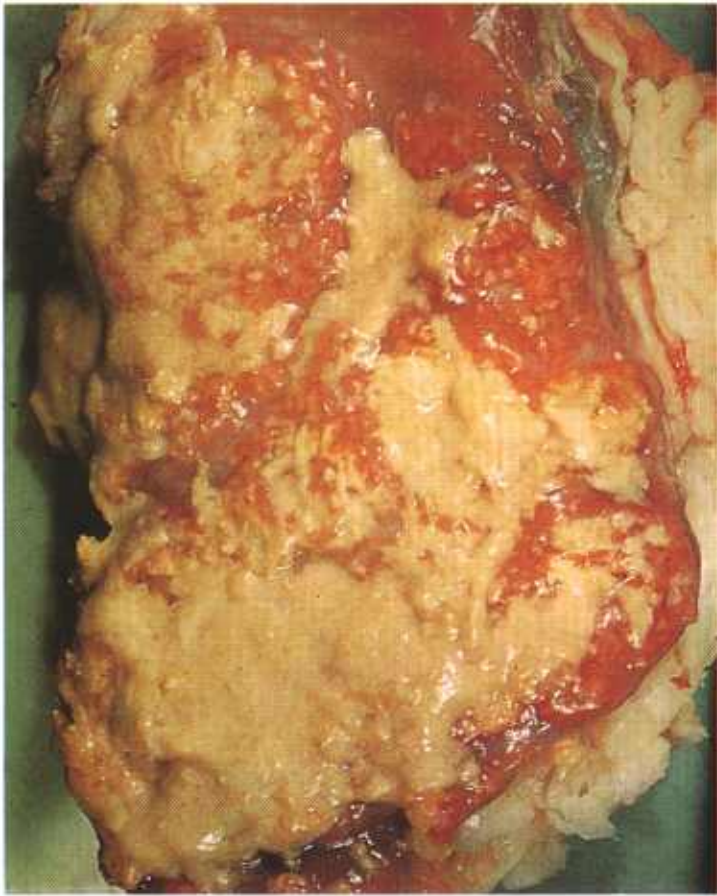

Figure 312.—Tuberculosis of a mediastinal lymph node in a 2-year-old Hereford bull. The hyperemic lymph node contains an abundance of yellow pus.

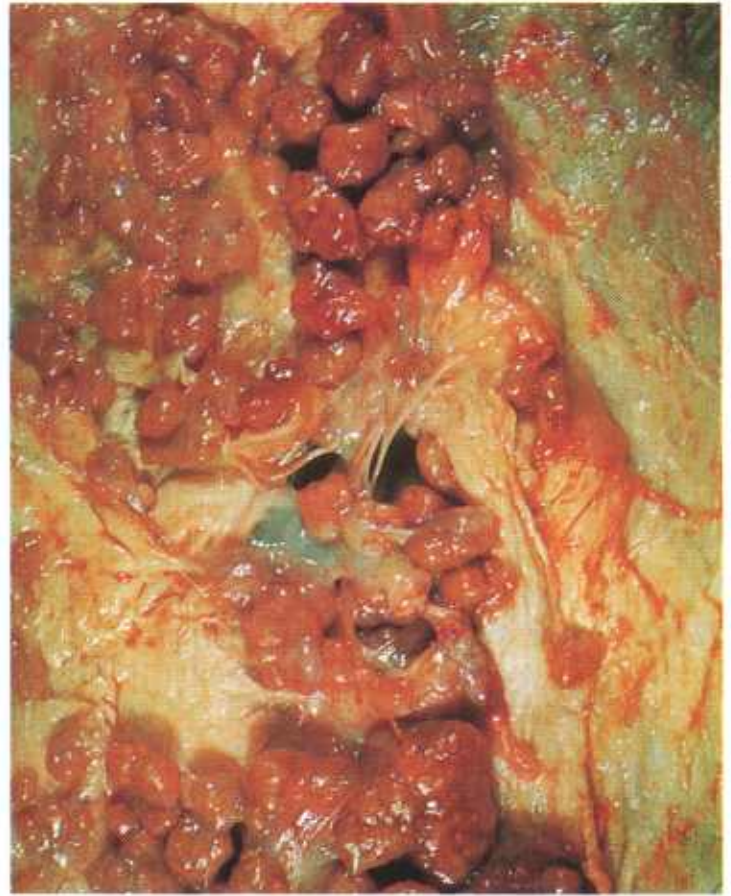

Figure 314.—Tuberculosis of the peritoneum of an 8-year-old cow (B111-130229). Multiple caseocalcific tubercles are attached to the peritoneal surface.

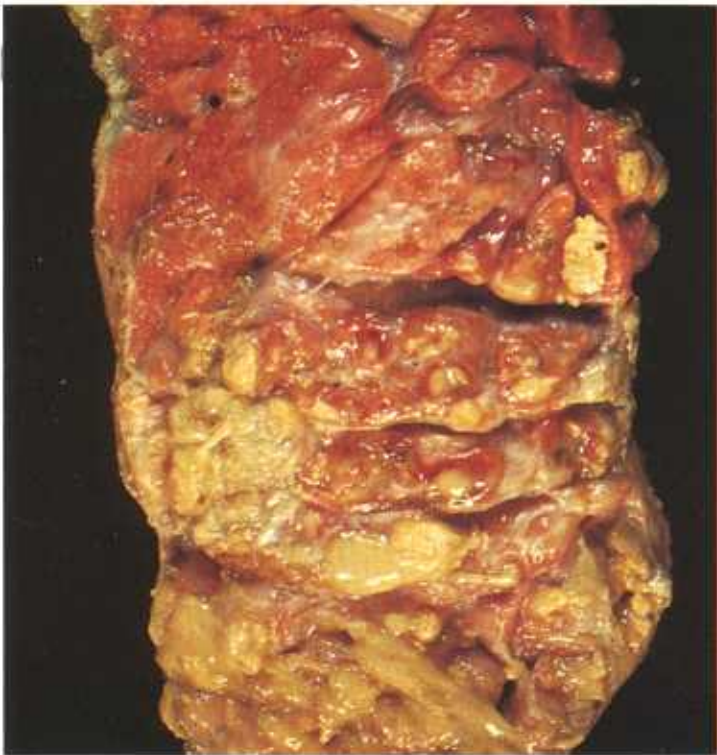

Figure 313.—Tuberculosis of the lung of a 3-year-old Hereford cow (B176-132308). Multiple caseocalcific and caseopurulent foci of tuberculosis are found throughout the lung.

respiratory system, the initial tubercle is usually found in the lungs or the intestines. The primary lesion may heal, or the infection may extend from the initial lesion into the adjacent tissues, or the organisms may metastasize to distant organs. The regional lymph nodes usually become involved.

The tubercle and subsequent lesions usually undergo caseous necrosis and calcification. The factors governing these alterations are the virulence of the organism, the type (bovine, avian, or human) of *M. tuberculosis* present, and the resistance of the host. When hosts having a high resistance to infection are invaded or when organisms of low virulence enter the tissues, a chronic inflammatory reaction is produced but necrosis is slight or is not present. Suppuration occurs if pyogenic bacteria invade the lesion.

Various descriptive terms (caseous, caseocalcific, suppurative, or productive) are used to describe the tissue reactions that occur in tuberculosis. A caseocalcific lesion is usually observed in cattle, sheep, and goats. In swine, the caseous type is most common although calcification does occur quite frequently. In horses, the lesion is productive with very little caseous necrosis or calcification.

When phagocytes—usually macrophages—that have engulfed mycobacteria migrate through the wall of the

tubercle into the surrounding tissue, secondary (daughter) tubercles arise at the site where the phagocytes cease to migrate. If the migrating phagocyte enters a lymphatic or a capillary, it is carried by the flowing lymph to the regional lymph nodes or by the flowing blood to the distant organs, such as the liver, lungs, or spleen, where a new focus of inflammation is established.

**Microscopic appearance.**—There is an acute suppurative inflammatory reaction in the immediate vicinity of the mycobacteria when they first enter the host's tissues. In a few days, macrophages and lymphocytes and proliferating connective tissue and capillaries begin to appear in the area of inflammation. Later, the macrophages form giant cells, and these multinucleated structures may become quite prominent in the exudate. The initial suppurative inflammatory reaction is usually followed by necrosis, at first coagulative and later caseous, in the center of the focus of inflammation. This necrotic mass gradually becomes enclosed within granulation tissue. Macrophages eventually become the most numerous leukocytes in the granulation tissue, and they are most abundant in the area immediately adjacent to the necrotic tissue. Neutrophils, present during the suppurative reaction, gradually disappear from the area of inflammation unless pyogenic organisms are present. If pyogenic organisms are present, neutrophils may become a major constituent of the cellular exudate.

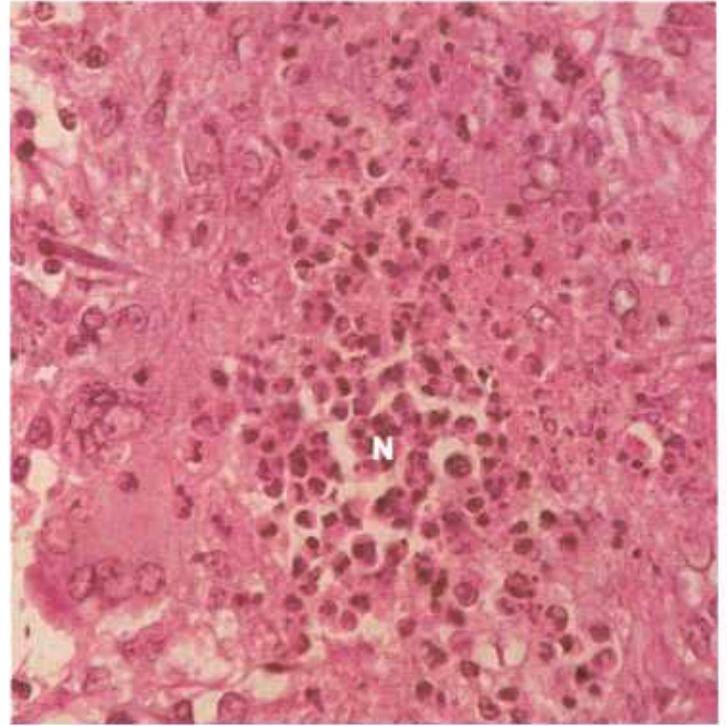


Figure 316.—Tuberculosis of the lung of a hog (D3005). The focus of neutrophils (N) indicates a suppurative type of lesion that occurs in the very early stages of the disease and later during the course of the disease when pyogenic organisms have invaded the area. Hematoxylin-eosin stain.  $\times 500$ .

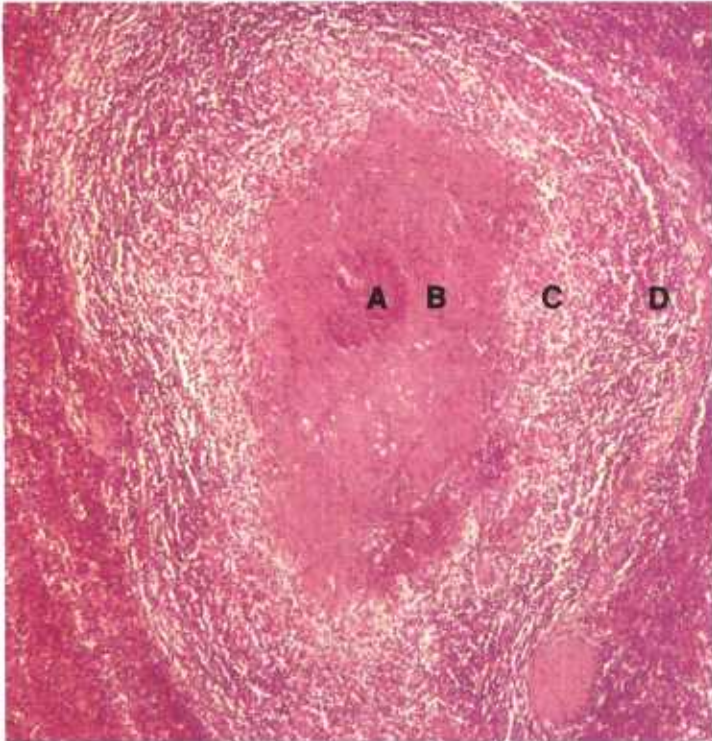


Figure 315.—Tuberculosis of the spleen of a 3-year-old steer (D1455). The lesion has the typical arrangement of a tubercle with a central focus of calcification (A) within a mass of caseous necrotic tissue (B) enclosed by a zone (C) of macrophages, giant cells, and connective tissue, and surrounded by a zone (D) of connective tissue and lymphocytes. Hematoxylin-eosin stain.  $\times 75$ .

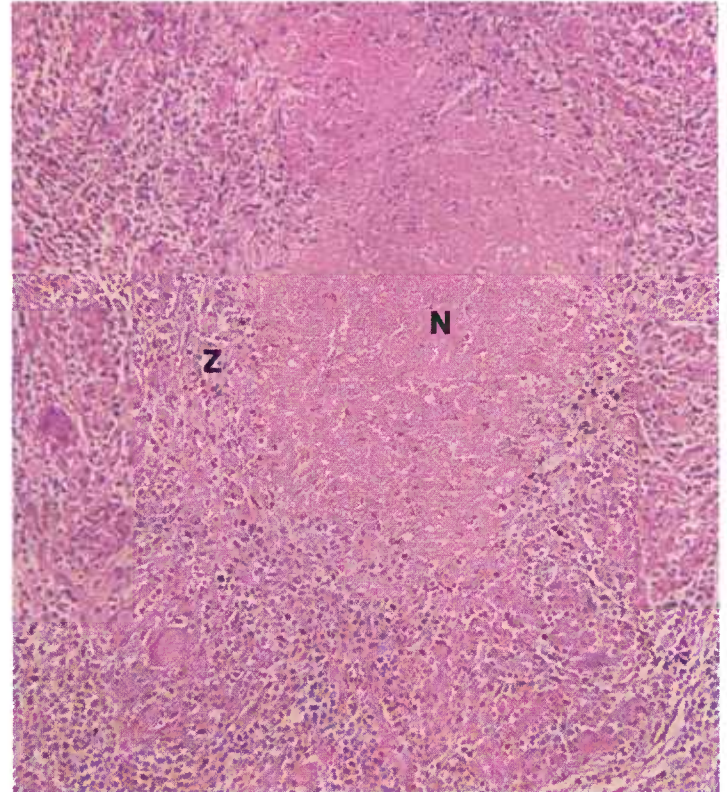


Figure 317.—Tuberculosis of the spleen of a 3-year-old steer (D1455). A caseo-productive type of lesion that has a central area of caseous necrosis (N) surrounded by a zone (Z) of proliferating macrophages, giant cells, and connective tissue. Hematoxylin-eosin stain.  $\times 125$ .

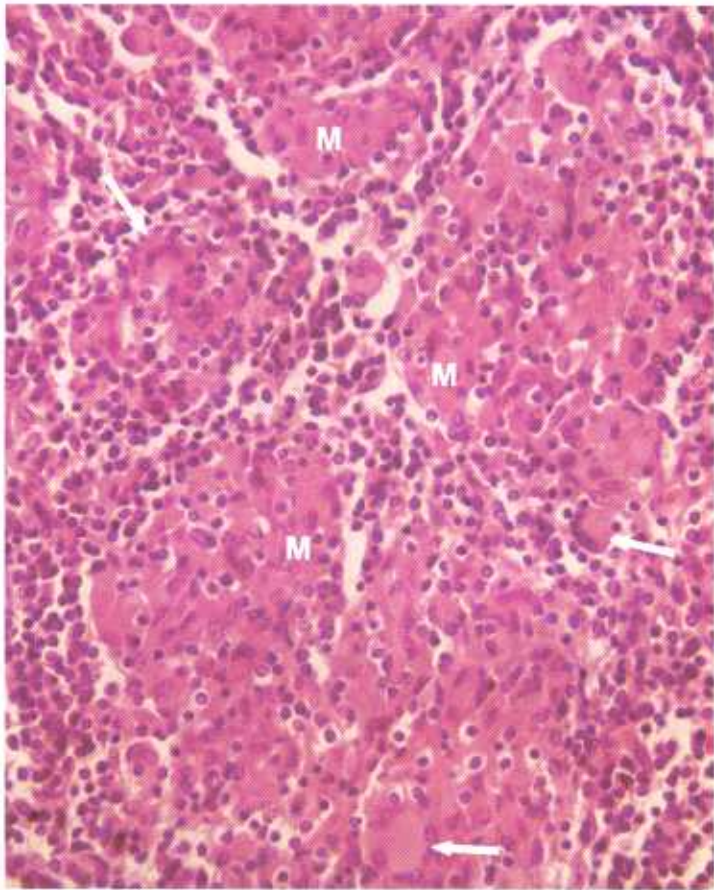


Figure 318.—Tuberculosis of the spleen of a 3-year-old steer (D1455). A productive type of lesion with extensive hyperplasia of macrophages (M) and beginning formation of giant cells (arrows). No necrosis or calcification is present. Hematoxylin-eosin stain.  $\times 320$ .

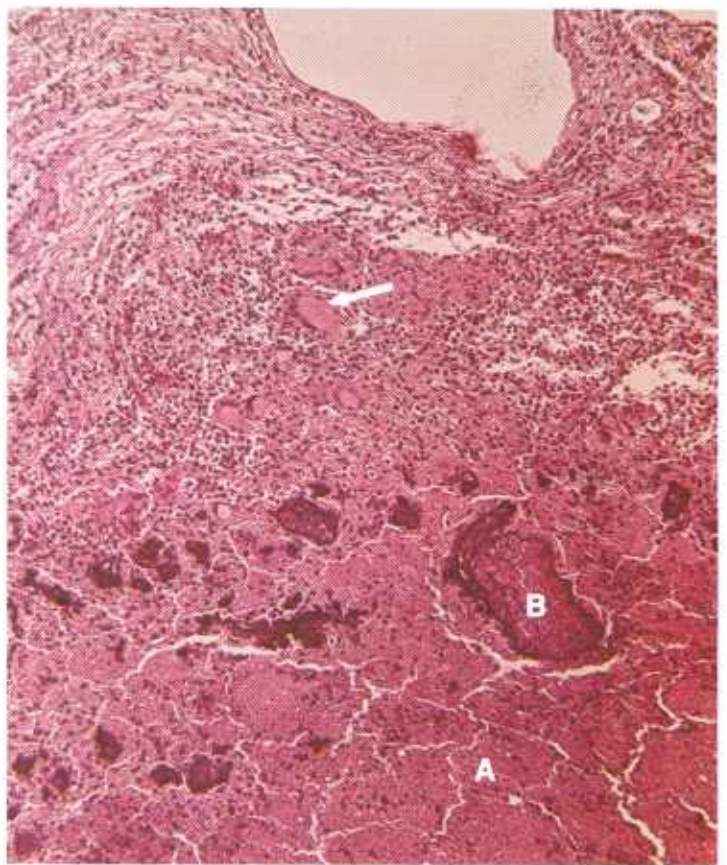


Figure 319.—A histologic preparation of the lung of a cow (B176-132308) shown in figure 313. The photograph shows an area of caseous necrosis (A), foci of calcification (B), and a zone of chronic productive inflammation containing macrophages, giant cells (arrow), and connective tissue. Hematoxylin-eosin stain.  $\times 125$ .



## CHRONIC PARASITIC DISEASES THAT RESEMBLE NEOPLASTIC ALTERATIONS

### Cysticercosis

**Definition.**—Cysticercosis is the invasion of the body by the larval forms (cysticerci) of tapeworms.

**Distribution and incidence.**—Cysticercosis is found throughout the United States. The species of parasite invading the tissues or organs depends upon the genus of animal affected. *Cysticercus bovis* is the larval form of *Taenia saginata* and occurs in cattle (intermediate host). The adult form of *T. saginata* is found in the intestinal tract of man. *Cysticercus cellulosae* is the larval form of *Taenia solium* and occurs mainly in swine (intermediate host). The adult form of this parasite is also found in the intestinal tract of man. *Cysticercus ovis*, the larval form of *Taenia ovis*, occurs in sheep (intermediate host). The adult form of the tapeworm is found in the intestine of carnivora, and the sheep dog guarding the flock is usually the carrier of the adult parasite.

When eggs of these three tapeworms are ingested by their appropriate intermediate hosts (cattle, swine, and

sheep), the infective larvae are liberated from the egg. Liberated larvae migrate into the wall of the intestine and are then carried by the lymph and blood streams to the body tissues, where they encyst. Encysted larvae are found in muscles throughout the body but are most frequently observed in the interstitial connective tissue of the tongue and heart and of the muscles of mastication. *C. cellulosae* often has a wider tissue and organ distribution than the other two tapeworm larvae and is found in the brain, spleen, lymph node, lung, liver, and eye. Occasionally, invasion of the heart and brain by *C. cellulosae* becomes so extensive that death of the host occurs.

**Macroscopic appearance.**—The fully developed cyst appears as an oval, pearly-white vesicle measuring 1 cm. in diameter. The cyst is distended with a clear fluid and contains a yellowish-white scolex that measures 1 to 2 mm. in diameter. An acute inflammatory reaction occurs in the muscle when larval migration is taking place.

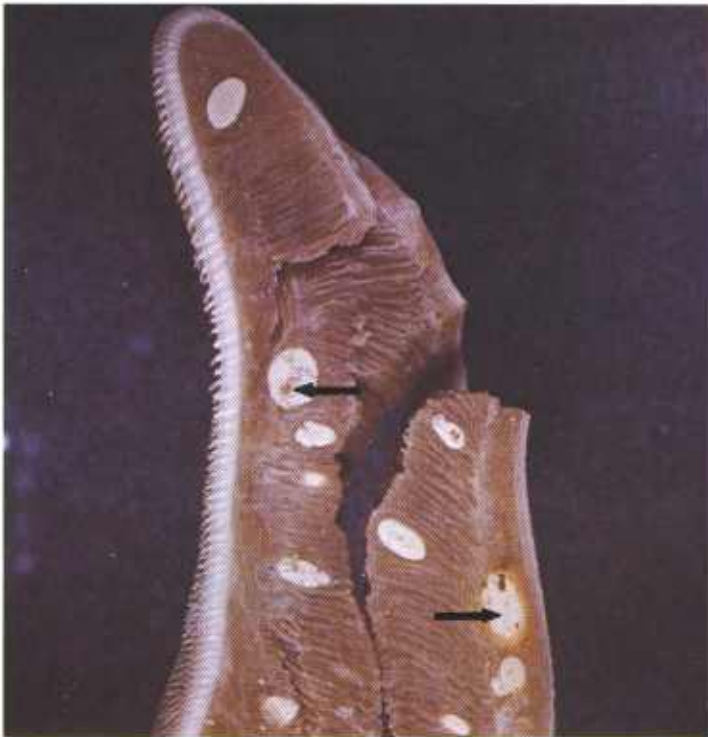

Figure 320.—Cysticercosis of the tongue of a 10-year-old cow (D32-D1757). The tongue has been incised several times by the meat inspector. White calcified cysts (arrows) are present in the musculature of the tongue.

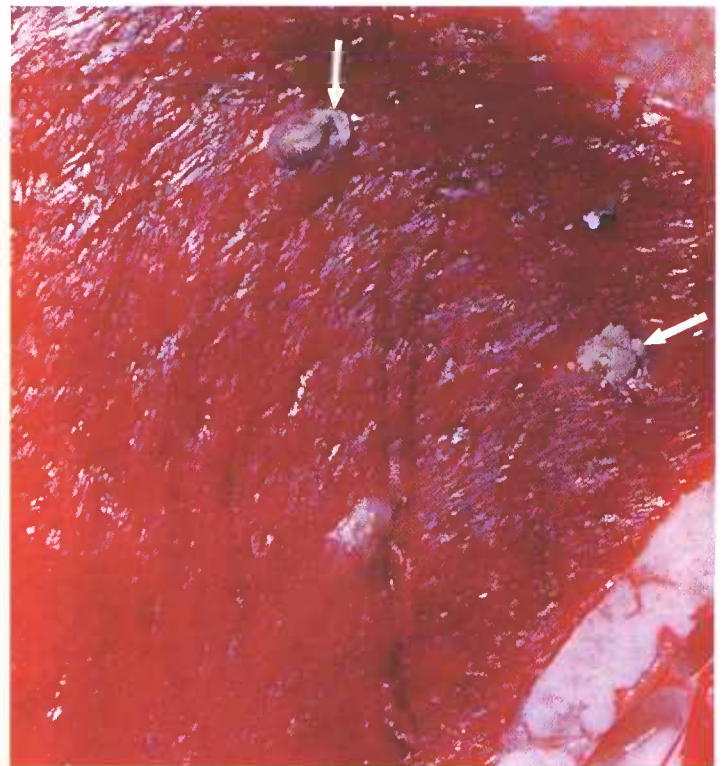


Figure 321.—Cysticercosis of the heart of a 2-year-old steer (D31-D1721). Multiple white, calcified cysts (arrows) are present in the myocardium.

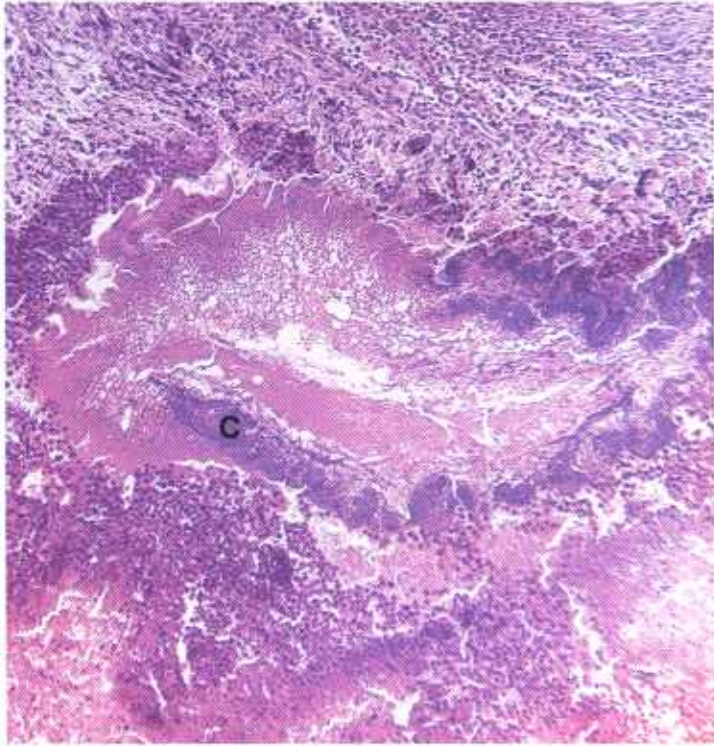


Figure 322.—A histologic preparation of one of the cysts (D31-D1721) shown in figure 321. The mineralized cyst (C) is surrounded by chronic inflammatory tissue. Hematoxylin-eosin stain.  $\times 50$ .

Once the parasite encysts, the inflammatory reaction disappears.

**Microscopic appearance.**—An acute myositis is present in the vicinity of the parasite when it first invades the muscle. Later, the inflammatory reaction becomes chronic and lymphocytes and macrophages are the predominating cells in the exudate. The inflammatory reaction is usually slight even though the parasite is quite large. Animals that have been sensitized by previous infections may have a heavy infiltration with eosinophils

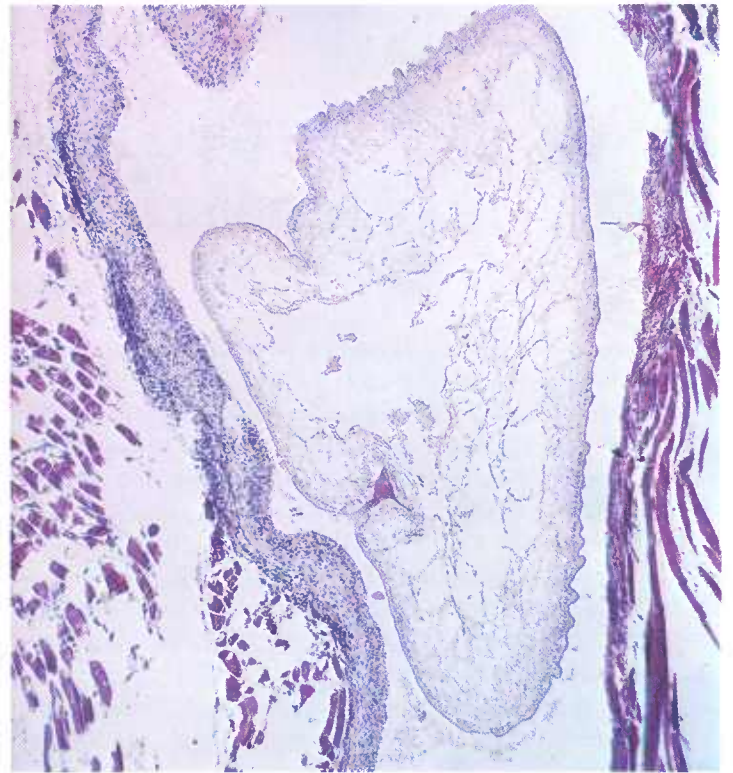

Figure 323.—A histologic preparation of a tapeworm cyst (129434). Hooks are present on the head of the larva. Hematoxylin-eosin stain.  $\times 75$ .

in the tissues in the vicinity of the parasite and along its route of migration through the host.

The cyst wall is composed of two layers. One is produced by the larva and the other by the host. As the cyst enlarges, pressure atrophy of the surrounding musculature occurs. When the parasite dies, the fluid of the cyst becomes cloudy and eventually both the fluid and the parasite become mineralized. At times, the cyst is invaded with macrophages that phagocytose the necrotic parasite as well as the cyst itself, and the area is then filled in with connective tissue.

## Demodectic Mange

**Definition.**—Demodectic mange is a skin disease that is caused by *Demodex folliculorum* var. *bovis*, *suis*, or *caprae*.

**Distribution and incidence.**—The disease is found throughout the United States. It is seldom a great problem in domesticated farm animals.

**Macroscopic appearance.**—Demodectic mange in goats, which usually occurs in pregnant animals, is characterized by an eruption of cutaneous cysts that vary in size from 1 mm. to 1.5 cm. in diameter and protrude above the surrounding skin surface. Lesions occur as single or multiple cysts in the skin of the neck, shoulder, side, abdomen, and thigh. The number of cysts present usually ranges from 1 to 35. When pressure is applied to

the cyst a thick, oily, sebaceous material can be expressed through the opening of the hair follicle.

In pigs, the disease involves the thin skin of the ventral underline, extending from the snout along the ventral cervical, thoracic, and abdominal regions to the flanks and the medial surface of the thighs. The lesions appear as protruding cysts in the skin and measure 1 mm. to 1 cm. in diameter.

Lesions in cattle appear as cysts in the skin over the withers, lateral surface of the neck and shoulders, and around the ears. There is no loss of hair or itching. In sheep, mites are found in the Meibomian glands and hair follicles of the eyelids and in the skin of the prepuce and vulva. Occasionally, the skin of the back and flanks

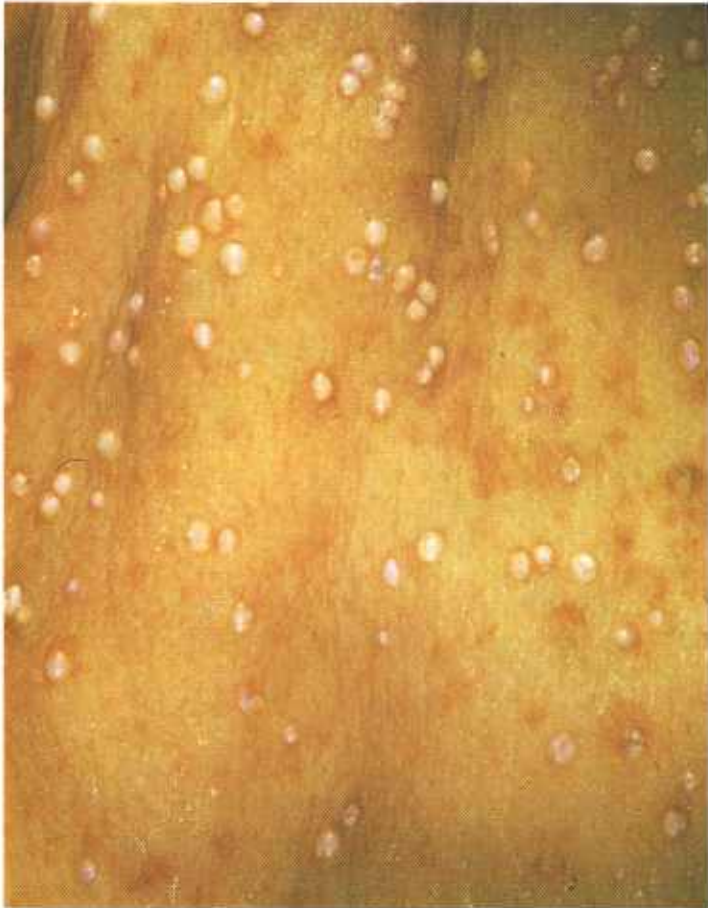

Figure 324.—Demodectic mange of the skin of a 2-year-old sow (D60-D2844). Multiple white, protruding nodules are present in the skin.

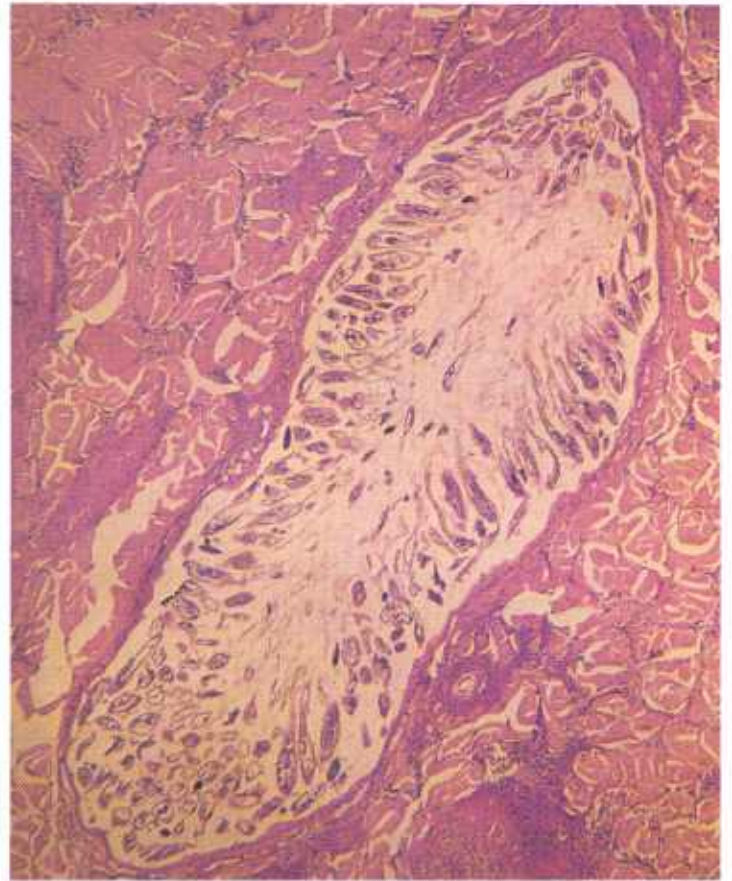


Figure 326.—A histologic preparation of one of the nodules of the demodectic mange specimen (D60-D2844) shown in figure 324. The cyst contains many cross sections of demodectic mites. Hematoxylin-eosin stain.  $\times 50$ .

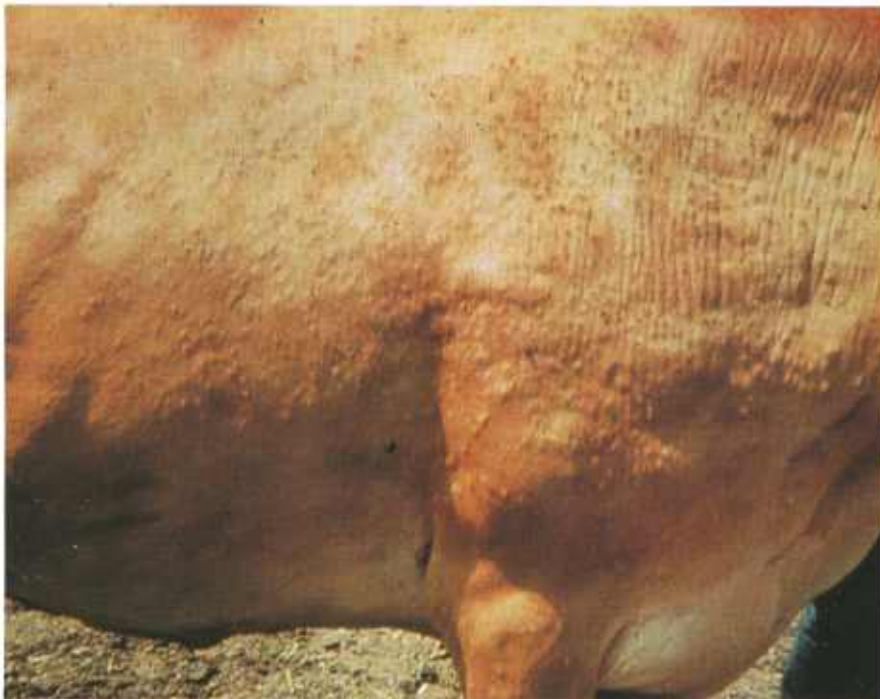

Figure 325.—Demodectic mange of the skin of a cow (RB200). Multiple nodules are present in the skin.

is involved. Because of itching, the wool is pulled out. The skin is hyperplastic and covered with keratinized epithelium in the form of scales. In some animals a pustular dermatitis appears in the areas of infection.

**Microscopic appearance.**—Lesions consist of large epidermal cysts that contain a mass of mites in various stages of development, mite eggs, desquamated epithelial

cells, and sebaceous secretion. A slight hyperplasia of connective tissue is present in the tissues immediately surrounding the cyst. Occasionally, bacteria invade the lesion and cause a focal suppurative inflammation. Epidermal inclusion cysts are frequently confused with demodectic mange lesions but do not contain mites, eggs, and associated debris.

## Echinococcosis

**Definition.**—Echinococcosis is the invasion of tissues by the larvae of *Echinococcus granulosus*.

**Distribution and incidence.**—Echinococcosis is found throughout the United States but is most frequently observed in the southeastern part of the country. The adult tapeworm, *Echinococcus granulosus*, inhabits the intestinal tract of dogs, wolves, foxes, and coyotes. All domesticated animals can be invaded by the larvae of the parasite, but it is of most importance in cattle, swine, and sheep.

Infection occurs with the ingestion of food or water contaminated with the eggs of the tapeworm. The embryonated eggs hatch in the lumen of the intestine and the liberated larvae penetrate the wall of the intestine. Once in the wall of the intestine, they may either invade the blood stream and be carried to the liver or enter a lymph vessel and be transported to the lungs. Larvae may lodge in the liver or lung, or they may pass through these structures to invade other organs. Although any organ of the body may be invaded, the principal location of the cysts is in the liver and lungs.

**Macroscopic appearance.**—Wherever the larvae of *E. granulosus* lodge, cysts are formed. These cysts are 1 to 10 cm. in diameter and are filled with a clear fluid. As the cysts enlarge they cause pressure atrophy of the surrounding tissue. Cysts are normally spherical but will mold their shape according to local tissue pressure. Elongated and indented shapes are produced when the cysts press against bile ducts, blood vessels, or bronchi. Cysts located within the bone marrow grow around and between the trabeculae and form irregularly shaped structures.

Daughter cysts, external to the mother cyst, are formed when the cyst wall is injured or when the spherical shape of the cyst is modified by external pressure. These daughter cysts protrude into the tissues surrounding the primary cysts and may or may not be attached to the original cyst. The result of this accessory daughter-cyst formation is seen when the organ is incised and its honeycomb appearance is revealed. The honeycomb effect is produced by the presence of multiple single cysts or a series of communicating vesicles.

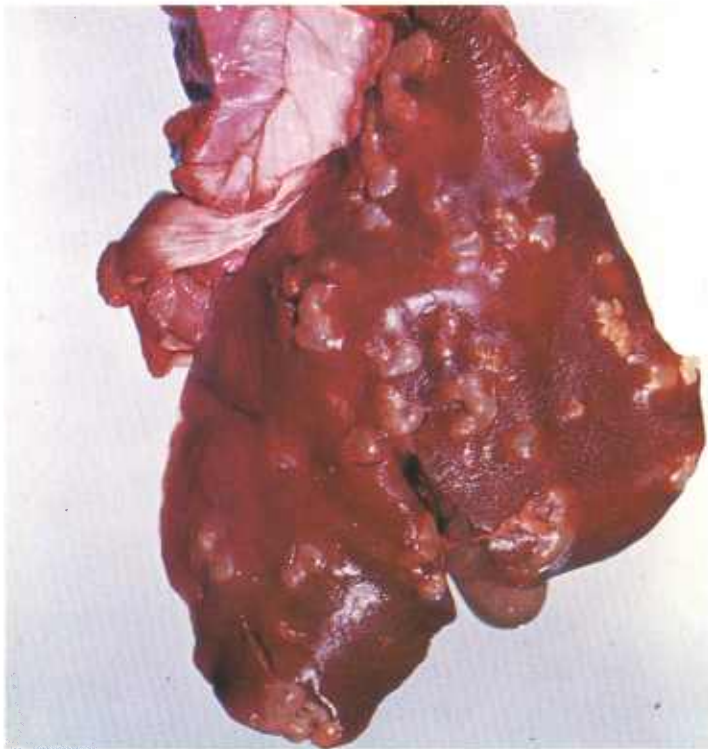


Figure 327.—Multiple *Echinococcus granulosus* cysts are present in the liver of a sheep (128971).

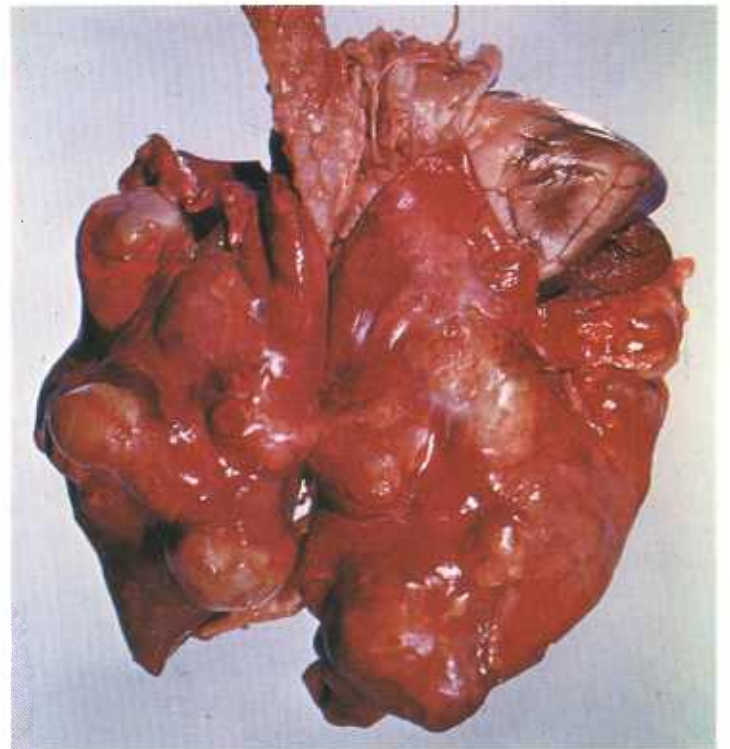


Figure 328.—Multiple *Echinococcus granulosus* cysts are present in the lung of a sheep (128971).

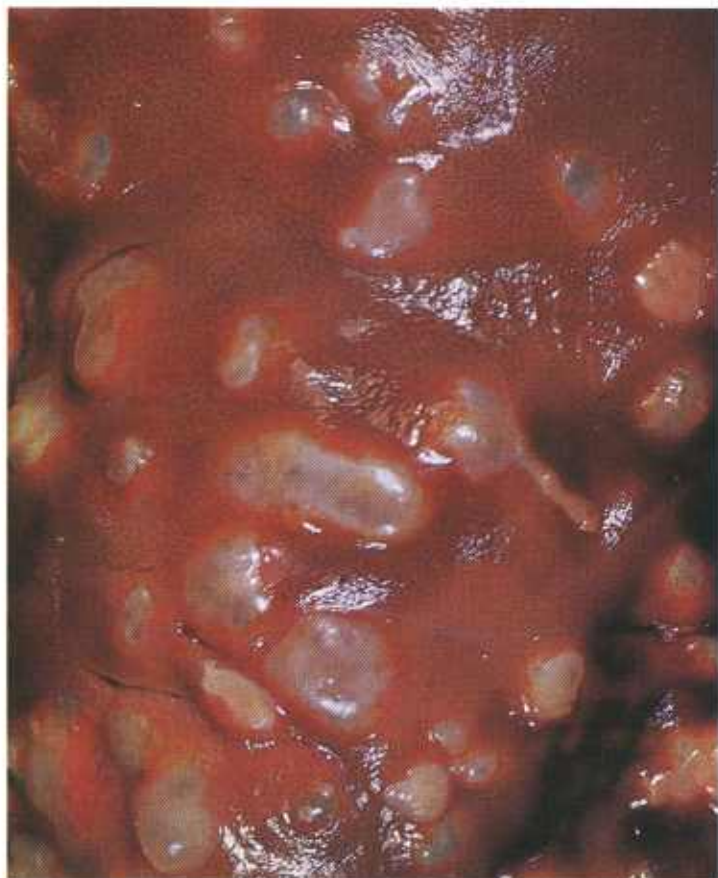

Figure 329.—*Echinococcus granulosus* cysts in the liver of a 5-year-old sheep (128237).

Occasionally this type of daughter-cyst formation has malignant characteristics, for it will infiltrate the entire organ, penetrate blood and lymph vessels, and metastasize to distant organs. Daughter cysts are also formed within the mother cyst. These daughter cysts have typical laminated cuticles, are lined with germinal epithelium, and are capable of producing brood capsules.

**Microscopic appearance.**—The cyst wall is composed of a fairly thick external concentrically laminated cuticle. Within this external capsule is a layer of germinal epithelium that produces the fluid of the cyst as well as its brood capsules. Each brood capsule may contain 1 to

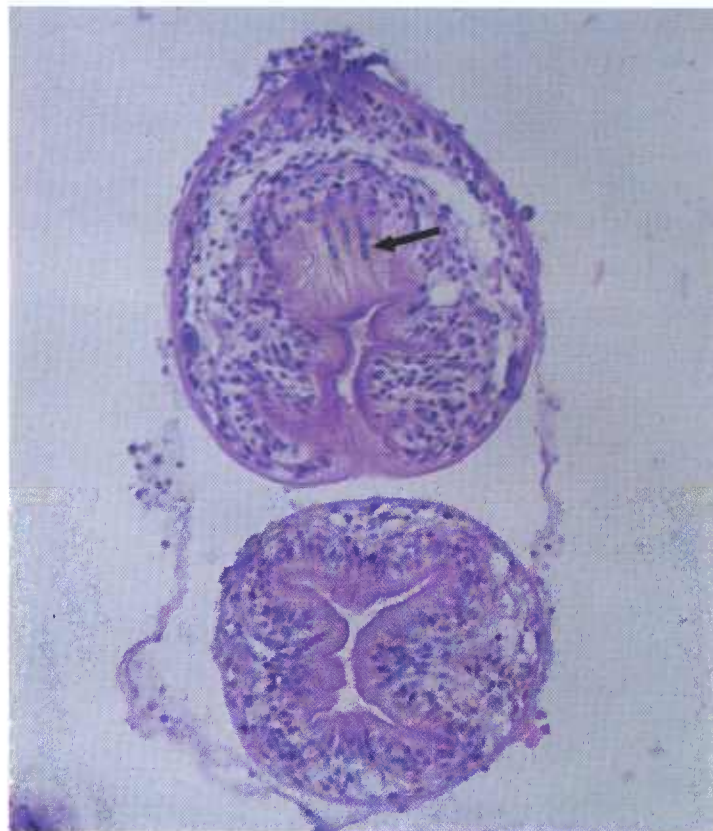


Figure 330.—A histologic preparation of two scolices of *Echinococcus granulosus* from the liver of a 10-month-old hog (D350). Hooks (arrow) are present in one scolex. Hematoxylin-eosin stain.  $\times 450$ .

40 invaginated scoleces attached to the wall of the brood capsules by narrow stalks.

Each hexacanth scolex is capable of producing a new cyst. Many of the brood capsules become detached from the cyst wall and float freely in the vesicular fluid in the form of small granules ("hydatid sand"). If the cyst wall is ruptured, the compressed vesicular fluid gushes forth and some of the scoleces are carried with it. Wherever the scoleces lodge, as on the peritoneal or pleural surface, new cysts can be formed. About 90 percent of the cysts in cattle, 20 percent of the cysts in pigs, and 8 percent of the cysts in sheep are sterile and do not contain scoleces.

## Fascioliasis

**Definition.**—Fascioliasis is the invasion of the liver and other tissues or organs by the fluke, *Fasciola hepatica*.

**Distribution and incidence.**—Fascioliasis is an extremely common disease of ruminants in those areas of the southern and western United States where snails, intermediate hosts in the life cycle of *F. hepatica*, are found. The disease is especially serious in swampy or irrigated pastures, the natural habitat of snails.

When the eggs of *F. hepatica* hatch, liberated miracidia invade the first hosts (snails) and develop into

sporocysts. Each sporocyst gives rise to five to eight rediae. The rediae develop into cercariae and the latter leave the snail  $4\frac{1}{2}$  to 7 weeks from the time of infection. The liberated cercariae encyst on vegetation. When the encysted infective cercariae are eaten by the final host (ruminant), the cercariae escape from their cysts and burrow into the intestinal wall. Their usual route of migration from the intestine to the liver in the final host is through the peritoneal cavity. The cercariae (young flukes) migrate through the peritoneal cavity for about a week, then penetrate the liver capsule and wander

in the hepatic parenchyma for a month or more until they reach the bile ducts. Once the flukes enter the bile ducts, they remain in them for the rest of their lives. The flukes become mature in 2 to 3 months from the time of infection of the definitive host. The left half of the liver is more extensively involved than the right. When massive fluke infections occur, hepatic damage



Figure 331.—Flukes (*Fasciola hepatica*) removed from a bile duct of a 9-month-old gilt (D70-3125).

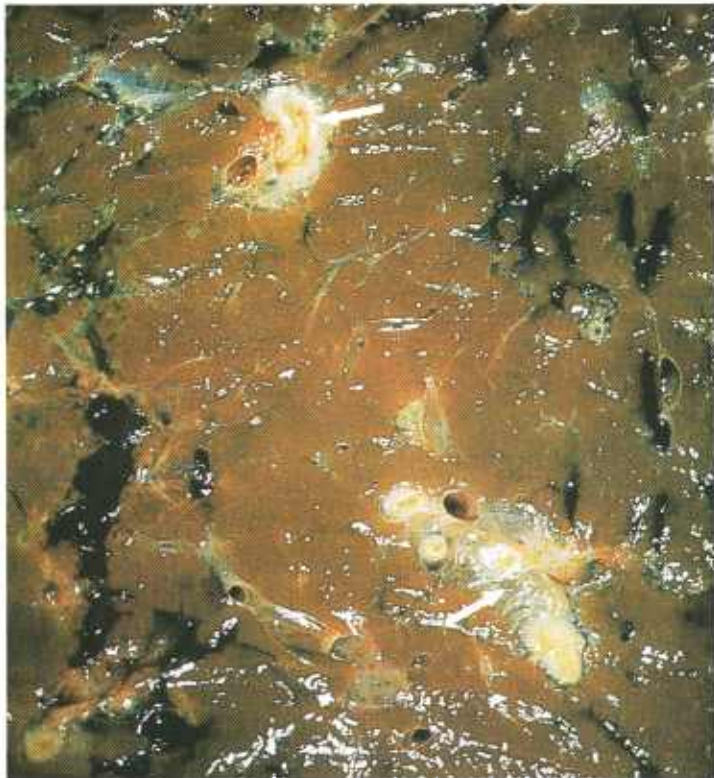


Figure 332.—Fascioliasis of the liver of a 5-year-old cow affected with *Fascioloides magna* (D44-D2032). The bile ducts (arrows) are prominent as the result of a chronic inflammatory response to the presence of flukes. Streaks of black pigment are present in the hepatic parenchyma.

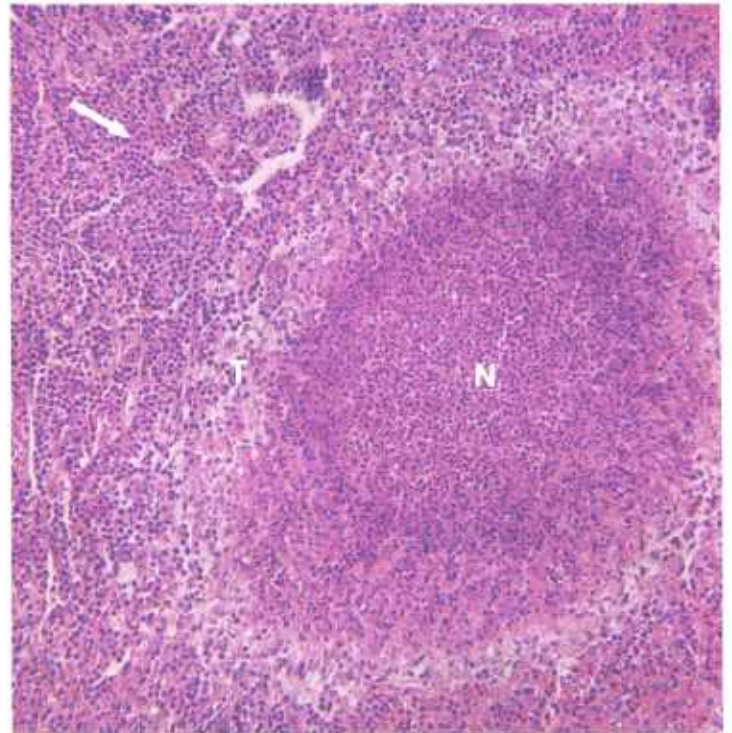


Figure 333.—Fascioliasis of the liver of a 5-year-old cow (D1336) affected with *Fascioloides magna*. A central area of liquefactive necrosis (N), where the fluke migrated through the hepatic parenchyma, is surrounded by a zone of chronic inflammatory tissue (T) that contains many eosinophils (arrow). Hematoxylin-eosin stain.  $\times 125$ .

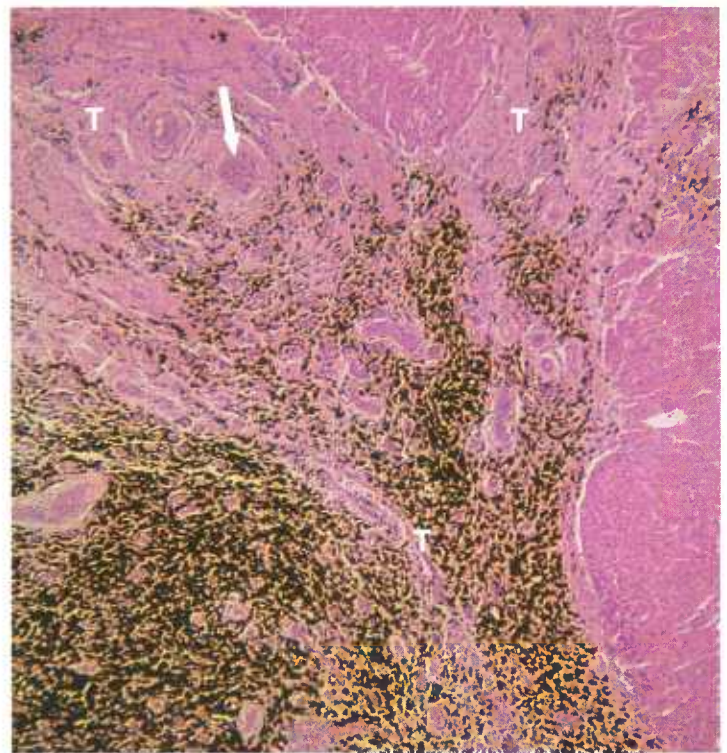


Figure 334.—Fascioliasis of the liver of a 2-year-old steer (D526) affected with *Fascioloides magna* and *Fasciola hepatica*. The liver is cirrhotic, with an abundance of connective tissue, hyperplastic bile ducts, and thick-walled blood vessels (arrow) in the hepatic triad (T). An abundance of dark-brown pigment, hemo-toporphyrin, is present. Hematoxylin-eosin stain.  $\times 50$ .

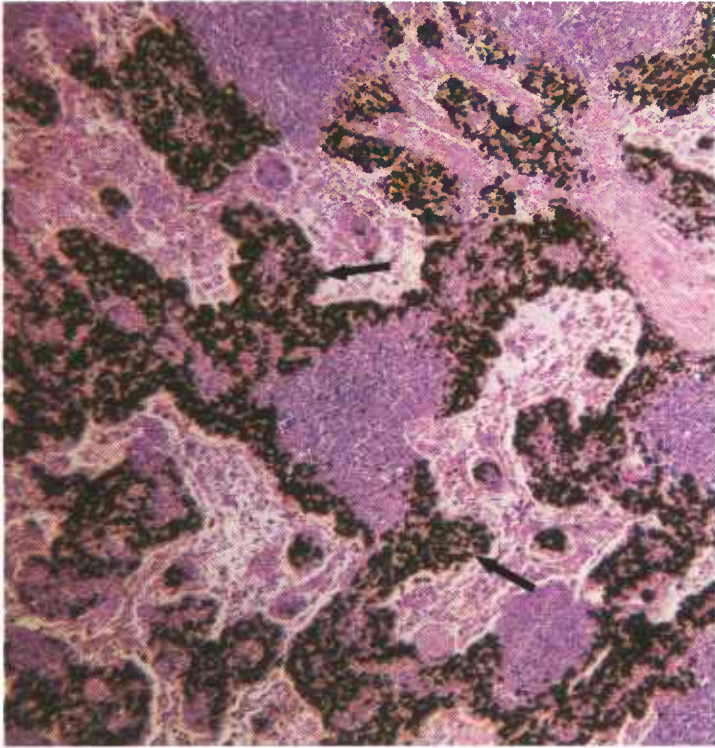


Figure 335.—Fascioliasis of the portal lymph node of a 2-year-old steer (D526) affected with *Fascioloides magna* and *Fasciola hepatica*. An abundance of dark-brown pigment, hematoporphyrin, is present in the sinuses of the node (arrows). Hematoxylin-eosin stain.  $\times 50$ .

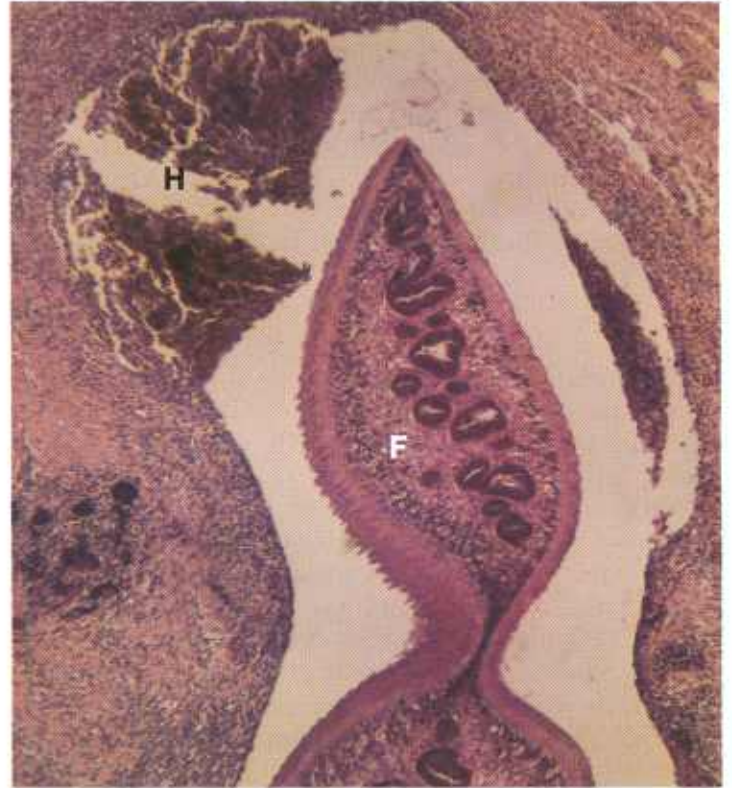

Figure 337.—Fascioliasis of the lung of an old cow (D470). A cross section of a fluke (F) is visible. Brown hematoporphyrin and cellular debris (H) can be seen near the parasite. Hematoxylin-eosin stain.  $\times 50$ .

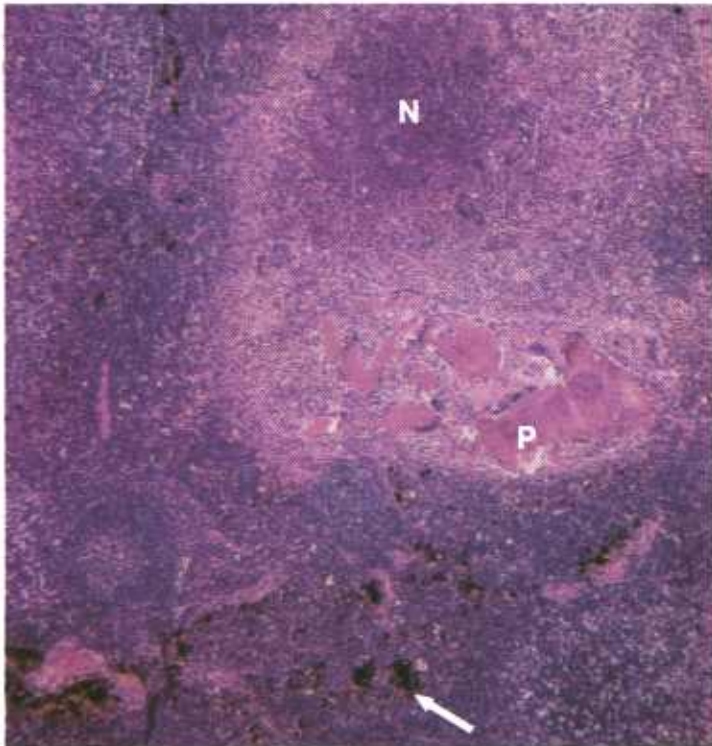


Figure 336.—Fascioliasis of the portal lymph node of a 5-year-old cow (D1336) affected with *Fascioloides magna*. An area of liquefactive necrosis (N) and chronic inflammation is present in the vicinity of the remains of a parasite (P). A dark-brown pigment (hematoporphyrin) is present in the parenchyma of the node (arrow). Hematoxylin-eosin stain.  $\times 50$ .

caused by migrating parasites may be so great that it will cause the death of the host.

Although the liver is the principal organ favored by adult flukes, they can be found in any organ of the body, including the lung. A few of the young flukes penetrate blood vessels and are carried by the blood stream to unusual sites, such as the fetuses in pregnant animals.

**Macroscopic appearance.**—No appreciable damage is done during the migration of the parasite through the intestinal wall and the peritoneal cavity unless massive infections occur. Focal peritonitis is produced at those points where the cercariae penetrate the intestinal peritoneum (to which they attach themselves for a period to suck blood during their transperitoneal migration), and where they penetrate the capsule of the liver. (This peritonitis is particularly severe in cattle.) After the peritonitis heals, tufts of scar tissue remain attached to the areas of peritoneal injury.

The line of migration of the young flukes through the hepatic parenchyma can be seen as a meandering streak of hemorrhage. When the flukes enter the bile ducts they produce a chronic productive cholangitis. Affected bile ducts become greatly enlarged, gray or white cord-like structures that correspond to the distribution of the bile ducts in the hepatic parenchyma. Here and there along the course of the ducts are saccular dilations containing flukes, fluke eggs, bile, choleliths, mucus, and a black pigment (hematoporphyrin).

**Microscopic appearance.**—The route of migration of a young fluke through the liver is a path of mechanical injury containing degenerating or necrotic hepatic cells, partially metabolized blood, and hematoporphyrin. When healing occurs the migratory route of the parasite persists as a streak of scar tissue pigmented with hemosiderin and hematoporphyrin.

Chronic cholangitis is present in those bile ducts con-

taining flukes. The ductal epithelium is hyperplastic and the lumens of the ducts contain papillomatous protrusions of the hyperplastic mucous membrane. Exudate and dead flukes in the lumens of the affected bile ducts are frequently mineralized (choleliths). The walls of the affected bile ducts are infiltrated with white fibrous connective tissue, lymphocytes, macrophages, and giant cells.

## Onchocerciasis of Cattle

**Definition.**—Onchocerciasis is the invasion of tissues by various species of *Onchocerca*. *Onchocerca gibsoni* is the most important parasite of this genus in meat-producing animals.

**Distribution and incidence.**—*O. gibsoni* infections of cattle are found in many localities in the United States. Since the adult parasite is usually not present in old lesions, the true nature of the calcified subcutaneous masses that characterize this disease is not recognized and the masses are considered to be foci of chronic inflammation and fat necrosis resulting from some type of mechanical injury (thorn or plant-barb penetrations, puncture wounds, or contusions).

*O. gibsoni* is an elongated filariform worm with a transversely striated cuticle bearing characteristic spiral

thickenings. The male is 30 to 53 mm, in length and the female is 10 to 50 cm. The female is viviparous and produces unsheathed microfilaria 240 to 280 microns in length. In the living animal, microfilaria can be demonstrated in the dermal and subcutaneous lymph in the vicinity of the encapsulated parasite, and occasionally in the blood stream.

*Onchocerca* are transmitted by *Culicoides* sp. After the microfilaria are introduced into the tissues of the host, they mature and wander about in the connective tissue, eventually locating in the subcutaneous tissues of the brisket and in the subcutaneous tissues of the lateral surfaces of the stifles. They occasionally locate in other subcutaneous sites or in intramuscular connective tissue. Wherever the parasite is found, its presence




Figure 338.—Onchocerciasis of the subcutaneous tissues in the vicinity of the left stifle joint of a 6-year-old cow (D20-D3569). The mass consists of chronic inflammatory tissue containing areas of necrosis that are partially calcified (arrows).

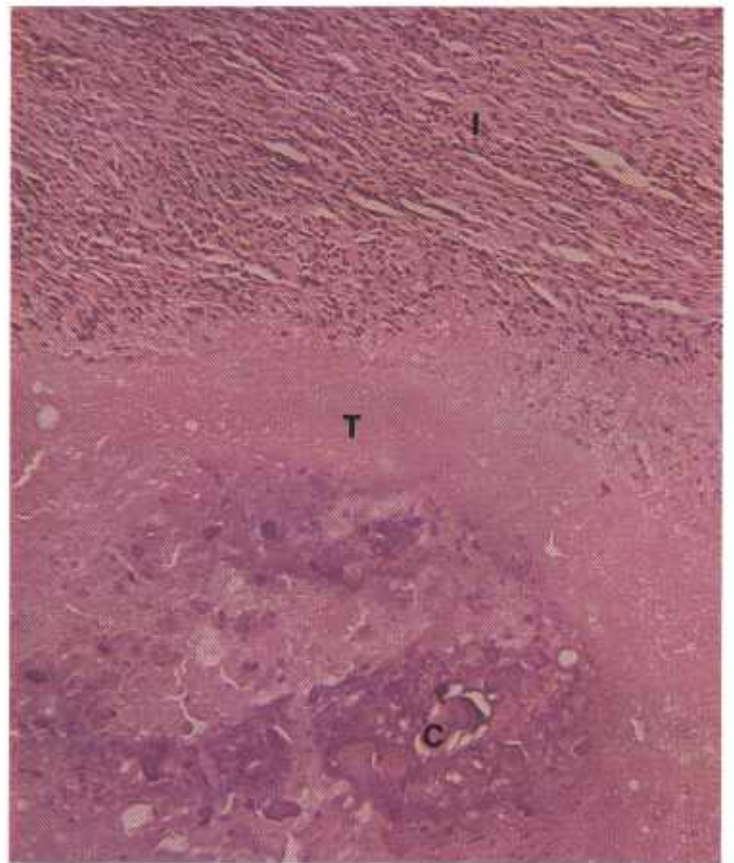


Figure 339.—A histologic preparation of the affected stifle (D20-D3569) shown in figure 338. The caseonecrotic tissue (T) is partially calcified (C) and is surrounded by chronic inflammatory tissue (I). Hematoxylin-eosin stain.  $\times 125$ .

causes an inflammatory reaction. This reaction is first manifested as an acute, and later as a chronic, inflammation. When the parasite dies, its remains and associated exudate become calcified.

Lesions on affected carcasses are unsightly and must be removed before the meat can be used for human consumption. This trimming can cause considerable financial loss when carcass parts (especially the brisket and round) are heavily parasitized.

**Macroscopic appearance.**—Postmortem lesions consist of firm, calcified, yellow, gray, or green nodular masses in the subcutaneous tissue. They are seldom more than 5 cm. in diameter and are ovoid or flattened because of compression between the skin and the underlying muscle or bone. Skin over the nodules may be slightly thickened. It is not certain whether the thickening is due to mechanical irritation from the exterior or to the presence of microfilaria in the skin.

**Microscopic appearance.**—An acute focal inflammatory reaction occurs early in the course of the disease. Neutrophils and eosinophils are the main constituents of the exudate in this stage. Later, the inflammatory reaction becomes chronic and the macrophage becomes the most prominent cellular constituent of the exudate. Lesser numbers of lymphocytes and a few giant cells are also present. The parasite and its associated caseonecrotic exudate gradually become enclosed within granulation tissue.

Microfilaria can be found in the adult parasite and in the surrounding exudate. Most of the microfilaria, however, leave the inflammatory tissue soon after they are liberated from the adult and migrate to the skin, where they may become quite numerous. Eventually the parasite dies and, with its associated exudate, becomes calcified; healing then occurs. Calcium salts and scar tissue usually persist in the area after healing has occurred.

## Pentastomiasis

**Definition.**—Pentastomiasis is the invasion of animals by the larval and nymphal forms of various species of the class Pentastomida.

**Distribution and incidence.**—Pentastomiasis is found throughout the United States. Adult parasites do not invade meat-producing animals, but their larvae and nymphs cause tissue alterations that are of concern to meat inspectors because these lesions may be confused with those of tuberculosis. All genera of meat-producing animals may be affected, but lesions are most commonly found in cattle.

Adult Pentastomida are degenerate, wormlike creatures that have no appendages except two pairs of hooks near the mouth. Larval forms have two or three pairs of short legs. The nymphs resemble the adults and are without legs. These parasites are arthropods, but like many of the parasitic worms, their larval and nymphal stages are found in the viscera of an intermediate host.

Adult parasites are found in the respiratory passages of various vertebrates, especially those of snakes, birds, dogs, and cats. Eggs of the adult worms are eliminated in the exudates of the respiratory passages. When the eggs are ingested by cattle, sheep, or other vertebrates, they hatch and the liberated larvae (which are about 75 microns long) migrate through the intestinal wall into the visceral tissues and organs where they encyst and develop into infective nymphs. The infective nymphs leave their cysts and wander in the body of the intermediate host. A severe inflammatory tissue reaction may occur along the route of nymphal migration. Heavy experimental infections have produced injurious and even fatal effects, but there is no evidence that the light infections found during meat inspection cause serious problems. Lesions of pentastomiasis are usually found in the mesenteric lymph nodes and, less commonly, in the liver, lungs, and heart.

**Macroscopic appearance.**—An inflammatory reaction, at first acute and later chronic, occurs along the route of larval and nymphal migration. The amount and severity of the tissue reaction depends upon the number of parasites present and the resistance of the host. Affected lymph nodes may be enlarged several times their normal size. The nodes are gray, buff, or green. They contain foci of caseous necrosis that are frequently calcified and are infiltrated with connective tissue.

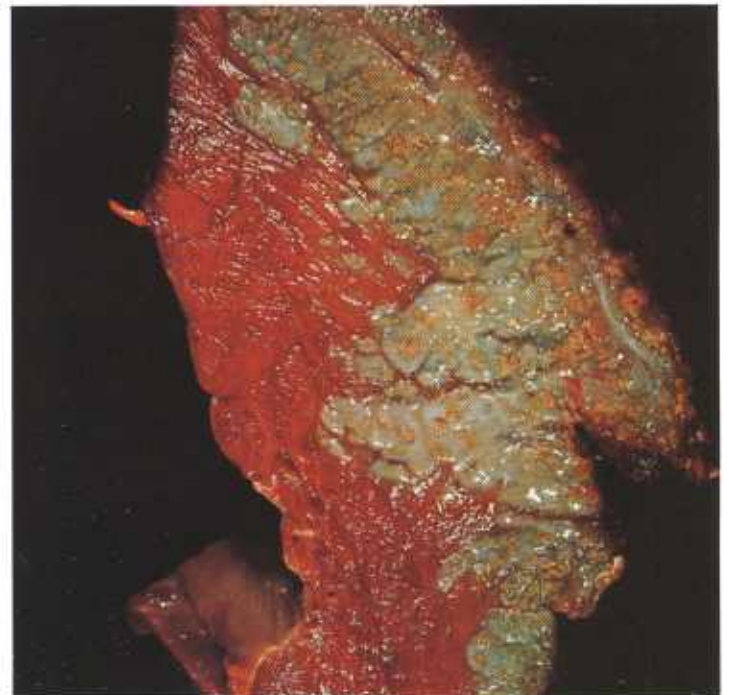

Figure 340.—Pentastomiasis of the heart of a 6-year-old cow (D48-D2051). Multiple green areas of chronic inflammation with yellow, partially calcified central foci of caseous necrosis are present in the myocardium.

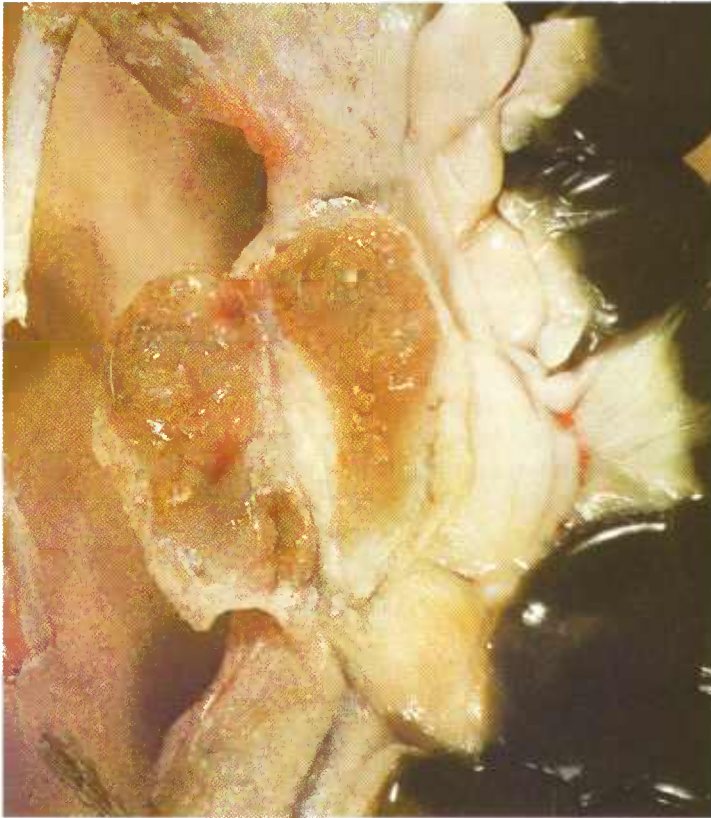


Figure 341.—Pentastomiasis of a mesenteric lymph node in a 1-year-old sheep (D57-D2449). The node is slightly green and contains multiple yellow areas of caseous necrosis.

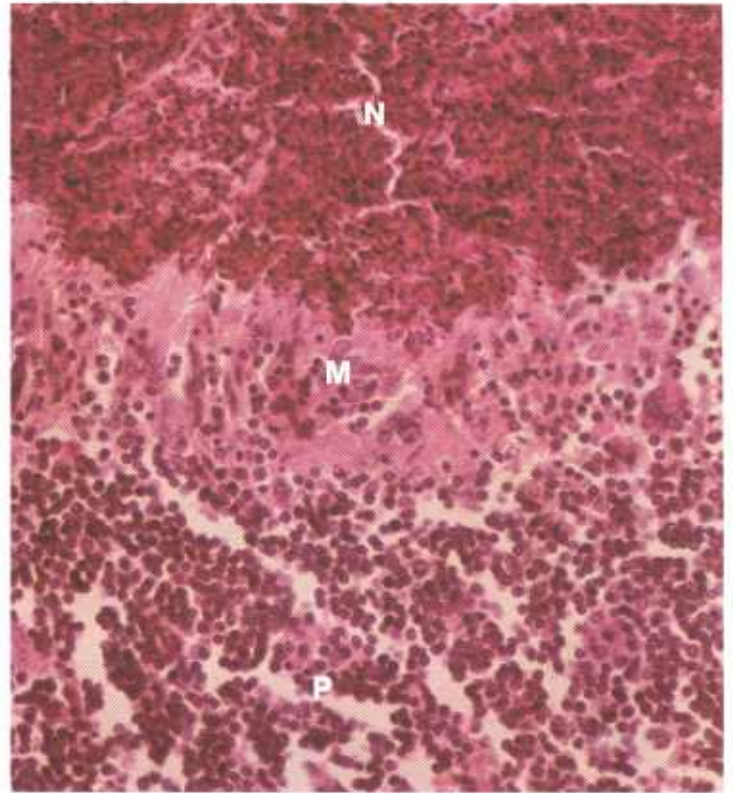


Figure 343.—A histologic preparation of the mesenteric lymph node (D57-D2449) shown in figure 341. A zone of macrophages (M) separates the necrotic tissue (N) from the lymph node parenchyma (P). Hematoxylin-eosin stain.  $\times 320$ .

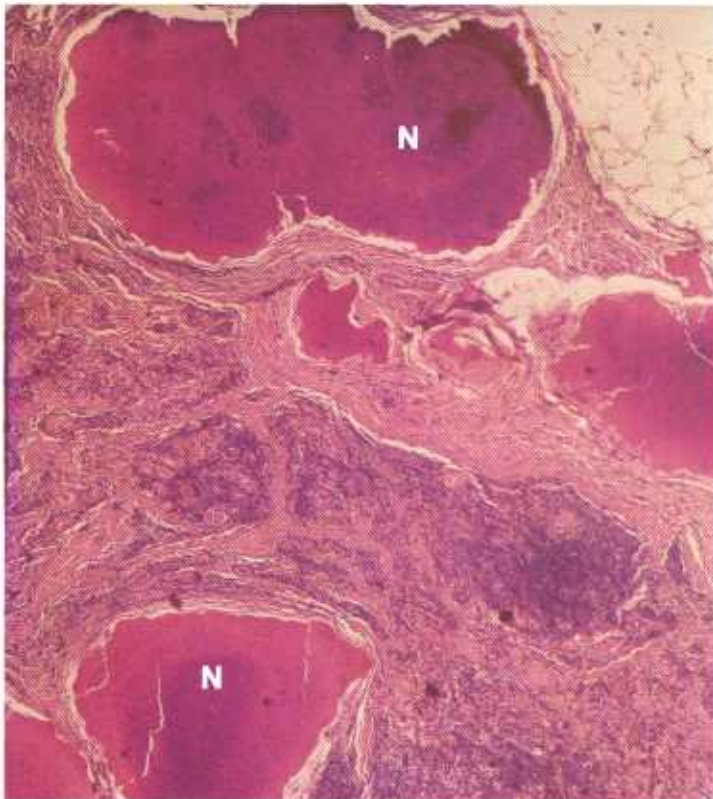


Figure 342.—Pentastomiasis of a mesenteric lymph node in a 5-year-old cow (D3067). Multiple foci of caseous necrosis (N) are surrounded by chronic inflammatory tissue. Hematoxylin-eosin stain.  $\times 20$ .

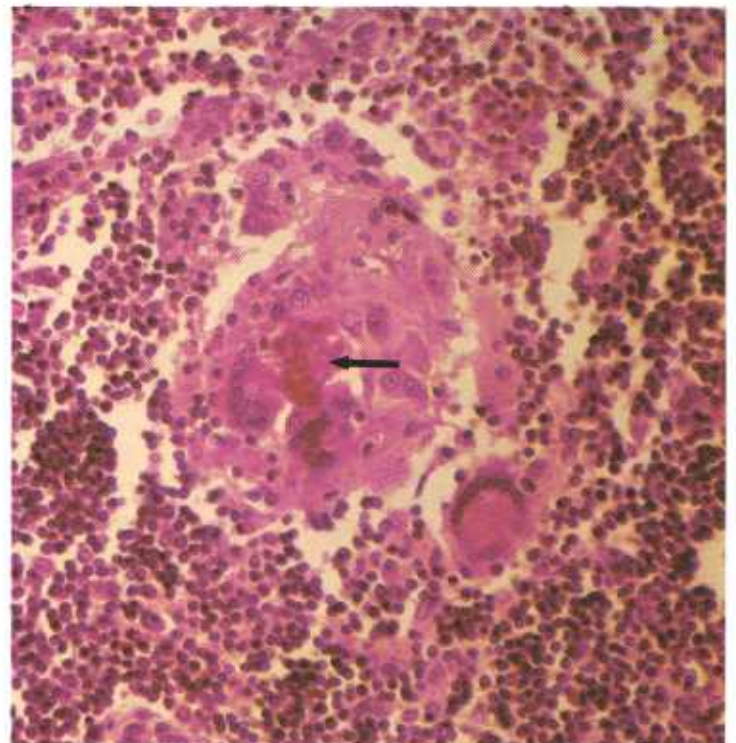


Figure 344.—A histologic preparation of the mesenteric lymph node (D57-D2449) shown in figure 341. A focus of macrophages and giant cells are surrounding a group of erythrocytes (arrow). The focus resembles a tubercle and could be confused with the alterations associated with tuberculosis. Hematoxylin-eosin stain.  $\times 320$ .

**Microscopic appearance.**—The first cellular response to the presence of these parasites is a local infiltration of the affected area with neutrophils and eosinophils, followed by an accumulation of macrophages, lymphocytes, plasma cells, and a few giant cells. As the inflammatory process progresses, macrophages and eosinophils become the predominating leukocytes in the exudate, some of the exudate becomes caseated and calcified, and the affected area becomes infiltrated with connective tissue. After a period of 6 months or more, the inflammatory response gradually subsides, although healing

is prolonged because of the presence of necrotic tissue and remains of parasites.

Diagnosis is based on the location of the lesions, the character of the tissue response (chronic inflammation containing eosinophils and giant cells), the demonstration of migration routes, the presence of intact larvae or nymphs or their remains, and the absence of other causative agents. Many of the lesions do not contain parasites. In these lesions, the parasites either have migrated to other locations or have died and have been phagocytosed.

## Sarcosporidiosis

**Definition.**—Sarcosporidiosis is a disease caused by the invasion of muscle with *Sarcocystis* sp.

**Distribution and incidence.**—Sarcosporidiosis is extremely common in animals throughout the United States and is most frequently observed in cattle, sheep, horses, pigs, and ducks. The life cycles of all species of *Sarcocystis* are not completely known, but apparently they are all direct ones and do not require an intermediate host.

The severe eosinophilic myositis of cattle, commonly attributed to sarcosporidiosis, has not been associated with an invasion of sarcosporidia. Experimentally, even though there are heavy infections with this parasite and even though the size of *S. tenella* is immense, the cysts are well tolerated by the host and, ordinarily, cause little tissue reaction. Meat containing many sarcocysts is unpalatable because the cysts, especially if calcified, resemble grains of sand.

**Macroscopic appearance.**—Sarcocysts occur in skeletal and cardiac muscles as white or yellowish-white elliptical or oval masses that are usually 0.5 to 4 mm. long and 0.3 to 0.6 mm. wide. *Sarcocystis tenella*, an exception, has larger sarcocysts (20 mm. long and 10 mm. wide) that are located in the cardiac region of the esophagus of sheep. Cysts of *S. tenella* are oval, white, nodular structures that are embedded in the esophageal musculature and that cause hemispherical swellings on the external surface of the esophagus. If the cysts are crushed, they discharge a white gelatinous material that contains elliptically shaped trophozoites.

The long axes of the cysts are arranged parallel with the course of the muscle fibers. The size and shape of the cysts depend upon the compactness or looseness of the involved muscle. Cysts located in firm, dense muscle, such as the diaphragm, are small and elongated. Cysts located in the loose muscle and connective tissue of the esophagus, tongue, pharynx, and palate are usually large and oval.

**Microscopic appearance.**—When trophozoites occurring either singly or within cysts are ingested by a suitable host, they become motile and those trophozoites within cysts are liberated from their enclosing cyst walls. The motile trophozoites invade the intestinal wall and are transported by the blood and lymph streams to

skeletal and cardiac muscles. Other tissues and organs (smooth muscle and brain) are occasionally invaded. The motile trophozoites invade muscle cells and develop into trophoblasts. The trophoblasts reproduce by binary fission and as they multiply they produce an enveloping cyst wall. As the cyst matures, it becomes divided into chambers and the enclosed trophoblasts develop into ellipsoidal trophozoites. When the cyst is mature, the cell wall ruptures and the liberated motile trophozoites find their way into the blood stream that transports them to the intestinal tract where they are eliminated in the feces. The remains of the empty cyst in the muscle are phagocytosed. A small amount of scar tissue may persist in the muscle where the cyst was located.

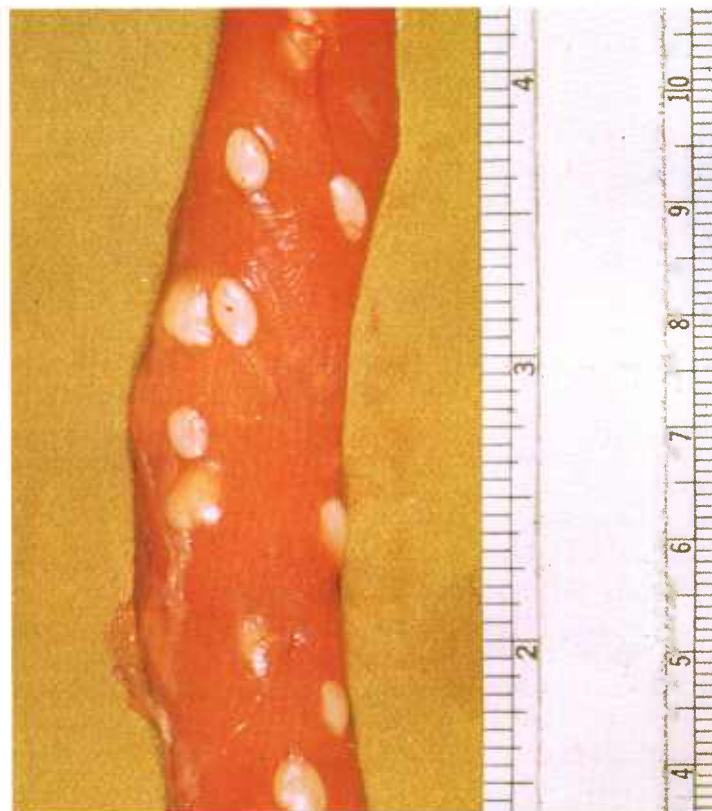

Figure 345.—Sarcosporidiosis of the esophagus of a ewe (D10-127736). White cysts of *Sarcocystis tenella* are protruding externally from the musculature of the esophagus.

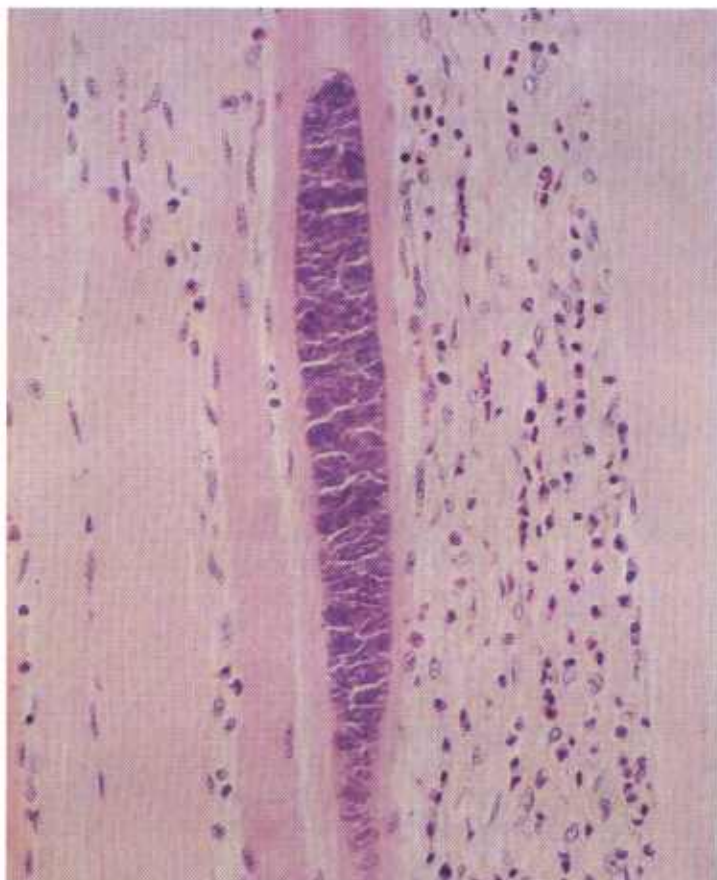


Figure 346.—Sarcosporidiosis of the tongue of a 3-month-old calf (127509). A muscle cell contains an elongated cyst filled with many trophozoites. Hematoxylin-eosin stain.  $\times 125$ .

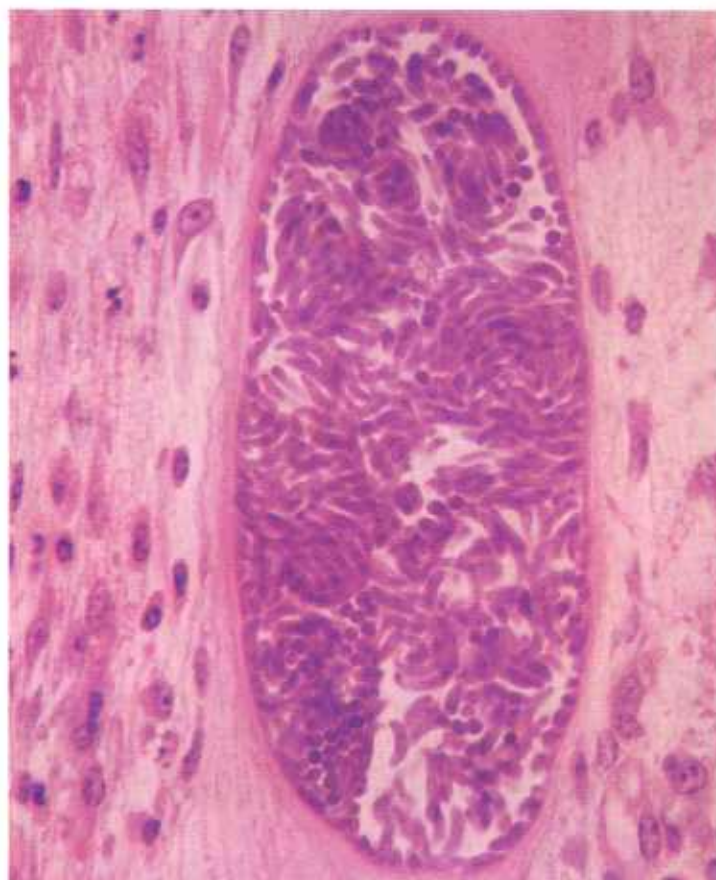


Figure 347.—Sarcosporidiosis of the heart of an 8-year-old Hereford cow (D2827). A muscle cell contains an elliptical cyst filled with many trophozoites. Hematoxylin-eosin stain.  $\times 500$ .

## Stephanofilariasis

**Definition.**—Stephanofilariasis is a chronic dermatitis of cattle caused by *Stephanofilaria stilesi*.

**Distribution and incidence.**—The parasite is quite widely distributed throughout the United States but is most frequently observed in South Dakota, Colorado, Wyoming, Nebraska, Texas, and New Mexico. Stephanofilariasis does not kill cattle, but its lesions are unsightly and are irritating to the host animals, and it causes some loss in hides because the affected areas must be discarded.

Stephanofilariasis is observed in cattle that are more than 2 years of age. Calves are seldom affected. The disease is most prevalent during hot, moist, humid weather. Its lesions are usually found in the skin of the ventral surface of the abdomen, sheath, and scrotum, but are occasionally observed on the medial surface of the stifle and on the ventral surface of the brisket. Skin lesions of stephanofilariasis must not be confused with lesions of acute or chronic dermatitis occurring as the result of mechanical injury when the skin of the abdo-

men and thorax is pressed against the floor or bedding when cattle are recumbent. The lesions, especially those occurring in the skin of the brisket of range cattle, may also be confused with the chronic inflammation caused by mechanical injury from thorns and plant barbs.

Active lesions of stephanofilariasis that are exuding blood and serum may become invaded by fly larvae. This invasion is especially serious when the maggots are screwworm larvae.

The life cycle of the parasite has not been determined. It is postulated that the vector is a blood-sucking arthropod, such as the horn fly. These flies congregate in large numbers on the lesions, especially on those oozing serum and blood.

**Macroscopic appearance.**—The skin lesions of stephanofilariasis are circular, dry, raised, gray areas of hyperkeratosis that measure from 2 to 15 cm. in diameter and 0.5 to 2 cm. in thickness. Their surfaces are covered with epidermal scales and contain cracks and crevices. Hair may or may not be present in the involved

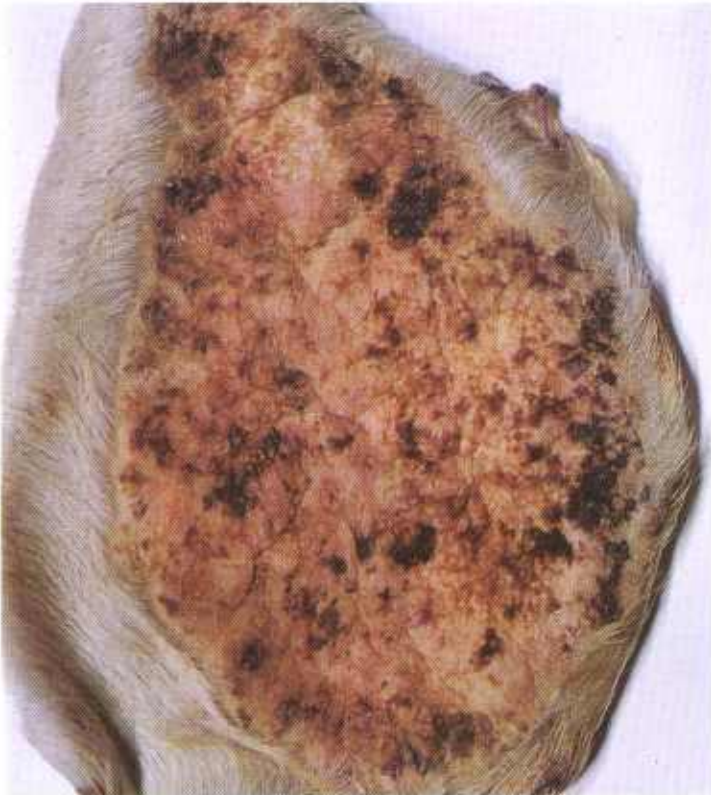

Figure 348.—Stephanofilariasis of the skin of a bovine animal (DWB105). There is a chronic dermatitis with crusts of exudate on the skin surface.

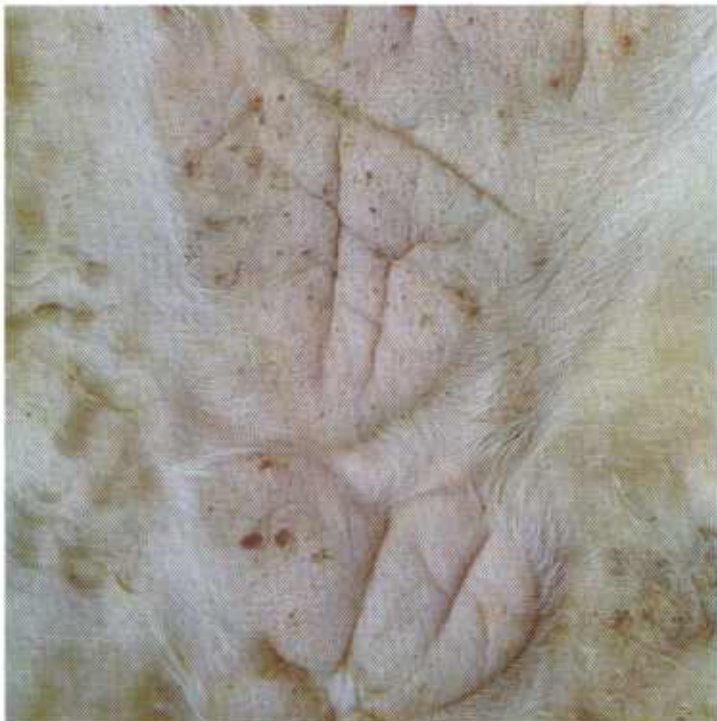

Figure 349.—Stephanofilariasis of the skin of a bovine animal (DWB106). The parasitic dermatitis is healing and only a small amount of exudate is now present on the skin surface.

areas. In the more active lesions, crusts of blood and serum are present on the surface of the affected skin. Healed lesions are smooth, hairless, thickened areas of skin.

**Microscopic appearance.**—Examination of the skin reveals a chronic suppurative parasitic dermatitis containing cross sections of larvae and adults. The principal cellular defense reaction is the accumulation of macrophages and lymphocytes in the involved area. Neutrophils and eosinophils are present in the immediate vicinity of the parasites. Hyperplasia and hyperkeratosis of the epithelium and hyperplasia of connective tissue are prominent alterations in the skin lesions.

If the skin lesions are scraped with a sharp knife and the scrapings are suspended in a warm physiological saline solution and examined with a microscope, the adult parasites and their larvae can be demonstrated. Parasites are easily discerned in the more active lesions, but they are difficult to find in old chronic lesions. It is imperative that deep scrapings be made. One of the principal reasons that parasites are not demonstrated is that the skin scrapings are too superficial.

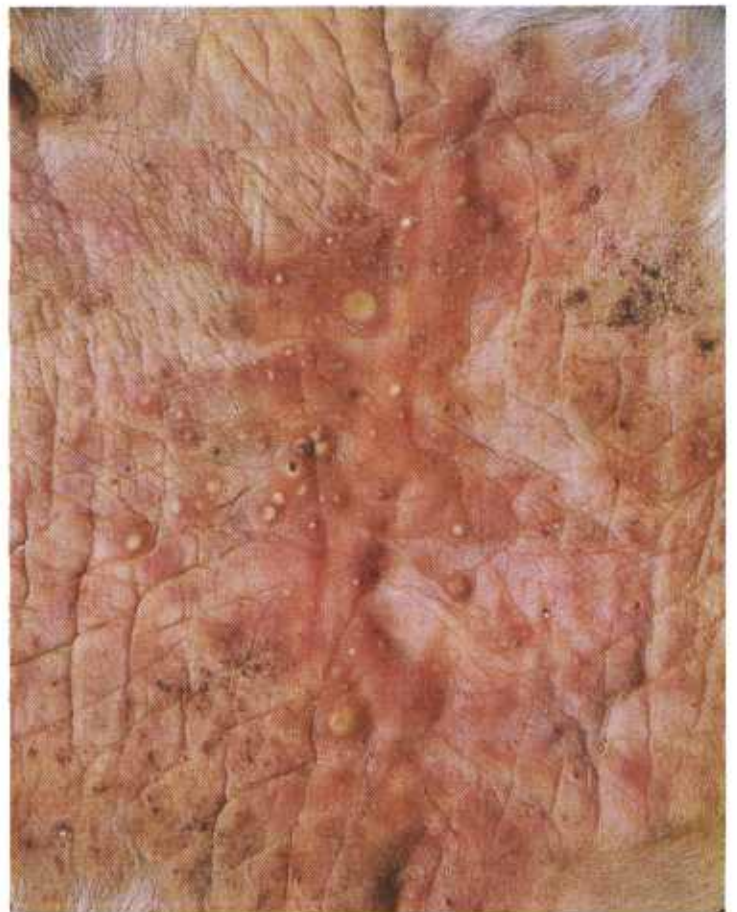

Figure 350.—Stephanofilariasis of the skin of a bovine animal (DWB107). Multiple abscesses are present in the skin as the result of bacterial invasion.

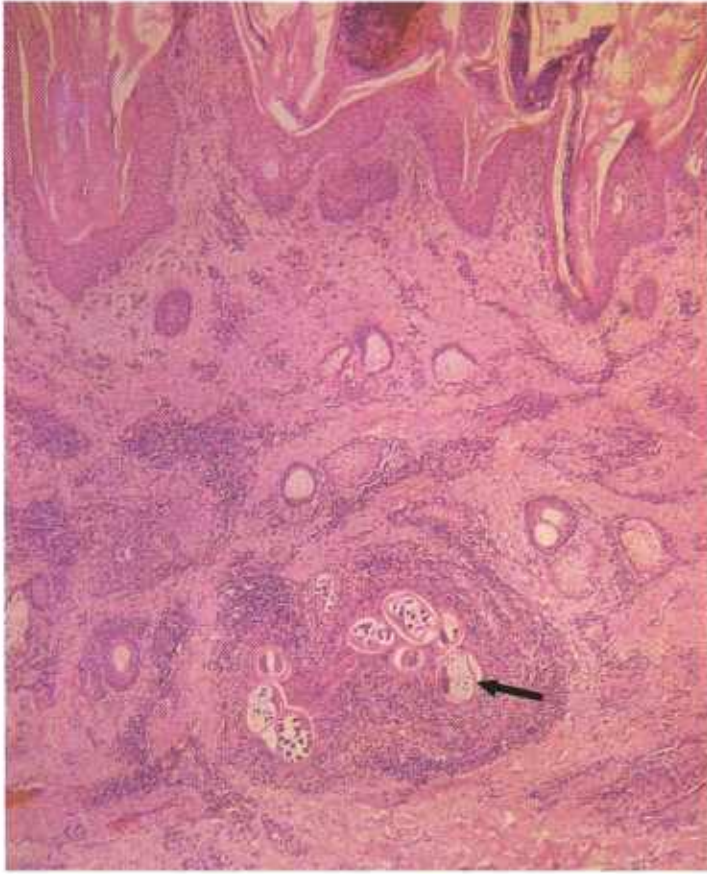


Figure 351.—Histologic preparation of stephanofilariasis of the skin of a 3-year-old steer (D3056). There is a chronic parasitic dermatitis with hyperplasia and hyperkeratosis of the epithelium. Cross sections of the parasite (arrow) can be seen in a focus of leukocytes and hyperplastic connective tissue. Hematoxylin-eosin stain.  $\times 50$ .

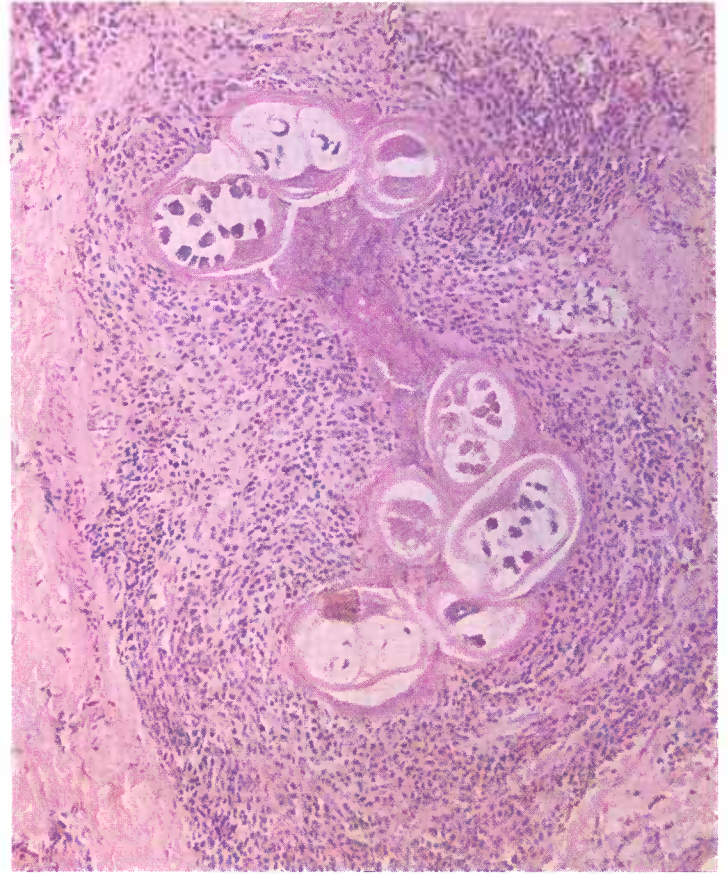


Figure 352.—A higher magnification of the histologic preparation (D3056) shown in figure 351. Cross sections of the parasite can be seen in a focus of leukocytes and hyperplastic connective tissue. Hematoxylin-eosin stain.  $\times 125$ .

## MISCELLANEOUS DISEASES THAT ARE FREQUENTLY SUBMITTED FOR DIAGNOSTIC CLARIFICATION

### Endocarditis

**Definition.**—Endocarditis is an inflammation of the endocardium of the heart.

**Distribution and incidence.**—Endocarditis is one of the more common lesions in domesticated animals throughout the United States. In nearly all instances, it is an indication that a bacterial infection of the endocardium is present. Endocarditis is usually associated with chronic septicemic diseases in which bacteria are constantly or frequently present in the blood stream. *Erysipelothrix rhusiopathiae* is a common cause of endocarditis in swine, and *Corynebacterium pyogenes* and streptococci of endocarditis in cattle and swine. Occasionally, other organisms, such as *Escherichia coli*, are isolated from the cardiac lesions. Except for blackleg—*Clostridium chauvei* infection in cattle and sheep—endocarditis is seldom associated with acute infectious diseases.

**Macroscopic appearance.**—Lesions can be found anywhere in the endocardium but are most frequently ob-

served in the heart valves. The lesion that is usually observed is a pale thrombus covering the area of endocarditis. The actual inflammatory process is not ordinarily visible unless the overlying thrombus is removed or the area is incised. (Such terms as “vegetative” or “cauliflower” are used to describe the physical appearance of the thrombus but do not describe the actual inflammatory process.) Lesions are located in the wall (mural) of the heart or are located in the valves (valvular).

After invasion of the endocardium by bacteria, the alterations first appear as focal yellowish-white roughened areas on the endocardium. They are composed of masses of thrombocytes that have accumulated at the site of endocardial injury. Lesions appear on the surface of the valve struck with the greatest force by the blood current, which is on the atrial side of the atrioventricular valves and the ventricular side of the aortic and pulmonary valves. The lesions are usually located near the

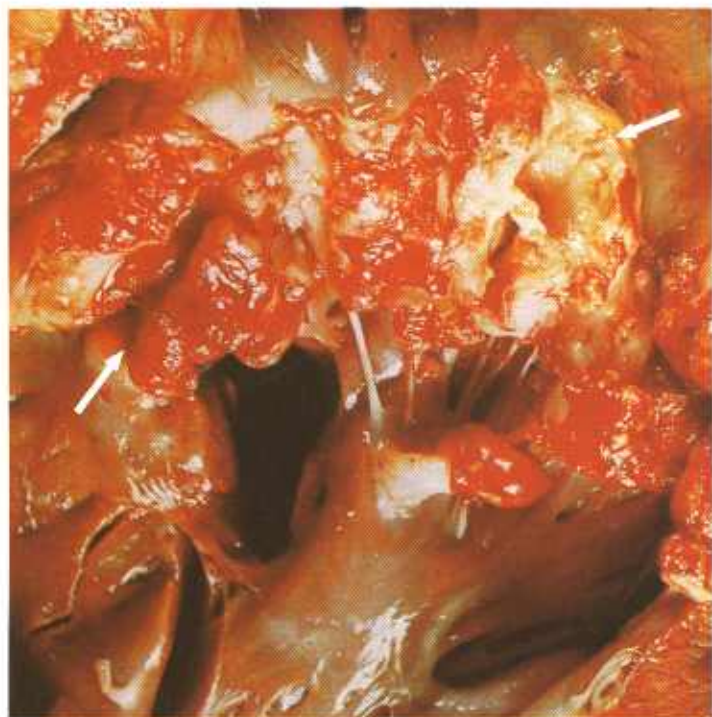

Figure 353.—Chronic vegetative valvular endocarditis (arrows) of the left atrioventricular valve of the heart of an old cow (B185-D3241). *Corynebacterium pyogenes* are present in the lesion.

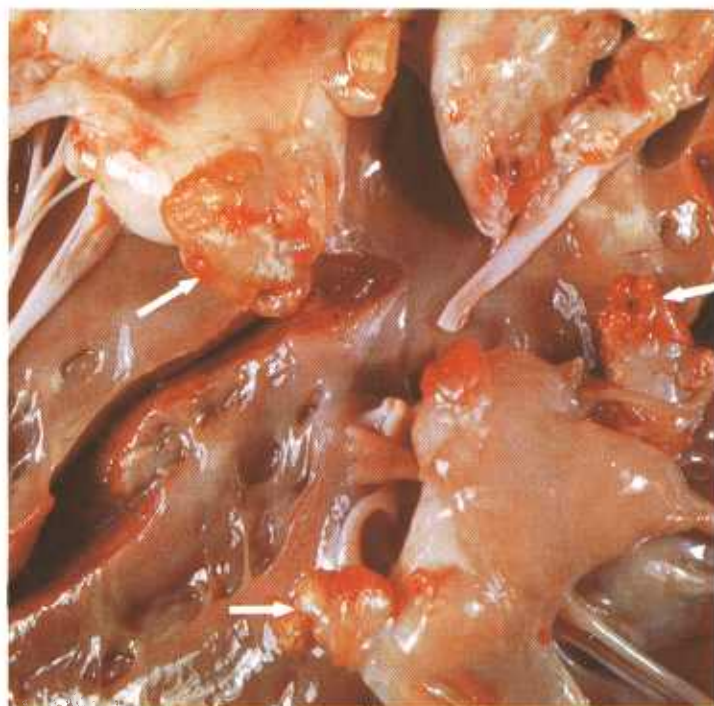

Figure 354.—Chronic vegetative valvular endocarditis (arrows) of the right atrioventricular valve of the heart of an old cow (B70-D1564). *Corynebacterium pyogenes* are present in the lesion.

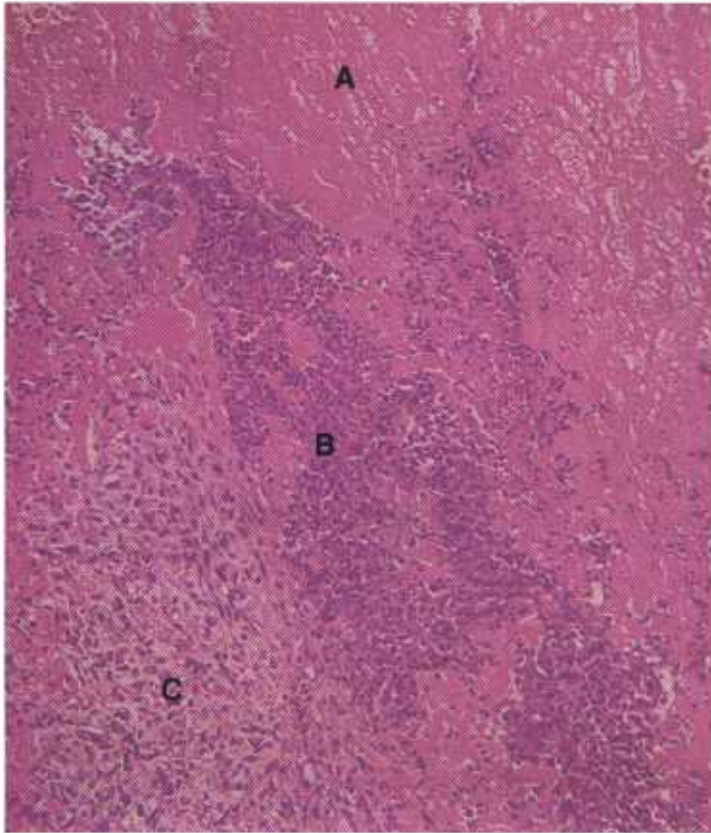


Figure 355.—A histologic preparation of the heart lesion (B185-D3241) shown in figure 353. The lesion is composed of three parts: (A), A superficial layer of platelets and fibrin; (B), a middle layer of leukocytes (principally neutrophils); and (C), a deep layer of chronic inflammatory tissue adjacent to the heart muscle. Hematoxylin-eosin stain.  $\times 125$ .

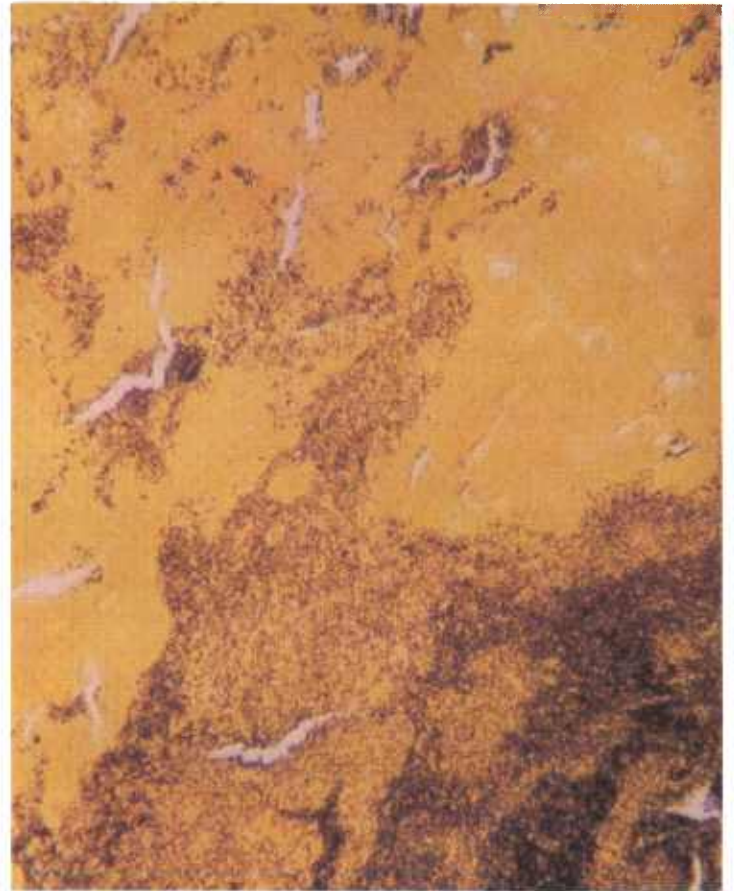

Figure 356.—A histologic preparation of the heart lesion (B185-D3241) shown in figure 353. The bluish-black cocci and short rods are *Corynebacterium pyogenes*. Brown and Brenn Gram's stain.  $\times 500$ .

free edge of the valves where the greatest stress and vibration from the flowing stream of blood is exerted. As the swirling blood within the heart comes in contact with the injured endocardium and the previously attached thrombocytes, additional thrombocytes in the blood stream stick to the injured area. In this manner, the thrombus gradually increases in size. Very little fibrin is present because the current within the heart is too swift for fibrin clotting. The enlarging mass of thrombocytes interferes with the free flow of blood through the heart and with the proper closing of the valves. This retardation of blood flow results in a general passive hyperemia.

The initial reaction in the endocardium after invasion by bacteria is an acute suppurative inflammation. In 48 hours, proliferating capillaries and connective tissue begin to appear in the area of injury. After several days, the newly formed granulation tissue is seen as a pearly-white zone between the myocardium and the thrombus. The presence of this zone indicates the lesion is chronic.

Acute endocarditis associated with blackleg occurs in about one out of four animals that die from this disease. Usually, the lesion involves the wall of the left atria but any part of the heart can be affected. The affected area

of the heart has a rough, cloudy endocardium because thrombocytes are present on the injured surface. Because of the abundance of thrombokinase in the area of inflammation, the intracardial postmortem clot is usually attached to this area. The underlying endocardium and myocardium show an acute fibrino-hemorrhagic type of inflammation and contain a few bubbles of gas. The acuteness of the lesion is indicated by the absence of new connective tissue in the endocardium or the underlying tissue. The typical odor of blackleg is present.

**Microscopic appearance.**—The principal component of the thrombus is the thrombocyte, in which masses of bacteria can be seen. No endothelium is present below the thrombus. A chronic suppurative inflammation is found in the underlying myocardium.

The process of healing (organization of the thrombus) begins in the myocardium and progresses into the thrombus. Healing is not accomplished until the organized thrombus is covered with endothelium. When the scar formed by the healing process contracts, it causes distortion of the heart. Persisting alterations in the heart valves are particularly serious because they can cause valvular insufficiency or stenosis.

## Eosinophilic Myositis

**Definition.**—Eosinophilic myositis is a focal or diffuse inflammation of muscle in which the eosinophil is the principal constituent of the cellular exudate.

**Distribution and incidence.**—Eosinophilic myositis is found throughout the United States but is most frequently observed in beef cattle on western ranges. Animals slaughtered in Denver abattoirs have a very high incidence of the disease. Although all ages of cattle may be affected, 1- to 3-year-old cattle and 6- to 12-month-old hogs are most frequently involved and usually have the most extensive lesions. The disease is occasionally observed in sheep.

The etiology of eosinophilic myositis in meat-producing animals has not been determined. Some of the lesions may be confused with those of sarcosporidiosis, trichinosis, cysticercosis, and the allergic response of tissue to "white muscle" disease. Although sarcosporidia may be present in the muscles of affected animals, it is very uncommon to find the parasites actually associated with the lesions. Further, feeding and transmission studies with sarcosporidia have not succeeded in producing eosinophilic myositis. These observations suggest that the presence of sarcosporidia is incidental and probably has nothing to do with eosinophilic myositis.

Typical lesions may not be detected during routine meat inspection but may be found later when the carcass is cut for retail trade. Although the involvement of smooth muscle has been described, lesions are usu-

ally confined to cardiac and skeletal muscles. It is obvious that massive involvement of the heart and skeletal muscle can produce signs of illness and even death.

Eosinophilic myositis is frequently confused with a myeloid sarcoma, but the tumor has definite characteristics associated with neoplasia rather than inflammation. The similarity of lesions can be confusing until the postmortem examination is completed or even, in some cases, until the characteristics of the lesions are observed histologically. Involvement of bone marrow does not occur in myositis whereas myeloid sarcomas involve bone marrow and other hematopoietic tissues.

**Macroscopic appearance.**—Lesions are acute or chronic and are most frequently observed in the heart, diaphragm, esophagus, tongue, and masseter muscles. Because eosinophils and inflammatory exudate are present in the affected muscles, the areas of inflammation are gray, yellow, or green. Recent lesions are often bright green but the color fades rapidly after exposure to air. The green color can be temporarily restored if hydrogen peroxide is applied to the tissue. Older lesions are greenish gray, gray, or yellow and are fibrotic. A multiple focal distribution of lesions in affected muscles is usually found, but they also occur as long gray or green streaks or as diffuse infiltrations. The green streaks may be several centimeters long but only 2 to 8 mm. wide, with the inflammatory process obviously paralleling small groups of muscle fibers. Single muscles or

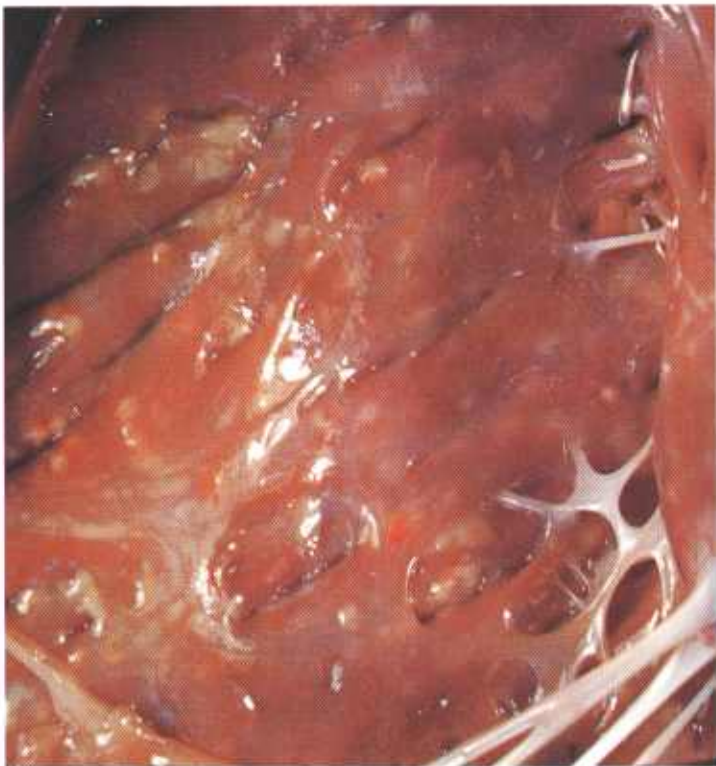

Figure 357.—Eosinophilic myositis of the heart of a steer (D14-128430). Multiple yellowish-green foci measuring 1 to 5 mm. in diameter are present in the myocardium.




Figure 358.—Eosinophilic myositis of the heart of a 4-year-old cow (D24-D1494). Multiple yellowish-green foci measuring 1 to 3 mm. in diameter are present in the myocardium.

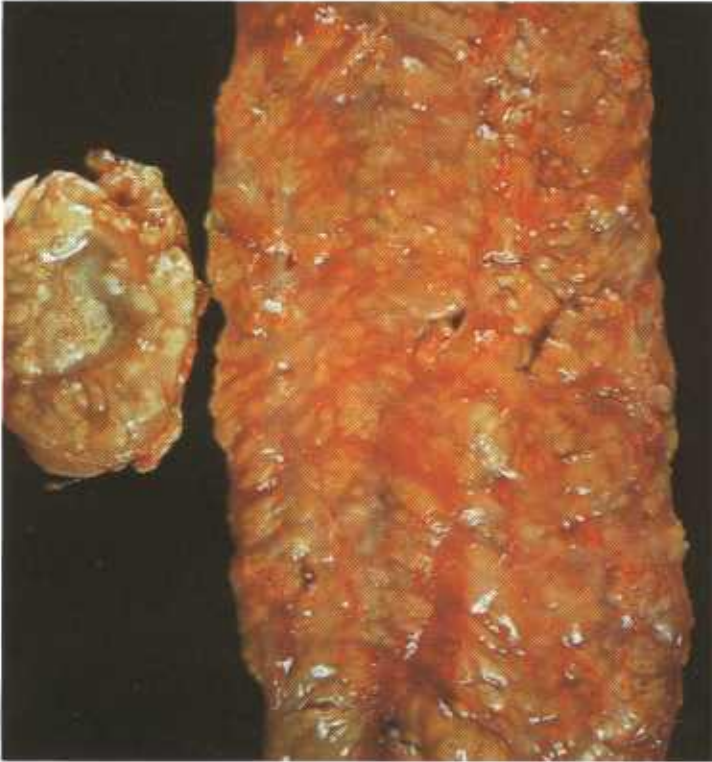

Figure 359.—Eosinophilic myositis of the esophageal musculature of an 18-month-old heifer (D23–D3611). Multiple yellowish-green foci are present in the esophageal musculature.

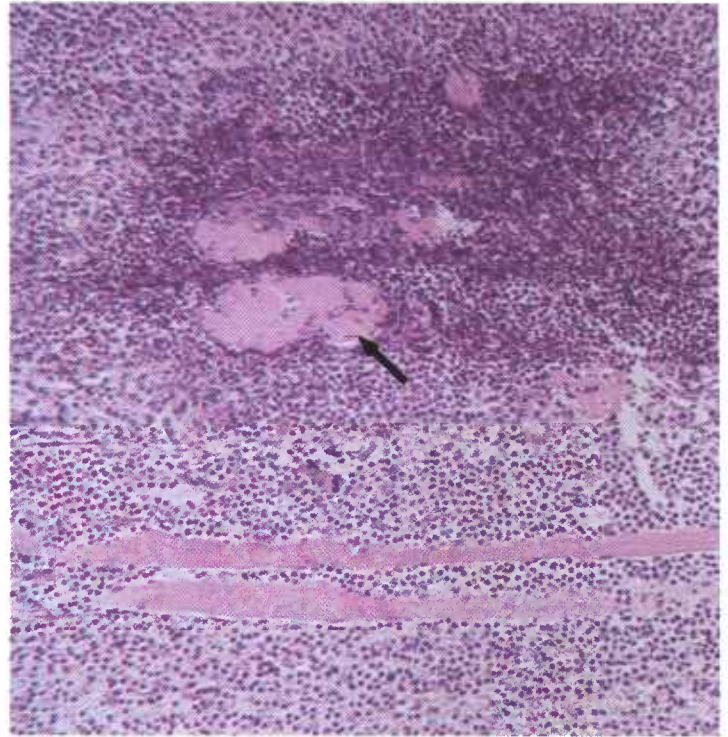


Figure 361.—A histologic preparation of the esophageal musculature (D23–D3611) shown in figure 359. A necrotic muscle (arrow) is enclosed by a mass of eosinophils. Hematoxylin-eosin stain.  $\times 125$ .

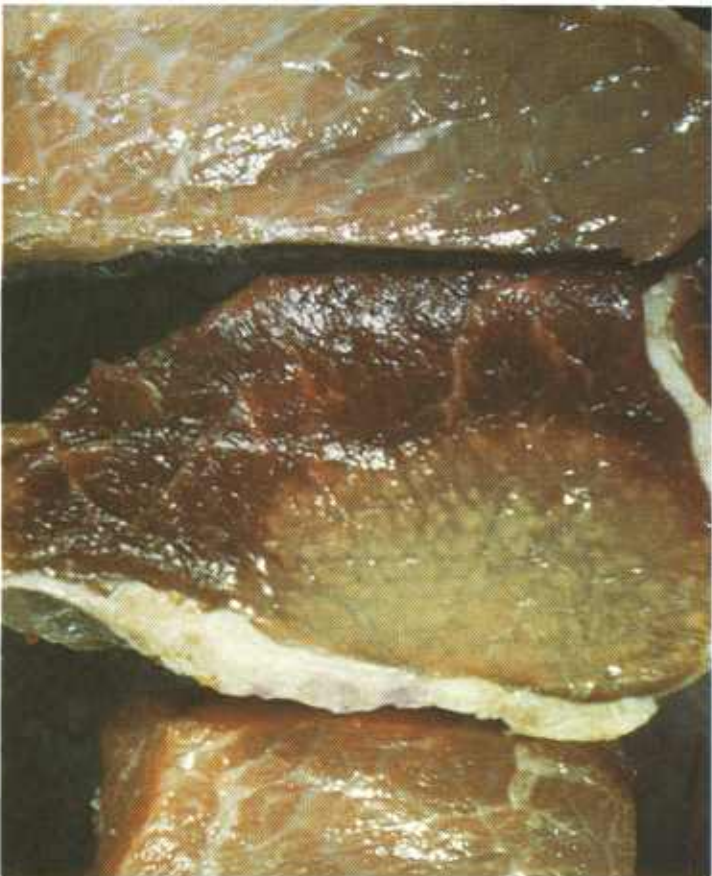

Figure 360.—Eosinophilic myositis of the thigh muscles of a 3-year-old cow (E65–D1615). The lesion is green and contains multiple necrotic foci.

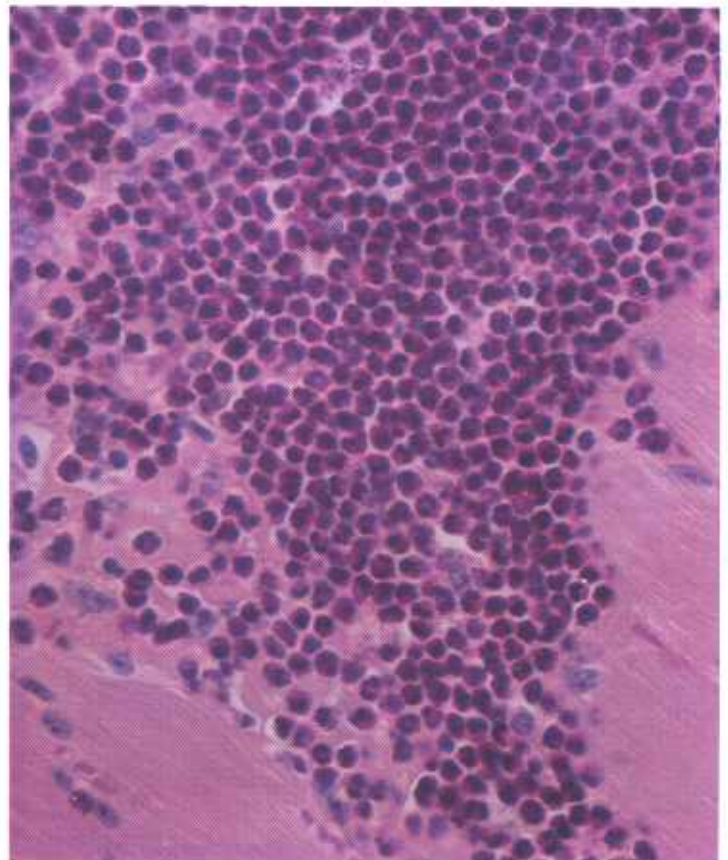


Figure 362.—Eosinophilic myositis of the musculature of a 3-year-old steer (D2588). An abundance of eosinophils are present in the affected muscle. Hematoxylin-eosin stain.  $\times 500$ .

groups of muscles are often affected, especially those of the back and thighs.

**Microscopic appearance.**—Tissue alterations may be acute, subacute, or chronic, and all alterations may be present in the same muscle. The most characteristic lesion of this disease is formed by focal areas of chronic inflammation in the involved muscle. Acute lesions are marked by the predominance of eosinophils in their cellular exudate, by the presence of some amounts of hem-

orrhage and necrosis of muscle, and by the scarcity or lack of collagen deposits. In the chronic form of the disease, necrosis occurs as well as regeneration of muscle cells; macrophages, lymphocytes, and plasma cells predominate in the exudate; and eosinophils are few. Proliferation of fibroblasts, which apparently occurs early, is a prominent feature. Necrotic muscle cells are phagocytosed by macrophages and calcification of the necrotic tissue and exudate may occur.

## Fatty Muscular Dystrophy

**Definition.**—Fatty muscular dystrophy (steatosis) is a condition in which muscle is replaced by an abnormal amount of fat without accompanying inflammatory or degenerative changes.

**Distribution and incidence.**—Fatty muscular dystrophy occurs throughout the United States and is observed primarily in cattle and occasionally in hogs. The disease has been described in sheep but no specimens have been submitted to the Denver laboratory. Although older cattle may be affected, the condition is usually found in cattle that are 1 to 3 years of age.

Fatty muscular dystrophy produces no clinical signs of locomotor disturbance. It has never been determined if the disease is present at birth or if it is acquired during growth. The dystrophy usually involves the heavy muscles of the hind quarter, loin, and shoulder; however, all muscles of the body may be affected, including the heart. Muscle alterations are usually not found at

slaughter but are detected when the carcass is cut for retail trade. Financial losses from this dystrophy are not great, but the displeasure the consumer expresses when he finds the musculature of a steak or roast replaced by fat can be of considerable concern to meat-packers and retail butchers.

Although the condition resembles pseudohypertrophic muscular dystrophy in man, the demonstration of atrophy associated with fatty infiltration has not been described, clinical signs of progressive weakness and incoordination have not been recorded, and familial relationships have not been reported. It has been speculated that faulty innervation and vascular supply account for the lesions, but these speculations are without scientific proof.

**Macroscopic appearance.**—Affected muscles contain an excessive amount of fat. The alteration may occur as a single well-demarcated area of fatty infiltration or

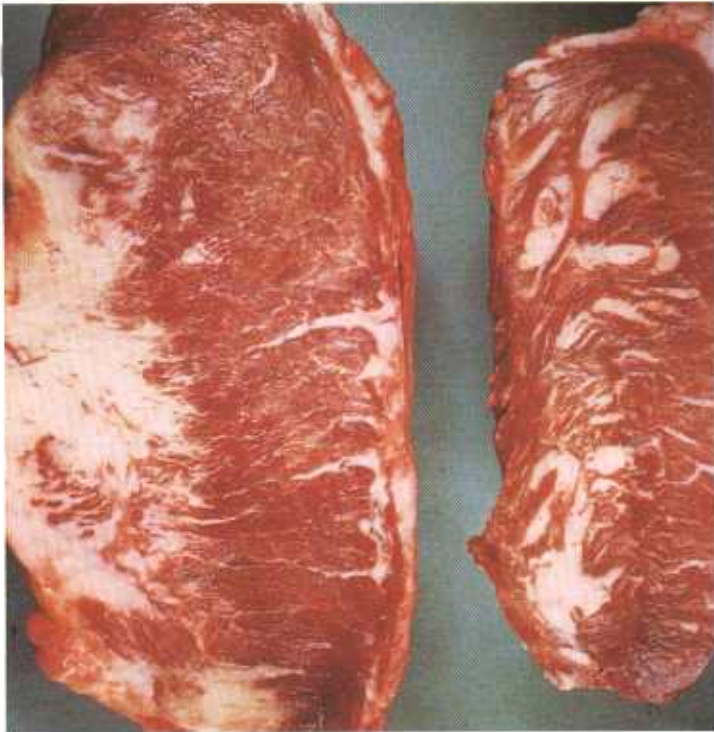


Figure 363.—Fatty muscular dystrophy of the heart of an old Hereford cow (E191-D3191). Large masses of fat are present in the myocardium although fat is not normally found in this locus.



Figure 364.—Fatty muscular dystrophy of the skeletal muscle of a ewe (E182-132378). Extensive infiltration of the musculature with fat has occurred.

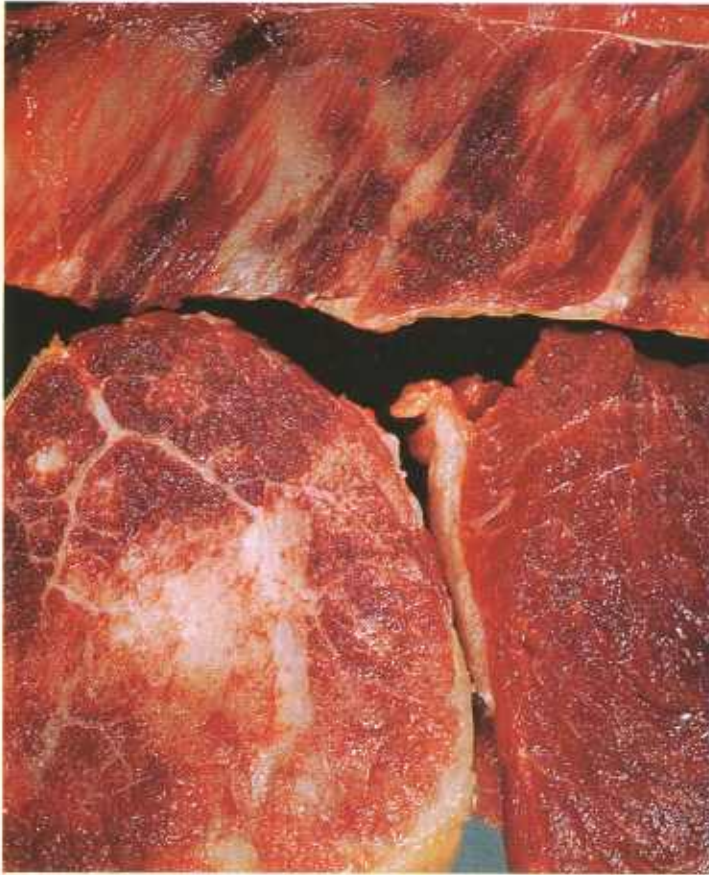


Figure 365.—Fatty muscular dystrophy of the loin, shoulder, and thigh of a 2-year-old Hereford steer (E154-D2664). All of the steer's skeletal musculature was similarly involved.

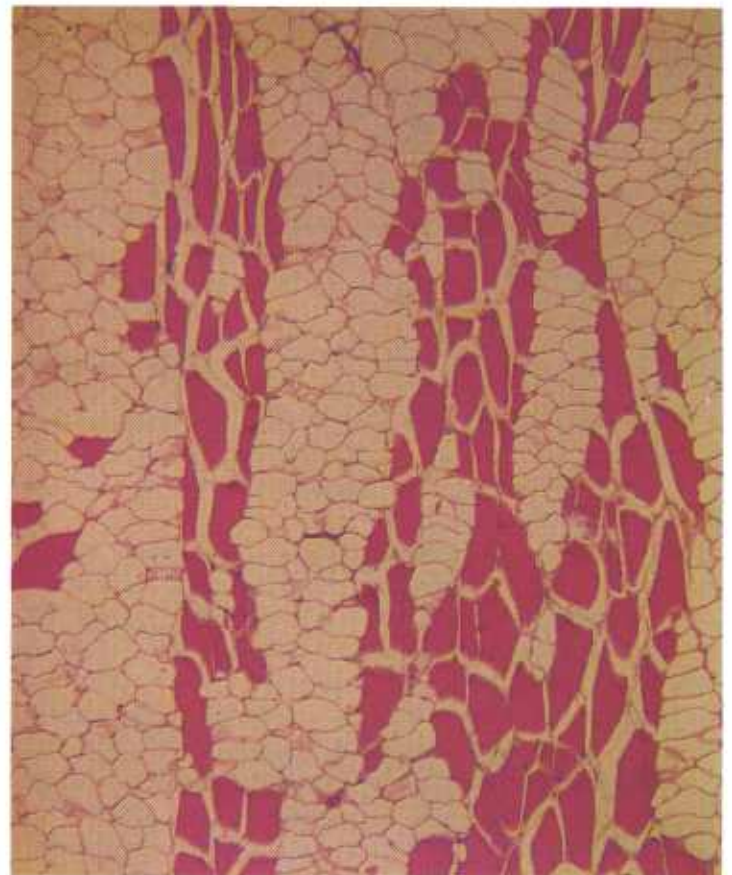


Figure 366.—Fatty muscular dystrophy of the thigh muscles of a steer (D1735). Adipose cells have infiltrated between the muscle cells. Hematoxylin-eosin stain.  $\times 50$ .

as multiple areas of fatty infiltration in one or several muscles, or the infiltration may involve a major portion of a muscle. The most extensive lesions of fatty muscular dystrophy are seen in fat cattle and hogs where the fatty infiltration ("marbling") associated with heavy feeding augments the amount of fat in the muscles of the affected animals.

**Microscopic appearance.**—Histologic alterations consist of an infiltration of the involved muscle with normal-appearing adipose cells. An entire muscle may be replaced with fat, or adipose cells may be interspersed between the remaining muscle cells. Muscles in the area show no signs of degenerative, necrotic, inflammatory, or fibrotic alterations.

## Focal Hepatic Necrosis ("Sawdust Liver"; Telangiectasis)

**Definition.**—Focal hepatic necrosis is a liver dystrophy of cattle and occasionally of swine that is caused by a deficiency of selenium, vitamin E, and probably other tissue antioxidants. The disease begins as hepatic necrosis ("sawdust") and progresses to focal vascular dilatations (telangiectasis).

**Distribution and incidence.**—This liver dystrophy is found throughout the United States but appears to be most prevalent in those areas where there is a deficiency of selenium in the soil and a high incidence of "white muscle" disease. Since cattle and swine on full feed are often fed a ration deficient in selenium and vitamin E, a high incidence of the disease occurs in feedlot animals. The disease is especially prevalent in "prime" and "choice" cattle. As many as 40 percent of the cattle in

certain feedlots are affected. Lesions are most frequently observed in 1- to 2-year-old cattle and 5- to 6-month-old swine (maximum slaughter ages), although younger and older animals are affected. No breed or sex predominance has been demonstrated.

"Sawdust" lesions are most commonly observed in calves, yearlings, and 2-year-old cattle. Although telangiectasis is seen in all ages, lesions are largest and most numerous in old cattle.

**Macroscopic appearance.**—Lesions are first observed as irregular yellow, tan, or gray multiple necrotic foci that measure 1 to 5 mm. in diameter. Because these lesions look like liver surfaces contaminated by sawdust, early stages of this hepatic dystrophy have been called "sawdust liver."

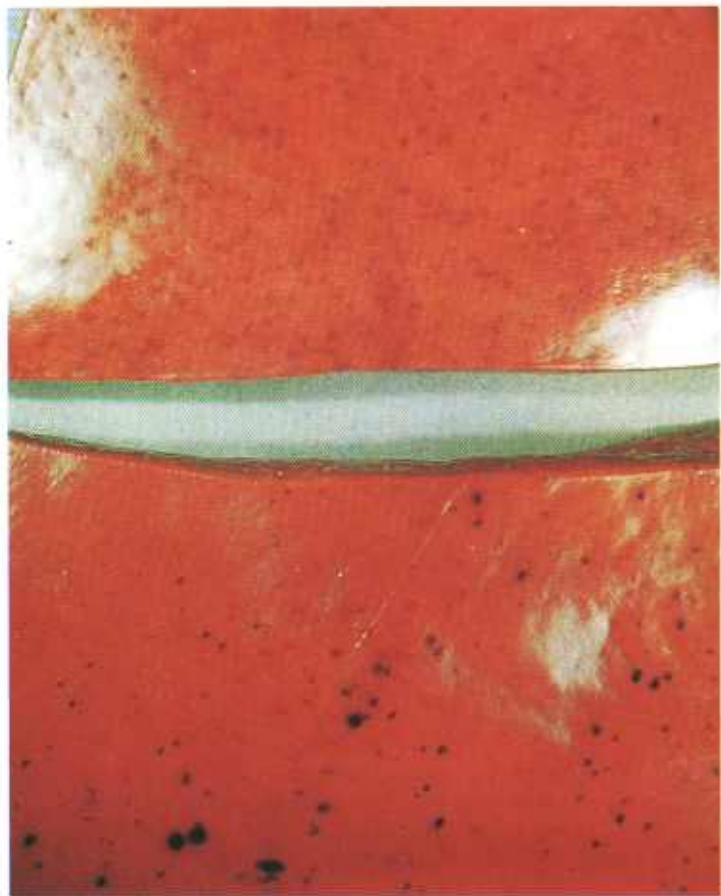


Figure 367.—Telangiectasis of the liver of a 2-year-old steer (E7-D1292). The multiple black and red foci are dilated hepatic sinusoids distended with blood.

As necrotic tissue is removed during the process of repair, space occupied by necrotic cells is filled with distended sinusoids that contain blood. This dilatation of hepatic sinusoids is known as telangiectasis. The size of the telangiectatic areas varies from small, scarcely visible red foci to large blue or purple cavernous spaces measuring 1 to 2 cm. in diameter. Larger sinusoids below the capsule are slightly sunken after death when blood pressure no longer distends the vascular spaces. Incision of a telangiectatic lesion reveals a network of anastomosing sinuses filled with blood that are sharply demarcated from surrounding hepatic parenchyma but that are not enclosed by a zone of inflammation or a connective tissue capsule.

“Sawdust” and telangiectasis are frequently present in the same liver. Intermediate stages—from early hepatic cell necrosis to distended sinusoids filled with blood—can be found in adjacent areas of the parenchyma.

**Microscopic appearance.**—The first and basic hepatic alteration is the focal coagulative necrosis of hepatic cells that begins in the periportal region of the lobule and that may eventually involve parts of one or several lobules or an entire lobule. Affected cells are swollen and foamy, and they contain vacuoles and numerous hyaline granules and globular masses. The hyaline globules are

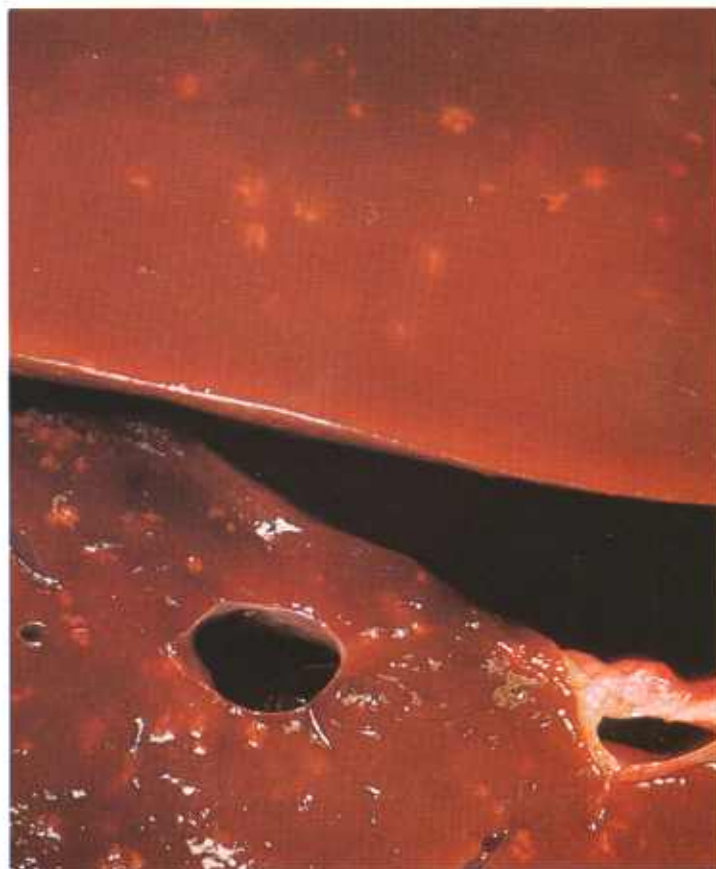

Figure 368.—Focal hepatic necrosis (“sawdust”) in the liver of a bovine animal (E167-132045). Multiple yellow, irregularly shaped foci of necrosis and cell infiltration measuring 1 to 4 mm. in diameter are present in the parenchyma of the liver.

swollen mitochondria. These cell structures are very sensitive to anoxia and rely on vitamin E, selenium, and perhaps other antioxidants to maintain their integrity. Nuclei show necrobiotic alterations (pyknosis, karyolysis, etc.) and cell cytoplasm has a heightened affinity for eosin. Local inflammatory response is minimal and is characteristic of coagulative necrosis. It consists of hyperemia and a slight infiltration of lymphocytes, neutrophils, eosinophils, and macrophages. Selenium deficiency apparently suppresses the regenerative ability of hepatic cells in the vicinity of the area of necrosis. Although some hepatic cells regenerate, regeneration is not sufficient to completely reproduce the hepatic cords and fill the tissue gap caused by the loss of hepatic cells.

Vascular sinusoids between hepatic-cell cords persist in areas of necrosis. As hepatic cells undergo lysis and phagocytosis, the space occupied by these cells is filled by a dilatation of adjacent sinusoids. As more and more hepatic cells disappear, distending sinusoids become larger and unite with adjacent sinusoids to form larger vascular structures. Sinusoidal expansion continues until pressure from the surrounding hepatic parenchyma equals sinusoidal blood pressure and prevents further dilatation.

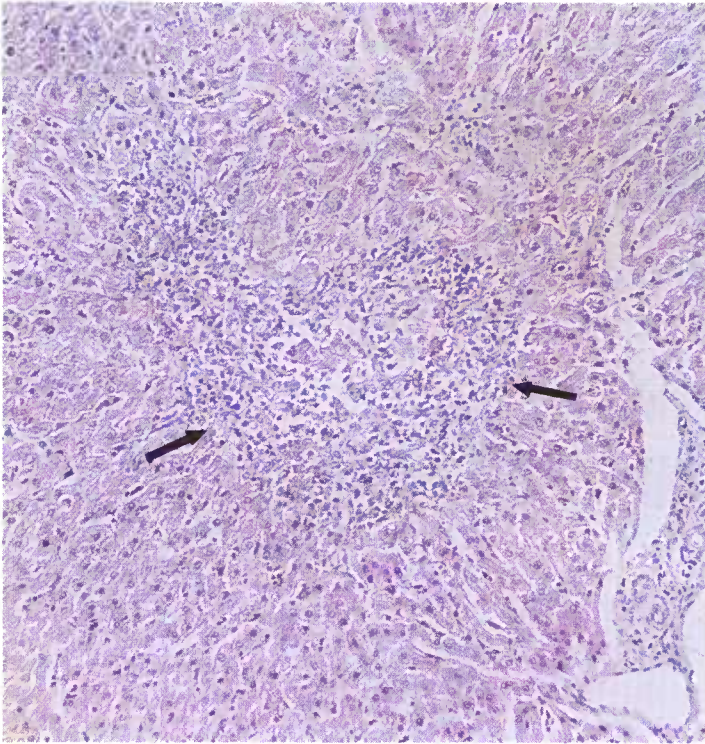


Figure 369.—Focal hepatic necrosis (“sawdust”) in the liver of a 2-year-old steer (E7-D1292). A focus (arrows) of necrotic hepatic cells and leukocytic infiltration is present. Hematoxylin-eosin stain,  $\times 125$ .

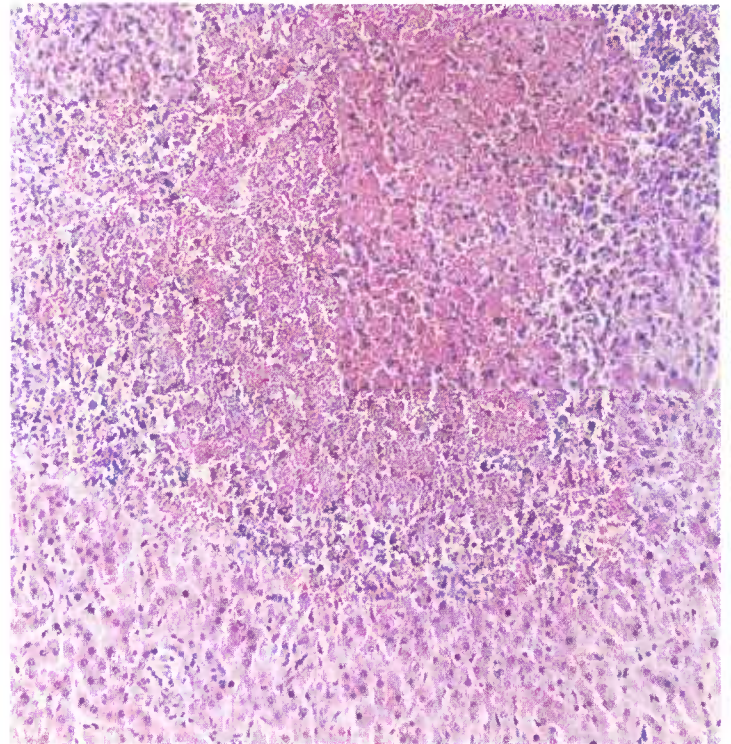


Figure 371.—Focal hepatic necrosis and telangiectasis in the liver (E7-D1292) shown in figure 367. Many sinusoids in this area of hepatic cell necrosis and leukocytic infiltration are distended with blood. Hematoxylin-eosin stain,  $\times 125$ .

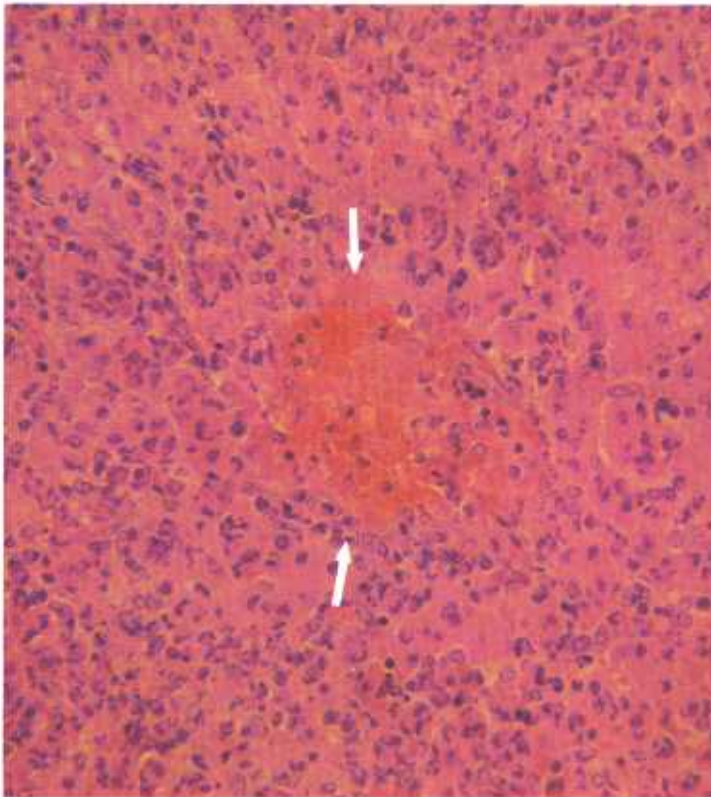


Figure 370.—A histologic preparation of the affected liver (E167-132045) shown in figure 368. Blood is beginning to distend the sinusoids (arrows) in the center of a focus of hepatic cell necrosis and leukocytic infiltration. Hematoxylin-eosin stain,  $\times 320$ .

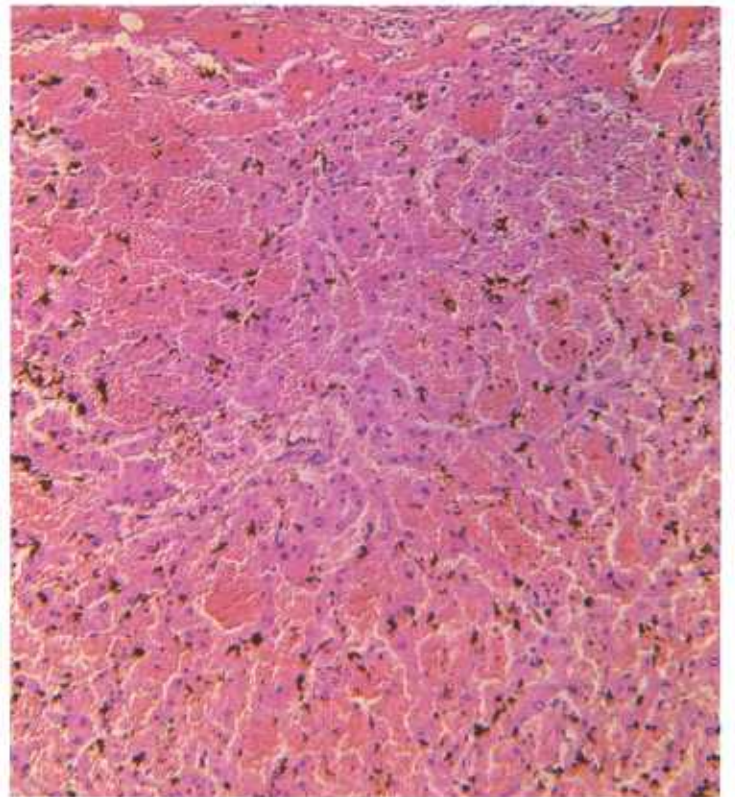


Figure 372.—Telangiectasis in the liver (E7-D1292) shown in figure 367. The sinusoids are distended with blood. Necrotic hepatic cells and leukocytes are no longer present. The dark-brown granules are formol-precipitated hemoglobin. Hematoxylin-eosin stain,  $\times 125$ .

## Hemosiderosis

**Definition.**—Hemosiderosis is the excessive accumulation of hemosiderin in the body tissues of animals having an oxygen-hemoglobin transport system.

**Distribution and incidence.**—Since hemosiderin formation and the metabolism of iron are common to all mammals, hemosiderosis is observed in all species of meat-producing animals throughout the United States. This pigment is seen mainly in organs possessing components of the reticuloendothelial system, such as the spleen, lymph nodes, liver, and bone marrow. Large amounts of hemosiderin are found in animals that have absorbed excessive quantities of iron from feed or that have had various iron-compound injections for the prevention of anemia. Hemosiderosis occurs in animals affected with anaplasmosis, leptospirosis, chronic copper poisoning, and infectious equine anemia where there has been excessive destruction of erythrocytes. The disease is commonly observed in areas of old hemorrhage or in organs where chronic hyperemia has been present.

**Macroscopic appearance.**—Hemosiderin is a brown pigment and if present in sufficient amounts, will impart a brown color to tissues or organs. When specimens of the pigmented tissues are placed in a solution of potassium ferrocyanide and hydrochloric acid (Prussian blue test), they will turn blue if hemosiderin is present.

Although hemosiderin is normally not injurious to cells, the fact that it is phagocytosed by macrophages indicates that it is an irritating substance and that the reticuloendothelial system treats it as a foreign material. If excessive amounts become concentrated in an area, a chronic focal inflammatory reaction occurs that results in the deposition of connective tissue and calcium in the

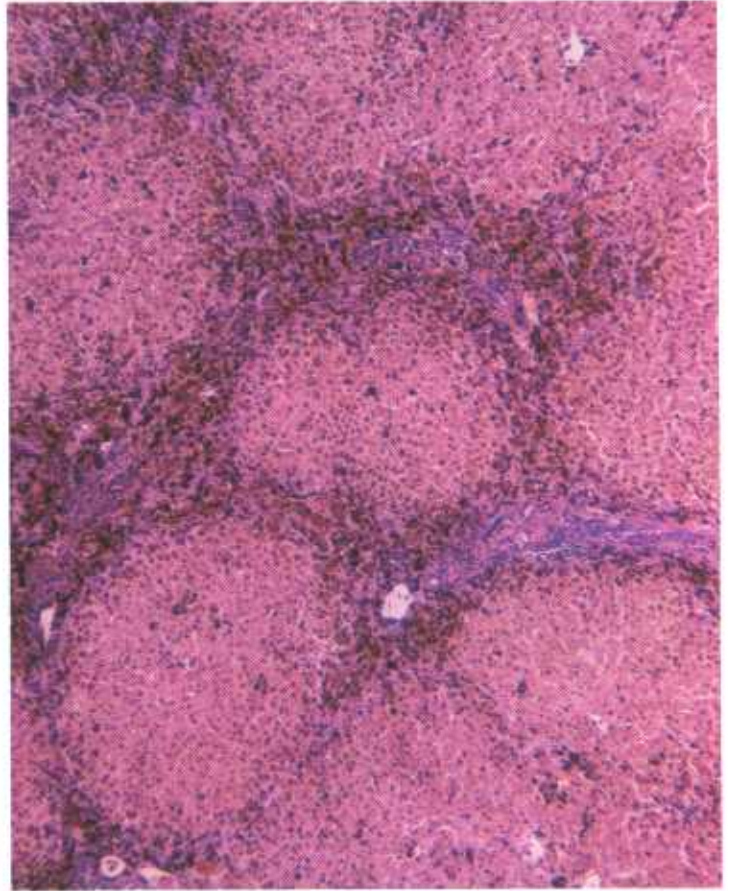


Figure 374.—A histologic preparation of the liver (E28-D1387) shown in figure 373. An abundance of brown pigment is present in the interstitial tissue and a lesser amount is present within the lobules. Hematoxylin-eosin stain.  $\times 50$ .



Figure 373.—Hemosiderosis of the intestine (I), liver (L), kidney (K), and lymph node (LN) of a 6-year-old Jersey cow (E28-D1387). The organs are brown because hemosiderin is present.

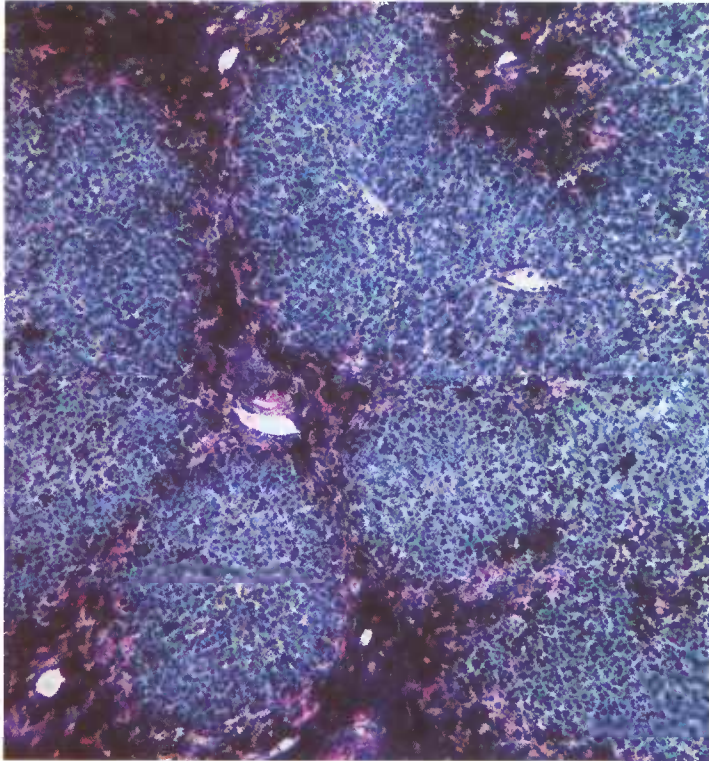


Figure 375.—A histologic preparation of the liver (E28-D1387) shown in figures 373 and 374. Hemosiderin is staining blue. Pearl's stain.  $\times 50$ .

affected area. Cells of the reticuloendothelial system may become so engorged with hemosiderin that they can no longer function effectively as part of the body's defense system and the animal may then succumb to various infectious diseases. A similar blocking of the reticuloendothelial system occurs when excessive amounts of injectable iron are administered. Massive accumulations of hemosiderin may cause necrosis of reticuloendothelial cells.

**Microscopic appearance.**—Hemosiderin pigments are

## Hyperkeratosis of Cattle

**Definition.**—Hyperkeratosis of cattle is caused by highly chlorinated naphthalenes and is characterized by hyperplasia of squamous and columnar epithelium.

**Distribution and incidence.**—The disease has been observed throughout the United States. It occurs chiefly in young animals 6 to 9 months old. A few years ago it was a very common disease, but at the present time it is infrequently seen because industry has discontinued the use of certain chlorinated naphthalenes.

Hyperkeratosis occurs when cattle consume or are exposed to feeds, machine lubricants, fly sprays, tar papers, and wood preservatives that contain or are contaminated by highly chlorinated naphthalenes. Cattle coming in contact with farm machinery greased with lubricants containing these naphthalenes develop the disease. Feed mixed or prepared in machines contaminated by such lubricants will retain enough chlorinated

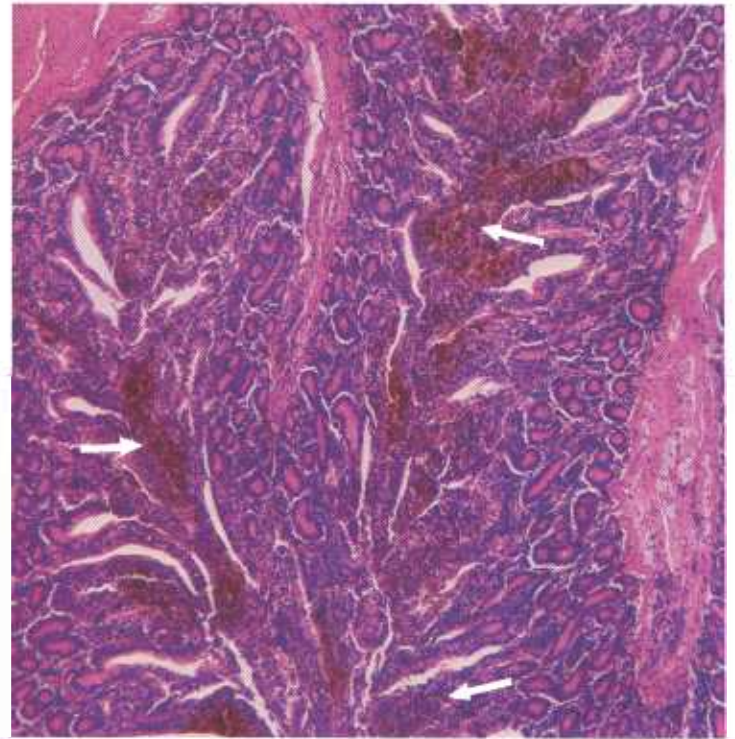


Figure 376.—A histologic preparation of the intestine (E28-D1387) shown in figure 373. Hemosiderin is present as brown granules (arrows) in the tunica propria of the intestinal mucosa. Hematoxylin-eosin stain.  $\times 50$ .

small yellowish-brown granules, irregular in size and shape. These granules are usually found within the cytoplasm of macrophages and, because of this containment, are clumped together in globular masses.

Hemosiderin is insoluble in tissue fluids as well as in aqueous and alcoholic solutions and thus can be seen in histologic preparations. The granules become blue when histologic preparations are placed in a mixture of potassium ferrocyanide and hydrochloric acid, an indication they contain iron.

naphthalene to produce hyperkeratosis. Chlorinated naphthalene is eliminated in cow's milk: nursing calves ingest the toxic substance with the milk and develop hyperplastic lesions. It is also absorbed through the skin when insecticides containing naphthalenes are applied to cattle for control of ectoparasites.

**Macroscopic appearance.**—The principal external manifestation of the disease is excessive hyperkeratosis of the skin. Alterations in the skin start on the sides of the withers, neck, and cheeks and finally involve the skin of the entire upper two-thirds of the body. The skin becomes dry, scaly, and leathery and is arranged in deep folds and creases. Hair in the affected areas gradually disappears. Affected animals are depressed and emaciated, and eventually die after a prolonged illness. Cows in the terminal stages of pregnancy are frequently

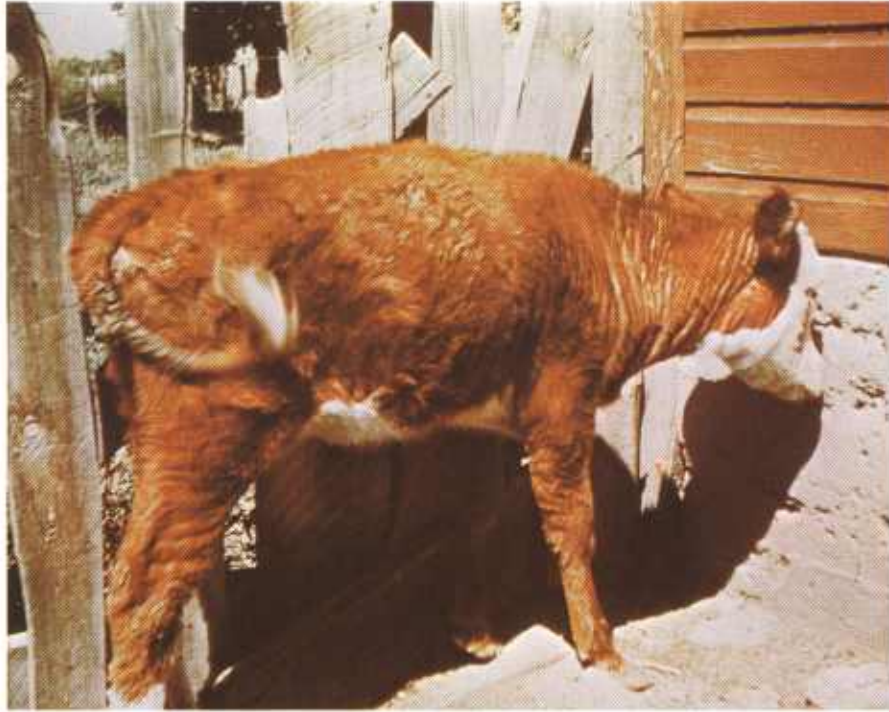


Figure 377.—Hyperkeratosis of a 3-month-old female Hereford calf (E220-127509). The calf is affected with a mucopurulent conjunctivitis and hyperkeratosis and wrinkling of the skin of the neck. The hair of its coat is rough and its tail and perineal region are matted with feces.

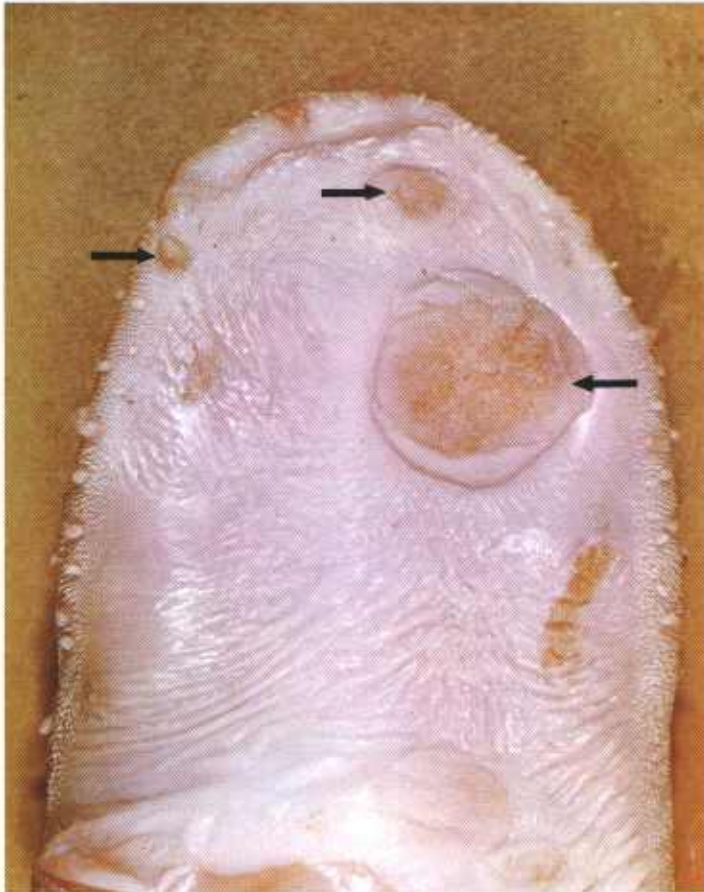


Figure 378.—Hyperkeratosis of the tongue of a 3-month-old calf (127680). Raised plaques (arrows) with rough surfaces are present on the glossal mucosa.

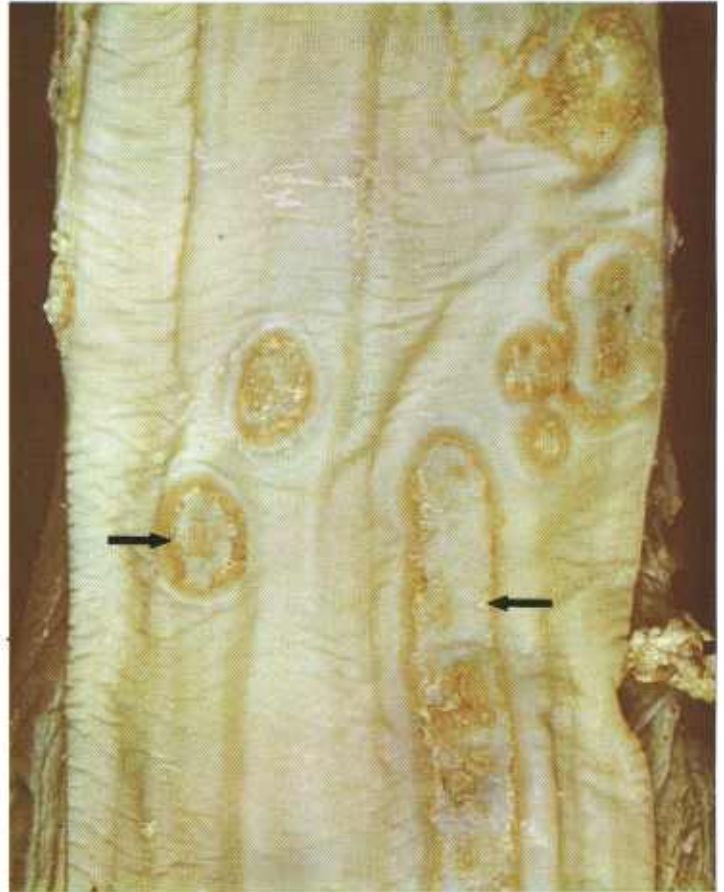


Figure 379.—Hyperkeratosis of the esophagus of a bovine animal (129117). Raised plaques (arrows) with rough surfaces are present in the mucosa of the esophagus.

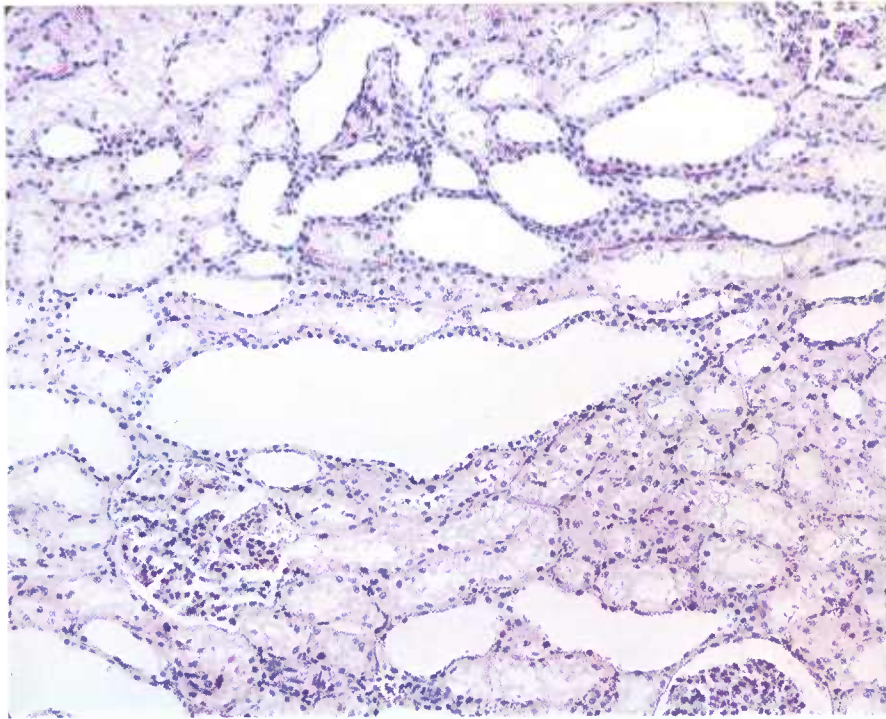


Figure 380.—A histologic preparation of the kidney of a 5-year-old Hereford cow affected with hyperkeratosis (129834). The renal tubules are dilated. Hematoxylin-eosin stain.  $\times 50$ .

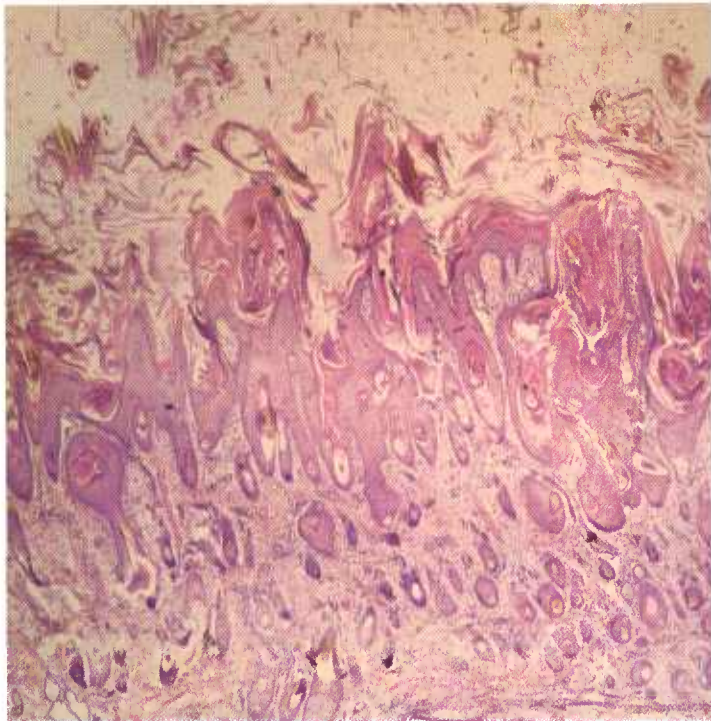


Figure 381.—A histologic preparation of the skin of the affected calf (E220-127509) shown in figure 377. There is a hyperkeratosis of the epidermis with the accumulation of keratotic epithelium on the skin surface. Hematoxylin-eosin stain.  $\times 20$ .

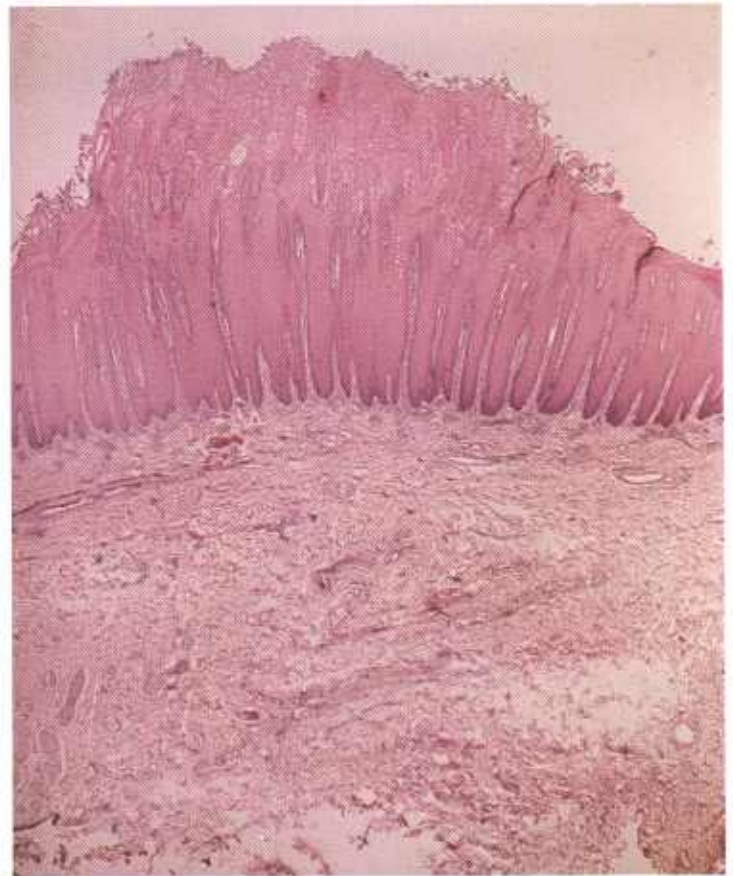

Figure 382.—A histologic preparation of the gum of the affected calf (E220-127509) shown in figure 377. Hyperplasia of the epithelium has resulted in the formation of a raised hyperkeratotic mass on the gum surface. Hematoxylin-eosin stain.  $\times 20$ .

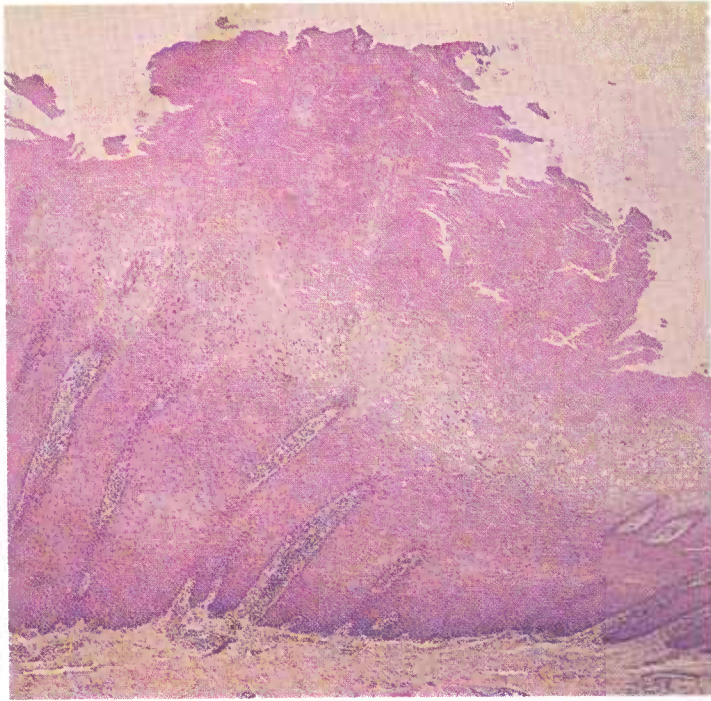


Figure 383.—A histologic preparation of the tongue of a calf (128334) affected with hyperkeratosis. The glossal epithelium shows hyperplasia and hyperkeratosis. Hematoxylin-eosin stain.  $\times 50$ .

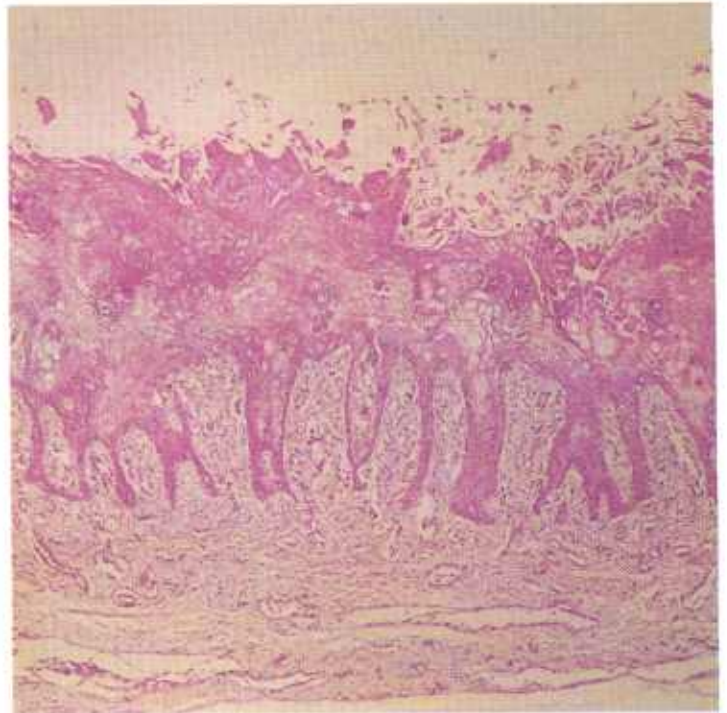


Figure 384.—A histologic preparation of the esophagus (129117) shown in figure 379. The esophageal epithelium shows hyperplasia and hyperkeratosis. Hematoxylin-eosin stain.  $\times 50$ .

affected with mastitis and acetonemia and the gestation periods of these animals is often prolonged.

Epithelium of the mouth, tongue, and esophagus contains raised, rounded, papillary proliferations. These areas of hyperplasia measure as much as 2 cm. in diameter and may be as much as a centimeter high. *Spherophorus necrophorus* invasion of the oral lesions is a common complication.

Focal and diffuse hyperplasia occurs in the epithelium of the bile ducts and gallbladder. The hyperplastic bile ducts appear as yellowish-white branching streaks throughout the parenchyma of the fibrotic liver. Retention cysts are frequently present in the mucous membrane of the gallbladder and larger bile ducts. The pancreas is fibrotic and the epithelium of the pancreatic ducts is hyperplastic.

## Intestinal Emphysema in Swine

**Definition.**—Intestinal emphysema is a disease of swine in which bubbles of gas appear in the wall of the intestinal tract and in the regional lymph nodes.

**Distribution and incidence.**—Intestinal emphysema occurs throughout the United States but is most frequently observed in areas having a concentrated swine industry. Clinically, the pigs appear to be normal. The disease is not as common today as it was up to about 1940. This decrease in incidence is probably the result of improvement in the nutritive content of porcine feed. A similar disease has been reproduced in swine fed a ration deficient in vitamin B and other essential substances, but

Occasionally the kidneys are large and pale red. The exposed surface of an incised kidney reveals yellowish-white radial streaking in the cortex and medulla. This radial streaking is due to cystic dilatation of the collecting tubules. Fibrosis of the interstitial tissue is frequently associated with this dilatation.

**Microscopic appearance.**—The basic alterations are focal and diffuse hyperplasias of squamous and columnar epithelium throughout the body. A thick layer of keratinized epithelium covers the surface of the skin and hair follicles are often keratinized. Very little secondary bacterial infection is present.

Hyperplasia of columnar epithelium causes obstruction of the lumens of ducts and glands. The result is an accumulation of secretions and excretions and the formation of cysts in the organs.

the exact cause of intestinal emphysema has never been completely identified.

**Macroscopic appearance.**—The location and distribution of the emphysematous lesions indicate that the gas associated with the disease is absorbed from the intestinal contents of the swine. Multiple bubbles of gas in the mucosa and the submucosa range in size from some that are just visible to others that measure several millimeters in diameter and project into the lumen of the intestine. Crepitation is detected when the surface of the mucous membrane is palpated.

The largest bubbles of gas are found in the serosa of

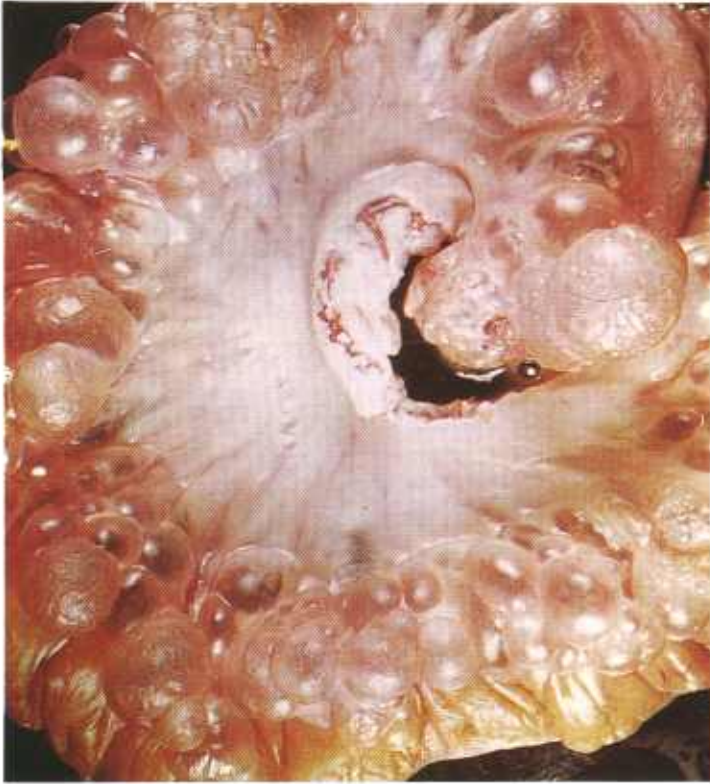

Figure 385.—Emphysema involving the small intestine of a hog (132837). Numerous gas bubbles measuring 1 mm. to 2 cm. in diameter are present in the subserosal tissues of the intestine.

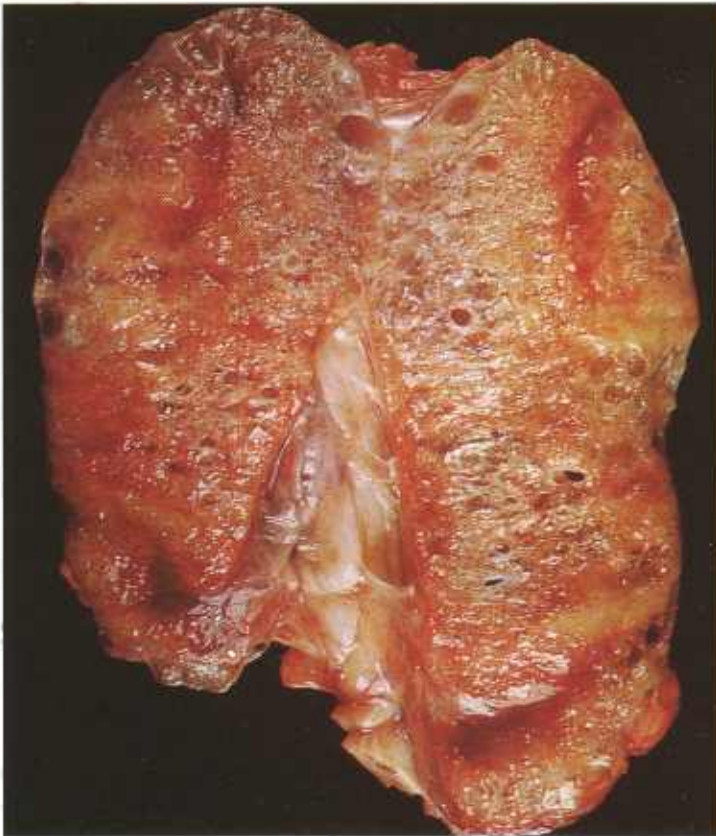


Figure 386.—Emphysema of a mesenteric lymph node receiving afferent lymph vessels from the emphysematous small intestine (132837) shown in Fig. 385. Numerous gas bubbles are visible in the node.

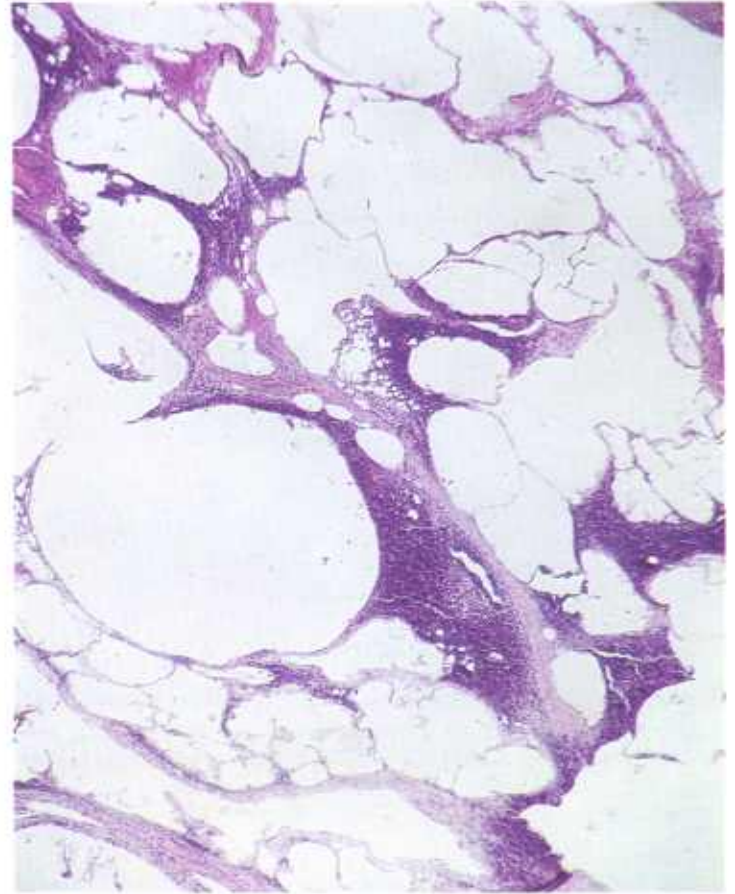


Figure 387.—A histologic preparation of the mesenteric lymph node (132837) shown in figure 385. Bubbles of gas are distending the sinuses of the node. Hematoxylin-eosin stain.  $\times 125$ .

the intestine and in the mesentery. They are most numerous in the region of the jejunum and ileum, and are especially abundant at the junction of the mesentery and the intestine. The gas-filled vesicles may occur as solitary or multiple structures, or they may be conglomerate masses that are sometimes pedunculated. Their presence and distribution in the wall of the intestine, mesentery, and regional lymph nodes indicate that the gas is present within the lymphatic system and is moving along the lymphatics. The beaded appearance of the lymphatics is associated with the valvular structure of these vessels. These bubbles of gas should not be confused with those that form in the wall of the intestine in connection with putrefaction.

The regional lymph nodes contain varying amounts of gas. In some nodes, only a few isolated vesicles are present but other nodes are so infiltrated with gas that they look like very porous sponges.

New gas bubbles are contained within a clear translucent wall. Later, the entire wall, or parts of the wall, become opaque and pink because of an inflammatory reaction produced by tissue tension as the result of distention and by irritation from the action of the intestinal gases.

**Microscopic appearance.**—The gas is usually located within lymph ducts, lymphatics, and sinuses of lymph

nodes and escapes into surrounding tissues if one of these structures ruptures. When the bubble of gas first appears, its wall is lined by the endothelial cells of the lymphoid structure that harbors it. When the inflammatory response ensues, the tissue surrounding the vesicle wall is infiltrated by macrophages (partially de-

rived from the endothelial cells of the lymphatics), lymphocytes, and numerous eosinophils. Some of the macrophages form giant cells that enclose bubbles of the gas. The inflammatory reaction is most severe in those areas where rupture of lymphatic structures has occurred and gas has escaped into the surrounding tissue.

## Melanosis

**Definition.**—Melanosis is the abnormal deposition of a brownish-black pigment, melanin, in tissues and organs.

**Distribution and Incidence.**—Melanosis is found in all meat-producing animals throughout the United States. It is most commonly observed in young animals and especially in those with heavily pigmented skins. This pigment is normally found in the skin, hair, retina, choroid, and iris; it imparts color to animals and serves as protection against the rays of the sun. When the skin or other areas of the body that contain melanoblasts are stimulated by the sun's rays, the melanin in the stimulated areas increases.

Abnormalities in fetal development cause foci of melanoblasts to become located in various internal organs. As a result, focal areas of pigmentation are sometimes found at birth in the intestine, heart, lung, kidney, and other organs. The condition is known as melanosis maculosa. These foci are especially common in calves. By the time affected animals have reached their first year, the pigment has usually disappeared.

Areas of abnormal pigmentation that ordinarily do not disappear with maturity are found in the aorta and the meninges of cattle and sheep (especially Angus and Jersey cattle and blackfaced sheep). Abnormal pigmentation is also found in the horns, hoofs, and claws of many animals, in the zona reticularis of the adrenal gland, and in the skin of red hogs. It is sometimes found in the mammary glands and surrounding fat of black and red gilts and sows. Incorporation of melanoblasts into the mammary gland and surrounding fat occurs during fetal development. The localized area of epidermis that proliferates and then invaginates into the corium to form the ducts of the mammary gland may carry some melanoblasts with it. These melanoblasts can produce a considerable quantity of melanin in the subcutaneous fat. Abnormally pigmented mammary gland fat can be a problem in lard production because a small amount of color makes the lard gray.

Lymph nodes are frequently pigmented when they receive lymph from areas of melanosis or from black skin affected with dermatitis. In cattle and sheep, the pigment is found in the subcapsular portion of the node and in swine, it has a medullary location.

Melanin is a protein produced from tyrosine by melanoblasts located mainly in the basal layers of the skin. Melanoblasts and macrophages that store melanin after it is formed are known as chromatophores, or more specifically as melanophores. Melanin is very similar to

adrenalin in chemical composition and has similar physiologic effects. Melanin is not harmful and can be consumed without causing injury. However, affected meat, because of its unsightly appearance, is not suitable for human consumption.

**Macroscopic appearance.**—Melanin imparts a black, brown, or red color to tissues, according to the amount of pigment present and its distribution in the affected tissue. Since the basic pigment granule is brown, small amounts of pigment (especially if the granules are scattered) impart a reddish color to tissue, greater concentrations produce a brown color, and heavy accumulations (because of the obstruction to the passage of ingoing and reflected light) have a black appearance.

**Microscopic appearance.**—Melanin can be recognized microscopically if thin histologic preparations are examined with a bright light. Individual melanin granules are very small brown bodies, uniform in size and spher-

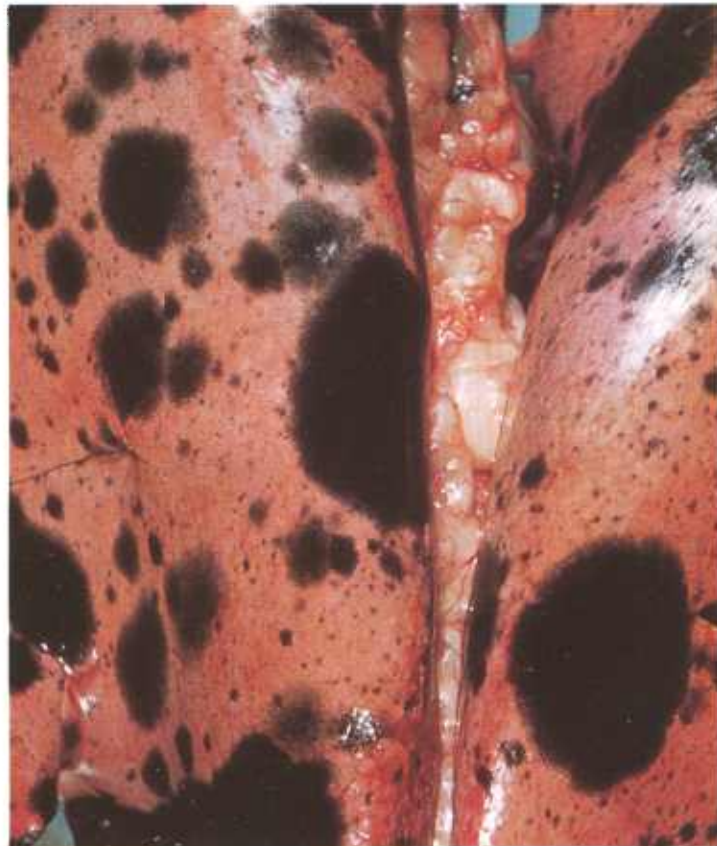


Figure 388.—Melanosis of the lung of a 1-year-old sheep (E197-D2697). Multiple black foci of melanin are scattered throughout the lung.

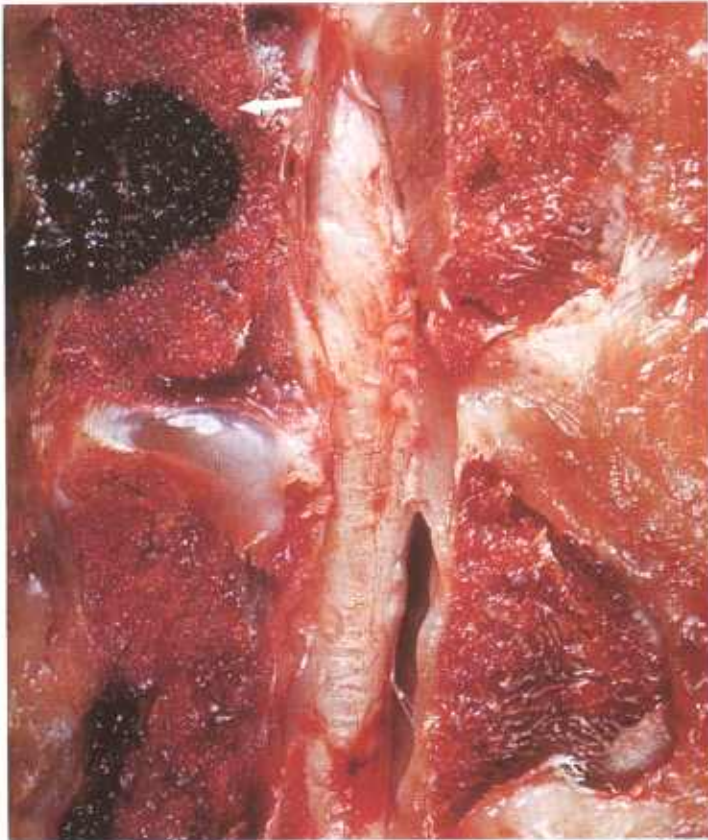


Figure 389.—Melanosis of a vertebra of a 6-month-old hog (E216-D3498). A black focus (arrow) of melanin is present in the body of a vertebra.

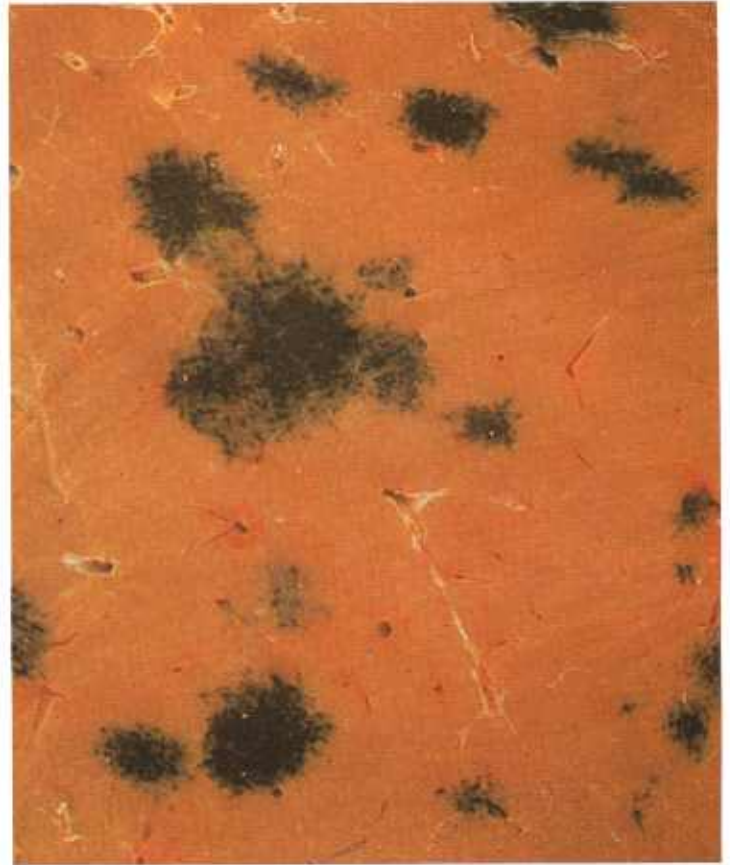

Figure 391.—Melanosis of the liver of a 6-year-old bull (E31-D1382).

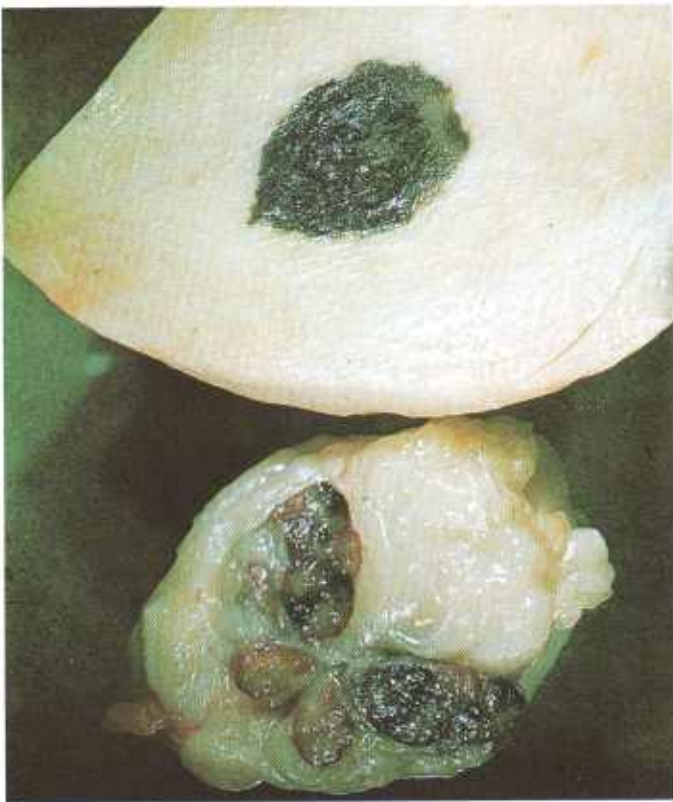

Figure 390.—Melanosis of the skin of the right flank and the right external iliac lymph node of an 8-month-old hog (E118-D2178).



Figure 392.—Melanosis of the endocardium of a 2-year-old steer (E26-D1363).

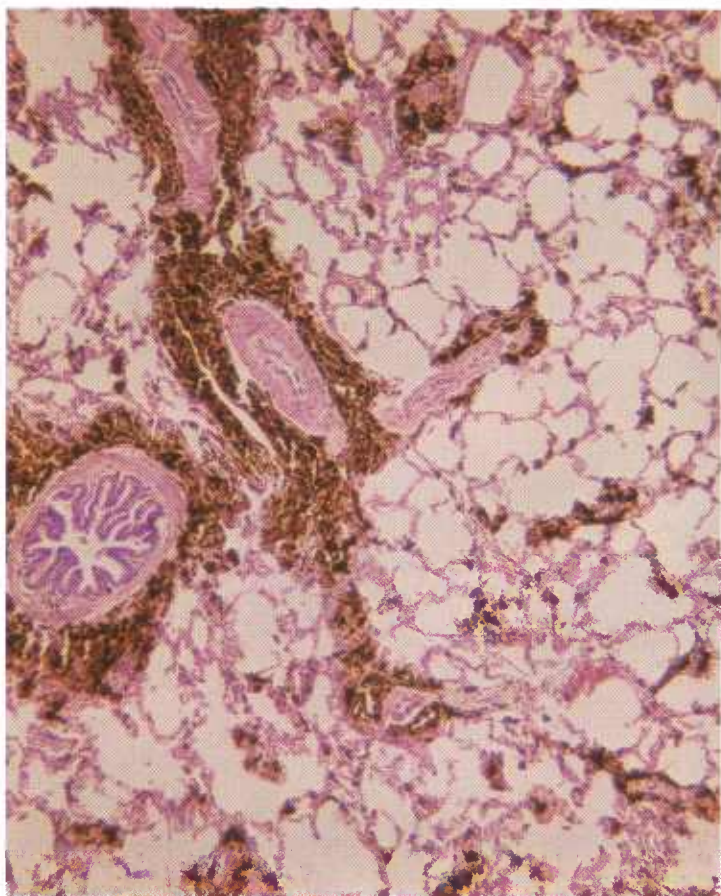


Figure 393.—Melanosis of the lung of a 6-year-old bull (E31-D1382). A dark-brown pigment (melanin) is present in the interstitial tissues of the lung. Hematoxylin-eosin stain.  $\times 50$ .

ical in shape. Most of the melanin is located intracellularly within melanoblasts or melanophores. Cells are frequently so distended with pigment that their cytologic structure cannot be determined. These heavily pigmented cells appear as black or brown globular masses (melanophores).

## Nutritional or Cachectic Fat Necrosis

**Definition.**—Nutritional or cachectic fat necrosis is a necrobiotic alteration in fat usually associated with extreme emaciation and debility.

**Distribution and incidence.**—This form of fat necrosis is found throughout the United States and is most frequently observed in cattle and sheep. It is associated with the incomplete utilization of body fat in a starving or debilitated animal. This form of necrosis may occur throughout the entire body of the animal but is most commonly observed in the abdominal fat (mesenteric, omental, and perirenal). It is commonly associated with tuberculosis and paratuberculosis in animals that have been affected for a long period of time and are showing extreme emaciation. Necrotic alterations are also observed when fat animals develop digestive disturbances (enteritis, traumatic gastritis, and impaction) or other illnesses (pneumonia and metritis), stop eating, and

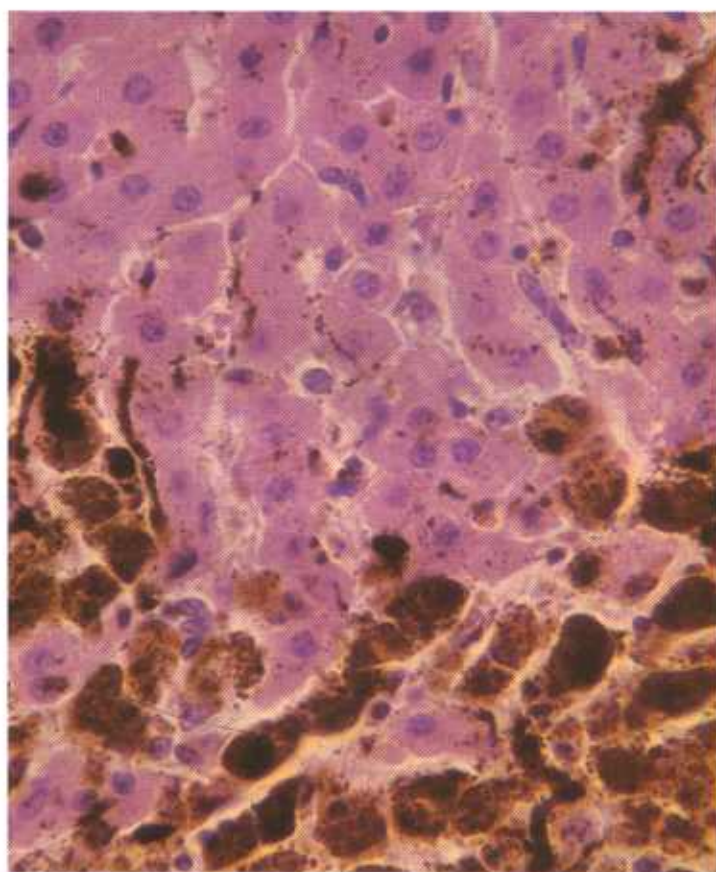


Figure 394.—A histologic preparation of the melanotic liver (E31-D1382) shown in figure 391. Numerous dark-brown granules of melanin are present in the hepatic parenchyma. Hematoxylin-eosin stain.  $\times 500$ .

The dopa reaction can be used to determine whether certain cells in the skin or other tissues contain the enzymes needed for the production of melanin. The tissue or histologic preparation is flooded with dihydroxyphenolalanine that is converted by cell enzymes to a brownish-black pigment similar to melanin.

utilize their body fats. The incidence of the disease is greater in bulls than in cows.

**Macroscopic appearance.**—The fat is opaque, chalky, white, and unusually firm. The alterations begin as small, scattered, yellowish-white foci in the fat. These foci gradually enlarge, coalesce, and finally form large firm masses of necrotic fat. Altered fat is frequently mineralized and then becomes a hard unyielding mass. This firm necrotic fat, especially that in the mesentery, immobilizes the intestinal tract and interferes with the passage of ingesta.

Extensive lesions of fat necrosis in the abdominal cavity can be recognized by rectal palpation when the firm, unyielding masses of fat are detected in the perirectal adipose tissue. The rectum may be so compressed by the altered fat that the arm cannot be inserted.

**Microscopic appearance.**—In the chemical breakdown

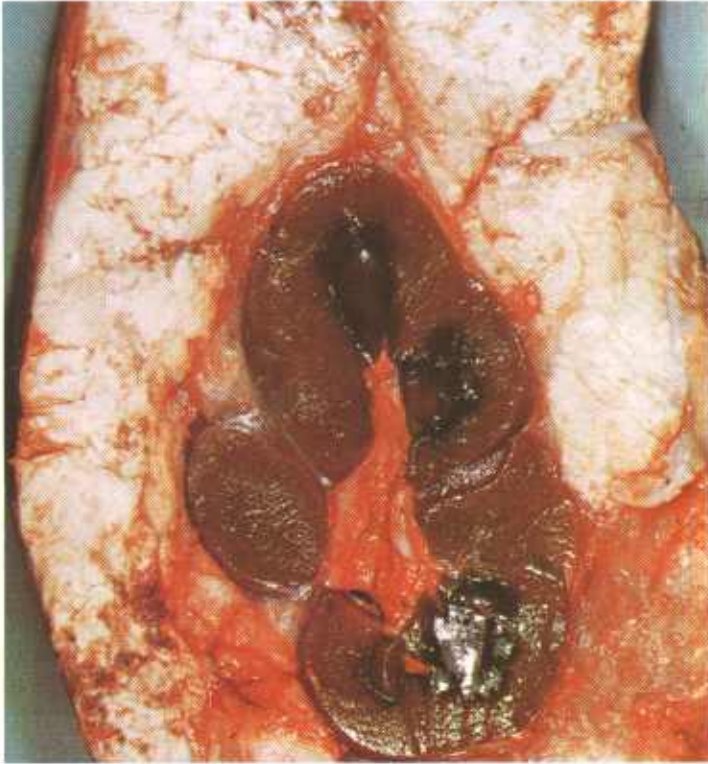


Figure 395.—Necrosis of the perirenal fat in a 2-year-old bovine animal (E1-127071). White, firm masses of partially calcified fat are enclosing the kidney.

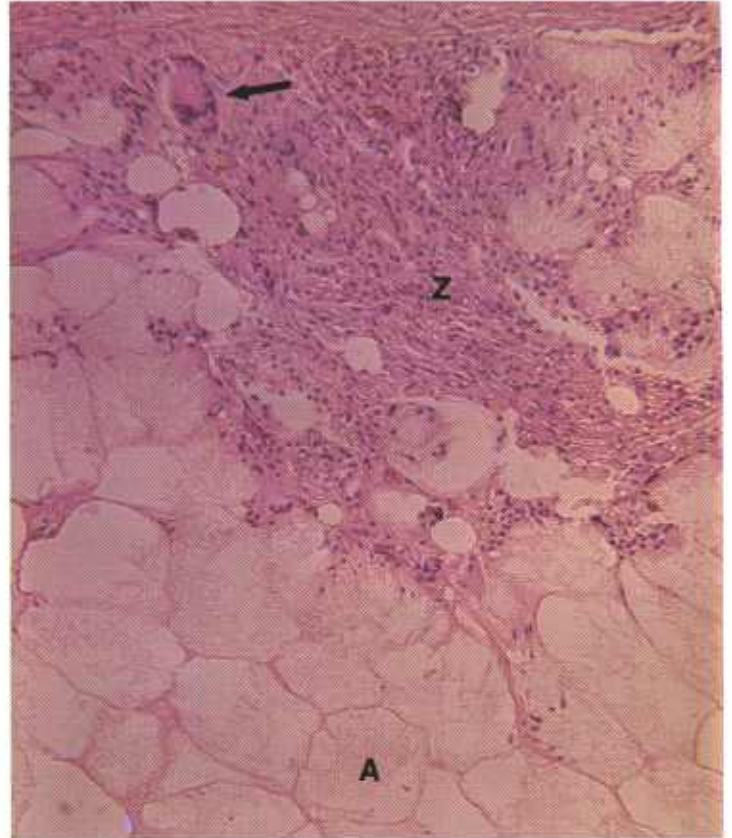

Figure 397.—Necrosis of the mesenteric fat of a bovine animal (123894). The adipose cells (A) contain a pale pink, slightly granular material in which numerous clefts and crystals can be seen. A zone (Z) of chronic inflammation composed of connective tissue, leukocytes, and a giant cell (arrow) borders the necrotic fat.


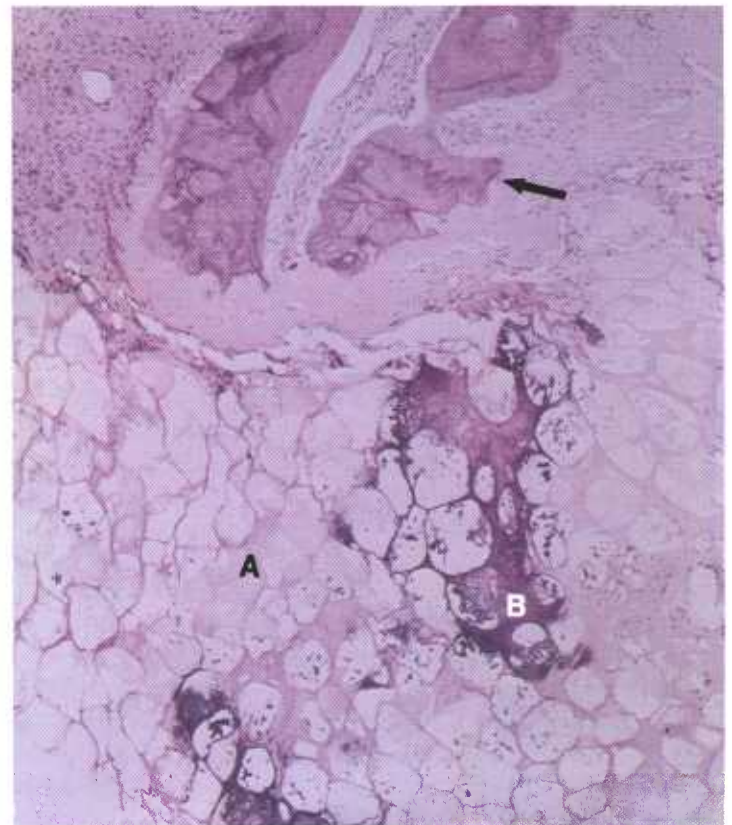


Figure 396.—Necrosis of the body fat in a 2-year-old Hereford cow (E194-D3209). The necrotic fat is firm, opaque, and lobulated, and has been partially calcified.



of fat, glycerol and fatty acids are formed. The glycerol is readily soluble in the body fluids and disappears from the area. Fatty acids, however, are not readily soluble in the fat solvents used in histology. As a result, the adipose cells contain a pale-pink (hematoxylin and eosin stain), slightly granular material with numerous clefts and crystals. The clefts are the sites of fatty-acid crystals (cholesterol) that, being more soluble in histologic reagents than other fatty acids, have been removed during the preparation of the specimen.

Calcium combines with the fatty acids in the necrotic tissue and accumulates in the area in the form of small spherical masses (calcospheres) that stain blue with hematoxylin.

An acute, or more usually a chronic, inflammatory reaction occurs at the junction of the necrotic and living

tissue. Liberated or altered fat is quite irritating and causes considerable proliferation of connective tissue. Macrophages are very abundant in the area of inflammation and giant cells are common. The inflammatory reaction is frequently confused with the local reaction to *Mycobacterium tuberculosis*, but the local inflammatory changes are caused by the necrotic fat, not by the organism.

Nutritional or cachectic fat necrosis must be differentiated from fat autolysis and putrefaction. The former exhibits hyperemia, an accumulation of leukocytes, depositions of connective tissue, mineralization, and, occasionally, bone formation. Because these alterations can only occur in the living animal, they are not present in postmortem fat autolysis and putrefaction.

## Nutritional Muscular Dystrophy ("White Muscle" Disease)

**Definition.**—Nutritional muscular dystrophy ("white muscle" disease) is a coagulative necrosis of skeletal and cardiac muscle caused by a deficiency of selenium, vitamin E, thiamine, and other nutritional substances.

**Distribution and incidence.**—The incidence of nutritional muscular dystrophy varies greatly from community to community and from year to year. All meat-producing animals are affected, whether they are raised in areas deficient in selenium, in drought-stricken districts, or on farms where excessive feeding is practiced. All of these situations are associated with problems in nutrition. Current research indicates that a deficiency of selenium is the most important cause of this disease.

**Macroscopic appearance.**—In the early stages of nutritional muscular dystrophy, colloidal changes within the sarcoplasm cause affected muscles to swell and to begin to lose the intense red characteristic of skeletal muscle. As the disease progresses and coagulative necrosis of muscle occurs, myoglobin is liberated from the muscle and most of the freed myoglobin is eliminated through the urinary system. With the liberation of myoglobin, the intense red is lost and the muscle becomes pale pink, yellowish red, gray, or white. Apart from the loss of myoglobin, color alteration is also caused by a change in the physical properties of sarcoplasm. When muscle protein is coagulated, as in the coagulation of egg white, its optical characteristics change from clear and translucent to white and opaque. The injured muscle is dry, inelastic, and firm in comparison to normal muscle.

The necrotic muscle has a remarkable ability to regenerate. After a period of several weeks, little or no evidence of the necrotic muscular change may remain.

**Microscopic appearance.**—As muscle cells undergo necrosis, they acquire fluid and swell. With this swelling the normal angularity of the cells seen in cross section disappears and the cells assume a circular shape. When necrosis is complete, the coagulated sarcoplasm has become a homogeneous mass that stains intensely pink with eosin and fills the distended sarcoplasm. When the cells are viewed in longitudinal section, most of their cross striations have disappeared.

Muscle nuclei adjacent to the sarcolemma are usually still viable, even though the sarcoplasm is coagulated. For this reason, muscle cells may regenerate and become functional again. Shortly after coagulation of the sarcoplasm occurs, muscle nuclei and the thin layer of sarcoplasm surrounding them begin to proliferate and to commence the process of regeneration.

These proliferating muscle nuclei and their surrounding sarcoplasm are known as sarcoblasts. Before new sarcoplasm can fill the persisting sarcolemma sheath, the old necrotic sarcoplasm must be removed. A small amount of the necrotic sarcoplasm is lysed by the lytic enzymes normally found in tissue, some is phagocytosed by macrophages, but most is removed by the sarcoblasts. In the process of muscle repair, the sarcoblasts undergo hypertrophy, multiply, form muscle giant cells, and digest the necrotic sarcoplasm. Vacuoles and fissures appear in the sarcoplasm as the process of digestion and removal of the coagulated sarcoplasm takes place. While the process of digestion and removal of the necrotic tissue is occurring, sarcoblasts are also regenerating sarcoplasm with its striated myofibrils.

Since coagulated sarcoplasm is only mildly irritating, the appearance of an inflammatory response in the affected muscle is slow. Macrophages, lymphocytes, neutrophils, and eosinophils appear but do not congregate in the area in great numbers for several days. Macrophages may penetrate the sarcolemma sheath and assist the sarcoblasts in removing necrotic sarcoplasm. Those muscle cells that are completely necrotic—whose nuclei were destroyed—are phagocytosed by macrophages

←  
Figure 398.—Necrosis of the perirenal fat in a bovine animal (D3782). The necrotic fat cells (A) contain a pink, slightly granular material in which numerous clefts and crystals are present. Some of the necrotic fat has been calcified (B) and stains blue. Metaplasia with the formation of bone has occurred in one area (arrow). Hematoxylin-eosin stain. × 50.

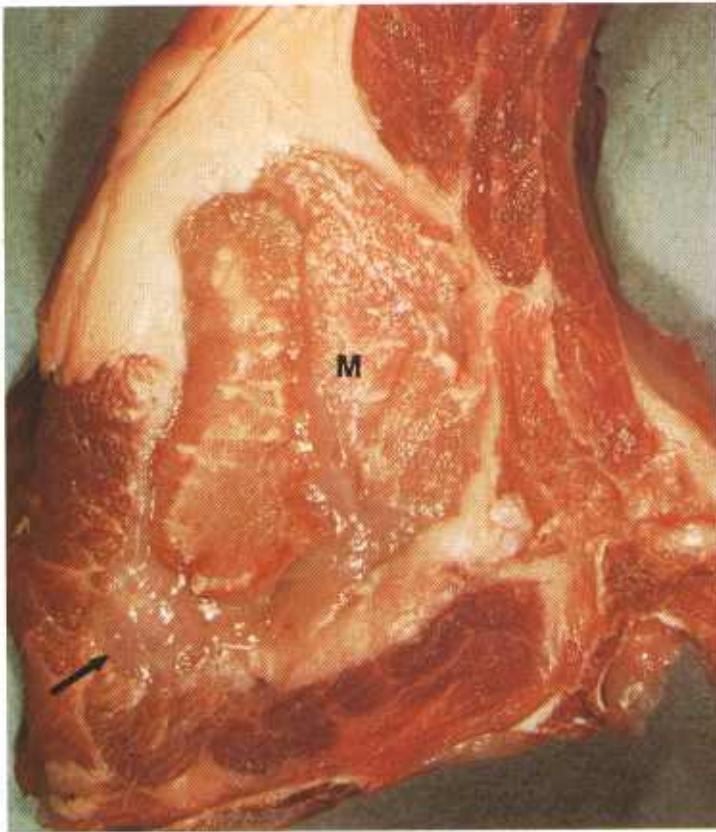


Figure 399.—Coagulative necrosis of the loin muscle of a 1-year-old hog (E30-D1383). The longissimus dorsi (M) muscle is firm and yellow and has been partially calcified. It contains zones of hyperemia where inflammation is in progress and is bordered by chronic inflammatory tissue (arrow).

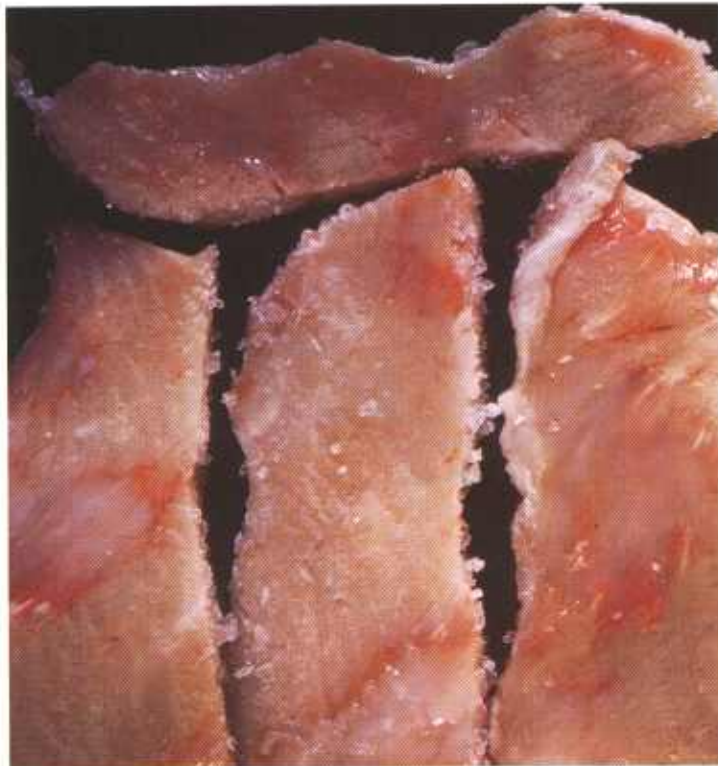


Figure 400.—Coagulative necrosis of the loin muscle of a 6-month-old hog (E169-D2941). The necrotic muscle is firm, white, opaque, and dry. It has a “cooked” appearance.




Figure 401.—Coagulative necrosis of the thigh muscles of a 4-year-old steer (E198-D3230). The necrotic muscle is not as red as normal muscle because of the loss of myoglobin. The muscle alterations are not as severe as those in figure 400.

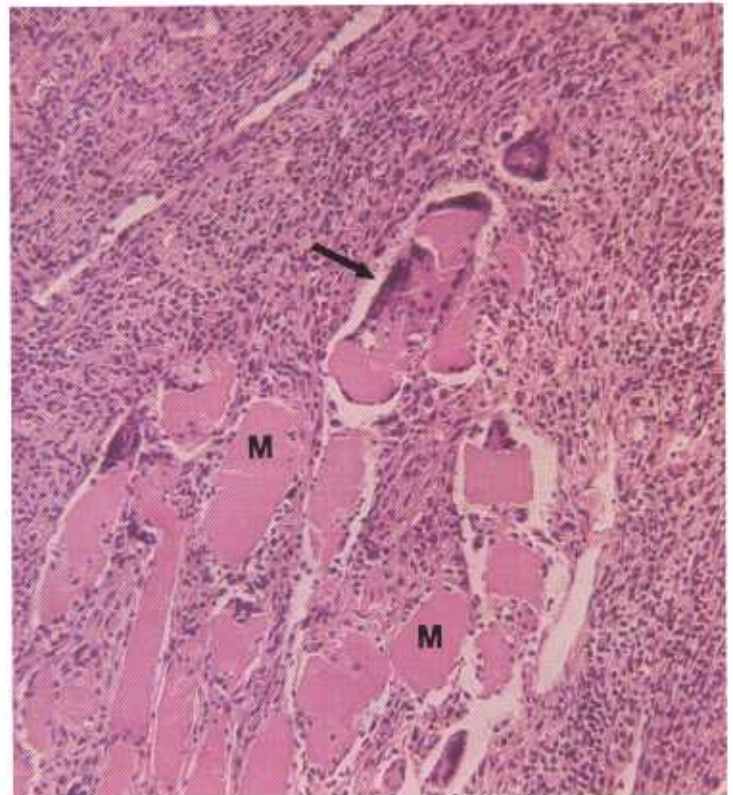


Figure 402.—A histologic preparation of the loin muscle (E30-D1383) shown in figure 399. Only a few muscle cells surrounded by chronic inflammatory tissue remain in the affected area. The necrotic muscle cells (M) have lost their normal angularity, their cytoplasm is coagulated, and many sarcoblasts (arrow) are present. Hematoxylin-eosin stain.  $\times 125$ .

without the assistance of sarcoblasts. Calcium and phosphorus are deposited in necrotic muscles. The muscles of calves may contain 20 times the normal amount of calcium and twice the normal amount of phosphorus.

After a period of several weeks all of the necrotic

muscle will have been removed and the sarcolemma sheaths will again be filled with sarcoplasm and myofibrils. When regeneration is complete, the inflammatory reaction disappears, and limited or complete function of the muscle is restored.

## Osteohemochromatosis (Porphyria)

**Definition.**—Osteohemochromatosis is a brown pigmentation of bone caused by the presence of porphyrin (uroporphyrin I).

**Distribution and incidence.**—This brown pigmentation of bone is observed throughout the United States. Although the disease can probably occur in all meat-producing animals, it is most frequently observed in cattle and swine.

It has been shown that this disturbance in the metabolism of hemoglobin is an inherited recessive trait and that the disease should be designated *congenital porphyria*. Osseous pigmentation is present in affected animals at the time of birth and persists for life.

Affected animals are in a medium to a good condition unless solar injury has occurred. Carcasses are usually boned and the unaffected meat is utilized for food.

**Macroscopic appearance.**—In osteohemochromatosis, all of the bones of the skeleton are reddish brown, brown, or black. The pigment involved is deposited in alter-

nating light and dark bands that correspond to the rate of bone growth during various periods of skeletal development. Periosteum is not involved, and the texture of the bones is not altered. Neither cartilage, articular cartilage, ligaments, nor tendons are involved, a circumstance that aids in differentiating osteohemochromatosis from other pigmentations. The reason for the deposition of uroporphyrin in bones is the marked affinity this pigment has for calcified structures. Porphyrin produces a brownish-pink discoloration in teeth that accounts for the popular name "pink tooth" that is applied to the disease. (Dentine and cement are discolored but enamel is unpigmented.) The urine in affected animals is amber or reddish brown.

When excessive amounts of porphyrin are present in the body, areas of the skin not protected by hair, wool, or melanin become extremely sensitive to solar radiation. The cutaneous reaction may consist of hy-

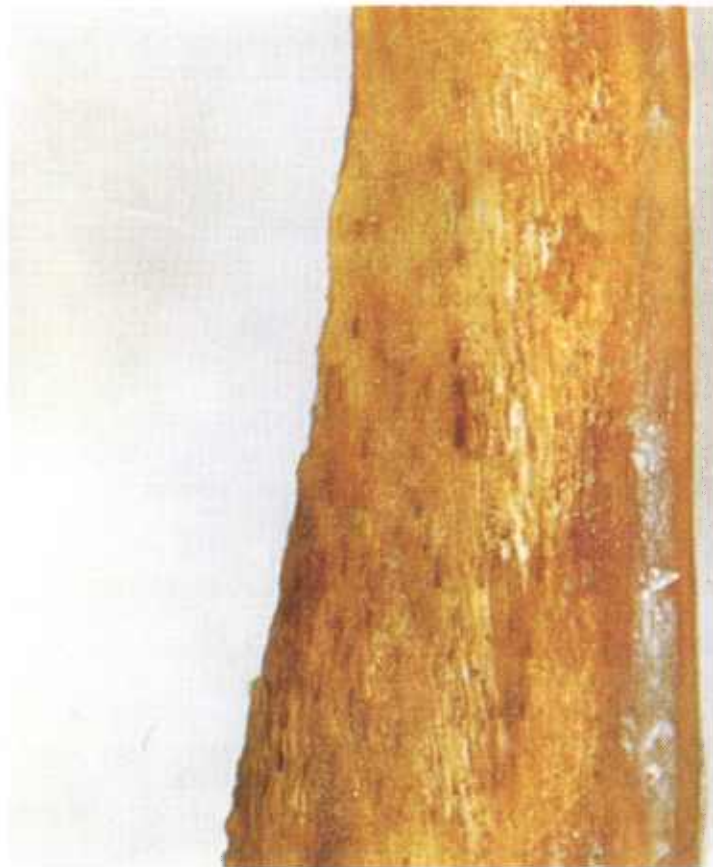

Figure 403.—Osteohemochromatosis of a bone from a 3-year-old bull (E180-D3083). The bone is brown because porphyrin is present.

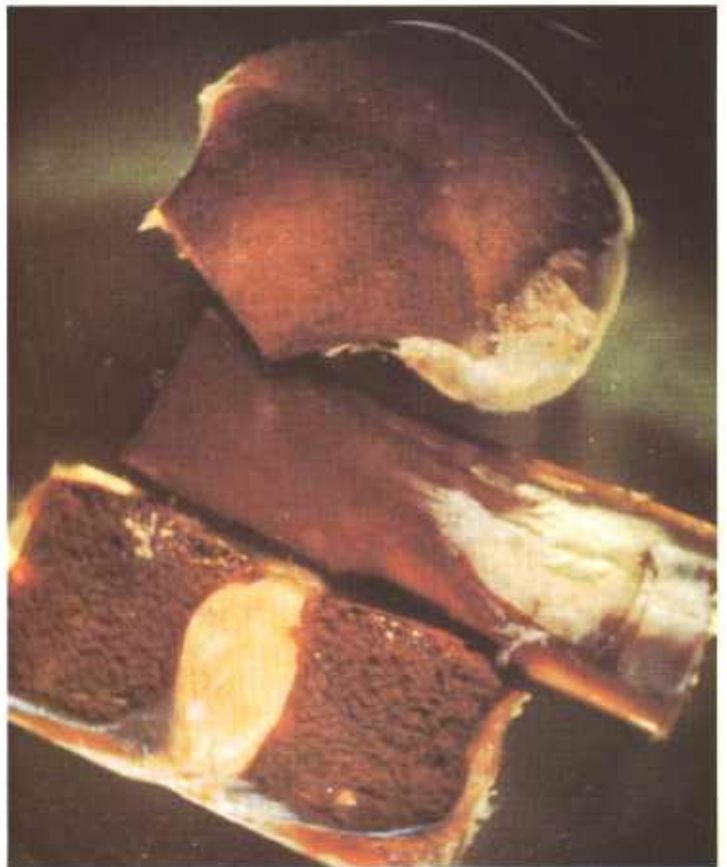

Figure 404.—Osteohemochromatosis of two vertebrae and a long bone in a 1-year-old hog (E46-D561). The brown coloring is caused by the presence of porphyrin.

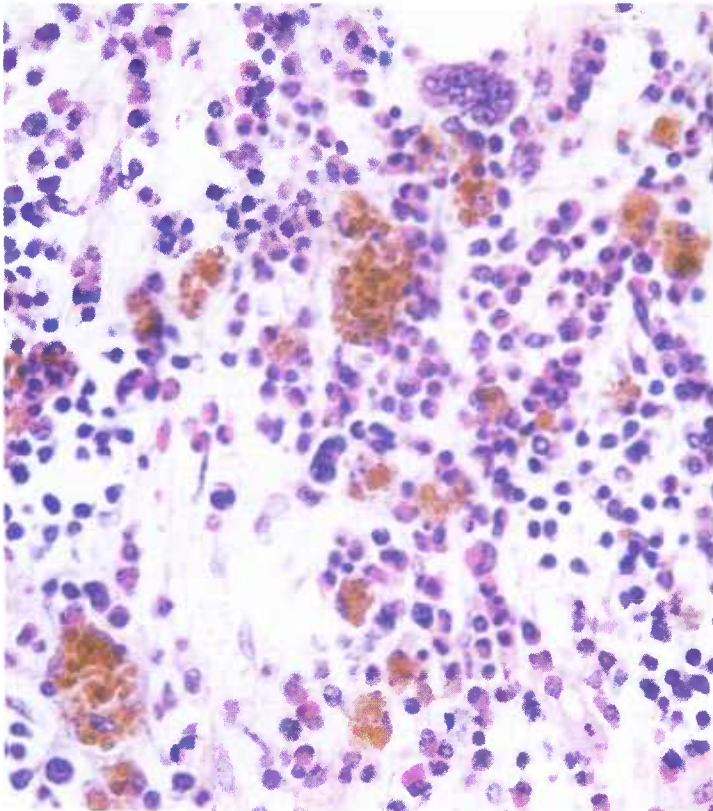


Figure 405.—A histologic preparation of the affected bone (E180-D3083) shown in figure 403. Granules of porphyrin are present in the bone marrow. Hematoxylin-eosin stain.  $\times 600$ .

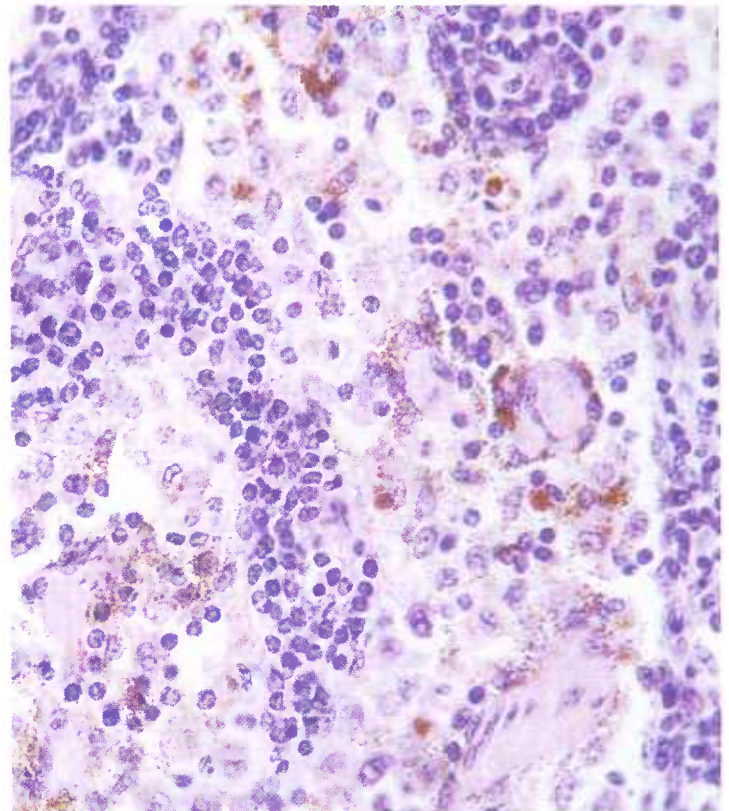


Figure 406.—A histologic preparation of a lymph node from a 3-year-old bull (E180-D3083). Granules of porphyrin are present in the sinuses of the node. Hematoxylin-eosin stain.  $\times 600$ .

peremia, vesicle formation, or necrosis. The severity of skin lesions depends upon the intensity of the solar radiation and the amount of cutaneous pigmentation occurring in specific families of animals.

**Microscopic appearance.**—When tissues containing porphyrin are exposed to ultraviolet light, fluorescence is observed. If bone tissue is decalcified, the uroporphyrin is removed with the calcium salts and the tissue no longer fluoresces. Melanin and hemosiderin pigments

could be confused with the porphyrin pigment if it were not for the fact that they do not fluoresce.

Bone marrow and the spleen, liver, lungs, kidney, and lymph nodes, and sometimes other organs as well, contain the brown, granular, iron-free porphyrin pigment. The pigment is irregular in size and shape and resembles granules of hemosiderin. It is enclosed within the cells of the reticuloendothelial system of the organ or tissue involved.

## Ossification of the Lungs

**Definition.**—Ossification of the lungs is a condition in which bone appears in the pulmonary tissue.

**Distribution and incidence.**—Ossification of pulmonary tissues is occasionally found in meat-producing animals throughout the United States. It is most frequently observed in cattle, seldom in sheep, and seldom in swine. Ossification of the lungs is usually found in old cattle. A few feeder cattle and an occasional calf are also affected. Animals with this pulmonary disease are usually in fair to good condition but a few are emaciated.

The extensive arteriosclerotic lesions (degeneration, necrosis, fibrosis, calcification, and ossification) in the endocardium and the walls of the aorta, arteries, vena cava, and veins indicate that the pulmonary ossification is a manifestation of a general systemic disease. A fourth of the cattle with extensive arteriosclerosis have ossification of the lungs.

Ossification of the lungs is probably associated with hyperparathyroidism, hypervitaminosis D, and chronic debilitating diseases (tuberculosis, paratuberculosis, nephritis, metritis, and complications of lactation and pregnancy) where demineralization of the skeleton occurs with resulting hypercalcemia. Tissue alterations of degeneration and necrosis also cause local precipitation of calcium. An increased alkalinity can cause a precipitation of calcium by lowering the solubility of calcium salts in body fluids, as in pulmonary tissues during the gaseous exchange of respiration, when the lung eliminates acids and becomes relatively alkaline.

When abnormal deposits of calcium occur in tissue, the calcium salts stimulate connective tissue proliferation and cause local metaplasia of fibroblasts to osteoblasts with resultant bone formation. Extensive proliferation of the interlobular connective tissue both precedes

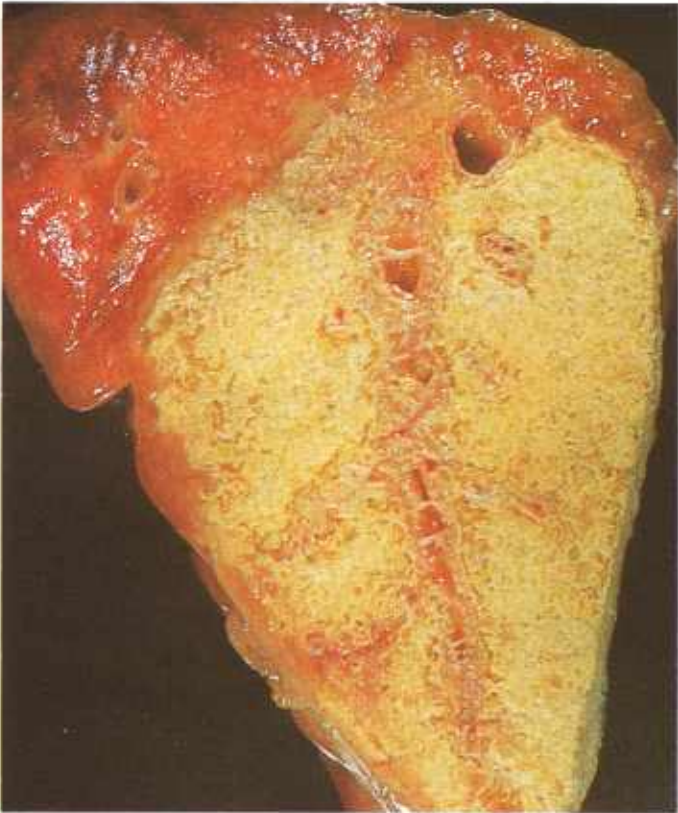


Figure 407.—Ossification of the lung of a 12-year-old horse (E21-D1781). A pale yellow network of bone spicules is present in the lung.

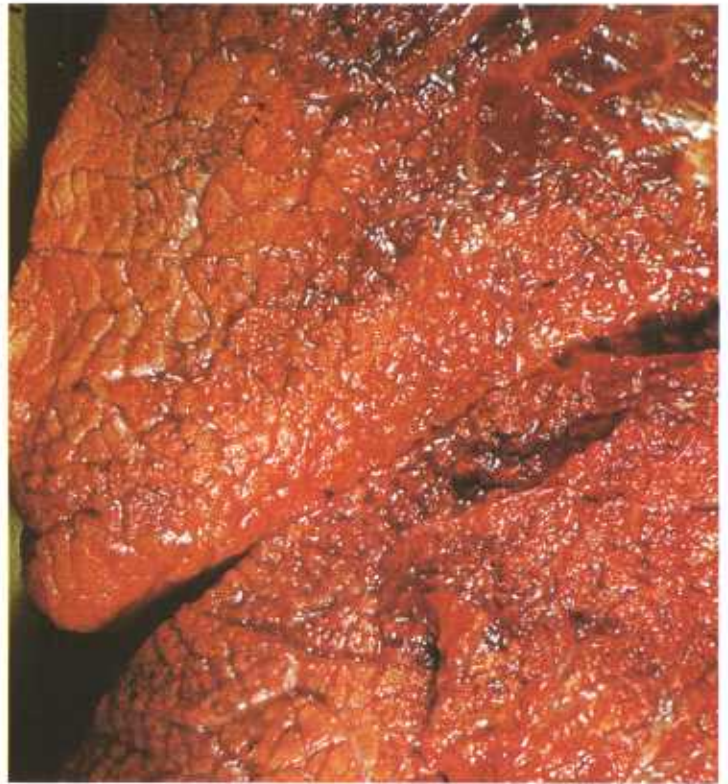

Figure 409.—Ossification of the lung of a 3-year-old cow (E71-129385). The lung is firm, dense, and inelastic. The pulmonary lobulation is more prominent than normal and the surface of the lung imparts a granular sensation when palpated.

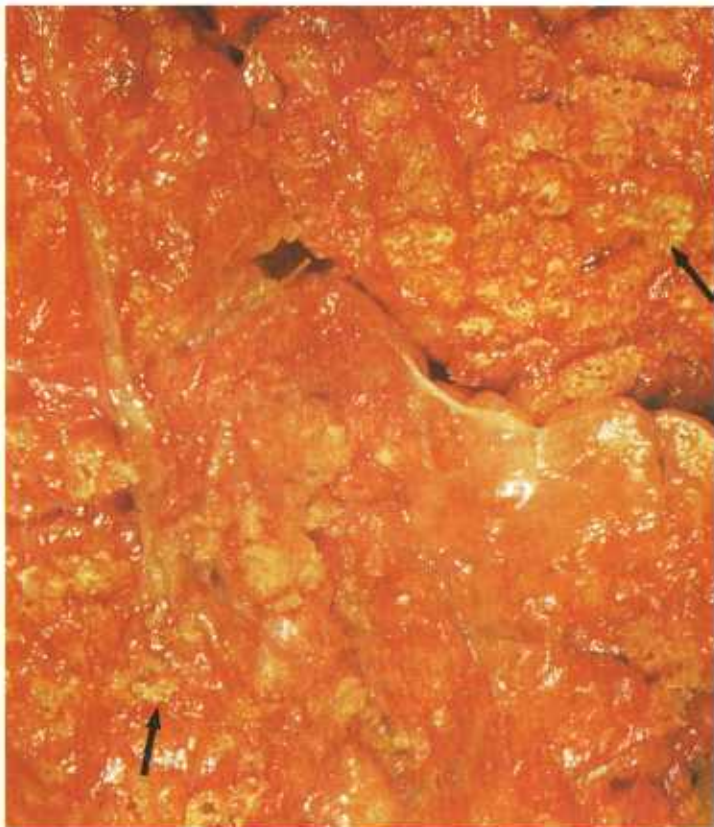

Figure 408.—Ossification of the lung of an adult Holstein cow (E4-127791). Multiple foci of bone spicules and plates are present in the lung (arrows).

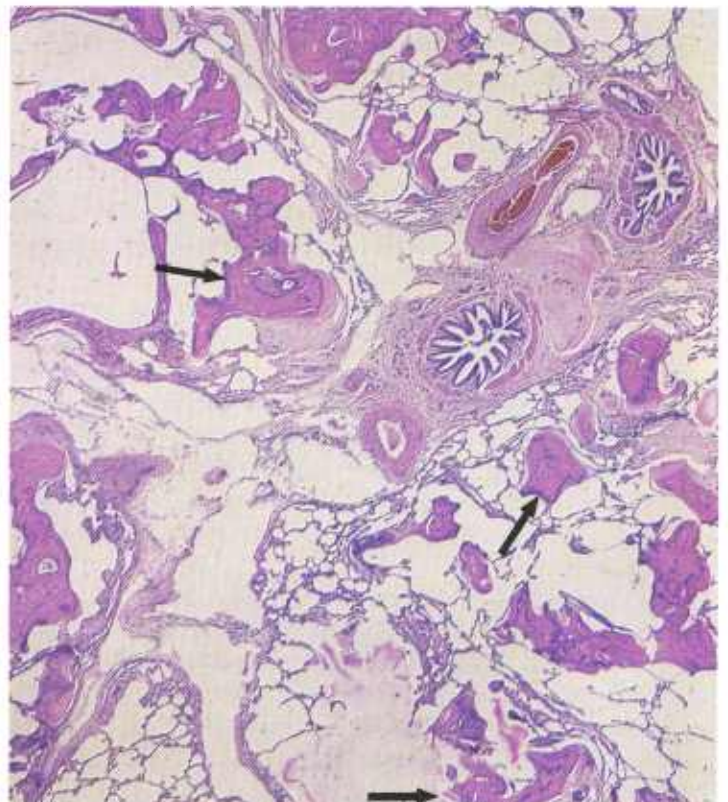


Figure 410.—Ossification of the lung of a 3-year-old bull (D3182). Many spicules (arrows) of bone are present. The lung is emphysematous but shows no inflammatory reaction to the presence of the bone. Hematoxylin-eosin stain.  $\times 25$ .

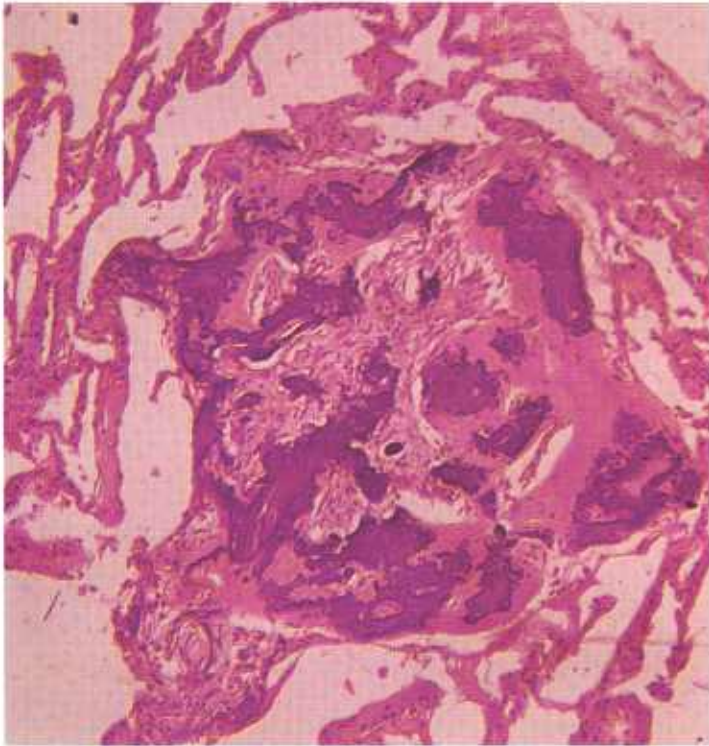


Figure 411.—A histologic preparation of the lung (E71-129385) shown in figure 409. The bone spicules have a focal arrangement. Hematoxylin-eosin stain.  $\times 125$ .

and progresses concomitantly with the deposition of bone. Under these conditions, the disorganized calcium precipitate is replaced by organized bone with the formation of bone lacunae, Haversian canals, and sometimes even marrow spaces containing fibrofatty tissue or

hematopoietic elements. Heterotopic bone may thus be encountered in any focus of metastatic or dystrophic calcification.

**Macroscopic appearance.**—Numerous small spicules and plates of bone are found throughout the pulmonary parenchyma. The amount of bone present varies with the animal affected. The lungs have an irregular surface and a dry consistency. They crepitate when palpated and do not collapse in the usual manner when removed from the carcass because of the rigidity of the pulmonary tissues and the slight to moderate pulmonary emphysema present. A crackling sound heard when parts of the lung are compressed is caused by fracturing of the spicules and plates of bone in the parenchyma.

**Microscopic appearance.**—Numerous spicules and plates of mature bone containing Haversian canals, lacunae, and canaliculi are present in areas of fibrosis in the interstitial tissue of the lung. The absence of infiltrations with leukocytes, accumulations of hemosiderin, or residual signs of pneumonia in the vicinity of the bone indicates that the formation of osseous tissue was not the result of metaplasia associated with previous inflammatory alterations in the area.

Because of the rigidity of the lungs and the fact that the inspiratory force of respiration is greater than the expiratory force, air accumulates in the lung and causes alveolar pulmonary emphysema. The alveolar distention is responsible for giant alveoli, rupture of alveolar walls resulting in confluence of several alveoli, and the formation of gas bubbles in the interstitial tissue. The presence of fibrous connective tissue, rigid bone, and alveolar emphysema causes considerable distortion of the pulmonary parenchyma.

## Panarteritis

**Definition.**—Panarteritis is a subacute or chronic inflammation involving small or medium-sized arteries throughout the entire animal.

**Distribution and incidence.**—Panarteritis occurs sporadically in cattle and swine throughout the United States. All ages, except the very young, are affected. Other meat-producing animals are seldom involved. Specimens collected in Denver were from swine that were 6 months to 5 years of age and from cattle that were 6 months to 9 years old. No sex predominance has been established. The etiology of this condition has not been determined.

Panarteritis has little importance as a cause of death. A few animals may die from advanced cardiac and renal lesions. Lesions of the disease are found in many tissues or organs but are most frequently observed in the kidneys, heart, and liver. Lesions in the heart and liver are confused with the alterations associated with cysticercosis

and pentastomiasis. In the mesentery, skeletal muscle, and subcutaneous tissues, the tortuous vessels are suspected of being the lesions of nematodiasis, especially onchocerciasis and dracunculiasis.

**Macroscopic appearance.**—Affected arteries are enlarged throughout their entire length and are readily visible as tortuous cords in the tissues or organs involved. They protrude from the exposed cut surface of tissues or organs as oval or circular gray structures that measure up to 4 mm. in diameter and that may or may not contain a visible lumen.

**Microscopic appearance.**—The magnitude of this vascular disease is recognized when histologic examinations are made and it becomes apparent that many arteries not visible grossly are also affected. Enlargement of affected vessels is due to inflammation and the abundant deposition of connective tissue in the intima, media, and adventitia. The largest deposits of connective tissue are

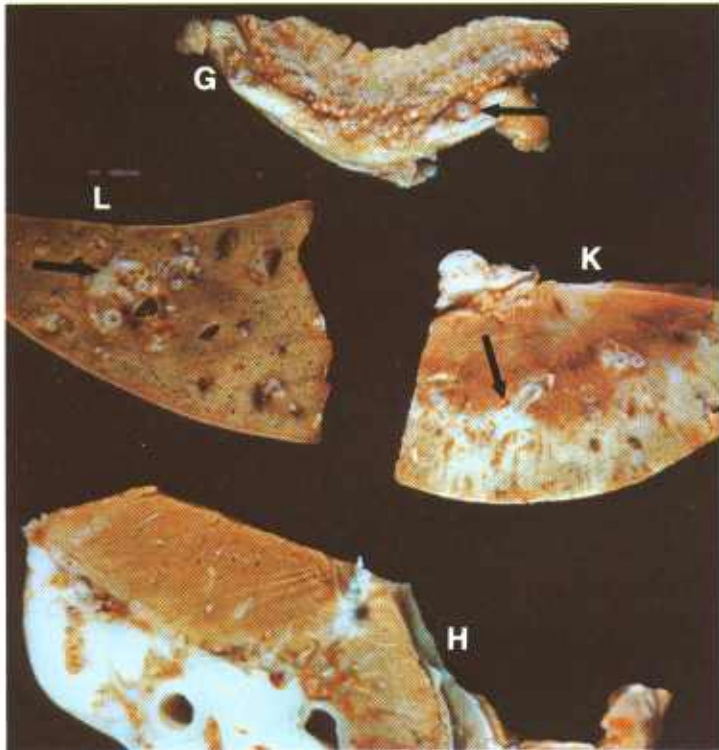


Figure 412.—Panarteritis of the gallbladder (G), liver (L), kidney (K), and heart (H) of a 2-year-old steer (E114-D2189). The arteries (arrows) are very prominent and protrude from the cut surface because of a thickening of their walls.

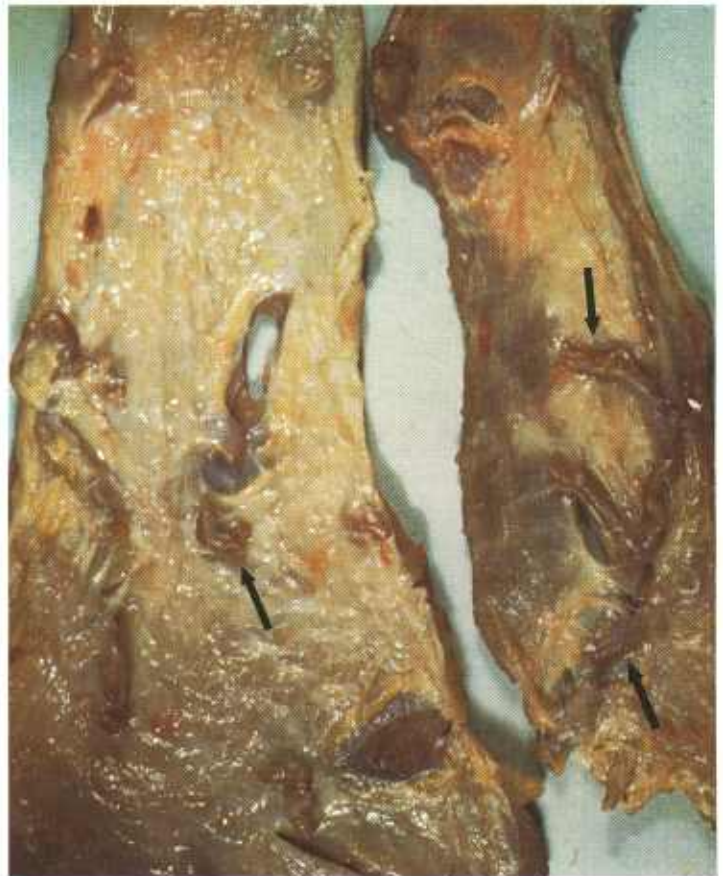

Figure 414.—Panarteritis of the panniculus carnosus of a 4-year-old cow (E49-D1435). The affected arteries appear as tortuous cords (arrows) in the muscle.

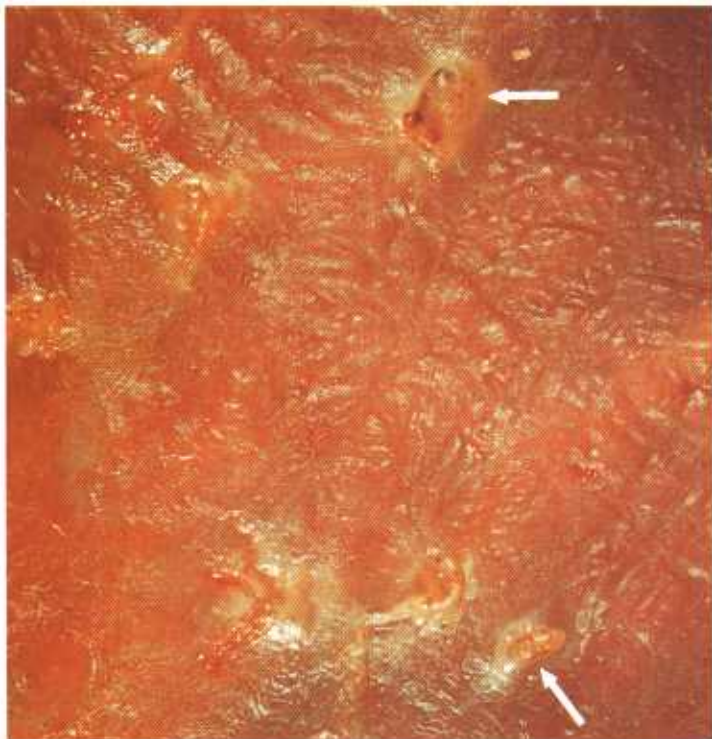


Figure 413.—Panarteritis of the diaphragm of an adult cow (E107-130101). The arteries (arrows) have thick walls and protrude from the musculature.

in the adventitia, where they are arranged concentrically around the vessel. Muscle cells in the media are fewer than normal and are separated from one another by connective tissue.

Degenerative arteriosclerotic changes with calcification, which may or may not be an independent vascular disease, are present in the walls of some of the arteries. A few vessels are thrombosed, but, in general, endothelial changes are minimal. A few neutrophils, eosinophils, macrophages, lymphocytes, and hemosiderin granules are present within the walls of affected vessels and in the adjacent periarterial tissue.

Connective tissue deposition in the intima of affected arteries causes stenosis or obliteration of their lumens. Capillaries are prominent in the adventitia and in the former luminal region of obliterated vessels, suggesting that the process of healing is attempting to provide tissues or organs supplied by the affected artery with an adequate blood supply. Quite frequently these capillaries in the affected vessel show changes in their walls similar to those observed in the original vessel, indicating a continuation of the arterial lesion.

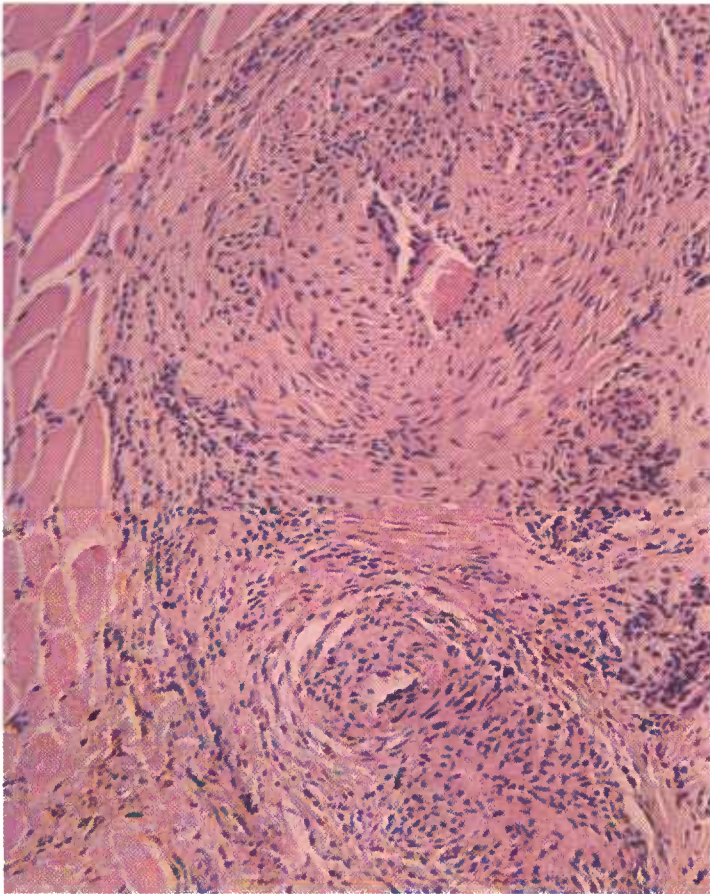


Figure 415.—A histologic preparation of the muscle (E49-D1435) shown in figure 414. The walls of the arteries are greatly thickened because of the chronic inflammatory process that is present. Hematoxylin-eosin stain.  $\times 125$ .

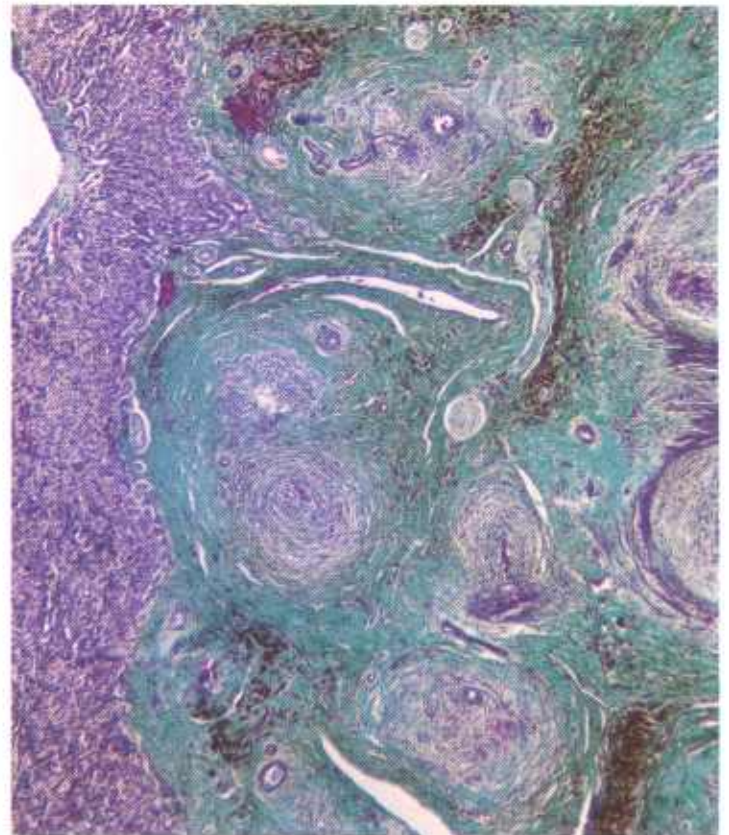


Figure 416.—A histologic preparation of the liver (E114-D2189) shown in figure 412. The walls of the arteries are greatly thickened because of the chronic inflammatory process that is present. Connective tissue stains green, muscle and hepatic parenchyma stain purple, hemosiderin stains black, and blood stains red. Gomori's trichrome stain.  $\times 50$ .

## Pulmonary Adenomatosis of Cattle

**Definition.**—Pulmonary adenomatosis is a disease of cattle characterized by pulmonary emphysema and hyperplasia and hypertrophy of the septal cells of the lungs.

**Distribution and incidence.**—This bovine pulmonary disease is found throughout the United States, and is known by local names, such as pulmonary emphysema, bovine asthma, fog disease, and kale, rape, or sweet-potato poisoning. Many types of feed can cause the disease. The etiology has not been clarified.

**Macroscopic appearance.**—The principal lesions found at necropsy are quite constant in their characteristics. The entire lung is involved with either a diffuse alteration or with multiple focal areas of consolidation. Affected lungs are voluminous and do not collapse when the thoracic cavity is opened. Often the imprint of the ribs can be seen upon the lungs. Lesions are not limited to the anteroventral part of the lungs as is usual in bronchopneumonia. Involved lung tissue has a reddish-pink, slightly cyanotic appearance resembling that of the thymus gland. The degree of consolidation depends upon the length of time the animal has been ill. If the disease has been present for a long period, a complicating

bronchopneumonia is sometimes observed in the anteroventral part of the lungs. When the lung is incised, an abundance of pink, foamy fluid flows from its cut surface, indicating extensive pulmonary edema. A quantity of white foam is found in the bronchi and trachea.

Parts of the lung that are not hepatized show a marked alveolar pulmonary emphysema. Interstitial pulmonary emphysema is prominent because the overdistention of alveoli and the rupture of alveolar walls allows air to escape into the interstitial tissue of the lung. When air enters the interstitial tissue it migrates to the hilus of the lung and then escapes into the mediastinum. Occasionally, the gas passes onward through the anterior thoracic inlet and appears under the skin of the neck and shoulders or follows the large blood vessels posteriorly and accumulates in the perirenal region.

An acute general passive hyperemia occurs. The heart is slightly or moderately dilated. Both the systemic alterations and the cardiac dilatation are caused by the reduction in the area of the capillary bed in the lungs and the interference with the exchange of gases.

**Microscopic appearance.**—Histologic examination of the lung does not reveal the acute inflammatory reaction

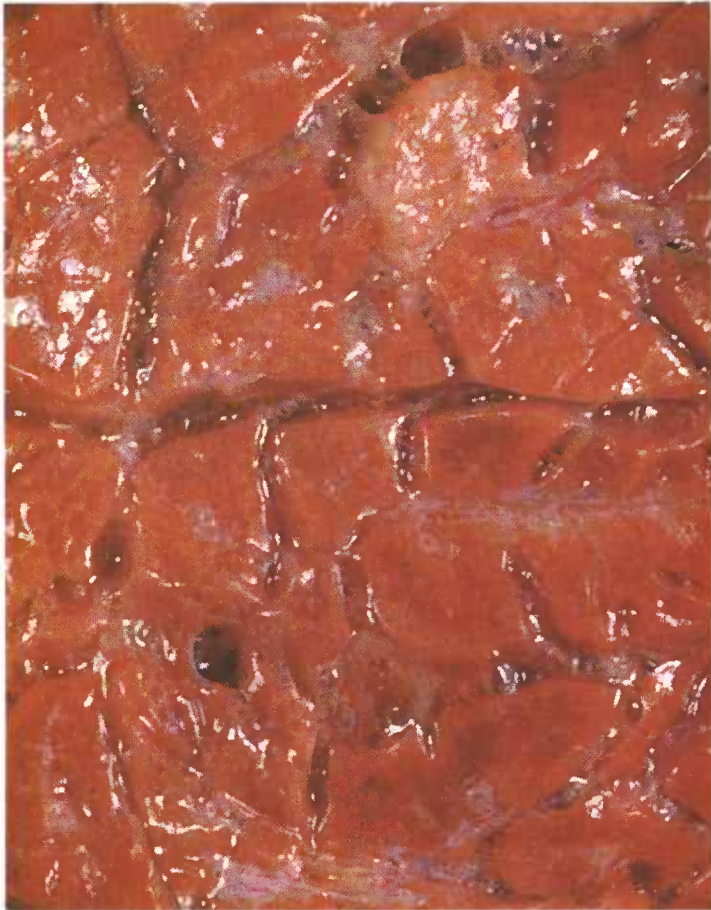

Figure 417.—Acute pulmonary adenomatosis of the lung of a steer (E45-129596). The pulmonary tissue has a dense, hepatized appearance.

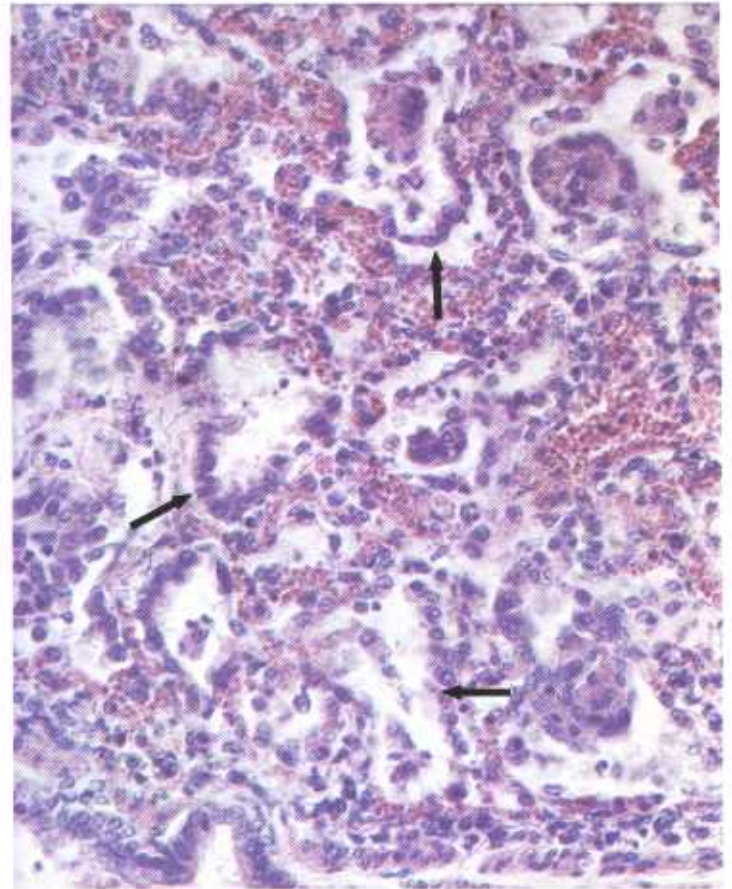


Figure 418.—Acute pulmonary adenomatosis of the lung of a steer (M16185). A layer of septal cells (arrows) is covering the luminal surface of the alveolar walls. Hematoxylin-eosin stain.  $\times 375$ .

associated with viral or bacterial diseases. Phagocytic cells are few unless a secondary complicating pneumonia or bronchitis is present. The most pronounced lung lesions are alveolar and interstitial pulmonary emphysema and hyperplasia and hypertrophy of the septal cells. In the more advanced cases, the alveolar walls are completely covered with one or more layers of septal cells, and at times the alveoli are entirely filled with these cells. Hypertrophy of the pulmonary musculature becomes prominent in animals affected for several days. In those animals with a very acute fulminating form of the disease, pulmonary emphysema and edema are

prominent alterations but very little septal cell hyperplasia is present. Hyperplasia and hypertrophy of the bronchial epithelium are usually observed. The lumens of the bronchi contain many septal cells and desquamated bronchial epithelial cells.

It is obvious that dyspnea is caused by the layer or layers of septal cells lining the alveoli that prevent the free exchange of gases between the lumens of the alveoli and the blood. Air is not able to enter some alveoli because they are completely filled with septal cells. Bronchial involvement and the presence of foam in the air passages also interfere with tidal air flow.

## Pulmonary Adenomatosis of Sheep

**Definition.**—Pulmonary adenomatosis is a disease of sheep characterized by hyperplasia and hypertrophy of the septal cells of the lungs.

**Distribution and incidence.**—Adenomatosis, often known as jaagsiekte, lunger disease, or Montana progressive pneumonia, is a disease of range sheep and is apparently most common in Montana. Farm flocks in the central and eastern United States are not affected. It is principally a disease of old ewes more than 4 years of age. Lambs and yearlings are seldom affected. Affected

sheep cannot keep up with the rest of the flock during drives or when grazing on the range. They gradually lose condition and seldom raise lambs. Because they represent an impending financial loss, affected sheep are "culled" before death occurs. Approximately 2 to 3 percent of range sheep in affected areas are lost each year because of this disease. Although a viral agent has been suspected of being the cause of pulmonary adenomatosis, adequate proof of its presence is lacking.

Pulmonary alterations associated with verminous

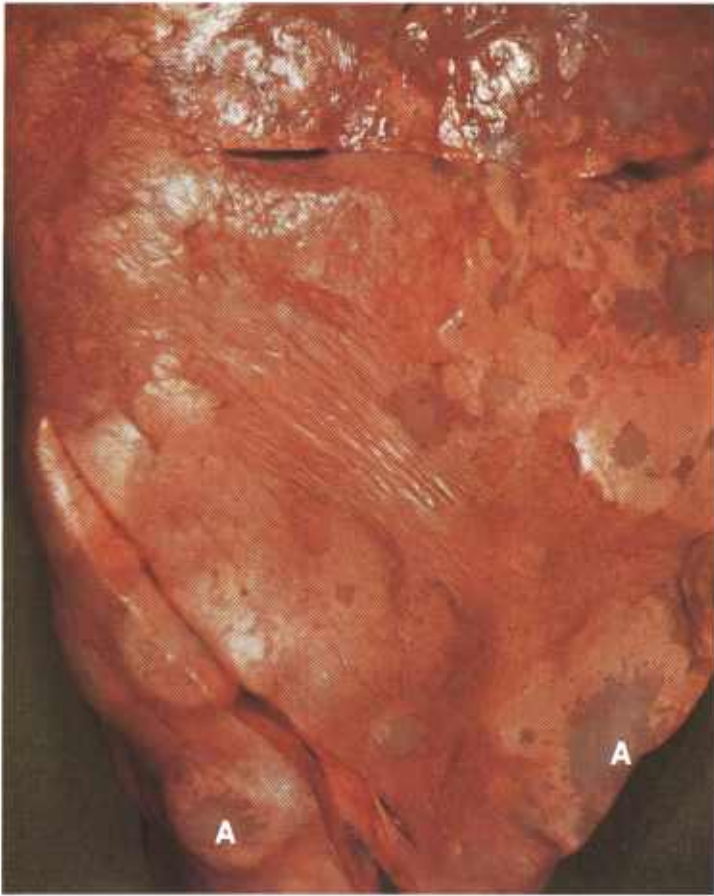

Figure 419.—Chronic pulmonary adenomatosis of the lung of a sheep (E8-127246). The adenomatous areas (A) are surrounded by a zone of alveolar emphysema.

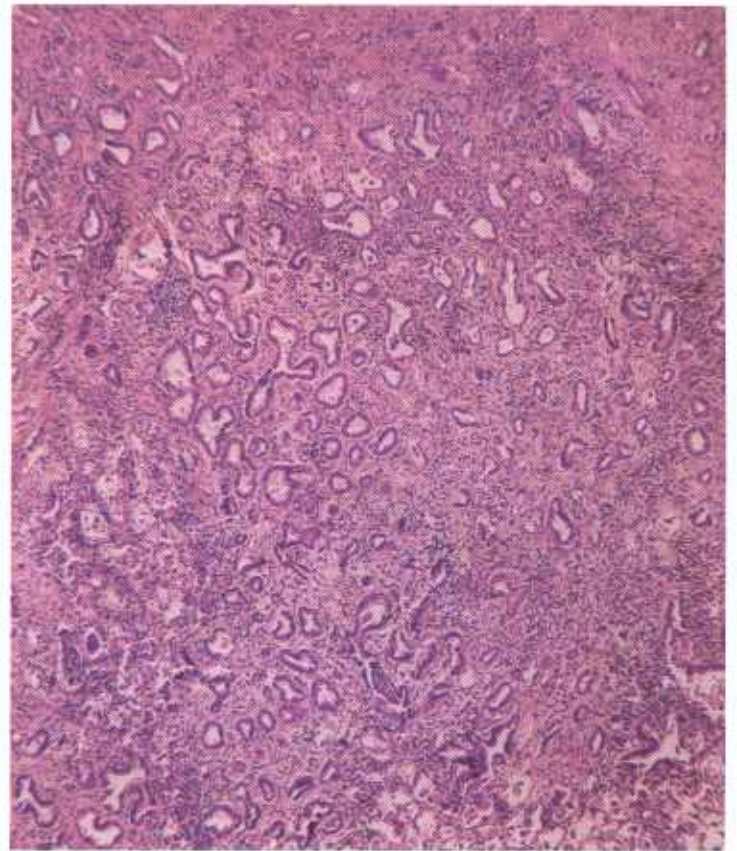


Figure 421.—A histologic preparation of the lung (E8-127246) shown in figure 419. A hyperplasia of the septal cells has resulted in the formation of alveoli that resemble the alveolar arrangement of an adenoma or an adenocarcinoma. Hematoxylin-eosin stain.  $\times 50$ .

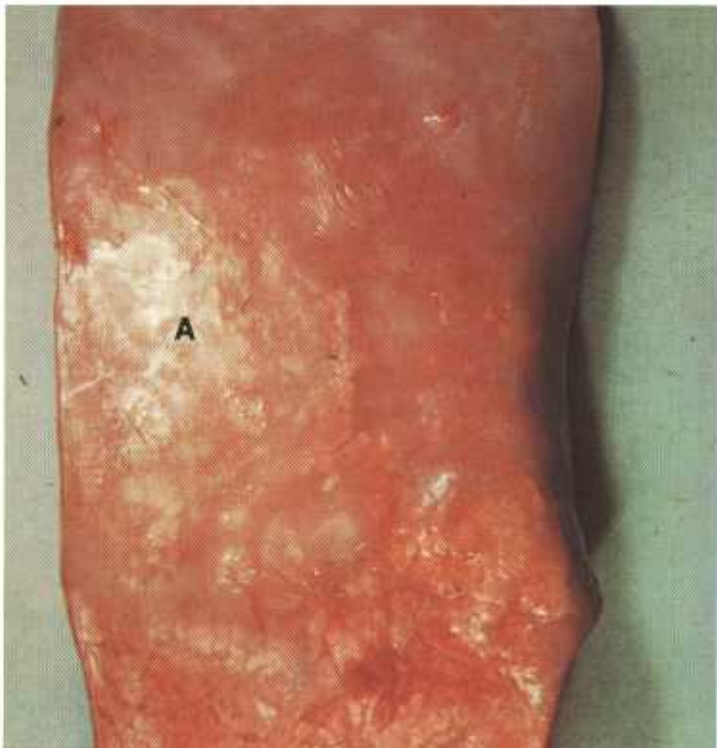


Figure 420.—Chronic pulmonary adenomatosis of the lung of a sheep (E8-127246). The adenomatous area (A) of the lung has a gray, consolidated appearance.

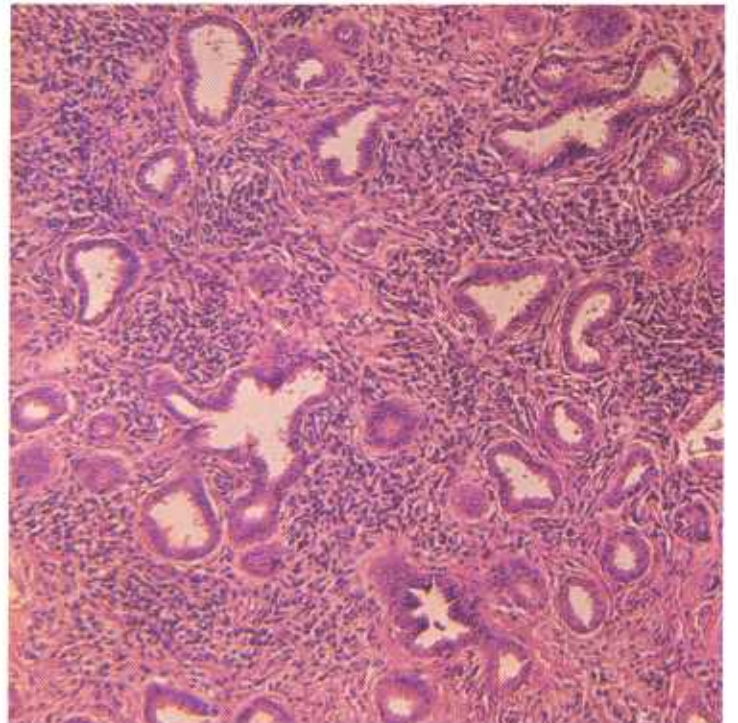


Figure 422.—A higher magnification of the lung (E8-127246) shown in figure 421. The alveolar arrangement of the hyperplastic epithelium and the interstitial chronic inflammation is readily discernible. Hematoxylin-eosin stain.  $\times 125$ .

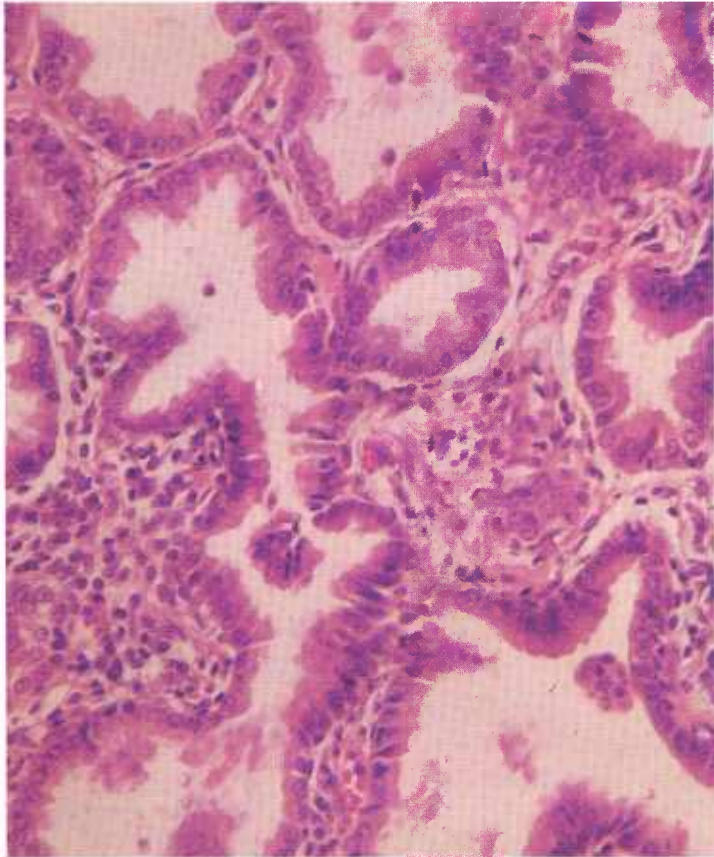


Figure 423.—A higher magnification of the lung (E8-127246) shown in figure 422. The alveolar epithelium is composed of hyperplastic columnar cells that are normochromic and that do not contain mitotic figures. Hematoxylin-eosin stain.  $\times 320$ .

pneumonia are often confused with adenomatosis. The presence of parasites, the distribution of pulmonary lesions, the ages of affected sheep, and the flock history all serve to differentiate the two diseases.

Isolated areas of pulmonary adenomatosis resemble pulmonary neoplasms. Differential diagnosis is based on several established facts: the low incidence of primary pulmonary tumors in sheep, the neoplasm's failure to effect a widespread involvement of the lung, and the neoplasm's tendency to metastasize to the regional lymph nodes and other organs—a tendency seldom observed in adenomatosis.

**Macroscopic appearance.**—Lungs of old sheep dying of adenomatosis are voluminous and do not collapse when

the thoracic cavity is opened, and they have a firm, dense, consolidated or meaty consistency. According to the stage of the disease, affected lungs are either slightly enlarged or as much as triple their normal size. Lesions in affected lungs occur as consolidated foci interspersed with areas of emphysema or as a diffuse involvement in which little unaffected pulmonary tissue can be recognized. The anteroventral part of the lungs shows the most extensive consolidation and the dorsoposterior parts are emphysematous. Consolidated areas are gray and the emphysematous parts are white. No acute active hyperemia, fibrinosuppurative inflammation, infarction, or pleuritis are present unless a complicating bacterial pneumonitis has developed. Pulmonary tissue, because of consolidation and emphysema, can be cut with ease. The cut surface protrudes slightly and contains multiple gray foci of adenomatosis measuring 1 to 5 mm. in diameter. These foci are surrounded by a narrow zone of atelectic pulmonary tissue resulting from the peripheral expansion of the lesion. The bronchi usually contain a copious mucopurulent exudate. Bronchial and mediastinal lymph nodes are enlarged, edematous, and emphysematous.

**Microscopic appearance.**—The basic pulmonary alteration consists of a proliferation of septal cells that results in the formation of a layer or layers of cells over the surface of the alveolar walls. These cell layers prevent the free exchange of gases between the lumen of the alveoli and the blood in the capillaries within the alveolar walls. As the condition progresses, hyperplasia of the intrapulmonic smooth muscle and extensive fibrosis of the lungs occur.

The cellular constituents of the exudate within the affected lung vary considerably. Early in the course of the disease the cellular exudate consists of lymphocytes, macrophages, and a few neutrophils and plasma cells. Later, after a complicating pneumonia develops, an abundance of neutrophils is found, indicating the presence of pyogenic micro-organisms.

Adenomatosis begins as focal areas of septal cell proliferation that enlarge in a peripheral direction. Pulmonary compensatory mechanisms and the restriction of the tidal air flow by exudate in the bronchi cause an over-ventilation in the pulmonary tissue between the areas of consolidation that results in distention of the alveoli (emphysema).

## Spondylitis

**Definition.**—Spondylitis is an inflammation of the vertebrae.

**Distribution and incidence.**—Spondylitis is found throughout the United States and is observed in all species of animals. It is a common cause of posterior incoordination and paralysis. Spondylitis in meat-producing animals is usually the body's response to the presence of infectious agents, although other factors (nutrition and trauma) may produce the condition. Any of the

vertebrae may be involved but the lesions are found most frequently in the lumbar vertebrae of cattle and swine and the sacral vertebrae of sheep.

The causative organisms may be carried to the vertebrae by the blood stream from primary lesions in other organs, or may localize in the vertebrae when a septicemia is present. Invasion of the vertebrae can occur by direct extension. This is especially common in the sacral region of sheep that have been docked. Bacterial

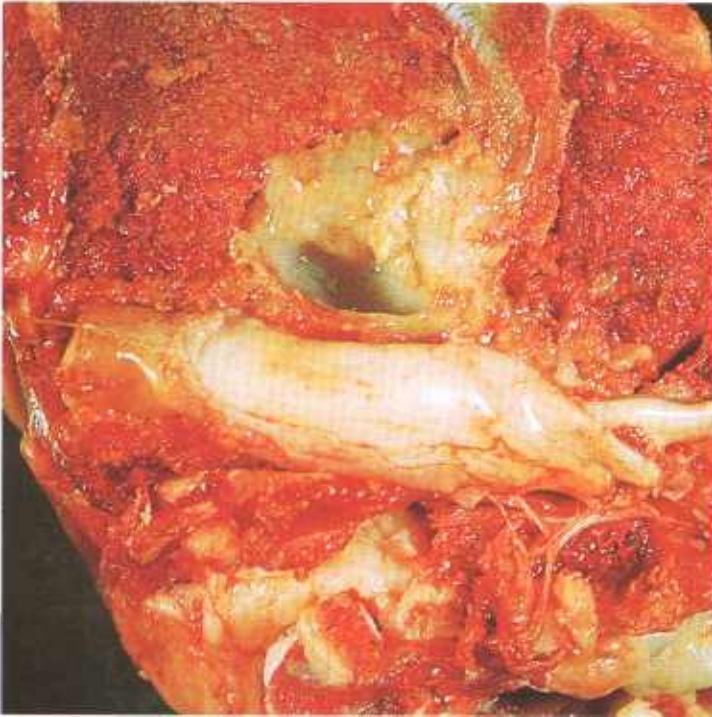


Figure 424.—Spondylitis of the lumbar vertebrae of a 2-year-old heifer (B133-130364). An abscess 5 cm. in diameter in the body of a vertebra has protruded into the vertebral canal and is compressing the spinal cord. *Spherophorus necrophorus* was isolated from the abscess.

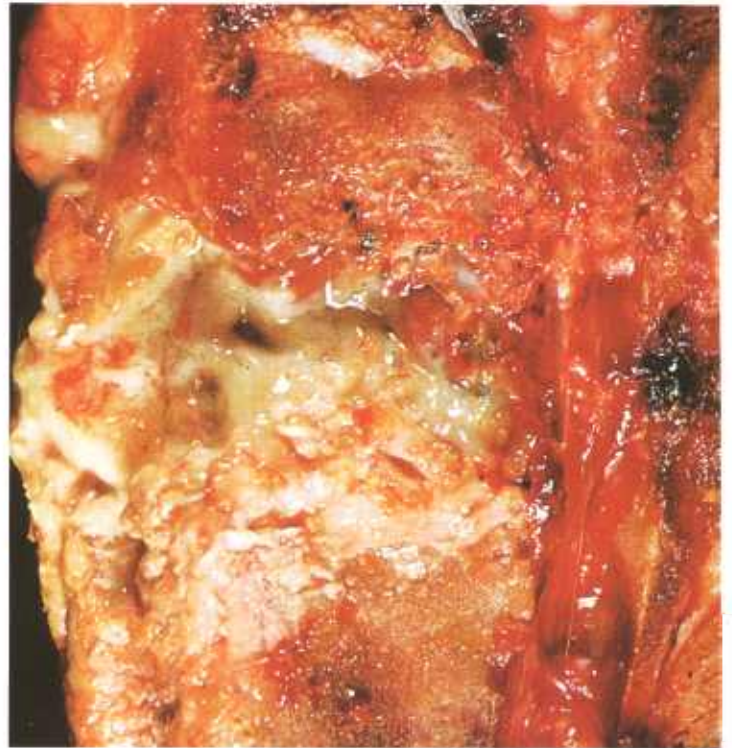

Figure 426.—Spondylitis of the 13th thoracic vertebra of a 1-year-old Hereford heifer (B92-129721). A suppurative process that contains a green viscid pus is present in the body of the vertebra. *Spherophorus necrophorus* was isolated from the exudate.

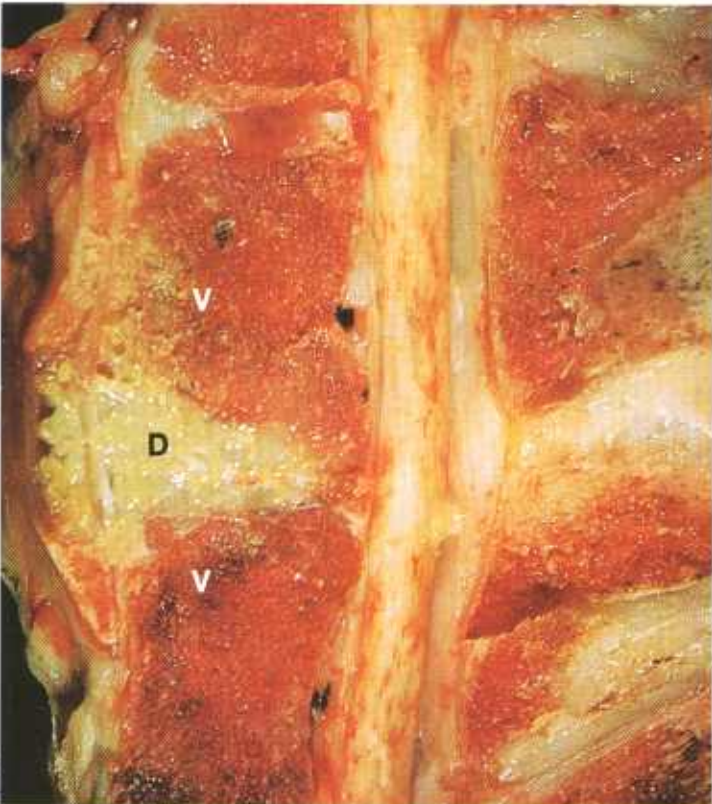


Figure 425.—Spondylitis of the lumbar vertebrae of a hog (B147-131160). The abscess, 5 by 3 by 2 cm., has invaded an intervertebral disc (D) and has extended into the two adjacent vertebrae (V). The inflammatory process has protruded into the vertebral canal and is pressing upon the spinal cord.

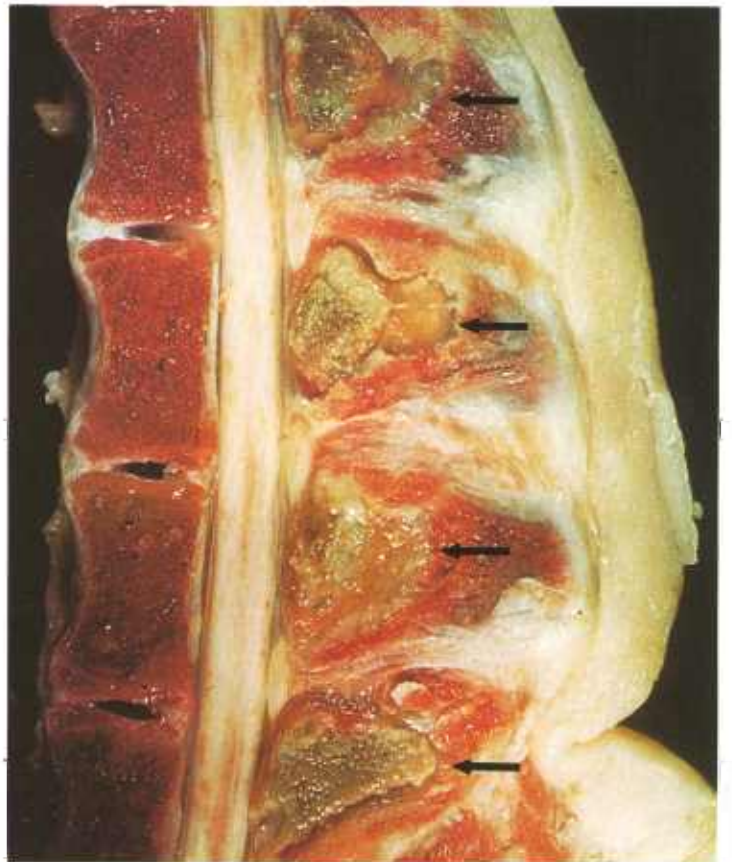


Figure 427.—Spondylitis (arrows) of the spinous processes of four lumbar vertebrae in a hog (E68-D1671). No bacteria were isolated from the purulent exudate.

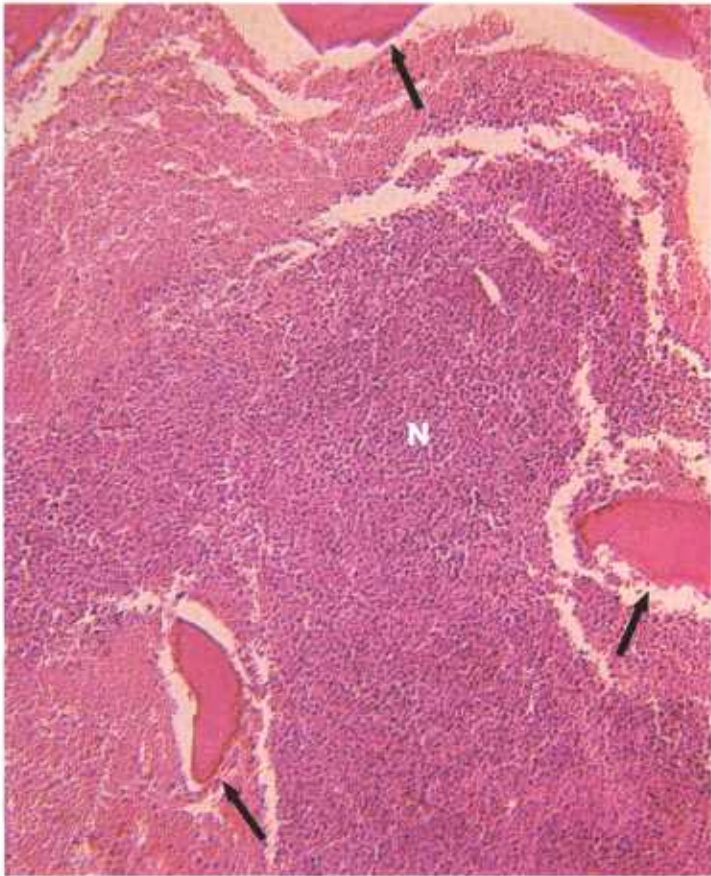


Figure 428.—A histologic preparation of the spinous process (E68-D1671) shown in figure 427. A mass of neutrophils (N) is present between the trabeculae (arrows) of the spinous process. Hematoxylin-eosin stain.  $\times 125$ .

infection of the stump of the tail frequently results in an extension of the inflammatory process into the coccygeal and sacral vertebrae.

Careful examination of the parietal lymph nodes of the abdomen of cattle often reveals a suppurative inflammation of the lumbar lymph nodes, especially those in the vicinity of the cisterna chyli. It is quite common to find a direct extension of the inflammatory process from these nodes into the adjacent bodies of the lumbar vertebrae and their intervertebral discs. Spondylitis involving the first two lumbar vertebrae is a common disease in

animals with umbilical infections, hepatic abscesses, traumatic gastritis, or other suppurative processes in the anterior portion of the abdominal viscera, since the lymphatic drainage from these tissues or organs is to the cluster of lumbar lymph nodes in the vicinity of the cisterna chyli.

Suppurative inflammation of vertebrae, especially those that involve the bodies of vertebrae, may cause the osseous structures to become so fragile that a compression fracture of the vertebrae occurs, resulting in injury to the spinal cord and spinal nerves. At times there is an extension of the inflammatory process into the vertebral canal, meninges, and spinal cord.

Bacteriologic examination of the suppurative lesions found in the spinal columns of slaughtered animals reveals a wide variety of organisms common to suppurative processes in domesticated animals. *Corynebacterium pyogenes* is most frequently isolated from spondylitis in sheep; *C. pyogenes*, *Spherophorus necrophorus*, and *Actinobacillus lignieresii* in cattle; and *C. pyogenes*, *Brucella suis*, and *Streptococcus pyogenes* in swine.

**Macroscopic appearance.**—Although nonsuppurative spondylitis caused by mechanical and nutritional diseases does occur, the spondylitis most frequently observed by meat inspectors is suppurative. The lesion consists of an abscess or a diffuse suppurative inflammation of one or more vertebrae. Although all parts of affected vertebrae may be involved, spondylitis usually affects the bodies of the vertebrae. The spondylitis begins as an acute suppurative reaction, but by the time the lesion is observed at slaughter, the reaction is usually chronic suppurative. The exudate is white, yellow, or green, and creamy, tenacious, or granular. The osseous structures in the area of inflammation are partially or completely destroyed and the space formerly occupied by them is filled with exudate.

**Microscopic appearance.**—The microscopic alterations are those of an acute or chronic suppurative inflammation. The type of alteration produced depends upon the species of micro-organism and the animal host involved. The neutrophil is the predominating cell of the exudate. In the more chronic infections, many macrophages and giant cells may be present, and extensive infiltrations with fibroblasts may occur.

## Steatitis (“Yellow Fat” Disease) in Swine

**Definition.**—Steatitis (“yellow fat” disease) in swine is a yellow pigmentation of adipose tissue associated with the use of fish products and flaxseed as feed.

**Distribution and incidence.**—Steatitis usually occurs near fisheries where cannery wastes are fed to swine. The disease is also found on fur ranches where the remains of mink feed containing fish products are consumed by pigs. The use of feed containing other substances possessing highly unsaturated fatty acids, such as flaxseed, will also produce the disease.

Feeding swine rations containing excessive amounts

of highly unsaturated fatty acids and inadequate quantities of tocopherols causes porcine adipose tissue to contain a yellow, acid-fast pigment. The pigment consists of fat soluble and fat insoluble fractions and the latter possesses acid-fast staining characteristics. Fat cells can incorporate and stabilize unsaturated fatty acids as “storage fat” if vitamin E, an antioxidant, is added to a ration rich in unsaturated fatty acids.

The fat of affected swine has an odor of fish that can be accentuated by heating the tissue. Swine having steatitis tend to be thin and in poor physical condition.

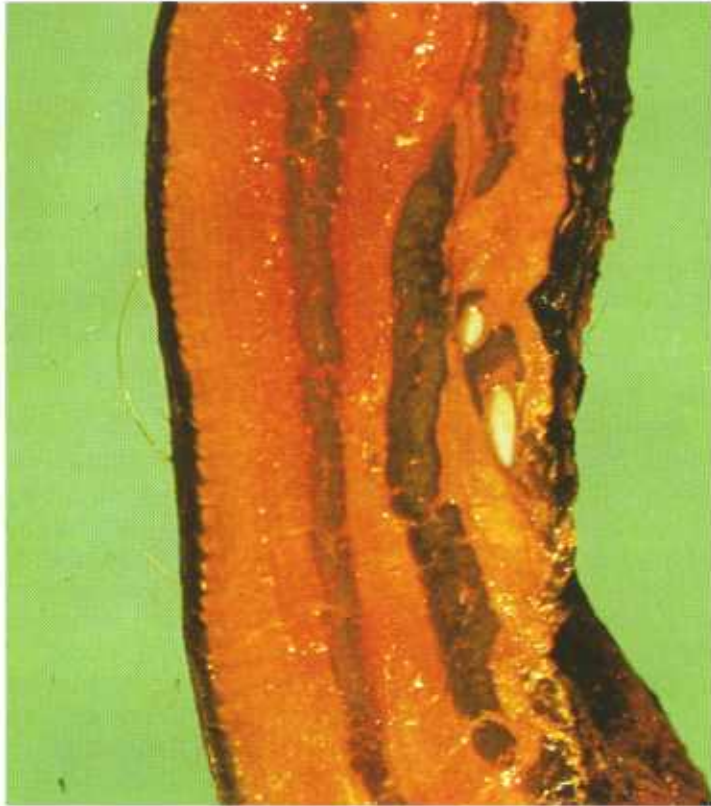

Figure 429.—Cross section of the lateral body wall of a hog. Note the orange-yellow color of the affected fat. Formalin preservation has intensified the color. Specimen—courtesy of G. R. Spencer (M626).

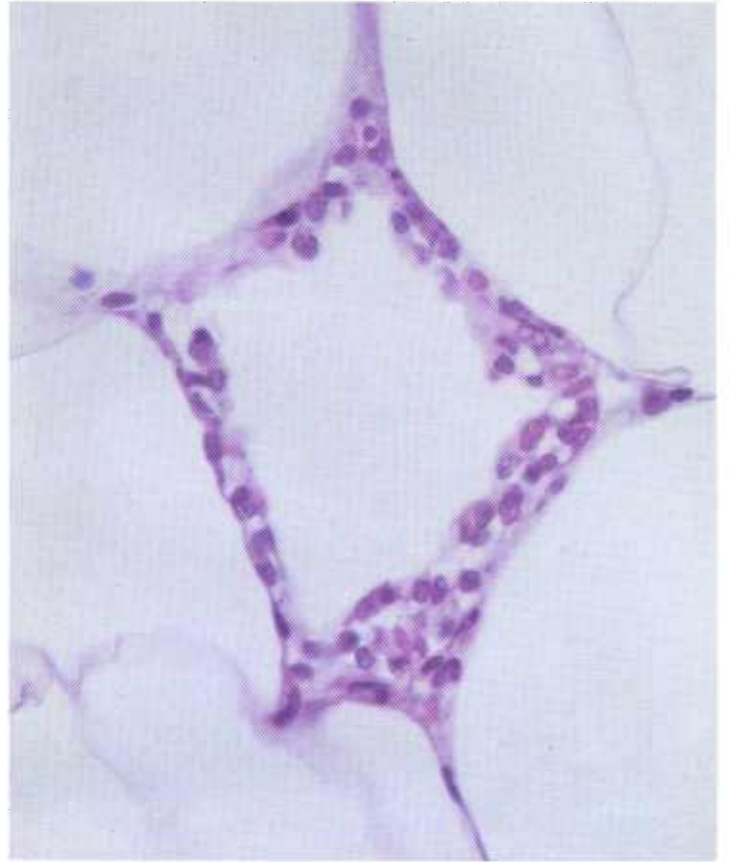


Figure 431.—A higher magnification of the lesion (62-1422-T7) shown in figure 430. Hematoxylin-eosin stain.  $\times 500$ .

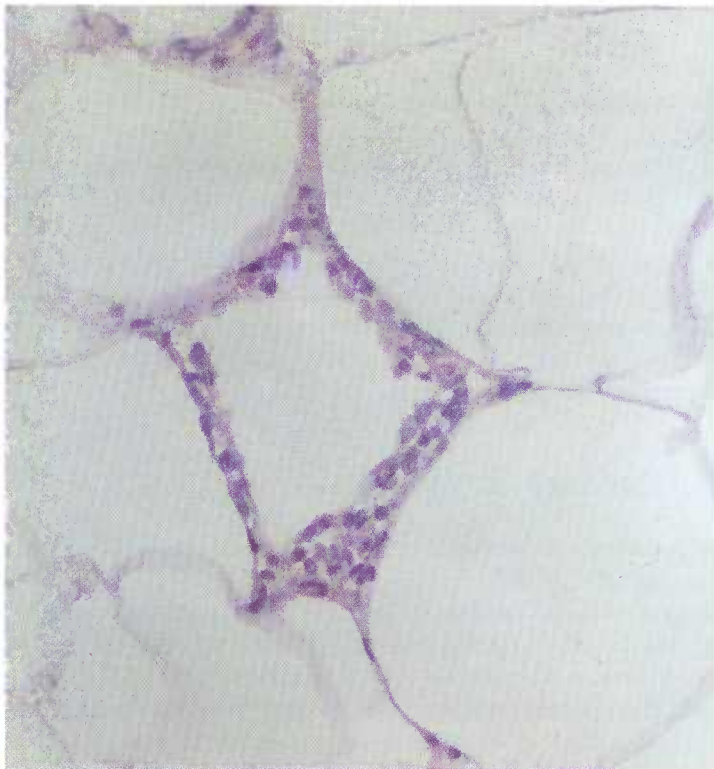


Figure 430.—A focus of inflammation located between adipose cells. The inflammatory exudate is composed of macrophages. Specimen—courtesy of G. R. Spencer (62-1422-T7). Hematoxylin-eosin stain.  $\times 320$ .

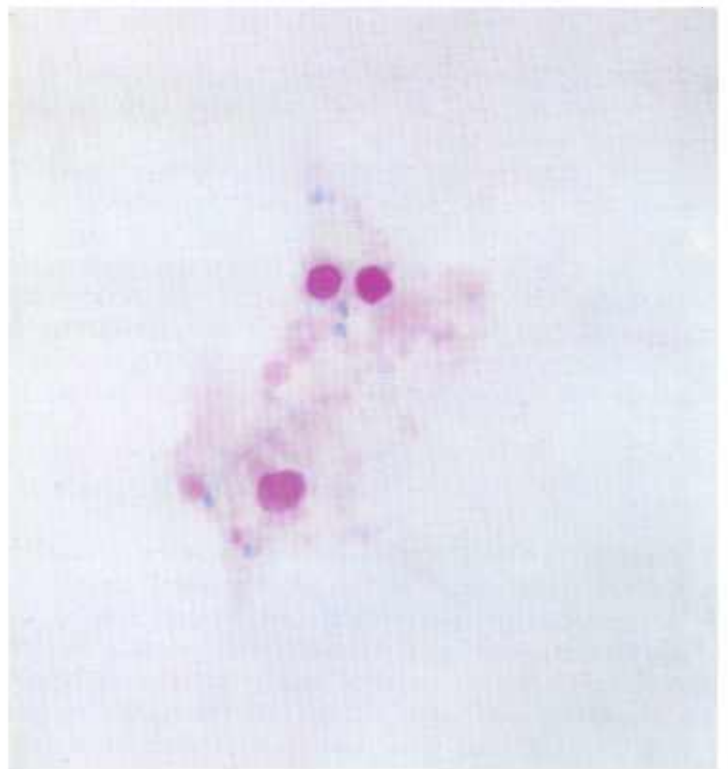


Figure 432.—Foreign fat globules that stain pink or red with an acid-fast stain are present in the interstices of the adipose tissue. Specimen—courtesy of G. R. Spencer (62-1723-T2) Ziehl-Neelsen acid-fast staining technique.  $\times 500$ .

**Macroscopic appearance.**—Subcutaneous and mesenteric fat, in particular, show the alterations characteristic of this dietary disease. Affected fat is slightly opaque and firmer than normal and varies from bright yellow to yellowish brown.

**Microscopic appearance.**—Foreign fat globules, some of which contain an acid-fast pigment, are deposited in the interstices of the adipose tissue. This deposition appears as fine droplets or, quite frequently, as larger discrete globules in groups or islets of variable size. At times the globules have a pericapillary and periarteriole location. Adipose tissue cells themselves are usually not affected. Occasionally, foreign fat globules are seen within adipose cells and their presence is interpreted to represent a permeation into the normal storage fat rather than a disturbed metabolic process. Foci of inflammation

composed of collections of macrophages, neutrophils, eosinophils, and an occasional foreign-body giant cell may be present between the adipose cells. These macrophages and giant cells contain droplets of yellow fat. This inflammatory reaction is the basis for applying the name “steatitis” to the condition. Fat necrosis and fibrosis are not present in the affected fat.

Histochemical staining techniques indicate the yellow pigment does not contain iron. The fat globules are pink or red when stained with the Ziehl-Neelsen acid-fast staining technique. Acid-fast pigment is present in the Kupffer cells of the liver. These pigment-laden cells are most numerous in the vicinity of the central veins. The cytoplasm of nearly all of the liver cells contain many small, intensely staining acid-fast droplets.

### Swine Abscesses

**Definition.**—Swine abscesses are focal suppurative inflammations in tissues (usually lymph nodes) that are most commonly caused by Lancefield group E streptococci.

**Distribution and incidence.**—Abscesses in swine are found throughout the United States but are most frequently observed in concentrated swine-raising areas of the Midwest. All breeds, sexes, and ages are involved. As many as 75 percent or more of the pigs on some farms are affected. Abscesses are one of the most important causes of swine condemnations in meat inspection. From 6 to 17 percent of the swine slaughtered at various abattoirs under Federal meat inspection have abscesses that

require condemnations of parts of the carcass or of the entire pig.

Experimental exposures with culture material indicate that ingestion of Lancefield group E streptococci will consistently produce the disease, an indication that the oral route may be the principal method of natural infection. Some abscesses are probably the result of wound infections or exposure by channels other than the oral route. Intravenous exposure does not result in the formation of abscesses.

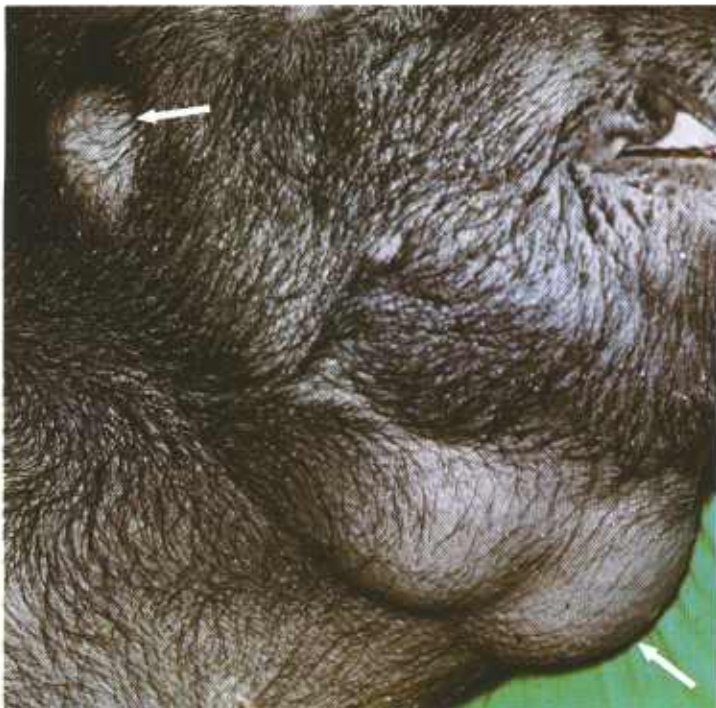

Figure 433.—Streptococcic abscesses (arrows) that involve the mandibular and parotid lymph nodes of a hog (M768).

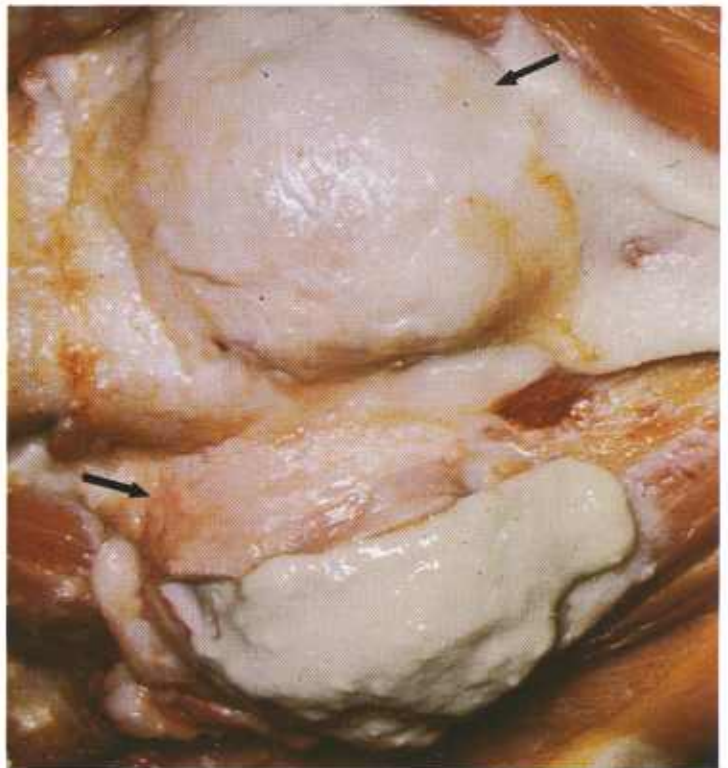


Figure 434.—Streptococcic abscesses (arrows) in the mandibular lymph nodes (M768) shown in figure 433. One of the lymph nodes has been incised. Note the creamy, pale-green pus that is exuding through the incision.

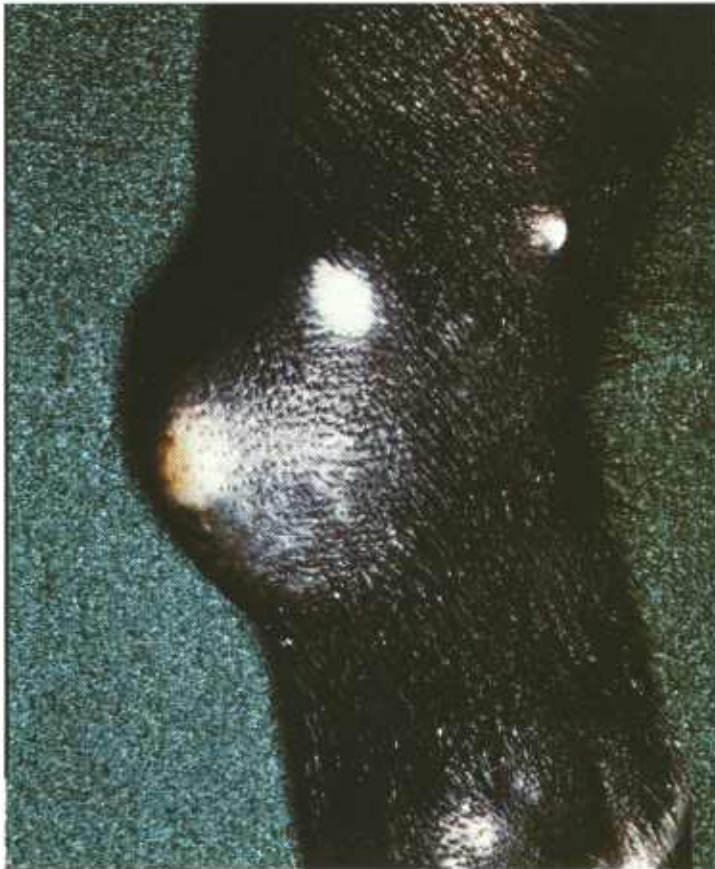

Figure 435.—Streptococcal arthritis and peri-arthritis in a hog (M769).

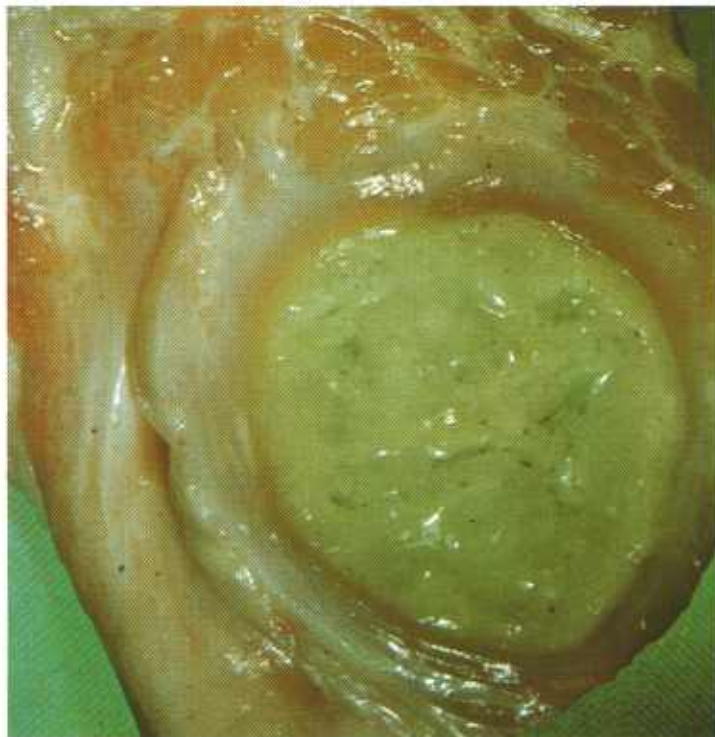


Figure 436.—A streptococcal abscess in the jowl of a hog (B33-128167). The abscess consists of a mass of green pus enclosed by a chronic inflammatory tissue capsule.

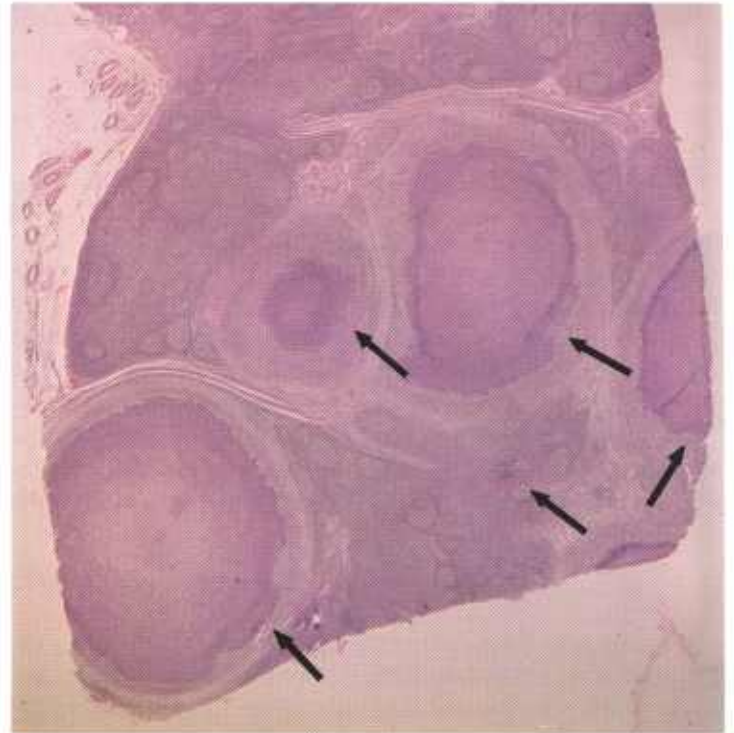


Figure 437.—Streptococcal abscesses in a lymph node of a 1-year-old boar (D2299). Each abscess (arrows) consists of a central mass of liquefactive necrosis (pus) surrounded by a chronic inflammatory tissue capsule. Hematoxylin-eosin stain,  $\times 11$ .

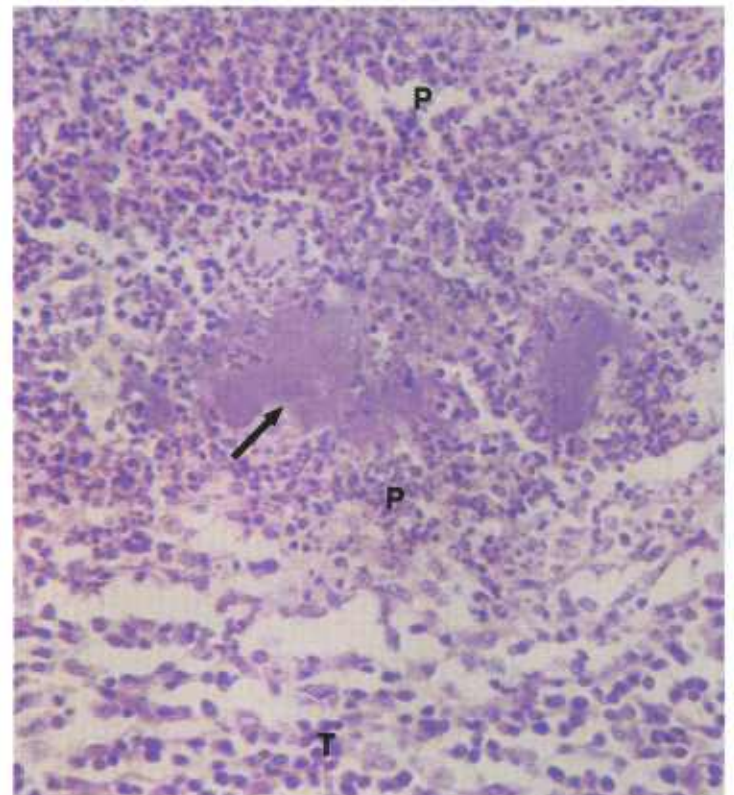


Figure 438.—A higher magnification of the abscess (D2299) shown in figure 437. Colonies of bacteria (arrow) are present in the pus (P) adjacent to the capsule of chronic inflammatory tissue (T). Hematoxylin-eosin stain,  $\times 320$ .

It is believed that after oral exposure, streptococci enter the body through the tonsils and that organisms are carried, probably within macrophages, to the mandibular, parotid, and suprathyroid lymph nodes. There, abscesses are produced. The invading streptococci may be confined to these nodes or they may continue to invade and may produce a septicemia that can cause death of the pig or abscesses in other lymph nodes and organs. A few pigs die with a streptococci septicemia before macroscopic abscesses appear in the lymph nodes.

**Macroscopic appearance.**—When streptococci invade a lymph node, an acute focal lymphadenitis appears in the vicinity of the organisms. The area of inflammation soon develops into an abscess that gradually enlarges until the entire node may be involved. A typical abscess is a mass of pale-green, thick or thin, creamy pus enclosed in a connective tissue capsule. The contents of the abscess may be under considerable pressure and may gush forth, contaminating the carcass when the lesion is incised. Thus, the abscesses cause concern to meat inspectors and butchers, for if the abscess is not recognized, incision may proceed before precautionary measures to prevent carcass contamination have been initiated. Some abscesses, especially those involving

lymph nodes of the jaw, rupture through the skin to the exterior. Exudate from these abscesses is discharged onto the ground, feed, water, and equipment in the environment. Swine coming in contact with this exudate are exposed to the streptococci and may become infected. The method of spread of the disease in herds where draining abscesses do not exist has not been determined.

**Microscopic appearance.**—When bacteria first enter the tissue, an intense acute focal inflammatory reaction occurs with an infiltration of neutrophils in the vicinity of the organisms. After a period of about 8 days, the acute inflammatory reaction subsides and the tissue response becomes first subacute and later chronic. As the reaction becomes chronic, macrophages, lymphocytes, fibroblasts, and capillaries appear in the periphery of the exudate and produce a zone of granulation tissue around the pus. The mass of exudate is eventually enclosed in a dense connective tissue capsule. Neutrophils in the exudate, except those close to the capsule, gradually lose their morphologic identity, become necrotic, and are converted into a homogeneous mass that stains pink with eosin. The necrotic exudate is seldom calcified. Masses of bacteria can be demonstrated in the exudate when it is stained with the Gram stain.

## Traumatic Fat Necrosis

**Definition.**—Traumatic fat necrosis is the death of adipose tissue in an area of mechanical injury.

**Distribution and incidence.**—Traumatic fat necrosis is found in animals throughout the United States. It is a very common alteration in subcutaneous adipose tissue caused by the mechanical injuries received while animals work, fight, or exercise. This alteration in fat is frequently observed in the back fat of swine and is, in some instances, caused by the injury to the subcutaneous fat by the skin lesions of erysipelas. The perivaginal fat in the bovine, especially in fat Herefords, very commonly undergoes necrosis as the result of mechanical injury during parturition. Herniation of perivaginal fat into the lumen of the vagina is common in fat cattle, especially following parturition, when the fat is forced into the lumen of the vagina through defects or tears in the vaginal wall. As the vagina contracts after parturition, the restriction of the blood supply by the vaginal wall causes ischemia and infarction of the herniated fat.

**Macroscopic appearance.**—The necrotic fat appears as a firm, opaque, chalky mass in the area of injury. The irritating action of the altered fat causes an acute or chronic inflammation. Because of the accumulation of exudate in the area, fat necrosis is often mistaken for an abscess or wound infection. When the area is incised, it may contain a yellow or white oily exudate or it may have little exudate but large amounts of connective tissue resulting from the chronic inflammation. If a wound is present, exudate may flow from the site of the necrotic

tissue to the exterior. Healing is very slow and is not complete until all of the necrotic fat has been removed.

Fat liberated from the necrotic cells is carried to the regional lymph nodes where it accumulates as droplets in the cortical and peritrabecular sinuses. Since free oil is irritating to body tissues, a chronic lymphadenitis occurs. The nodes become enlarged and fibrotic. When

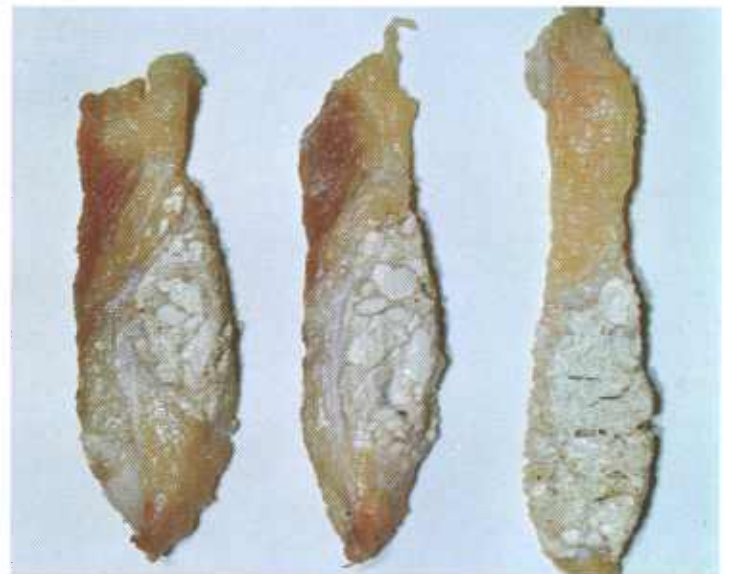


Figure 439.—Traumatic fat necrosis in the stifle region of a bovine animal (DWB 111). The white necrotic fat is partially mineralized.

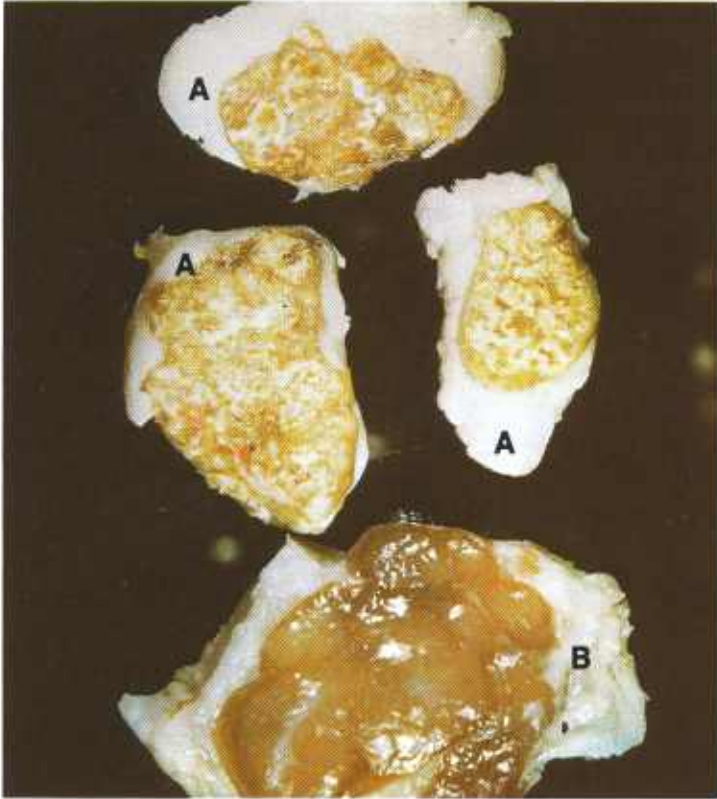

Figure 440.—Infiltration of lymph nodes with fat from an area of fat necrosis in a hog (E106-D1984). The white, irregularly shaped streaks in the affected lymph nodes (A) are masses of fat droplets in the sinuses. The unaffected node (B) can be used for comparison.

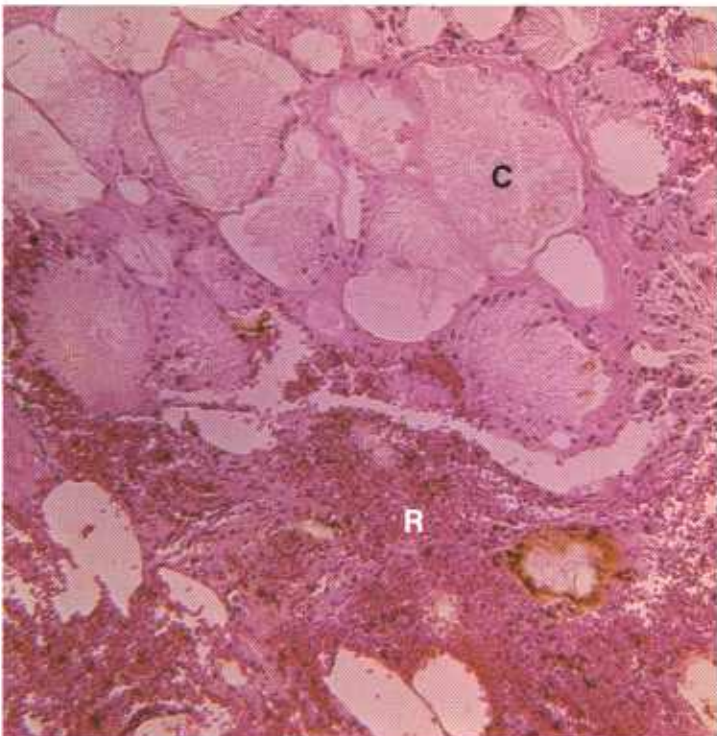


Figure 441.—Traumatic fat necrosis in the mesentery of a cow (P123). The necrotic fat cells (C) contain a granular material that stains pink with eosin. An inflammatory reaction (R) with considerable hemorrhage is present adjacent to the necrotic fat. Hematoxylin-eosin stain.  $\times 125$ .

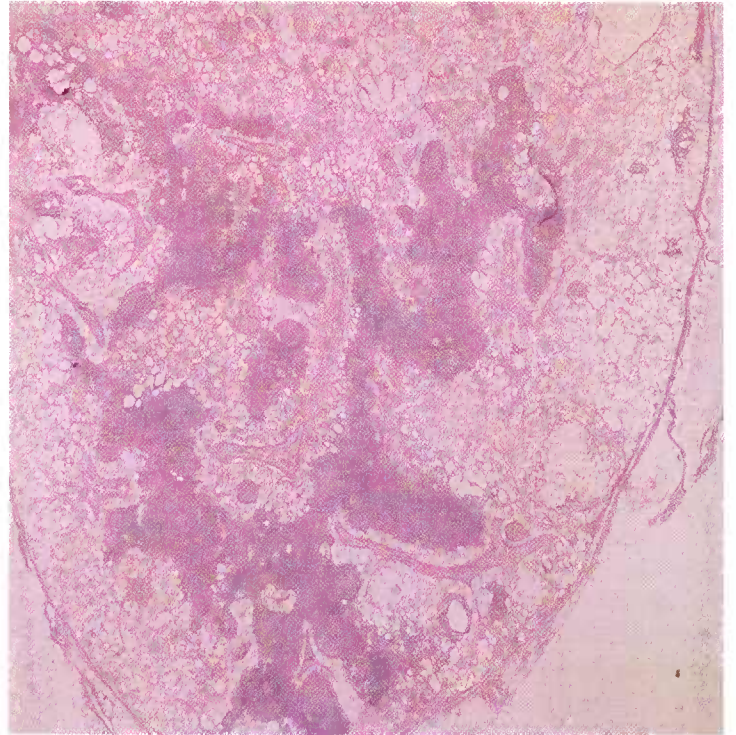


Figure 442.—Infiltration of a lymph node with fat from an area of fat necrosis in an 8-month-old barrow (D2301). The sinuses of the lymph node are filled with fat. Hematoxylin-eosin stain.  $\times 10$ .

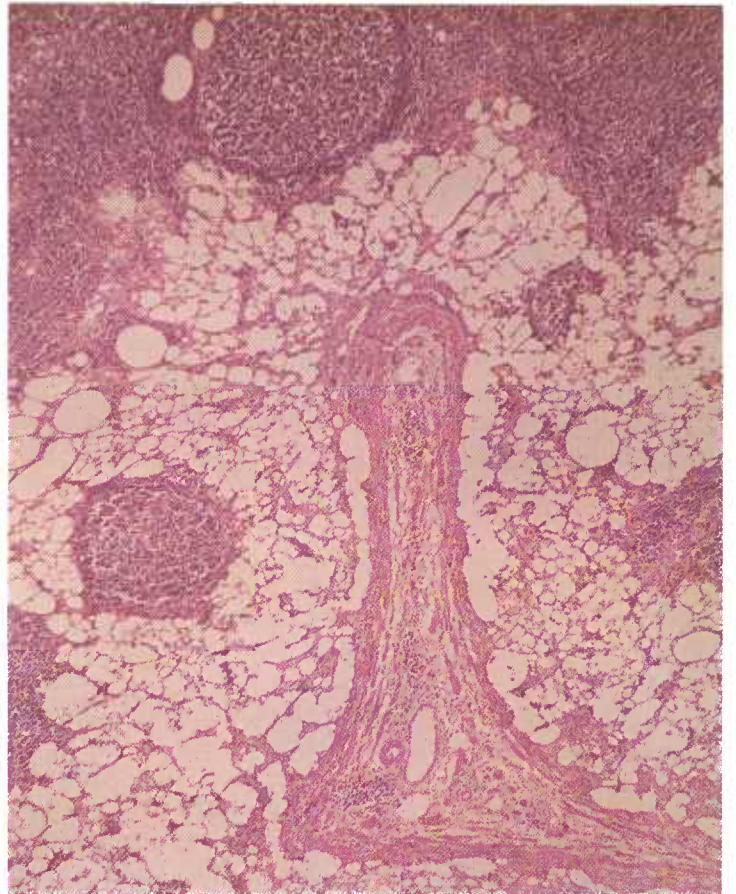


Figure 443.—A higher magnification of the lymph node (D2301) shown in figure 442. The peritubercular sinuses are filled with fat droplets. Hematoxylin-eosin stain.  $\times 50$ .

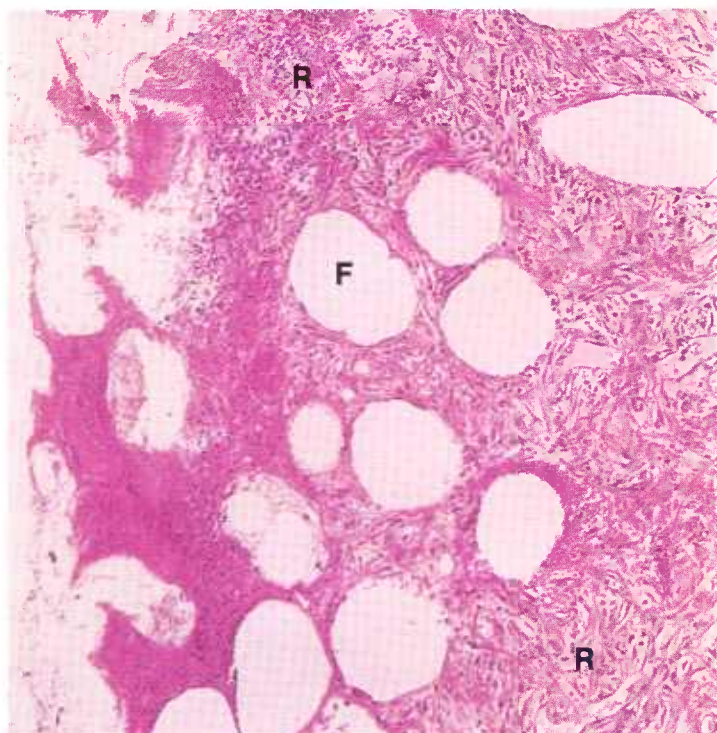


Figure 444.—Traumatic fat necrosis of perivaginal fat that has herniated into the lumen of the vagina of a cow (P163). The necrotic fat has elicited a persisting chronic inflammatory reaction (R) that encloses spaces (F) from which fat was removed during preparation of the histologic specimen. Hematoxylin-eosin stain.  $\times 125$ .

incised, droplets of oil may flow from their cut surfaces and cavities may persist in the sinusoidal region of the nodes where the oil was located.

**Microscopic appearance.**—In the chemical breakdown of fat, glycerol and fatty acids are formed. Fatty acids are not readily soluble in the fat solvents used in histology. As a result, the pale pink (hematoxylin and eosin stain), slightly granular material observed in the adipose cells has numerous clefts and crystals. The clefts are the site of fatty acid crystals (cholesterol) which, being more soluble in histological reagents than other fatty acids, have been removed during the preparation of the specimen.

Fat from ruptured adipose cells is liberated in the area of injury. Free fat is very irritating to tissue and causes fibrosis and the accumulation of macrophages, giant cells, and eosinophils. The droplets of fat and the necrotic tissue are phagocytosed and removed by the macrophages. If there is an open wound, bacteria may enter the necrotic tissue and produce a suppurative or gangrenous inflammation.

The sinuses of the regional lymph nodes become distended with droplets of oil that cause a chronic lymphadenitis. Macrophages and giant cells, actively engaged in phagocytosing the oil, are numerous. Many eosinophils are also present. As the result of the chronic inflammation, hyperplasia of connective tissue and atrophy of the lymphoid elements occur.

## Viral Diarrhea of Cattle

**Definition.**—Viral diarrhea of cattle is an acute infectious viral disease characterized by multiple ulcers in mucous membranes.

**Distribution and incidence.**—Bovine viral diarrhea, also known as Indiana viral diarrhea and mucosal disease, is extremely prevalent throughout the United States, is very infectious, and spreads rapidly through affected herds. Most cattle are so slightly affected that the disease is not clinically recognized.

Abortion may follow the acute attack. When relatively mild outbreaks of the disease occur in a herd, the association of the viral diarrhea with the wave of abortions is often overlooked, and considerable effort is made to demonstrate vibriosis, brucellosis, or leptospirosis as causative agents when actually the basic disease is viral diarrhea.

The morbidity is usually from 33 to 88 percent, and the mortality is generally low, ranging from 4 to 8 percent. In a few herds a larger death loss may occur.

**Macroscopic appearance.**—Affected animals show anorexia, depression, and a very severe diarrhea. Cattle that are still apparently normal in an affected herd may have temperatures of 105 to 108 degrees F. When the diarrhea appears the temperature usually drops to normal or near normal. Shortly after the very severe diarrhea appears, multiple ulcers are observed in the mouth, along the gum line, on the muzzle, and in the region of

the external nares. A mucous or mucopurulent rhinitis is present, and an abundance of exudate may cover the muzzle. In some animals there is rather profuse salivation. A serous, mucous, or mucopurulent conjunctivitis is present, and considerable exudate is encrusted on the hair below the eyes.

Usually the cadaver is dehydrated and emaciated. An acute catarrhal inflammation is present throughout the gastrointestinal tract. Multiple ulcers with sharp borders (punched-out appearance) are found in the epithelium of the muzzle, external nares, tongue, dental pad, palate, gum line, esophagus (especially in the posterior 12 inches), and forestomachs (particularly in the pillars of the rumen). Multiple and rather shallow ulcers are found in the abomasum, and ulceration also occurs in the Peyer's patches and lymph follicles throughout the large and small intestine. The inflammation is most severe in the terminal 6 feet of the small intestine, where diffuse necrosis of the entire mucous membrane may be present. In some animals the necrosis also involves the cecum and colon. One characteristic of the disease is the abundance of mucus in the intestinal tract, especially noticeable in the region of the Peyer's patches.

**Microscopic appearance.**—The basic alteration is a catarrhal, suppurative, or ulcerative inflammation of all mucous membranes. The viral agent is particularly in-

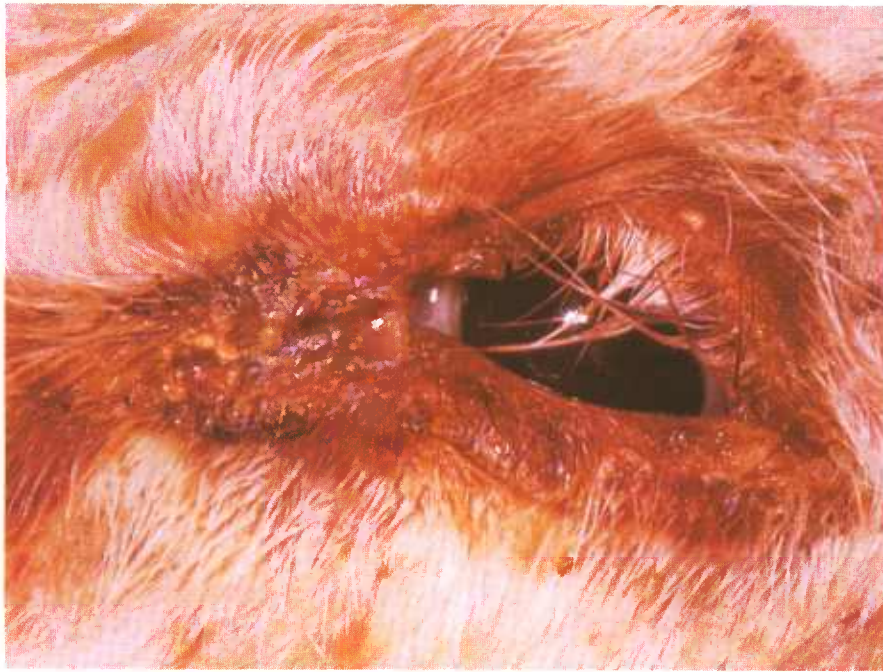

Figure 445.—Accumulation of a mucopurulent exudate around the eye of a bovine animal affected with viral diarrhea (M193).

jurious to lymphoid tissues. Necrosis of lymphocytes within Peyer's patches, lymph follicles, and lymph nodes is quite prominent throughout the animal affected with bovine viral diarrhea. As a result, there is a noticeable suppression of lymphocyte regeneration in the affected animal. One of the characteristics of this disease is a leukopenia with leukocytes ranging from 450 to 3,100

cells per cubic millimeter.

Lymphoid tissue suppression occurs not only in cattle affected with viral diarrhea, but also, to varying degrees, in cattle that have been vaccinated with viral diarrhea vaccines. This suppression results in a failure of the immune response that may cause cattle to succumb to other diseases.

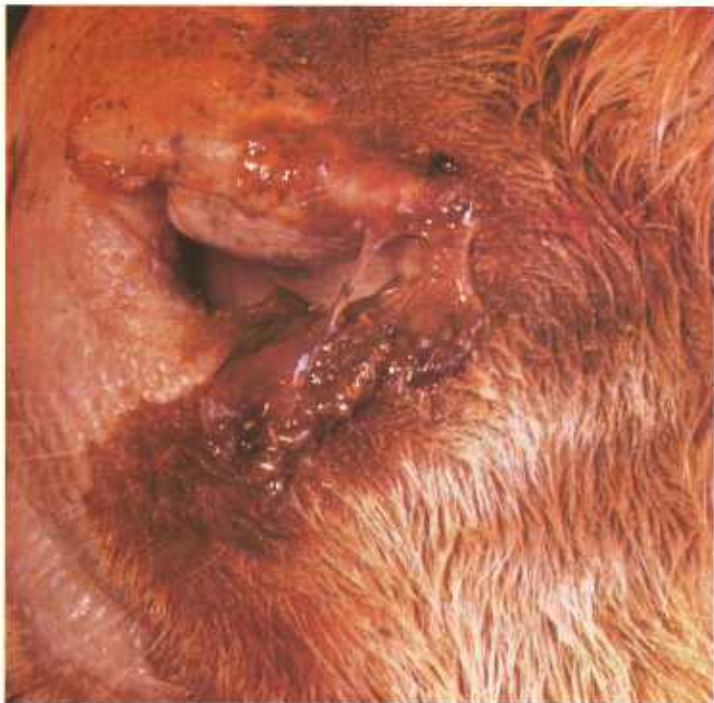

Figure 446.—Accumulation of a mucopurulent exudate around the nostrils of a bovine animal affected with viral diarrhea (M194).

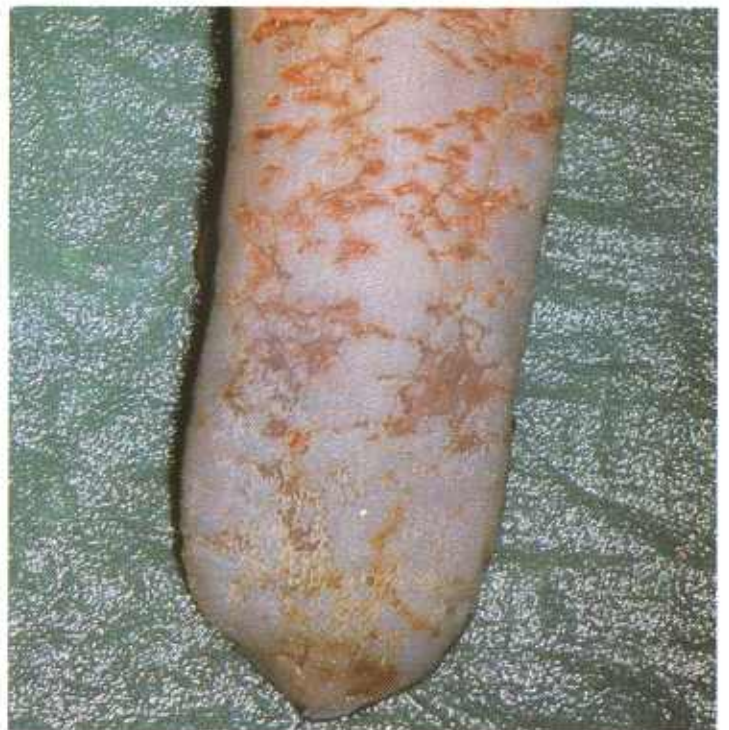

Figure 447.—Multiple ulcers in the tongue of a bovine animal affected with viral diarrhea (M31).

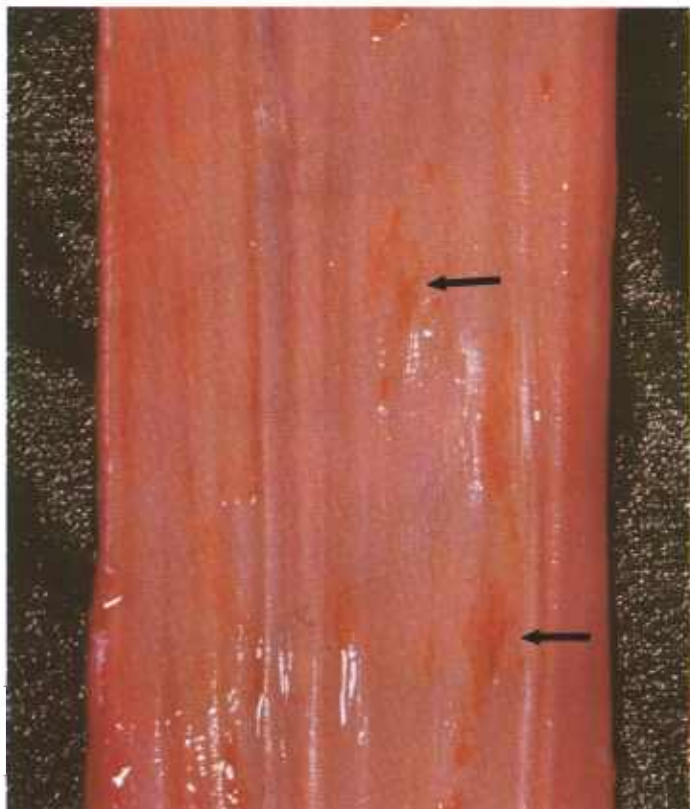


Figure 448.—Multiple ulcers (arrows) in the esophagus of a bovine animal affected with viral diarrhea (M192).

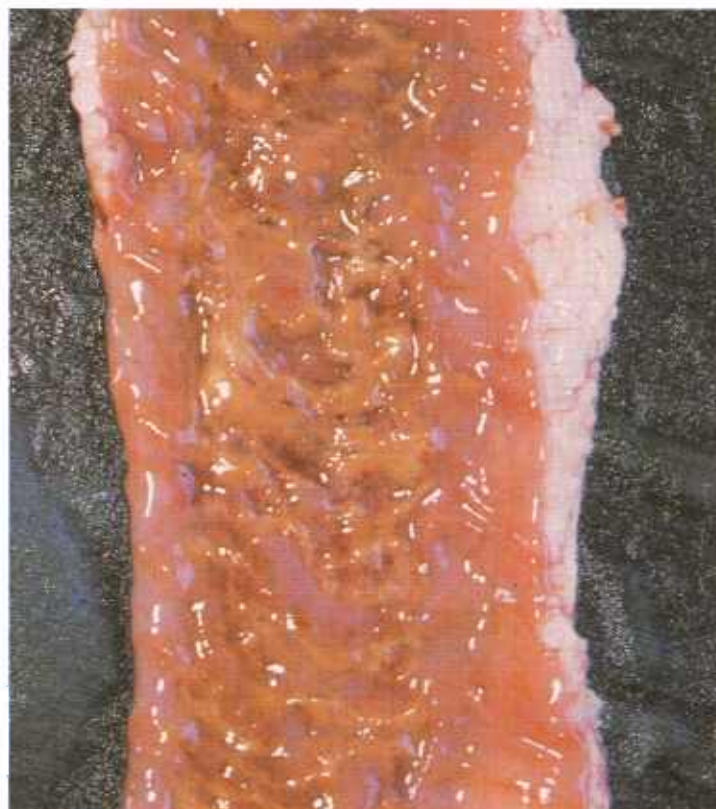


Figure 450.—Fibrinous enteritis in a bovine animal affected with viral diarrhea (M181).

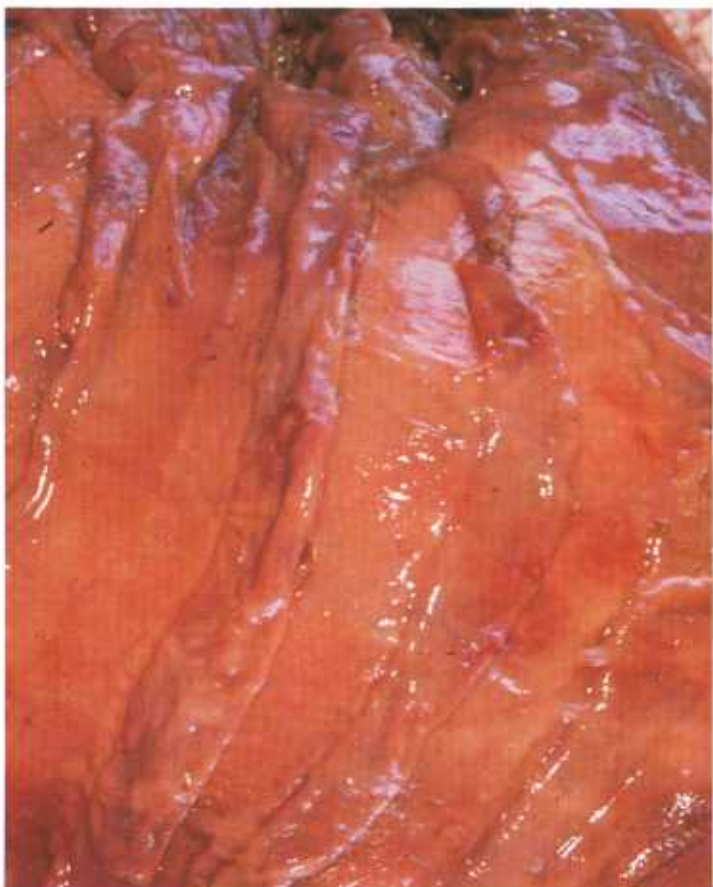

Figure 449.—Multiple ulcers in the abomasum of a bovine animal affected with viral diarrhea (M182).

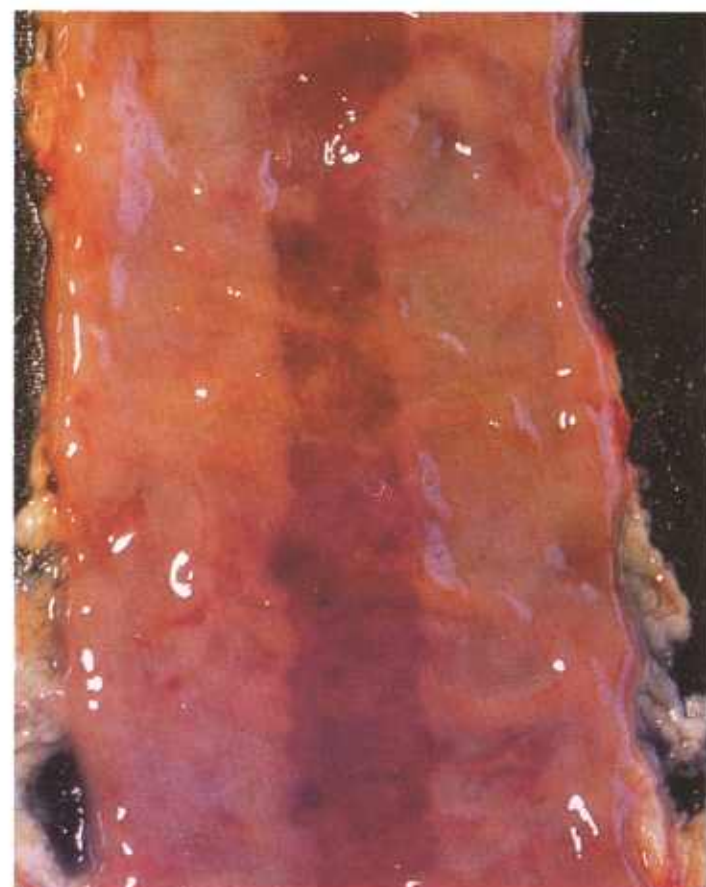


Figure 451.—Ulcerative enteritis involving a Peyer's patch in a bovine animal affected with viral diarrhea (M191).



## MISCELLANEOUS LESIONS OF INTEREST IN MEAT INSPECTION PATHOLOGY

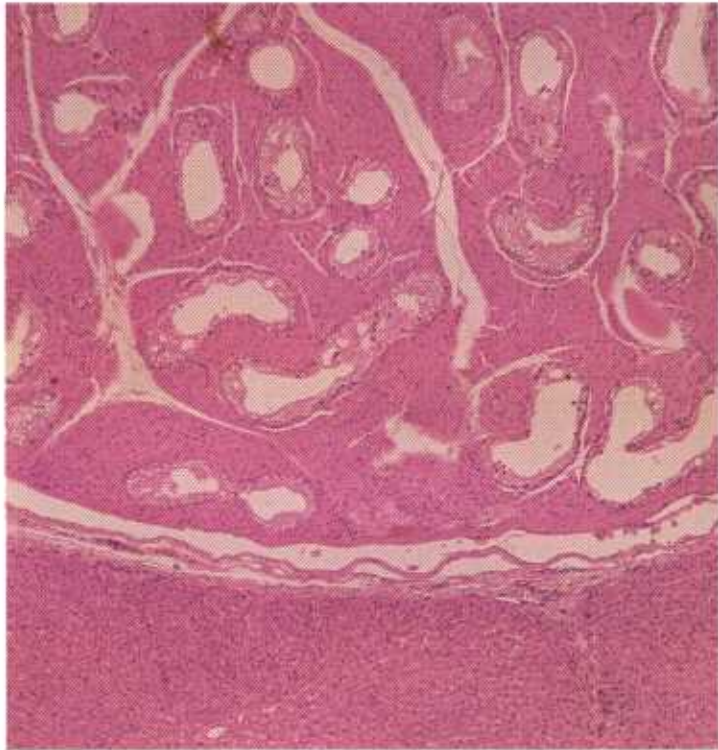


Figure 452.—A histologic preparation of aberrant gonadal tissue attached to the surface of the liver of a 1-year-old barrow (D2745). The tissue consists of interstitial cells and seminiferous tubules. This type of lesion usually occurs as multiple light-brown nodules attached to the peritoneal surfaces of the abdominal organs. Hematoxylin-eosin stain.  $\times 50$ .

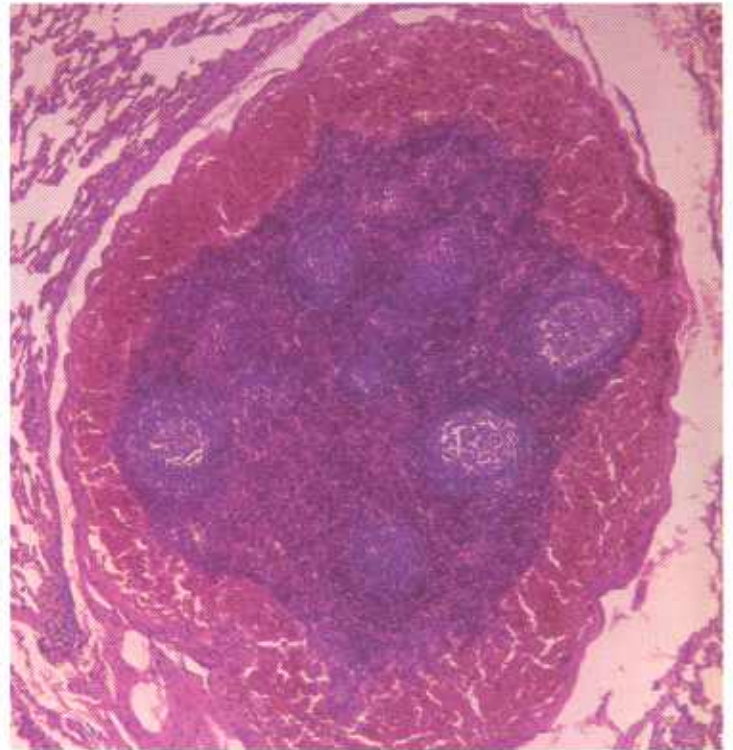


Figure 453.—A histologic preparation of a hemolymph node in the lung of a 2-year-old steer (D1720). Multiple red, blood-filled nodules, 1 to 10 mm. in diameter, are scattered throughout the parenchyma of the lung. The identity of the lesion is usually quite confusing until histologic examinations have been completed. Hematoxylin-eosin stain.  $\times 50$ .

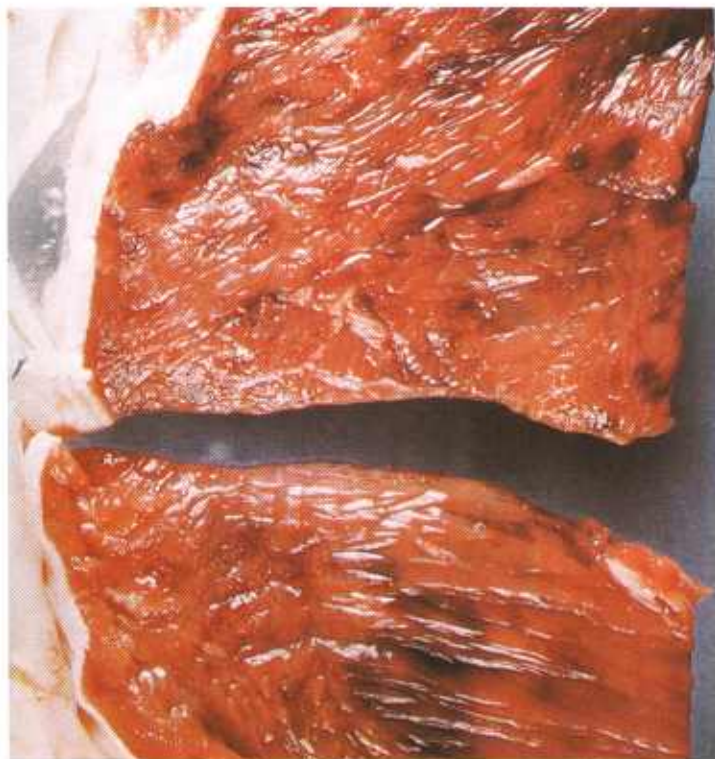

Figure 454.—Hemorrhage in the skeletal muscle of a 2-year-old steer (E215-D3422). Hemorrhages in muscle tissue occur when fat beef cattle with coagulative necrosis of the muscle are slaughtered. The violent muscle contractions at the time of slaughter cause the necrotic muscle to rupture. Hemorrhage occurs at the site of muscle rupture.

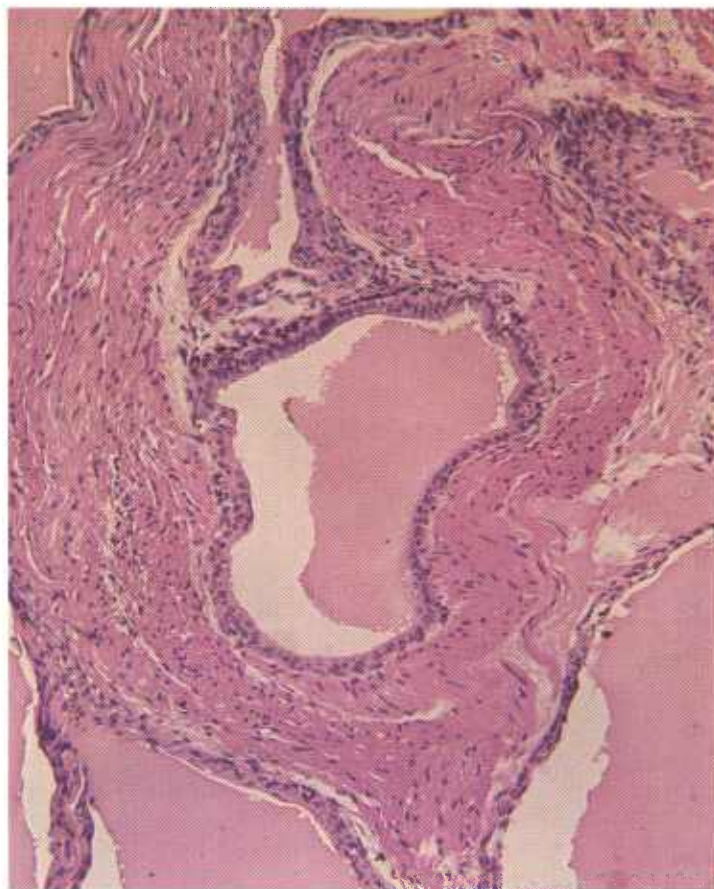
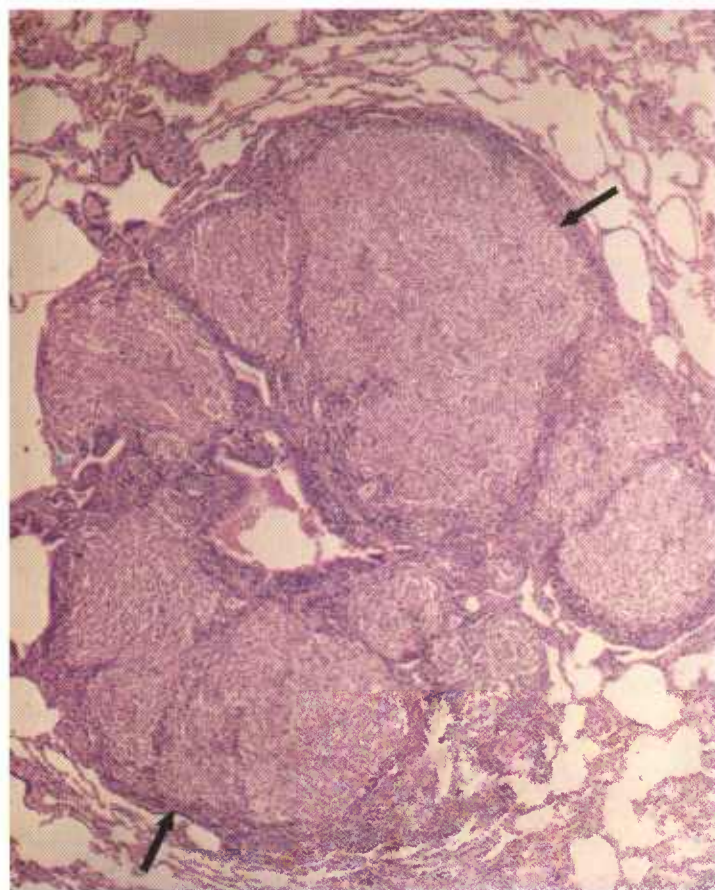


Figure 456.—Cysts in the abdomen of an old ewe (D3179). Cysts, especially in the paraovarian tissues, are common in all meat-producing animals. The cysts are lined with epithelium and contain a secretion that varies in the intensity with which it stains with eosin. Cysts in the ovarian region contain pseudomucin and stain intensely with eosin. Hematoxylin-eosin stain.  $\times 125$ .

Figure 455.—Oil granuloma of the lung in an 8-year-old cow (D1351). A focus (arrows) of chronic inflammation composed mainly of macrophages is present in the pulmonary parenchyma. At a higher magnification oil droplets can be seen within the macrophages. Such lesions are common in the lungs of animals that have inhaled oily medicaments administered to them orally. The oil causes a chronic inflammatory reaction in the lungs. The lesions are usually located in the anteroventral part of the lung and have a peribronchial arrangement. Hematoxylin-eosin stain.  $\times 50$ .

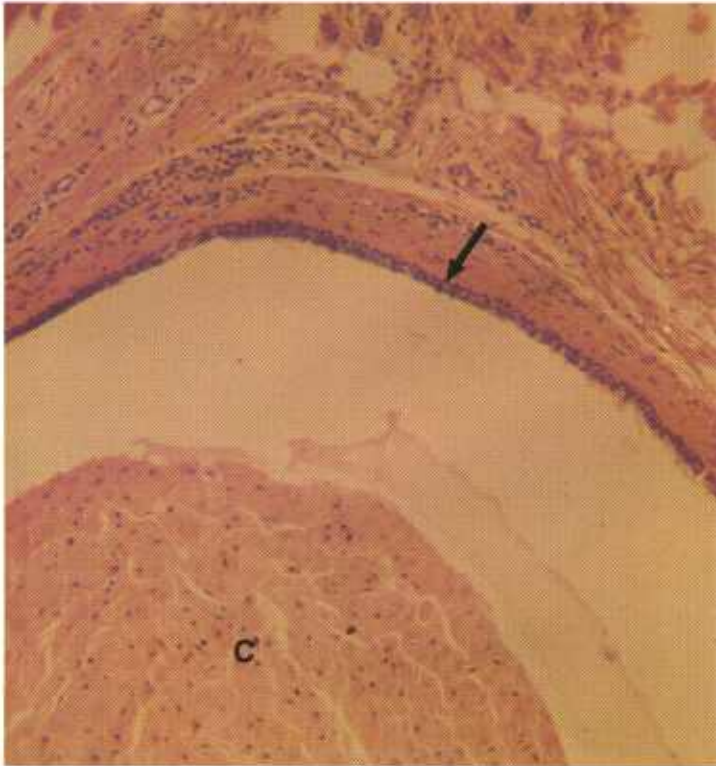


Figure 457.—Epidermal inclusion cysts of the masseter muscles of a 2-year-old steer (131314). The epithelial-lined cyst wall (arrow) encloses a mass of desquamated, cornified epithelial cells (C). Epidermal inclusion cysts in the masseter muscles are confused with tapeworm cysts. Hematoxylin-eosin stain.  $\times 125$ .

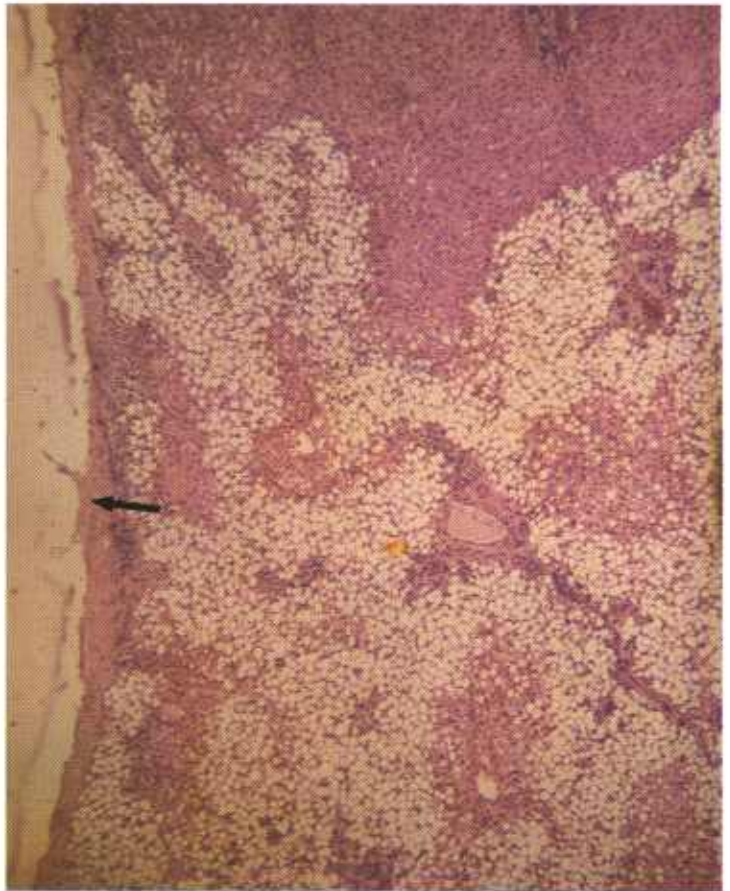


Figure 459.—Pseudoinfarct in the liver of an 8-year-old cow (D3170). An area of the liver has undergone fatty degeneration at the point where an adhesion (arrow) is attached to the hepatic capsule. Tension produced by the adhesion interferes with the vascular circulation of the hepatic parenchyma. The pseudoinfarct is sometimes confused with the infarcts associated with bacillary hemoglobinuria of cattle. However, whereas *Clostridium hemolyticum*, the cause of bacillary hemoglobinuria, initiates an acute inflammatory reaction in the region of the infarct, no such reaction occurs in the vicinity of the pseudoinfarct. Hematoxylin-eosin stain.  $\times 50$ .

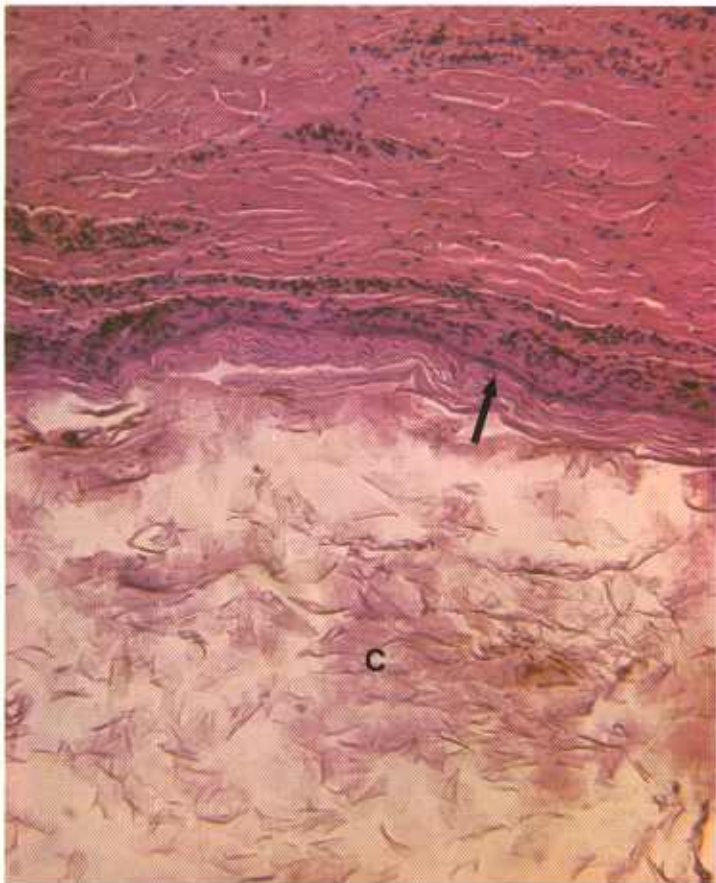


Figure 458.—Epidermal inclusion cysts in the skin of a hog (D469). The epithelial-lined cyst wall (arrow) encloses a mass of desquamated, cornified epithelial cells (C). The cysts measure 1 to 5 mm. in diameter and appear as clear or blue globular structures in the skin. They are confused with the cystic lesions of demodectic mange. Hematoxylin-eosin stain.  $\times 125$ .

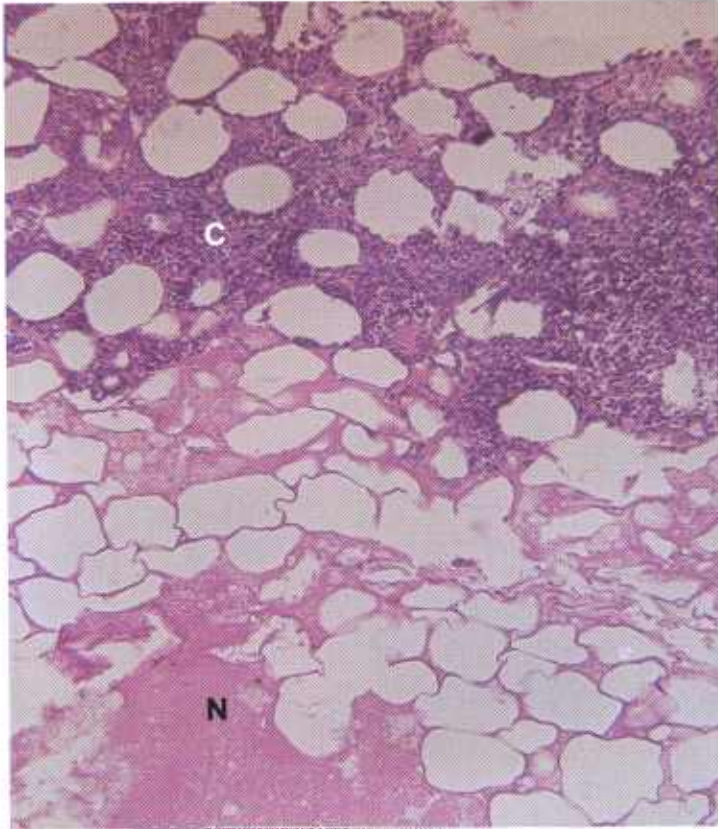


Figure 460.—Vaccination abscess in the flank region of a hog vaccinated with crystal violet hog cholera vaccine (D2396). The necrotic mass (N) is surrounded by a zone of inflammatory cells (C). The spaces are fat cells. Hematoxylin-eosin stain.  $\times 125$ .

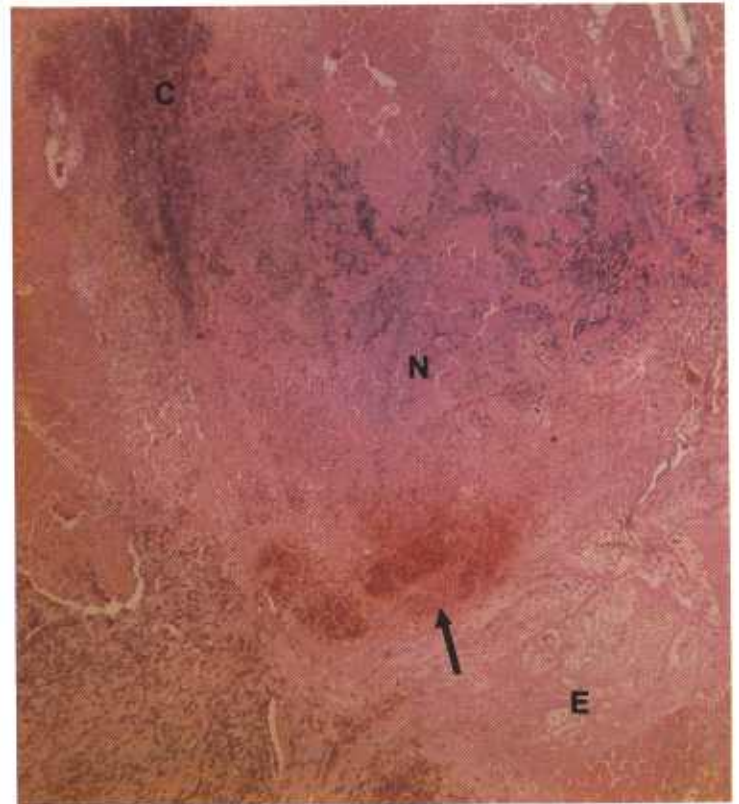


Figure 461.—Vaccination reaction in the neck muscles of a 10-month-old bull vaccinated with anthrax spore vaccine (D1863). An acute inflammatory reaction at the vaccination site shows edema (E), hemorrhage (arrow), infiltration of inflammatory cells (C), and coagulative necrosis (N) of muscle cells. Hematoxylin-eosin stain.  $\times 50$ .